

Cardiac arrest, chronic total occlusion, and occluded stent in a 16-year-old boy with Kawasaki disease: a case report

Michelle J. Connolly ^{1*}, Sarosh Khan ², Matthew E. Li Kam Wa ¹,
Matthew E. Faircloth³, and Brian Clapp²

¹Department of Cardiology, Atkinson-Morley Wing, St George's Hospital, St George's University Hospitals NHS Foundation Trust, Blackshaw Road, London SW17 0QT, UK;

²St Thomas' Hospital, Guy's and St Thomas' NHS Foundation Trust, UK; and ³Frimley Park Hospital, Frimley Health NHS Foundation Trust, UK

Received 31 March 2020; first decision 11 May 2020; accepted 30 July 2020; online publish-ahead-of-print 4 November 2020

Background

Kawasaki disease is the leading cause of premature coronary artery disease in developed countries. As such, patients may require revascularisation as children. However, there are no randomized data guiding treatment so this must be individualized. This case report describes the decision-making in a young patient requiring revascularization who had already suffered stent occlusion.

Case summary

Our patient, a 16-year-old boy with Kawasaki disease, presented with cardiac arrest during exercise. Coronary angiography showed that a proximal left anterior descending artery stent implanted at the age of 8 years had occluded some time ago and his right coronary artery was also chronically occluded. He has discussed in several Heart Team meetings and with international colleagues and a consensus reached to revascularize him surgically.

Discussion

It is vital that young patients with complex coronary disease are discussed in an extensive multidisciplinary setting to determine the most suitable means of treatment. The previously occluded stent was crucial in the individualized decision-making in this patient.

Keywords

Kawasaki disease • Cardiac arrest • Chronic total occlusion • Heart Team • Coronary revascularization • Case report

Learning points

- Kawasaki disease causes accelerated coronary artery disease that may require revascularization as a child or adolescent.
- A dedicated Heart Team approach is essential in managing this often complex pattern of disease in young patients.
- These patients need appropriate long-term follow-up, ideally in specialized Kawasaki clinics or with physicians familiar with Kawasaki patients.

Other specialities involved

Paediatrics, Intensive care medicine

Introduction

Kawasaki disease, first described in 1967, is an acute cryptogenic systemic vasculitis of infancy and early childhood that affects medium-

* Corresponding author. Tel: 020 8725 2866, Email: michelle.connolly@doctors.org.uk

Handling Editor: Aref Bin Abdulhak

Peer-reviewers: Inga Voges; Christoph Sinning

Compliance Editor: Christian Fielder Camm

Supplementary Material Editor: Deepthi Ranganathan

© The Author(s) 2020. Published by Oxford University Press on behalf of the European Society of Cardiology.

This is an Open Access article distributed under the terms of the Creative Commons Attribution Non-Commercial License (<http://creativecommons.org/licenses/by-nc/4.0/>), which permits non-commercial re-use, distribution, and reproduction in any medium, provided the original work is properly cited. For commercial re-use, please contact journals.permissions@oup.com

sized arteries.¹ Owing to coronary artery aneurysm formation, it is the leading cause of premature coronary artery disease in developed countries and patients may require revascularization at a very young age.² However, the optimal mode of this has not been established in randomized trials. We report a case of a 16-year-old boy with Kawasaki disease and previous coronary intervention who required further revascularization. All key decisions regarding his care were made in a multidisciplinary Heart Team setting, a crucial approach in the management of such complex patients.

Timeline

October 2003	Diagnosed with Kawasaki disease aged 3 months.
October 2010	Coronary angiogram shows 80% stenosis of the proximal left anterior descending artery (LAD) and a chronic total occlusion (CTO) of the right coronary artery (RCA).
April 2012	Elective percutaneous coronary intervention (PCI) to the proximal LAD with a bare-metal stent.
2015	Lost to follow-up.
3rd September 2019	Cardiac arrest whilst exercising at the gym. Angiogram shows occluded LAD stent and CTO of the RCA.
10th September	Discussed at local Heart Team meeting. Decision to transfer to centre with paediatric and adult cardiology and cardiothoracic surgery.
18th September	Patient transferred. Initial Heart Team discussion at second centre.
24th September	Cardiac magnetic resonance imaging demonstrates a limited infarct in the apical anterior wall and part of the apical septum.
25th September	Further Heart Team discussion. Both PCI and coronary artery bypass grafting (CABG) feasible.
27th September	Discussion with international colleagues. Consensus decision for CABG.
4th October	Undergoes bilateral mammary artery grafting.
10th October	Discharged home.
December 2019	Well at ongoing clinic follow-up.

Case presentation

A 16-year-old male of East Asian descent arrived at night via air ambulance intubated and ventilated to our Heart Attack Centre with a history that during high-intensity interval training at the gym he suffered a cardiac arrest. On site, he received three shocks for ventricular fibrillation with a return of spontaneous circulation (ROSC) after 17 min. An electrocardiogram (ECG) recorded 11 min after ROSC (*Figure 1A*) demonstrated marked anterolateral ST-segment elevation. An ECG recorded 116 min post-ROSC on arrival to our centre showed normalization of the ST segments (*Figure 1B*). On examination, he was intubated and ventilated, invasive blood pressure was

105/75 mmHg, and his heart rate was 86 b.p.m. in sinus rhythm. His heart sounds were normal, and there were no murmurs. His chest was clear to auscultation. Bedside echocardiography demonstrated a structurally normal heart with preserved left ventricular (LV) systolic function and no regional wall motion abnormalities. Initial troponin T was 798 ng/L (0–14 ng/L) and peaked at 3073 ng/L 2 h later. His parents gave a past medical history of Kawasaki disease, but that he was not taking any medications.

In view of the patient's stable clinical status, the lack of persistent ST-segment elevation on the ECG, and normal echocardiogram, we did not perform emergent coronary angiography as we did not suspect an acute coronary artery occlusion. He received a 300 mg loading dose of aspirin, a 180 mg loading dose of ticagrelor and continued on 75 mg aspirin once daily, and ticagrelor 90 mg twice daily with lansoprazole 30 mg once daily. In addition to antiplatelet therapy, he received a single 2.5 mg dose of fondaparinux, bisoprolol 2.5 mg once daily, and atorvastatin 80 mg once daily. He was admitted to the adult cardiac intensive care unit where he remained stable. Coronary angiography was performed the following morning.

Kawasaki disease was diagnosed at the age of 3 months in his country of origin for which he received intravenous immunoglobulin (IVIG) therapy on day 21 of his illness. He was not treated with acetylsalicylic acid nor was he anticoagulated. Echocardiography 6 days after IVIG treatment showed an aneurysm in the left main coronary artery measuring 5.5 mm. He responded well to treatment and remained under follow-up for mild left main coronary artery dilatation.

Aged 7 years following routine surveillance echocardiography suggestive of left anterior descending artery (LAD) stenosis, he underwent invasive coronary angiography. This demonstrated a small aneurysm followed by an 80% calcific stenosis of the proximal LAD, and a chronic total occlusion (CTO) of the dominant right coronary artery (RCA). Cardiac magnetic resonance (CMR) imaging showed reversible ischaemia in the inferior, inferolateral, and anterolateral walls.

In 2012 aged 8 years, he underwent elective intravascular ultrasound-guided rotablation-assisted percutaneous coronary intervention (PCI) to the proximal LAD with a 3.0 mm × 18 mm Multi-Link Vision bare-metal stent (Abbott Vascular, Chicago, USA; *Figure 2B*). This corrected the CMR perfusion abnormalities initially, but from 2015 he was lost to follow-up and was not taking any medications.

Coronary angiography during the current admission demonstrated an unobstructed left main stem; however, the previous LAD stent was occluded (*Figure 3A*) with the distal vessel filling retrogradely via septal and well-developed epicardial collaterals from the RCA. The left circumflex artery (LCx) was unobstructed (*Figure 3A*). There was a CTO in the RCA, as before, in the mid vessel (*Figure 3B*). The likeliest explanation for his presentation was the insufficient ability of the collateral circulation to meet the metabolic demand of the heart during exercise, resulting in ischaemia and ventricular fibrillation.

Computed tomography of the brain demonstrated no acute intracranial abnormality, and his neurological course was unremarkable.

Following a local Heart Team discussion, he was transferred to a different centre with expertise in both adult and paediatric cardiology and cardiac surgery. He underwent further imaging. Computed tomography established that the internal mammary arteries (IMAs) were free of disease. CMR demonstrated increased indexed LV end-diastolic volume (118 mL/m²) and normal LV wall thickness and normal indexed

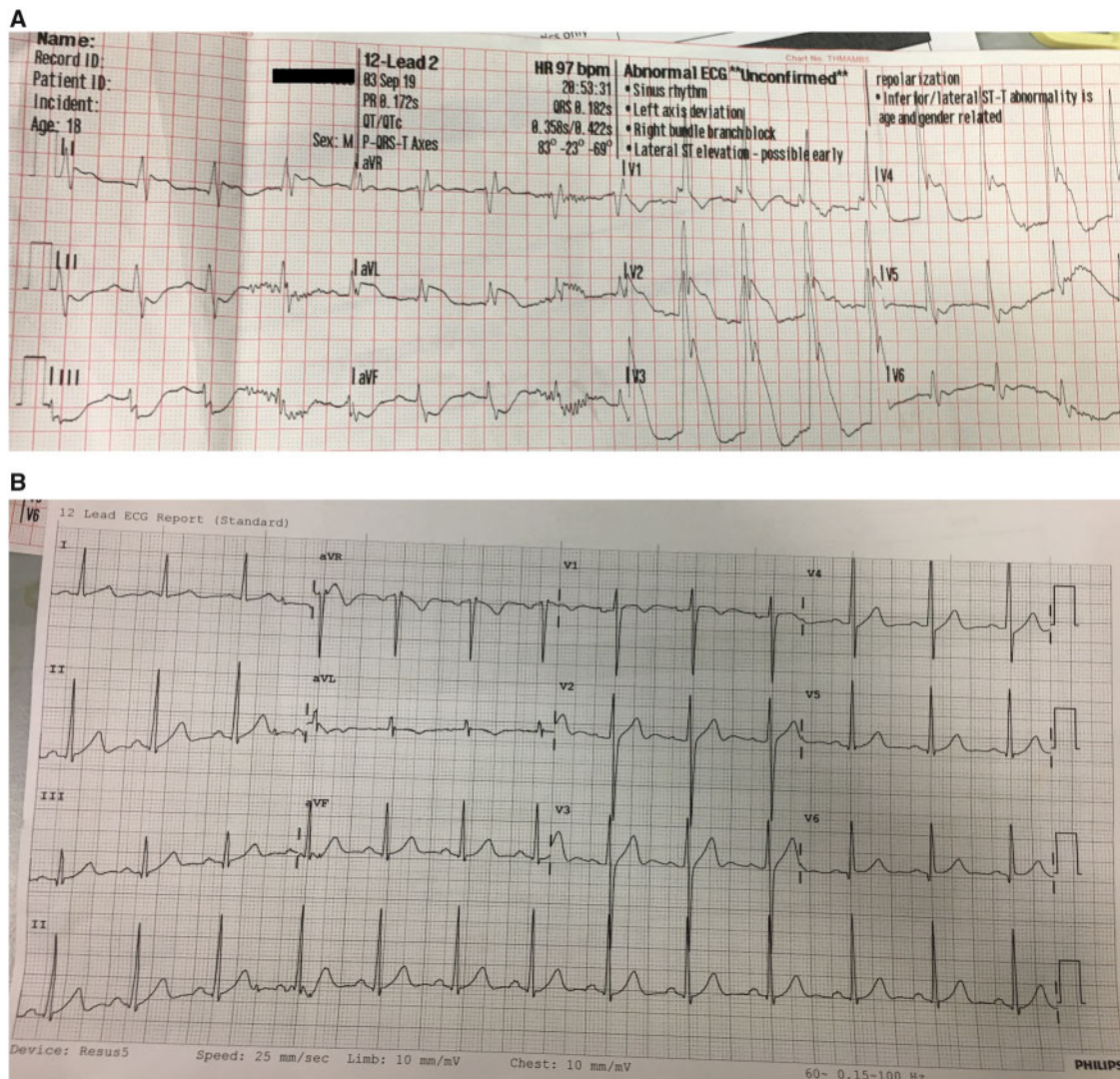


Figure 1 Electrocardiograms recorded after resuscitation (A) 11 min after ROSC showing sinus rhythm with anterolateral ST elevation; (B) 116 min after ROSC showing resolution of ST changes. ROSC, return of spontaneous circulation.

LV mass with preserved global LV systolic function and no regional wall motion abnormalities at rest. There was a limited infarct in the apical anterior wall and part of the apical septum (Figure 4). There was inducible ischaemia in 5/7 segments of the LAD territory and 4/5 segments of the RCA territory. All segments were viable.

At the Heart Team meeting, it was felt that either percutaneous or surgical revascularization were suitable strategies. Two days later, the case was discussed with international colleagues and a consensus reached to revascularize him surgically with the opinion being that this would provide him with a more durable result. This was particularly pertinent in his case given the RCA CTO and previously occluded stent. Following detailed discussion with the patient and his parents, he received a left IMA to the LAD and free right IMA to the posterior descending artery. His immediate post-operative course was uncomplicated. He was discharged home 7 days after surgery on

aspirin 75 mg once daily, clopidogrel 75 mg once daily, ranitidine 300 mg once daily, bisoprolol 1.25 mg once daily, atorvastatin 80 mg once daily, and paracetamol as required.

He was last seen in clinic in December 2019. Symptomatically, he was well and had returned to the gym but was refraining from heavy weights given his sternotomy scar. Clinical examination revealed a well-healed wound, no murmurs and a clear chest. All medications were stopped except aspirin and atorvastatin. He underwent repeat CMR in January 2020, which showed no inducible myocardial ischaemia.

Discussion

We have described the case of a 16-year-old male with Kawasaki disease who presented with cardiac arrest. A bare-metal stent in the

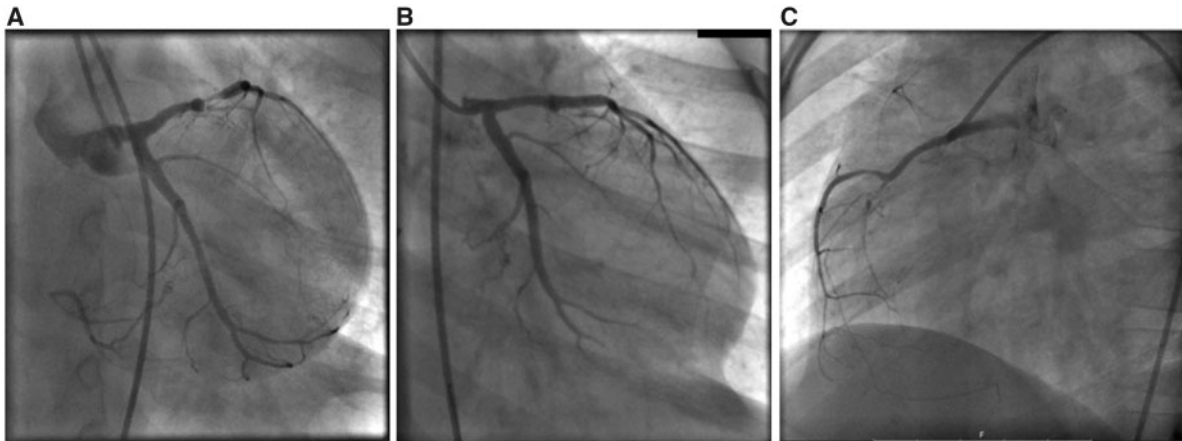


Figure 2 Angiogram aged 8 years (A) Critical proximal left anterior descending artery stenosis before and (B) after angioplasty with a 3.0 mm × 18 mm bare-metal stent; (C) Chronic total occlusion of the mid right coronary artery.

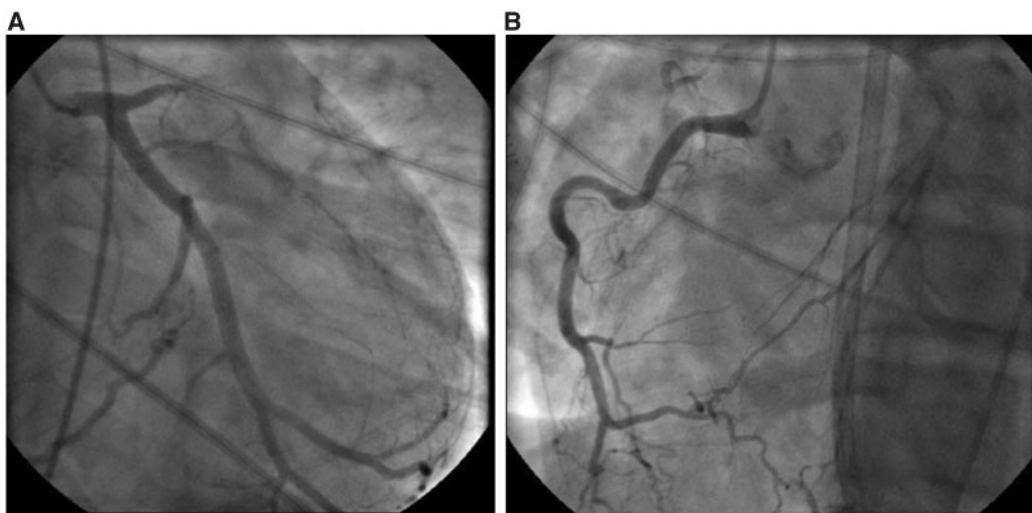


Figure 3 Angiogram following cardiac arrest (A) Occluded proximal LAD stent and unobstructed left circumflex artery; (B) Chronic total occlusion of the mid RCA at the level of a large acute marginal branch. Collaterals from the RCA are shown backfilling the mid LAD at the distal stent edge. LAD, left anterior descending artery; RCA, right coronary artery.

proximal LAD had occluded some time previously, and the RCA was also chronically occluded. He was extensively discussed in a Heart Team setting and underwent surgical revascularization.

Kawasaki disease is the leading cause of coronary artery disease in children in developed countries. The highest incidence is in Asian children, especially those of Japanese origin.² At diagnosis, IVIG and aspirin are given to prevent coronary artery aneurysm formation although even with timely immunotherapy one in five children will develop aneurysms, with those younger than six months at diagnosis at particular risk.³ Our patient was diagnosed aged 3 months and did not receive IVIG until day 21 of his illness.

Patients with Kawasaki disease complicated by significant aneurysms will often require coronary revascularization due to vessel wall changes both within the aneurysm and the adjoining area. There are no randomized controlled trials of coronary artery bypass grafting (CABG) vs. PCI in this population. Most of the experience with paediatric revascularization in Kawasaki disease comes from Japan where CABG using the left IMA has been practised since the mid-1980s⁴ and balloon angioplasty, rotational atherectomy, and stenting have been utilized since the 1990s.^{5,6}

In a Japanese observational retrospective study, 67 paediatric Kawasaki patients underwent PCI with bare-metal stents and 81 underwent CABG.⁷ Whilst the primary endpoint of all-cause

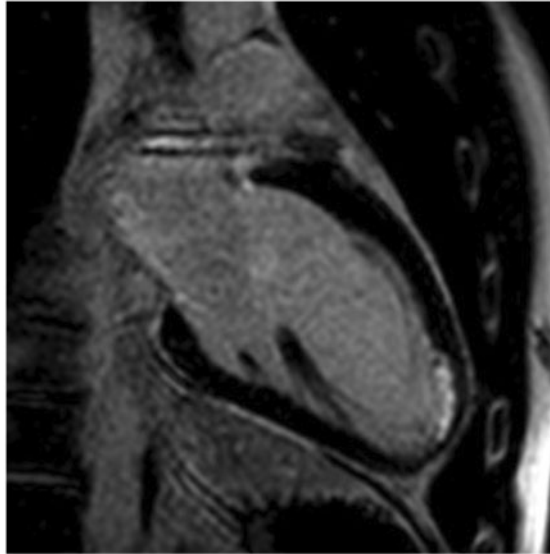


Figure 4 Cardiac magnetic resonance imaging slice showing a limited infarct in the apical anterior wall and part of the apical septal wall of 25–50% transmural.

mortality and myocardial infarction was similar in both groups, there was a significantly higher rate of target lesion revascularization in the PCI group. More recent retrospective data from Canada comparing mode of revascularization in 22 paediatric patients found that CABG was more likely to be performed for multivessel disease and required less reintervention than did PCI with bare-metal stents.⁸ This pattern of similar outcomes in terms of mortality although with increased frequency of repeat revascularization is seen in older patients with atherosclerotic disease.⁹

As with the more common atherosclerotic patient, the decision between surgical and percutaneous intervention is an individualized one. There are several reasons why bilateral IMA grafting was favoured in our patient. The superior long-term patency of arterial grafts over vein grafts is well established in adults, and data also exist for the Kawasaki population. Twenty-five year patency has been demonstrated at 87% with IMA grafts vs. 44% for vein grafts.¹⁰ The IMA also deserves particular consideration in children, with its ability to grow in proportion to somatic growth allowing its use from an early age.¹⁰ The same cannot be said for vein grafts or percutaneously placed stents.

Our approach was in line with American Heart Association consensus statements on revascularization in Kawasaki disease based on observational data, which favours CABG in older children and adults with multivessel involvement using bilateral IMA grafts where possible.² The presence of the previously occluded stent was relevant in the individualized decision-making of this patient. Further studies in this important patient subgroup are desirable as they will help to direct future treatment strategies.

Lead author biography



Michelle Connolly is an ST6 interventional cardiology trainee at St George's Hospital in London. She graduated MBPhD from Guy's, King's and St Thomas' School of Medicine in 2011.

Supplementary material

[Supplementary material](#) is available at *European Heart Journal - Case Reports* online.

Slide sets: A fully edited slide set detailing this case and suitable for local presentation is available online as [Supplementary data](#).

Consent: The authors confirm that written consent for submission and publication of this case report including images and associated text has been obtained from the patient and his parents in line with COPE guidelines.

Conflict of interest: none declared.

References

1. Kawasaki T. Acute febrile mucocutaneous syndrome with lymphoid involvement with specific desquamation of the fingers and toes in children. *Arerugi* 1967;**16**: 178–222.
2. McCrindle BW, Rowley AH, Newburger JW, Burns JC, Bolger AF, Gewitz M et al.; On behalf of the American Heart Association Rheumatic Fever, Endocarditis, and Kawasaki Disease Committee of the Council on Cardiovascular Disease in the Young; Council on Cardiovascular and Stroke Nursing; Council on Cardiovascular Surgery and Anesthesia; and Council on Epidemiology and Prevention. Diagnosis, treatment, and long-term management of Kawasaki disease: a scientific statement for health professionals from the American Heart Association. *Circulation* 2017;**135**:e927–e999.
3. Newburger JW, Takahashi M, Burns JC. Kawasaki disease. *J Am Coll Cardiol* 2016; **67**:1738–1749.
4. Kitamura S, Kawachi K, Oyama C, Miyagi Y, Morita R, Koh Y et al. Severe Kawasaki heart disease treated with an internal mammary artery graft in pediatric patients. A first successful report. *J Thorac Cardiovasc Surg* 1985;**89**:860–866.
5. Ino T, Nishimoto K, Akimoto K, Park I, Shimazaki S, Yabuta K et al. Percutaneous transluminal coronary angioplasty for Kawasaki disease: a case report and literature review. *Pediatr Cardiol* 1991;**12**:33–35.
6. Ishii M, Ueno T, Ikeda H, Iemura M, Sugimura T, Furui J, et al. Sequential follow-up results of catheter intervention for coronary artery lesions after Kawasaki disease: quantitative coronary artery angiography and intravascular ultrasound imaging study. *Circulation* 2002;**105**:3004–3010.
7. Muta H, Ishii M. PCI versus CABG for stenotic lesions after Kawasaki disease. *J Pediatr* 2010;**157**:120–126.
8. Dionne A, Bakloul M, Manlhiot C, McCrindle BW, Hosking M, Houde C et al. Coronary artery bypass and percutaneous intervention after Kawasaki disease: the Canadian pediatric experience. *J Am Coll Cardiol* 2016;**67**:971.
9. Stone GW, Kappetein AP, Sabik JF, Pocock SJ, Morice MC, Puskas J, et al. Five year outcomes after PCI or CABG for left main coronary disease. *N Engl J Med* 2019;**381**:1820–1830.
10. Kitamura S, Tsuda E. Significance of coronary revascularization for coronary-artery obstructive lesions due to Kawasaki disease. *Children* 2019;**6**:16.