

Contents lists available at [ScienceDirect](http://www.sciencedirect.com)

International Journal of Surgery Case Reports

journal homepage: www.casereports.com

Pushing the boundaries in liver graft utilisation in transplantation: Case report of a donor with previous bile duct injury repair



Asma Sultana*, James J. Powell, Gabriel C. Oniscu

Scottish Liver Transplant Unit, Royal Infirmary of Edinburgh, Edinburgh, Scotland, United Kingdom

ARTICLE INFO

Article history:

Received 17 January 2017

Received in revised form 23 June 2017

Accepted 25 June 2017

Available online 29 June 2017

Keywords:

Extended criteria donor

Liver transplantation

Organ procurement

Bile duct injury

ABSTRACT

INTRODUCTION: Liver transplantation is a recognised treatment for extensive bile duct injuries with secondary biliary cirrhosis or recurring sepsis. However, there have been no reports of successful liver transplantation from a donor who sustained a previous bile duct injury.

PRESENTATION OF CASE: Here we discuss the case of a liver transplant from a 51-year-old brain dead donor who had suffered a Strasberg E1 bile duct injury and had undergone a Roux-en-Y hepaticojejunostomy 24 years prior to donation. The liver was successfully recovered and transplanted into a 56-year-old male recipient with end stage liver disease consequent to alpha 1 antitrypsin deficiency. The graft continues to function well 36 months post-transplant, with normal liver function tests and imaging revealing a patent hepaticojejunostomy.

DISCUSSION: The potential associated vascular injuries should be identified during bench preparation whilst the management of biliary reconstruction at the time of transplant should follow the principles of biliary reconstruction in cases with biliary injuries, extending the hilar opening into the left duct.

CONCLUSION: This case highlights the successful utilisation of a post bile duct injury repair liver, employing an experienced procurement team and careful bench assessment and reconstruction.

© 2017 Published by Elsevier Ltd on behalf of IJS Publishing Group Ltd. This is an open access article under the CC BY-NC-ND license (<http://creativecommons.org/licenses/by-nc-nd/4.0/>).

1. Introduction

Bile duct injuries can be of varying degrees of severity and have the potential for causing secondary biliary cirrhosis/recurrent biliary sepsis, which may require liver resection and even transplantation [1]. Liver transplantation for bile duct injuries is performed either for acute liver failure or secondary biliary cirrhosis. Prognosis in patients transplanted for early hepatic insufficiency is much worse than those transplanted electively [1,2]. Associated vascular injuries are common in patients who sustain a bile duct injury. This can lead to ischaemia and partial atrophy of the liver, stricturing of the hepaticojejunostomy with secondary biliary cirrhosis, or liver abscesses [3]. Therefore, livers that sustained a previous bile duct injury may not be considered as suitable grafts for transplantation. Furthermore, at the time of donation, the extent of the injury is unlikely to be known. Herein, we discuss a case where a post bile duct injury liver was recovered and successfully transplanted. We have adhered to the SCARE guidelines in the reporting of this case [4,5].

2. Presentation of case

A 51-year-old female sustained an intracranial haemorrhage and proceeded to donation after brain death. She had previously

sustained a Strasberg E1 [6] bile duct injury at the level of common hepatic duct during a laparoscopic cholecystectomy in 1988 managed with a Roux-en-y hepaticojejunostomy with no further problems during the follow-up.

At the time of liver procurement, an atrophic right lobe was noted. During bench preparation no hepatic arterial tree injuries were identified. The bile duct confluence was opened into the left duct, identifying a segment 4, caudate and segment 2 and 3 ducts and creating a wide opening to facilitate hepaticojejunostomy (Fig. 1).

The recipient was a 56-year-old male with cirrhosis secondary to alpha-1 antitrypsin deficiency (MELD score 16). Liver implantation was performed using a side-to-side cavo-cavostomy, end-to-end portal vein reconstruction, donor common hepatic artery to recipient common hepatic artery anastomosis and a hepaticojejunostomy. Given the atrophy of the right lobe, the diaphragm was plicated in order to avoid rotation of the liver leading to hepatic venous outflow problems. The recipient had patent vasculature and hepaticojejunostomy as demonstrated on cross sectional imaging (CT scan) at 12 months. The recipient remains well at 36 months follow-up with normal liver function tests and Doppler ultrasound.

3. Discussion

There remains a significant shortfall between the numbers of available donor organs and the number of patients on the waiting list for a liver transplant. Despite an increased utilisation of Donors after Circulatory Death (DCD), live donors or splitting of suitable

* Corresponding author at: Royal Infirmary of Edinburgh, Little France Crescent, Old Dalkeith Road, Edinburgh, EH16 4SA, United Kingdom.
E-mail address: asmasul@yahoo.com (A. Sultana).

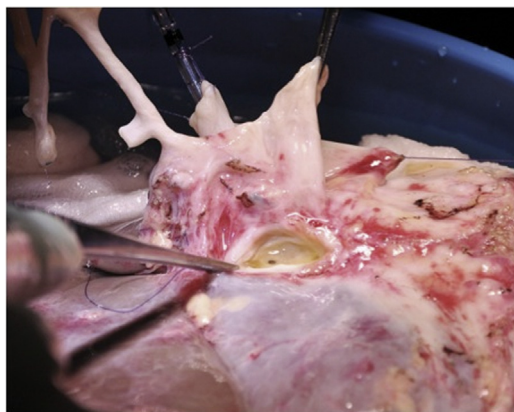


Fig. 1. Biliary anatomy, demonstrating a segment 4, caudate and segment 2 and 3 ducts during bench surgery.

livers, there is still a need to expand the organ utilisation criteria in order to reduce waiting list mortality [7,8]. Among the extended criteria organs [9] the use of livers from donors of advanced age, or those with hepatic steatosis, infective conditions such as hepatitis B and C and HIV, or a previous history of malignancy warrant careful review and quantification of associated risks prior to transplant.

A particularly challenging category is the use of liver grafts that sustained previous injuries [such as trauma [10,11], biliary or vascular injuries [12]]. Their utilisation is haphazard and relies on surgeon's experience with complex transplant and hepato-biliary cases.

The use of a liver post bile duct injury has not been reported before, making this the first such case report. The particular concerns regarding biliary injuries are the extent of the injuries and the potential associated vascular injuries, which must be identified during bench preparation. A long interval between injury and retrieval (as was the case here) provides some reassurance that transplantation can be successfully undertaken. The management of biliary reconstruction at the time of transplant should follow the principles of biliary reconstruction in cases with biliary injuries, extending the hilar opening into the left duct to ensure a wide, patent anastomosis. During this step, attention should be paid to segment IV arteries which sometimes may be difficult to identify during bench surgery.

The presence of previous bile duct injury should not be regarded as an absolute contraindication to liver transplantation. Scrutiny of donor's clinical course post bile duct injury repair, together with an experienced procurement team and a careful bench assessment are key to a successful transplant. The lack of biliary complications three years post transplant reinforces the safety of using such donors.

4. Conclusion

This case highlights the successful utilisation of a post bile duct injury repair liver, employing an experienced procurement team and careful bench assessment and reconstruction.

Learning points

- First case report on the use of a donor with previous bile duct injury for liver transplantation.
- Emphasis on careful liver retrieval and backbench preparation, with attention to arterial blood supply.

Open Access

This article is published Open Access at sciedirect.com. It is distributed under the [IJSCR Supplemental terms and conditions](#), which permits unrestricted non commercial use, distribution, and reproduction in any medium, provided the original authors and source are credited.

- Previous bile duct injury does not preclude use of the liver in orthotopic liver transplantation.

Conflicts of interest

No conflicts of interest.

Funding

No funding to declare.

Ethical approval

Ethical approval not required.

Consent

Consent obtained.

Authors contribution

All 3 authors contributed to the case report, in the form of identification of the report, and write up.

Guarantors

All 3 authors act as guarantors viz Asma Sultana, James Powell and Gabriel Oniscu.

References

- [1] B.N. Thomson, R.W. Parks, K.K. Madhavan, et al., Liver resection and management of iatrogenic biliary injury, *World J. Surg.* 31 (12) (2007) 2363–2369, <http://dx.doi.org/10.1007/s00268-007-9234-9> [publishedOnlineFirst:2007/10/06].
- [2] P. Parrilla, R. Robles, E. Varo, et al., Liver transplantation for bile duct injury after open and laparoscopic cholecystectomy, *Br. J. Surg.* 101 (2) (2014) 63–68, <http://dx.doi.org/10.1002/bjs.9349>.
- [3] J.F. Buell, D.C. Cronin, B. Funaki, et al., Devastating and fatal complications associated with combined vascular and bile duct injuries during cholecystectomy, *Arch. Surg.* 137 (6) (2002) 703–708, discussion 08–10.
- [4] R.A. Agha, A.J. Fowler, A. Saetta, et al., A protocol for the development of reporting criteria for surgical case reports: the SCARE statement, *Int. J. Surg.* 27 (2016) 187–189, <http://dx.doi.org/10.1016/j.ijsu.2016.01.094>.
- [5] R.A. Agha, A.J. Fowler, A. Saetta, et al., The SCARE statement: consensus-based surgical case report guidelines, *Int. J. Surg.* 34 (2016) 180–186.
- [6] S.M. Strasberg, M. Hertl, N.J. Soper, An analysis of the problem of biliary injury during laparoscopic cholecystectomy, *J. Am. Coll. Surg.* 180 (1) (1995) 101–125.
- [7] W.R. Kim, T.M. Therneau, J.T. Benson, et al., Deaths on the liver transplant waiting list: an analysis of competing risks, *Hepatology* 43 (2) (2006) 345–351, <http://dx.doi.org/10.1002/hep.21025> [publishedOnlineFirst:2006/01/28].
- [8] F. San Juan, M. Cortes, Mortality on the waiting list for liver transplantation: management and prioritization criteria, *Transplant. Proc.* 43 (3) (2011) 687–689, <http://dx.doi.org/10.1016/j.transproceed.2011.01.106> [published Online First: 2011/04/14].
- [9] A.S. deLemos, P.A. Vagefi, Expanding the donor pool in liver transplantation: extended criteria donors, *Clin. Liver Dis.* 2 (4) (2013) 156–159.
- [10] I.L. Geenen, M.N. Sosef, A. Shun, et al., Usage and outcomes of deceased donor liver allografts with preprocurement injury from blunt trauma, *Liver Transpl.* 15 (3) (2009) 321–325, <http://dx.doi.org/10.1002/lt.21687> [publishedOnlineFirst:2009/02/27].
- [11] F. Di Benedetto, C. Quintini, N. De Ruvo, et al., Successful liver transplantation using a severely injured graft, *J. Trauma* 63 (1) (2007) 217–220, <http://dx.doi.org/10.1097/TA.0b013e318074ecaa> [publishedOnlineFirst:2007/07/12].
- [12] S. Falconer, J.J. Powell, G.C. Oniscu, When there is not plenty for everyone: options for reconstructing a suprahepatic vena cava injured during organ procurement, *Liver Transpl.* 19 (3) (2013) 349–350, <http://dx.doi.org/10.1002/lt.23599> [publishedOnlineFirst:2013/03/01].