

Multiplanar Assembly Mammoplasty Based on the Divine Proportion

Oswaldo Pereira Filho, MD*

Jorge BIns Ely, PhD†

Kuang Hee Lee, MD‡

Elizabeth Machado Paulo, MSc§

Alfredo Spautz Granemann, MD¶

Background: The study sought to plan mastopexy and breast reduction according to the principle of the divine proportion, represented by the letter phi, via the convergent assembly of multiple layers to create the new breast. This strategy is based on the constancy of the submammary fold and the orientation of the vertex of a V-shaped triangle opening at approximately 60° at the umbilicus, with each branch opening in the direction of the acromioclavicular joint.

Methods: The strategy was prospectively investigated in 265 patients (n = 530 breasts). The mean patient age was 36 years. The follow-up ranged from 6 months to 3 years.

Results: A total of 220 patients (83%) received a good score (1–4) according to Strasser grading. Complications were few, but included delayed healing with minimal scar ulceration in 19 patients (7%), asymmetry in 16 (6%), and partial nipple necrosis in 4 (1.5%).

Conclusions: This approach adds precision to mammoplasty, reduces the laxity in the axillary region, promotes bulk in the upper pole, and eases nipple–areola complex elevation. (*Plast Reconstr Surg Glob Open* 2019;7:e1979; doi: 10.1097/GOX.0000000000001979; Published online 13 February 2019.)

INTRODUCTION

The current techniques employed for breast reduction, mastopexy with or without implants, are planned using the pinch test, prefabricated molds, and several other empiric strategies. Although body types vary widely, some approaches involve positioning the nipple–areolar complex (NAC) 18–21 cm from the suprasternal notch (SN) or from a clavicle middle point to the nipple. The breast assembly usually is achieved by approximating the border of the remaining tissue to form the base of the new breast cone. The repositioning of the NAC is also subject to the artistic surgeons' empirical interpretation. Integument mobilization utilizes different flaps or pedicles to ease NAC elevation and to fill the upper pole. All these strategies reflect the challenge to obtaining a desirable breast outcome.^{1–14}

From the *Plastic Surgery Department, Clinica Jane - Hospital Ilha - UFSC, Florianópolis, Santa Catarina, Brazil; †Universidade Federal de Santa Catarina - UFSC, Florianópolis, Santa Catarina, Brazil; ‡Clinica Jane - Hospital Ilha, Florianópolis, Santa Catarina, Brazil; §Univale - Universidade do Vale do Itajaí, Florianópolis, Santa Catarina, Brazil; and ¶Clinica Jane, Plastic Surgery Department, Cirurgia Plástica, Florianópolis, Santa Catarina, Brazil.

Received for publication October 14, 2017; accepted August 22, 2018.

Copyright © 2019 The Authors. Published by Wolters Kluwer Health, Inc. on behalf of The American Society of Plastic Surgeons. This is an open-access article distributed under the terms of the Creative Commons Attribution-Non Commercial-No Derivatives License 4.0 (CCBY-NC-ND), where it is permissible to download and share the work provided it is properly cited. The work cannot be changed in any way or used commercially without permission from the journal. DOI: 10.1097/GOX.0000000000001979

Attractive breast geometry depends on the achievement of the golden ratio among the submammary fold, NAC border, and sternal midline. Therefore, the purpose of this study was to plan mastopexy and breast reduction according to the principle of the divine proportion,^{15–17} denoted by phi, with centripetal multiplanar (ie, multiple layer) assembly of the new breast. This strategy is based on the constancy of the submammary fold, with the breast planned over a V-shaped isosceles triangle with a vertex at the umbilicus. Each branch of this triangle opens in the direction of the acromioclavicular joint and functions as a vanishing point that orients the vertical and horizontal resection and the convergent assembly of the mammary tissue.

METHODS

The strategy was investigated in 265 patients (n = 530 breasts). The mean age of the patients was 36 years. The follow-up ranged from 6 months to 3 years.

Technique

The new breast is planned over a V-shaped triangle with the vertex situated at the umbilicus, point u. The triangle affords vanishing points, with the 2 branches of the isosceles triangle opening at an angle of approximately 60° from point u, parallel to the mammary line, and close

Disclosure: The authors have no financial interest to declare in relation to the content of this article.

Supplemental digital content is available for this article. Clickable URL citations appear in the text.

to the acromioclavicular articulation. P1, the key point of the strategy, is situated at the intersection of each branch of the V-shaped triangle with the submammary fold. Using a compass, the distance measured in centimeters from P1 to the midline, point m, is transposed to the midsternal line cranially, determining point m'. According to the divine proportion, point P2, the apex of the new breast, is situated over each branch of the V-shaped triangle at a distance from P1 = $(P1 \rightarrow m) \text{ cm} \times \phi = (P2 \rightarrow m')$ cm.

Coincidentally, the distance between P1→P2 in centimeters measured with a compass is almost the same as the distance between P2→m' (Fig. 1).

Pulling the breast upward with a temporary loop stitches at point P2, the same distance between P1→P2 is transposed from that point downward, marking the limit of the base of the cone and the amount of horizontal skin and hypertrophic tissue to be resected. For example, if P1 until m = 7.5 cm, then P2, the ideal position of areola superior

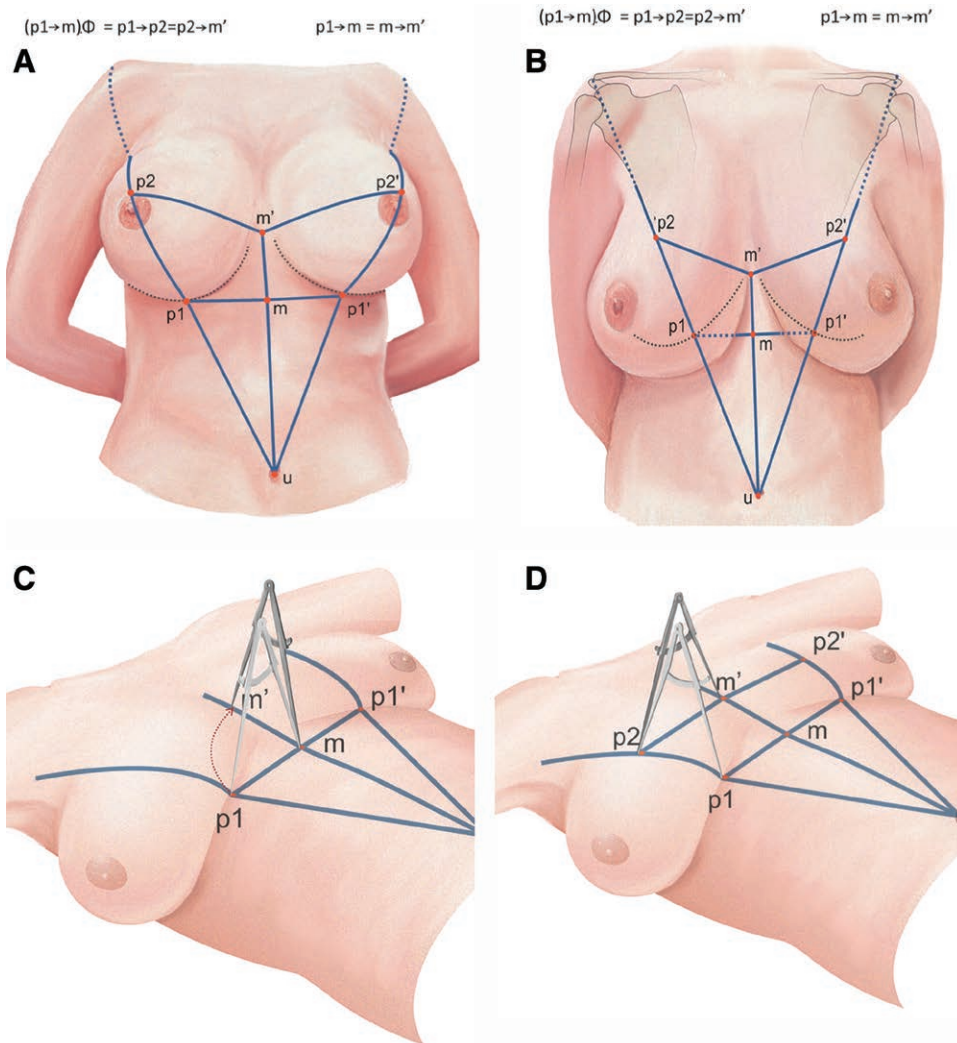


Fig. 1. Planning the new breast in the orthostatic and supine position. A, The golden ration can be seen in an attractive breast. In the example, if $P1 \rightarrow m = 7.5 \text{ cm}$, then $P1 \rightarrow P2 = (P1 \rightarrow m) \times \phi = 7.5 \text{ cm} \times 1.618 = 12.1 \text{ cm}$, which is the expected distance between them. When $P1 \rightarrow m = 7 \text{ cm}$, the projected $P1 \rightarrow P2 = m' \rightarrow P2 = 7 \times \phi (1.618) = 11.3 \text{ cm}$. B, Planning the new breast. With the patient in a standing position, the submammary fold is delineated. The 30° vertex of the squadron is positioned over the umbilicus, point u. The branches of the isosceles of the triangle run in the direction of the acromioclavicular joint. Its intersection with the submammary fold gives the origin of P1, the key point. P2, the superior border of the areola of the new breast, is situated over the axis of each triangle at the distance from P1 $(P1 \text{ until } m) \times \phi$. The distance of P1 to m = m toward m'. C, Planning the new breast with the patient in 30° dorsiflexion. Knowing the projection of the submammary fold, the key distance from P1 to m and the patient's body type, the distance from P1 to m is transposed over the midline creating m', composing the triangle $P1 \rightarrow m \rightarrow u \rightarrow P1$. D, P2 is situated over the branch of the triangle with the vertex at point u (umbilicus) running to the acromioclavicular joint. The distance $P1 \rightarrow P2 = m' \rightarrow P2 = P1 \times \phi (1.618)$. In the example, if $P1 \rightarrow m = 7$; $P1 \rightarrow P2 = 7 \times (1.618) = 11.3 \text{ cm}$. Coincidentally, most of the times $m \rightarrow m' = 1/3$ of distance $m' \rightarrow u$.

border at the apex of the new breast, will be situated at the distance $P1 \rightarrow m$ ($7.5 \text{ cm} \times \phi (1.618) = 12.1 \text{ cm}$) from P1. That distance is equal to $P2 \rightarrow m'$ in centimeters (Fig. 2). The final scar is converted into an inverted T and can be converted into an L shape if the distance between the medial limit of the breast to be resected, point C (medial corner of the new cone of the breast after resection), until the submammary fold, P1, is $< 2 \text{ cm}$.

The breast is assembled with multiple internal layers, and the auxiliary pulls the lateral quadrant in the direction of P1. Depending on the extent of tissue resection, usually, 4–8 retention sutures are used between the inner layers of the breast integument and the pectoral muscle (Fig. 3). The main layer is the suturing of the remaining mammary border with the submammary Scarpa's fascia along the submammary fold¹⁸ (Fig. 4). Usually, 6–8 adhesion sutures are used to mobilize the lateral quadrant in the direction of P1 and 2–3 stitches are used from the mammary sternal medial border, also in the direction of P1 (Fig. 5). In the same fashion, the dermal layer is sutured. The V-shaped branch of the triangle orients the objective amount of vertical resection along the axis P1 toward P2. The epithelium is removed to complete Schwarzmann maneuver and is facilitated using tumescent infiltration between the epidermal and dermal layer with saline solution without epinephrine. If necessary, the dermis around the NAC can be incised to help its transposition at P2. Lipoplasty under the areola and the upper pole eases NAC repositioning overall in large fat breast, prevalent in overweight patients mainly after fifth decade. Lipoplasty under the areola and the upper pole eases NAC repositioning overall in large fat breast, prevalent in overweight patients mainly after fifth decade. It preserves subdermal vascular plexus around areola important to maintain adequate lymphatic and venous drainage.¹⁹ The ideal distance between the inferior contouring of the areola and P1 is the same distance as $P1 \rightarrow m$. However, the action of gravity from that

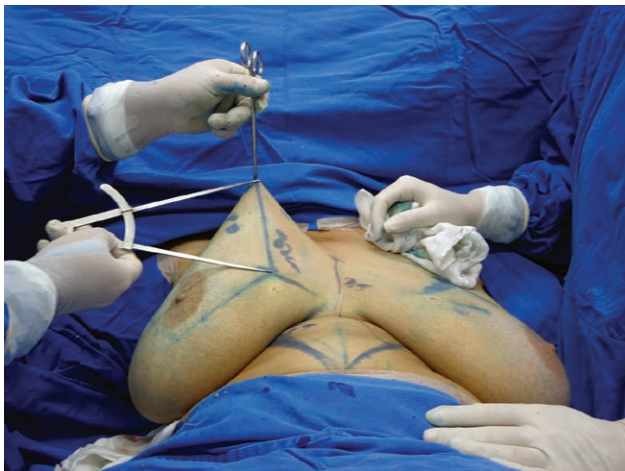

Fig. 2. The amount of the horizontal resection is calculated by pulling the breast with a hook at P2. In this case, P1 to m measured 7.5 cm. Then, the horizontal excess of the hypertrophic integument preserved 12.1 cm ($7.5 \text{ cm} \times 1.618$) from P2 to form the new mammary cone.

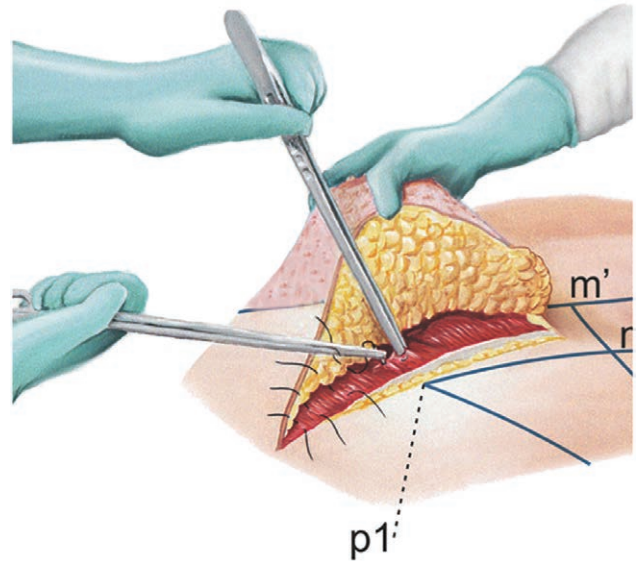


Fig. 3. The breast assembly is oriented by the axis of the umbilicus and the acromioclavicular joint. The integument is sutured in a multiplanar, that is, multilayer fashion with absorbable retention sutures over the serratus and pectoralis major muscle. The breast lateral quadrant converges in a centripetal rotation to point P1. The medial quadrant is also rotated to P1.

distance is subtracted from 1 cm to result in a final transoperative proportion of upper pole/lower pole of 55/45 (Fig. 6). No drains are used (see **Video 1, Supplemental Digital Content 1**, which demonstrates the divine proportion concept in planning the vertical and horizontal resection, the steps of multiplanar convergent assembling, the ideal NAC positioning in a 64-year-old patient presenting intermediated body type, and large breast reduction. This video is available in the “Related Videos” section of the Full-Text article on PRSGlobalOpen.com or available at <http://links.lww.com/PRSGO/A899>).

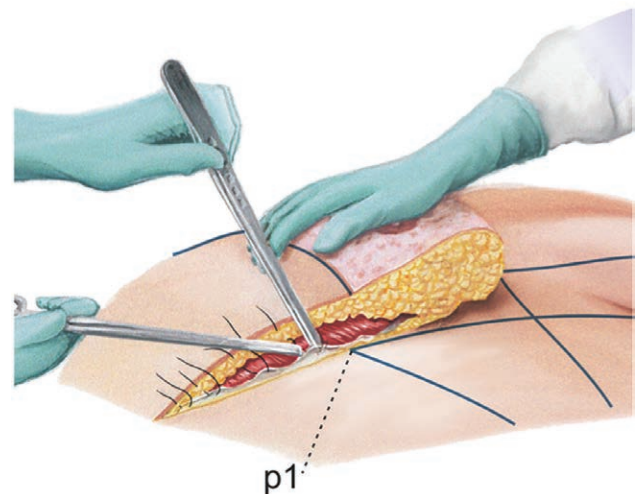


Fig. 4. The main layer is created between the breast integument and the Scarpa's fascia at the level of the submammary fold. This is a very strong layer. Finally, the suturing is completed with running sutures of the subdermal and intradermal layers.

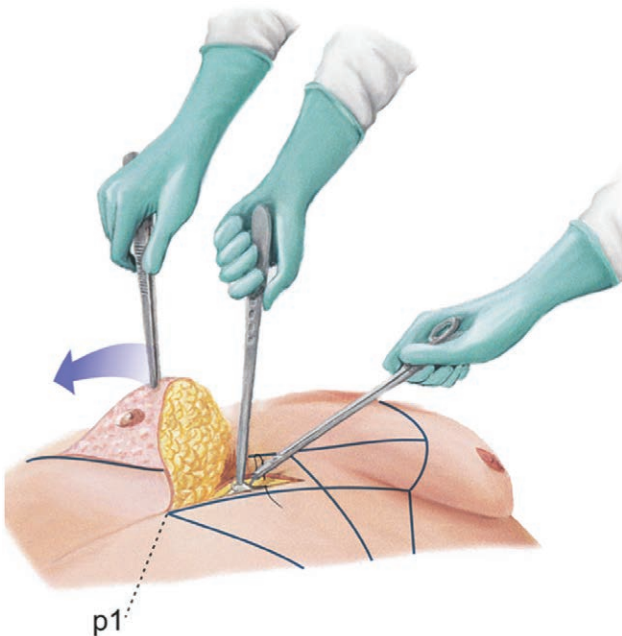


Fig. 5. Centripetal rotation of breast tissue from the sternum region to P1 completes the assembly. The vertical amount of skin is objectively evaluated and completed with Schwarzmann maneuver.

To obtain an objective analysis of the esthetic result, the data are evaluated according to Strasser grading.²⁰ In this system, the flaws are classified according to 5 headings: malposition, distortion, asymmetry, contour deformity, and scarring all negative attributes. The absence of any of these flaws is considered a perfect result; thus, with this system, a perfect result obtains zero points. One to 4 is classified as a good result, 5–14 as mediocre, and ≥ 15 as a poor result.

The inclusion criteria consisted of breast reduction or mastopexy with upper pedicle. Breast reduction using an inferior pedicle or associated with an implant was excluded from study.

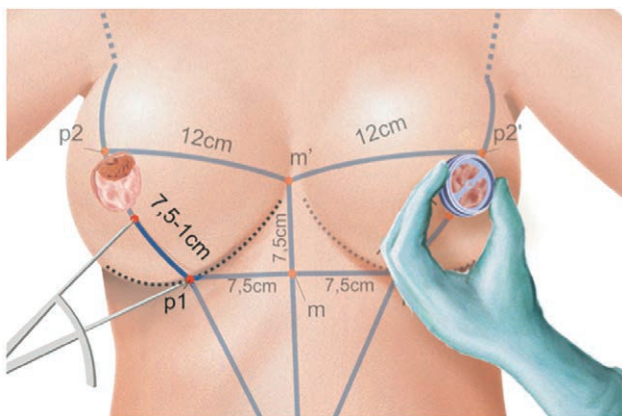
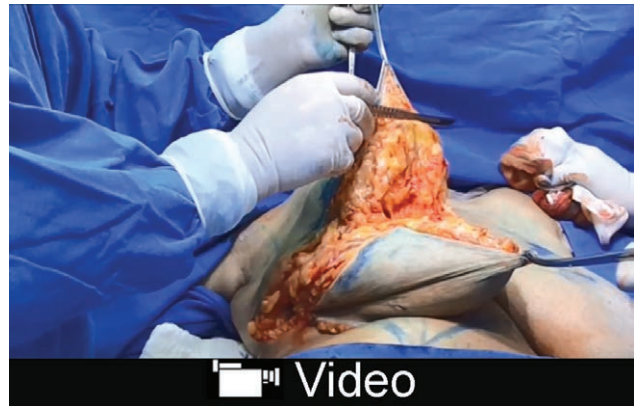

Fig. 6. The NAC is positioned at the apex of the breast along the branch of the triangle that starts at the umbilicus. In general, the distance from P1 to the inferior border of the areola is the same $(P1 \rightarrow m) - 1\text{cm}$. The reduction of -1cm is to compensate for the action of gravity that will have an effect over time. At the end of the procedure, relationship of upper pole/lower pole must be 55/45.



Video Graphic 1. See video, Supplemental Digital Content 1, which demonstrates the divine proportion concept in planning the vertical and horizontal resection, the steps of multiplanar convergent assembling, the ideal NAC positioning in a 64-year-old patient presenting intermediated body type and large breast reduction. This video is available in the “Related Videos” section of the Full-Text article on PRSGlobalOpen.com or available at <http://links.lww.com/PRSGO/A991>.

RESULTS

Two hundred twenty-one patients in our data scored a good result (83%). A desirable breast outcome was achieved in most of the cases of breast reduction and mastopexy. Centripetal mobilization of breast tissue to point P1 reduced axillary laxity contributing to upper pole projection. Good scarring was noticed overall at the submammary fold. Complications were few but include delayed healing at the inverted T scar confluence in 19 patients (7%), asymmetry in 16 (6%), and partial nipple necrosis in 4 (1.5%). The method allowed for a transposed superior border of the areola attached to the upper pedicle to P2, the apex of the cone breast cone, even in large breasts with a distance from the SN to NAC of approximately $\geq 30\text{cm}$.

In a few cases, complications such as asymmetry, partial nipple necrosis, and delayed healing scored at the lower limit of Strasser grading system, that is, scores 5–14, which is considered mediocre. All of these complications occurred in patients presenting with large breasts.

DISCUSSION

Current mammoplasty approaches use pinch test, prefabricated molds, and even complex empirical markings to plan the new breast. This study evokes the mathematical principle of the divine proportion to construct a balanced breast (Fig. 7). With this method, point P2 is vertically positioned at the distance of P1 to the point m—the intersection with the midsternal line—times the constant phi, 1.618. Horizontally, the distance is the same from P2 to m' which orients the ideal point of the superior border of the NAC when measured with a compass from P1. This distance is the same as P2 to m'. This mathematical proportion shows that P2 is also situated at the longitudinal line coincident with a point between the distal third and medial two thirds of the distance between the anterior ax-

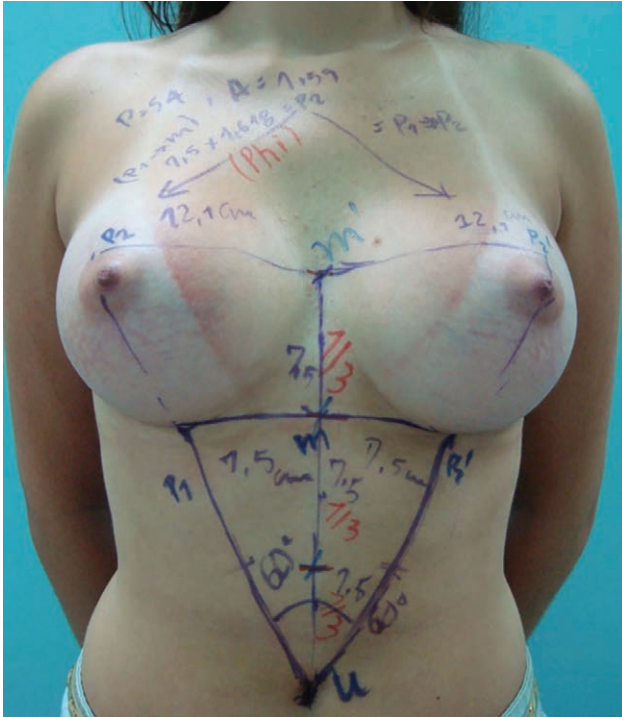


Fig. 7. A 19-year-old woman with an attractive breast, weight of 54 kg and height of 1.59 m, presenting an intermediate body type and circular cone base. The divine proportion is noticeable when the mammary structure is reconfigured to a 60° V-shaped triangle with 1 vertex at the umbilicus (point u) and each isosceles branch opening to the articulation between the acromioclavicular articulation. In the figure, P1→m = 7.5 cm. P2, the superior border of the NAC is positioned at the distance: (P1→m) × constant phi (1.618). If the distance P1→m is 7.5 cm, P1→P2 = 7.5 × phi = 12.1 cm = m'→P2.

illary anterior line and the presternal midline. The new mammary cone is planned taking into consideration the submammary fold, a constant structure that is the foundation to built the new breast and must be determined with the patient in an upright standing position. The method

also employs another objective parameter: the triangle with the vertex, point u, situated at the umbilicus. Each branch opens in the direction of the acromioclavicular articulation parallel to the anatomical mammary line. P1, the key point, is situated at the intersection of the submammary fold line and each branch of the V-shaped triangle. Each axis of the branch of this isosceles triangle orients the creation of the new breast. An intrinsic proportion between the 2 geometric figures exists: the triangle with an almost 60° vertex at the umbilicus and the cone of the breast.

The geometric explanation shows that the divine proportion can be detected from a mathematical point of view in the ideal breast as we seen in a breast augmentation. All of this theory can be simplified by considering geometric parameters according to body types. As point out by Del Yerro,²¹ the breast must maintain a harmonious proportion within the body that frames it. Usually, in a thin body corresponding to the asthenic or ectomorphic body type, the normal distance from P1 to m is 6.5–7 cm (Fig. 8). The shape of the base of the breast cone is more oval with a larger vertical axis. In the thick, muscled body with broad shoulders patients, the distance from P1 to m is usually 8–9 cm, the cone base that tends to be of an oval shape with large horizontal axis. Considering the horizontal shape of the mammary cone, the distance of P2 to m' can be a multiplication of the distance P1 to m × phi (1.618). However, the distance of P1 to P2 (the apex of the breast cone) along the acromioclavicular joint to the umbilical line is the result multiplying the distance P1 until m subtracted 1 or 2 cm less × phi. In these cases, the breast horizontal axis is larger than the vertical one (Fig. 9). Between these 2 types is the intermediate type, the most prevalent in our investigation, in which the P1 to m average distance is 7–7.5 cm and the cone base is circular. In these body types, the correlation of P1 to P2 and P2 to m' is usually equal to P1 to m × phi (Fig. 10). We have to consider that the anatomical NAC positioning is divergent because of curved rib arches (Fig. 11).

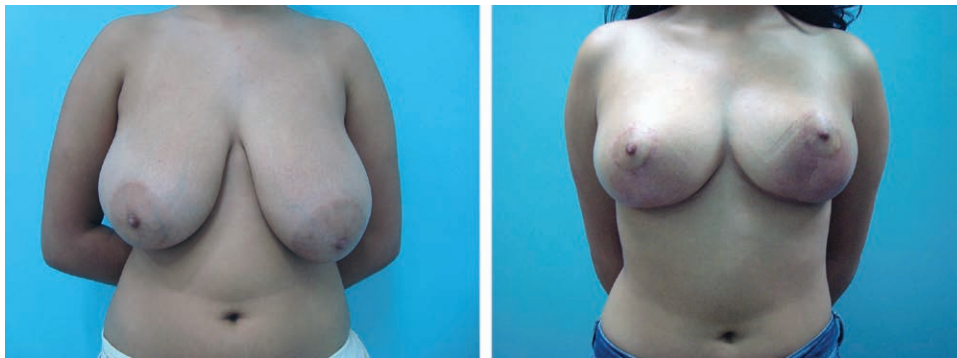


Fig. 8. Pre- and postoperative view of a 16-year-old female patient presenting ectodermic (thin) body type (Y ratio = 3.7). The height and width of the torso in the area of the breast submammary fold were used to determine the TP (71 cm) which was divided by the SN and the projected site of the new positioning of the NAC distance (19 cm). This patient scored 3 based on Strasser classification, that is, malposition = 1, distortion = 0, asymmetry = 2, contour deformity = 0, and scar = 1. TP indicates thoracic perimeter.

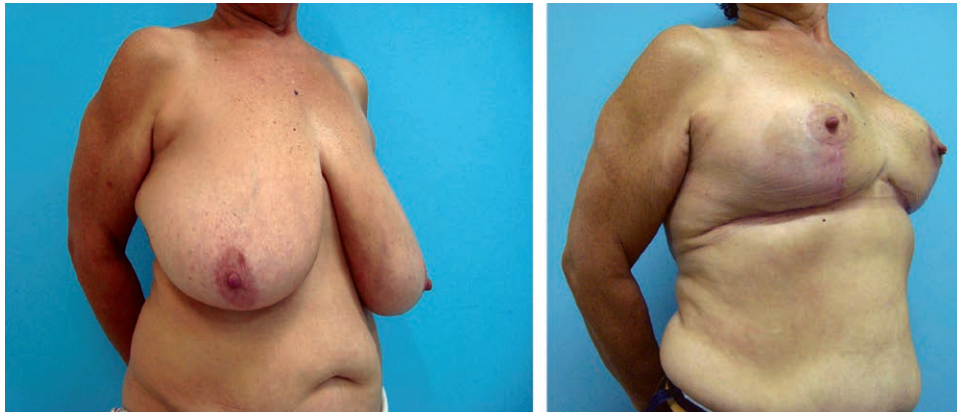


Fig. 9. A 58-year-old patient presenting endomorphic (thick) body type with $Y = 4.3$, grade 3 hypertrophic breast, and important ptosis. This case scored 3 according to Strasser classification. See NAC rotation proportioned by multiplanar-layered assembly (compare the black nevus position on the right breast at the upper pole before and after surgery).

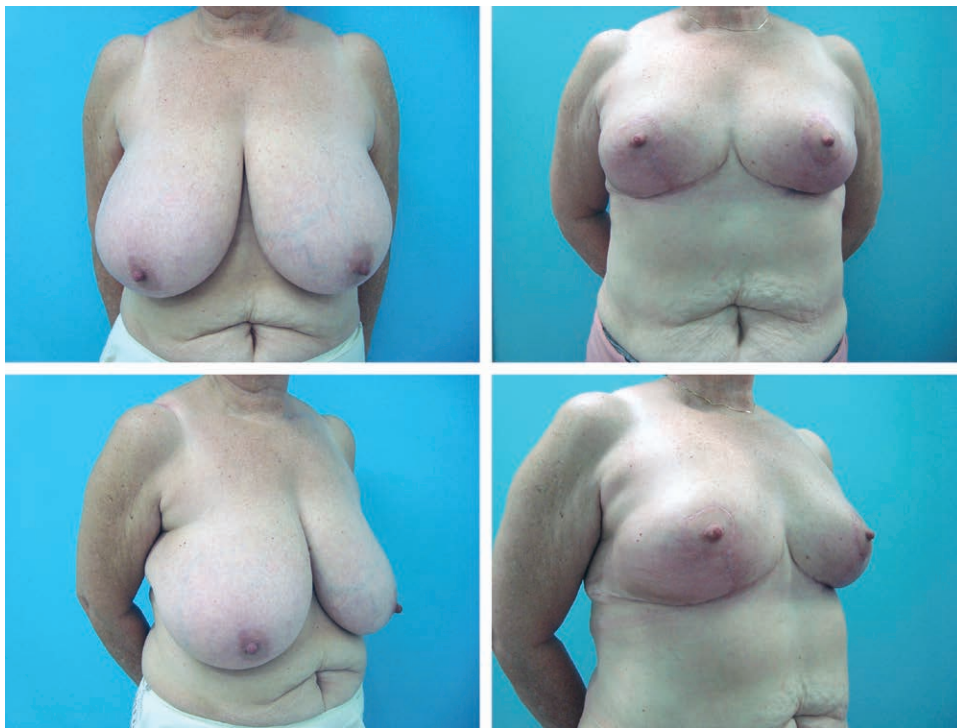

Fig. 10. One-year follow-up of a 62-year-old patient presenting intermediate body type ($Y = 39$) after resection of >1 kg from each side. She was classified as 2 in Strasser grade, that is, malposition = 0, distortion = 0, asymmetry = 0, contour deformity = 1, and scar = 1. See the improvement at the axillary region, the rotation of the NAC, and the maintenance of upper pole projection as a result of multiplanar convergent centripetal assembly of the breast lateral and medial quadrants.

An anatomic evaluation of body types (Y) can be calculated by dividing the thoracic perimeter at the level of the inframammary fold by the distance from the SN to the NAC (SN→NAC). In breast reduction and ptosis, the distance SN→NAC is the expected new positioning of the NAC. The result (Y) = thoracic perimeter / (SN→NAC) is indicated by the ratio of the height and width of the torso in the area of the breast in an objective and quantifiable manner, the body type, and the breast base. When Y is >4.3 , the body

type is pyknic and corresponds to women who are broader than they are tall. When Y value is <3.7 , the body type is asthenic (thin) with a longer vertical line. Patients between these 2 values have an intermediate body type, that is, the Y value is close to 4 (between 3.8 and 4.2) (Table 1).

In this way, we add precision to cone apex positioning. In contrast to many current techniques that use only the pinch test to plan the NAC topography, Wise⁷ utilized prefabricated molds with their apex at a constant distance

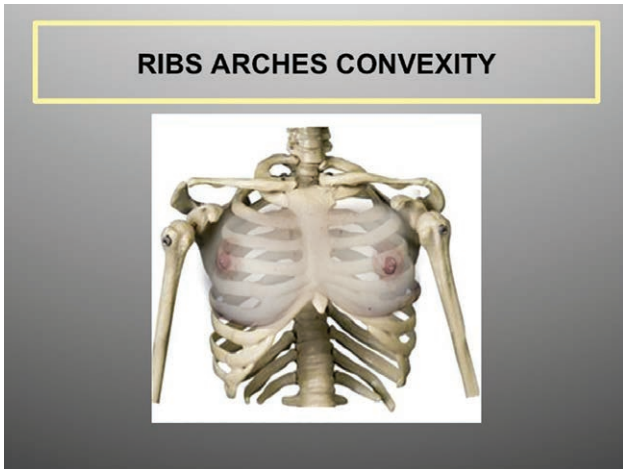


Fig. 11. Schematic drawing showing the divergence of the breast cone and the NAC because of the convexity of the costal arches of the ribs. The vertical meridian of the NAC has to be positioned under a descendent line that runs from the lateral one third with the medial two third of the distance between the axillary crease and the presternal midline.

from the SN to the areola border. Pitanguy²² imagined the superior border of the areola by feeling the projection of finger over the upper pole after touching the meridian of the breast integument inferiorly at the submammary fold. Tebbetts²³ considers the half size of the submammary fold to project NAC and to evaluate the vertical and horizontal excess to be resected. Many authors situated the superior border of the NAC at an empirical distance of 18–21 cm from the clavicle midpoint. These strategies show the challenging difficulties of adding mathematical precision according to different body types.

By determining P2, planned topography of superior border of NAC positioning, horizontal resection can be measured objectively. With an upward traction at this point and breast tissue hanging under gravitational force (constant, 9.8 m/s²), horizontal resection can be measured objectively. This ideal horizontal resection from P2 is approximately under the limit of the distance from P1 to $m \times \phi$.

Table 1. Distance of P1 to m, P1 to P2, and P2 to m' Related to Different Body Types and the Constant Phi (1.618) and Prevalence in the Study in Percentage (%)

Body Type	Distance (cm)			%
	P1 → m	(P1 → P2) × phi	(P2 → m) × phi	
Ectomorphic	6.5–7	10.5–11.3	10.5–11.3	15%
Intermediate	7–7.5	11.3–12.1	11.3–12.1	54%
Endomorphic	8–9	12.9–14.5 (-1–2 cm)	12.9–14.5	31%

It is the result of the TP divided by the SN and the projected new positioning of the NAC distance: $Y = TP / (SN \rightarrow NAC)$. In the ectomorphic (thin) body type ($Y < 3.7$), intermediate (Y between 3.8 and 4.2), and in the endomorphic (thick) ($Y > 4.3$).

m, intersection point of the midsternal line with a straight line running from the P1; m', same distance of P1 to m transposed cranially over the midsternal line; P1, intersection point between the sub-mammary fold and the acromioclavicular joint to umbilicus line; P2, expected position of the superior areolar border along the acromioclavicular line to the umbilicus; TP, thoracic perimeter; Y, ratio of height and width of the torso in the area of the breast; % patients, percentage of body type group prevalence in the study.

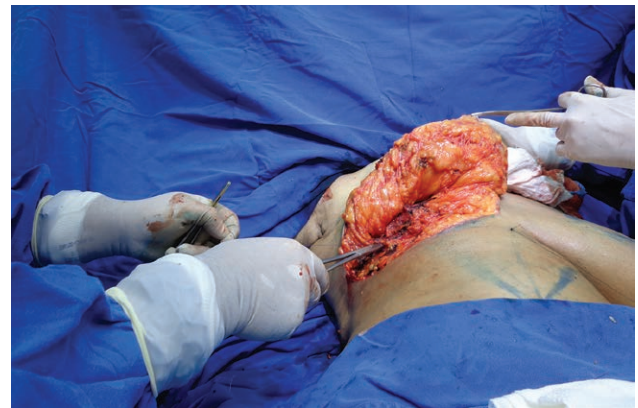

Fig. 12. Breast assembly with multiplanar layers starting inside out with multiple adhesion stitches approximating the breast tissue and the pectoralis major muscle.

The centripetal assembly with multiple adhesion sutures performed by rotating the lateral and medial breast quadrants to P1 (the point of the intersection of the branch of the triangle and submammary fold) creates the breast cone inside out. The inner part of the tissue is sutured to the muscle fascia of the serratus muscle laterally and the pectoralis major muscle medially (Fig. 12). The second suture layer connects the breast tissue deeply to the fascia of Scarpa along the line of the submammary fold. This layer is very strong (Fig. 13) and contributes to medial rotation, and minimizes scar tension and dead space. This maneuver mobilizes the mammary tissue to the upper pole presenting an effect similar to a mammary prosthesis at the end of the procedure. This approach diverges from the breast tissue assembly as most mammoplasty techniques do. Basically, current techniques suture the points B and C referring to the remaining breast integument border after resection of the hypertrophy or mastopexy. The method expands the single suture to rotate the lateral mammary quadrant to the second rib arch indicated by some authors.²⁴

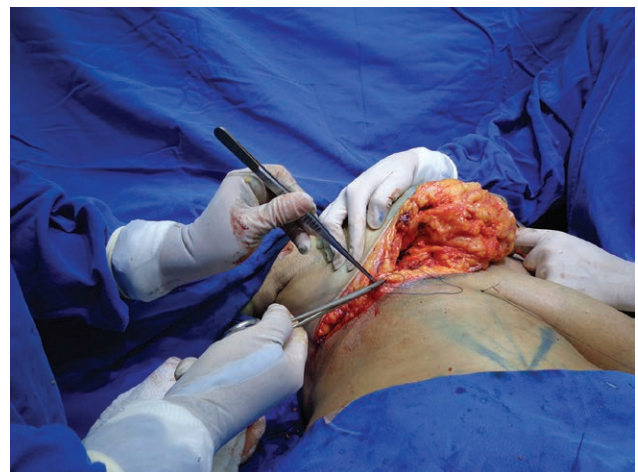
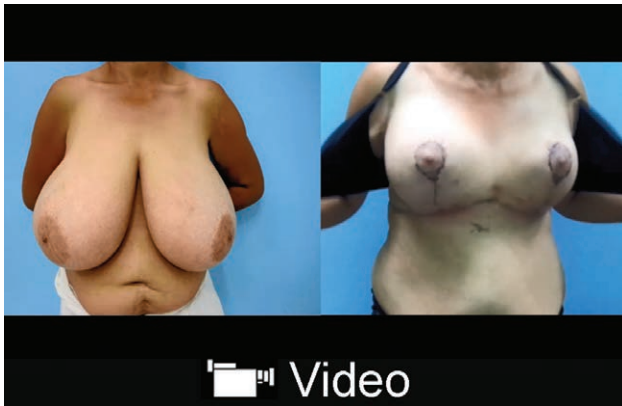
Fig. 13. Multiple sutures between the breast's remaining border and the Scarpa's fascia comprise the strongest layer. This helps to give projection to the upper pole and minimizes axillary flaccidity.



Video Graphic 2. See video, Supplemental Digital Content 2, which displays a dynamic view of 4 patients submitted to large breast reduction with upper pedicle presenting intermediate and thick body types with suprasternal notch and nipple–areolar complex distance ≥ 30 cm. This video is available in the “Related Videos” section of the Full-Text article on PRSGlobalOpen.com or available at <http://links.lww.com/PRSGO/A992>.

The convergent assembly helps to elevate the NAC attached to the upper pedicle, one of the most challenging tasks in larger hypertrophy associated with ptosis (see **Video 2, Supplemental Digital Content 2**, which displays a dynamic view of 4 patients submitted to large breast reduction with upper pedicle presenting intermediate and thick body types with SN and NAC distance ≥ 30 cm. This video is available in the “Related Videos” section of the Full-Text article on PRSGlobalOpen.com or available at <http://links.lww.com/PRSGO/A900>). It does the same intent as techniques used for severe breast hypertrophy or ptosis that either require medial pedicle rotation^{25,26} or use the areola attached to an inferior pedicle.²⁷ This method also helps to avoid amputation and the free graft of the NAC used in large breasts as proposed by Thorek.^{28,29} As we highlight above in the technique, the Shwartzmann maneuver is facilitated using tumescent infiltration between the epidermal and dermal layer with saline solution without epinephrine. If necessary, the dermis around the NAC can be incised to help its transposition at P2. Lipoplasty under the areola and the upper pole eases NAC repositioning overall in large fat breast.

The centripetal rotation of the breast lateral and medial quadrants to P1 minimizes the axillary laxity, contributes to the transposition of the NAC, and adds volume to the upper pole. In this way, it works as an “autologous” implant at the end of the procedure (Fig. 14).

To achieve this objective, many contributions have been made to give long-term upper pole projection and prevent early breast ptosis. Inferior pedicle rotation to the upper pole is one of the most popular strategies,^{30–34} although other techniques link the inferior pedicle with a pectoral muscle belt.^{35,36} In the past, we supported the superior pedicle under the inferior third of the pectoralis major muscle, which works as a pocket.³⁷ Later, we proposed total coverage of the inferior pedicle by the pectoralis major muscle, which functions as a biological implant. Because of oncologic considerations, we have

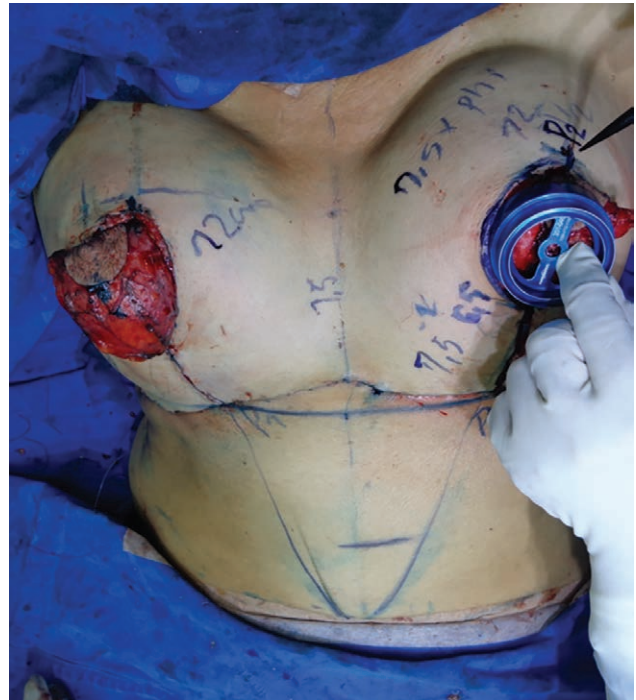

Fig. 14. The multiplanar-layered assembly rotates the breast's lateral and medial quadrants medially toward point P1, the union between the submammary fold and the branch of the almost 60° triangle. This contributes to NAC elevation and gives fullness to the upper pole. The mammary cone is built over the branches of the almost 60° triangle that starts from the umbilicus in direction of the acromioclavicular joint. The inferior border of the NAC is positioned at the distance between (P1→m)–1 cm, owing to the gravitational force. In this case, it was 7.5 – 1 cm = 6.5 cm. At the end of the surgery, the relationship of the upper pole/lower pole was approximately around 55/45.

stopped using that variation. Swanson³⁸ investigated almost 100 mammoplasty reduction techniques using photometric analysis and concluded that it is very difficult to maintain long-term upper pole fullness. He indicates implant to achieve upper pole fullness and inferior convexity associated with mastopexy.³⁹ A small implant of 200 cm³ or less may be associated with mastopexy in cases that the final transoperative view the upper pole/lower pole relationship is inferior than 55/45, that is, 45/55 or 35/65. Replacing mammary tissue with prosthesis after partial integument resection has also gained popularity.⁴⁰ However, the presence of a synthetic product and its potential complications inside the breast must be considered. Additionally, it seems impractical to replace part of the mammary integument in women who may become pregnant, given the potential negative impact on breastfeeding. We prefer to preserve breast tissue under the NAC and resect tissue from the lateral quadrant to gain more projection under the upper pole. The strongest adhesion suture layer is made between the breast tissue and fascia of Scarpa. As we have point out, this approach rotates the medial and lateral quadrants to P1 giving bulk to the upper pole working as an autologous implant.⁴¹

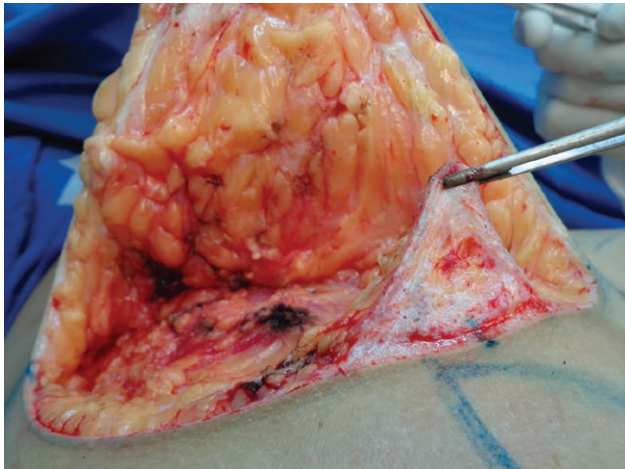


Fig. 15. A small triangle bridge of tissue with a base at P1 is preserved to minimize ulceration and delayed healing at the confluence of the vertical and horizontal scars.

The almost 60° V-shaped figure orients the vertical resection and the positioning of the NAC working as a vanishing point. Usually, the inferior border of the areola is situated at 6.5–7.5 cm from P1 in an intermediate body type, which follows the golden ratio, the distance between P1 and P2/phi. Taking into consideration the action of gravity that contributes to natural mammary ptosis, we deducted 1 cm from that measurement. Pursuing the ideal breast, the mammary shape ends at the transoperative view in a proportion of 55/45 (upper pole/lower pole). The gravitational force acting on the mammary tissue changes that proportion to 45/55, which is considered more attractive as shown in the study by Mallucci and Brandford.⁴² According to Franciosi,⁴³ the vertical meridian of the NAC has to be situated over

a line that runs downward from the point between the lateral one third and the medial two third of the distance between the axillary crease and the presternal midline. The geometric positioning of P2 according to our investigation corroborates that analysis. It considers also the body type and the interference in the new breast planning as abducted patient arms and cranial natural excursion of the mammary tissue during the procedure with the patient in the supine position.

Complications in our study were few, but included delayed healing at the inverted T confluence in 19 patients (7%), asymmetry in 16 (6%), and partial nipple necrosis in 4 (1.5%). In the few cases of asymmetry, partial nipple necrosis and delayed healing scored at the lower limit of the Strasser grading system, that is, 5–14, which is considered mediocre. All of these complications were present in patients presenting significant ptosis, with an SN to NAC distance near or >30 cm and with relevant hypertrophy with approximately 1,000 g of tissue resected from each breast.

After creation of the skin envelope, the scar usually ends in an inverted T. This can be end to an L shape if the distance between the medial limit of the breast to be resected, point C (the medial corner of the new breast cone after resection), and the submammary fold, P1, is <2 cm. It is easier to ensure accuracy with this strategy than with the current “L” scar mammoplasty approaches.^{44–46}

Precision in mammoplasty remains a challenging subject. The method we proposed defines quantified parameters for nipple positioning, and vertical and horizontal skin resection that take into a consideration more than the breast width.⁴⁷ Bozola et al⁴⁸ advocated the concept of the golden ratio to plan implant design preferences. Our investigation defines comprehensive process guided by the universal principle of the divine proportion. In the

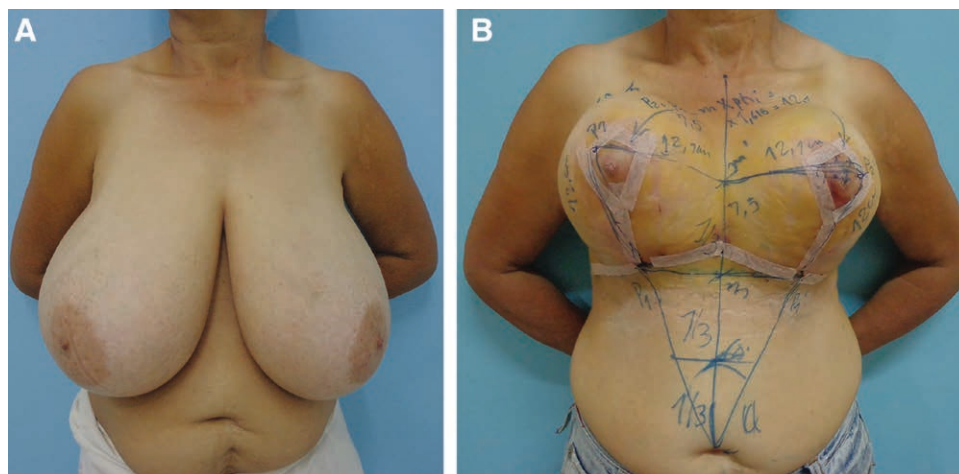


Fig. 16. Divine proportion seen after large breast reduction associated with multiplanar assembly. A, Preoperative view of a 64-year-old patient presenting with significant breast hypertrophy. B, One week later after resection of 975 g from the right side, resection of 1,035 from the left side, and breast lipoplasty of 950 ml in volume. The distance from P1 to m was 7.5 cm. $P1 \rightarrow P2 = (P1 \rightarrow m) \times \text{phi} = 7.5 \times 1.618 = 12.1$ cm. This patient presented an intermediate body type (Y ratio = 3.9). The divine proportion can be seen between the distance P1 to m (7.5) and P1 to P2 = $[7.5 \times \text{phi} (1.618) = 12.1$ cm]. Note the upper pole projection as a result of the multiplanar centripetal convergent assembling and the high transposition of the NAC.

multilayer assembly process, the breast cone is sculpted inside out and is oriented by objective parameters. This technique preserves more tissue under the NAC and emphasizes tissue resection at lateral quadrant, more susceptible to tumors formation. This approach also contributes to the upper pole projection using autologous tissue, reduces axillary laxity, and minimizes dead space. The complication rates were low. To minimize the most prevalent complication, that is, delayed healing at the union of the vertical and horizontal scar, we preserve a small triangle of tissue without the dermis (Fig. 15). This represents another solution to the problems addressed in other strategies.^{50,51} Therefore, the approach proposed can be considered part of plastic surgeon's armamentarium in conjunction or association with other methods described in mammoplasty (Fig. 16).

CONCLUSIONS

Mammoplasty via the convergent assembly of multiple layers planned according to the golden ratio adds precision to vertical and horizontal resection in breast reduction. The method is based on constant parameters, such as the submammary fold, and the V-shaped triangle with a vertex at the umbilicus with each branch oriented to the acromioclavicular articulation. The convergent assembly with multiple layers using progressive multiple retention sutures reduces the laxity at the axillary region, adds bulk to the upper pole, eases NAC elevation, contributes to a lower tension scar, and minimizes dead space.⁴⁹ Furthermore, a low rate of complications was recorded. Therefore, this technique should be considered as part of the arsenal of approaches indicated to correct mammoplasty.

Oswaldo João Pereira Filho

Clinica Jane - Hospital Ilha - UFSC
Florianópolis, Santa Catarina, Brazil
E-mail: osvaldojpf@gmail.com

REFERENCES

- Ariê G. Nova técnica em mamoplastia. *Ver Lat Amer Cir Plast*. 1957;3:28.
- Avelar J. *Mamoplastia. Conduta Pessoal Simetria e Funcional Anais XXXI Congresso SBCP, Belo Horizonte, out.* Sao Paulo, Brazil: SBCP; 1994.
- Erol O, Spira M. A mastopexy technique for mild to moderate ptosis. *Plast Reconstr Surg*. 1980;65:603-609.
- Franco T, Rebelo C. *Cirurgia Estética*. Rio de Janeiro, Brazil: Livraria Atheneu; 1977.
- Geogiade NG, Serafin D, Reifkohl R, et al. Is there a reduction mammoplasty for "all seasons?" *Plast Reconstr Surg*. 1979;63:765.
- Corine W, Megan V, Rohrich R. Mammoplasty pedicles and skin resection pattern. *Plast Reconstr Surg Glob Open*. 2014;2:e202.
- Wise RJ. A preliminary report on a method of planning the mammoplasty. *Plast Reconstr Surg*. 1956;7:367-375.
- Ribeiro L. Redução mamária. *Cirurgia Plástica da Mama*. Rio de Janeiro: Medsi; 1989.
- Peixoto G. Reduction mammoplasty: a personal technique. *Plast Reconstr Surg*. 1980;65:217-225.
- Perez-Macias JM. Personal mastopexy technique for breast stabilization: update. *Br J Plast Surg*. 2004;7:178.
- Pitanguy I, Torres E, Salgado F, et al. Breast pathology and reduction mammoplasty. *Plast Reconstr Surg*. 2005;115:729-734.
- Nahabedian MY, McGibbon BM, Manson PN. Medial pedicle reduction mammoplasty for severe mammary hypertrophy. *Plast Reconstr Surg*. 2000;105:896-904.
- Hugo NE, McClellan RM. Reduction mammoplasty with a single superiorly-based pedicle. *Plast Reconstr Surg*. 1979;63:230-234.
- Hoopes JE, Maxwell GP. Reduction mammoplasty: a technique to achieve the conical breast. *Ann Plast Surg*. 1979;3:106-113.
- Huntley HE. *The Divine Proportion - A Study in Mathematical Beauty, Aesthetic Claim*. New York, NY: Dover Publications; 1970.
- Hemenway P. *Divine Proportion Ø (Phi) in Art, Nature, and Science*. New York, London: Sterling; 2005.
- Theodore AC. *The Curves of Life*. New York, NY: Dover Publications; 1914:465-466.
- Muntan CD, Sundine MJ, Rink RD, et al. Inframammary fold: a histologic reappraisal. *Plast Reconstr Surg*. 2000;105:549-556.
- Auersvald A. Lipomamoplastia. Paper presented at: 30a. Jornada Sul-brasileira de Cirurgia Plástica; April, 2014; Gramado, RS, Brazil.
- Strasser EJ. An objective system for the evaluation of cosmetic surgical results. *Plast Reconstr Surg*. 1999;104:2282.
- Del Yerro JLM. *Anatomic Cohesive Gel Implants: Reshaping the Breast in Different Body Types. Innovations in Plastic Surgery*. St Louis: Quality Medical Publishing; 2007:15-36.
- Pitanguy I. *Breast Hypertrophy. Transactions of International Society of Plastic Surgeons, 2nd Cong*. London: E&S. Livingstone Ltd, Edinburgh; 1959.
- Tebbetts JB. A process for quantifying aesthetic and functional breast surgery: I. Quantifying optimal nipple position and vertical and horizontal skin excess for mastopexy and breast. *Plast Reconstr Surg*. 2014;133:421e-422e.
- Uebel CO. In: *Abdominoplastia e mastopexia. Contorno Corporal e Lipoaspiração*. Elsevier; 2013:75-83.
- Naufal RR, Pinheiro AS, Maciel PJ, et al. Impacto da mamoplastia redutora com técnica do pedículo medial na redução dos sintomas dolorosos em pacientes com gigantomastia. *Rev Bras Cir Plást*. 2010;25(3 Suppl 1):55.
- Finger RE, Vasquez B, Drew S, et al. Superomedial pedicle technique of reduction mammoplasty. *Plast Reconstr Surg*. 1989;83:471-478.
- Ariyan S. Reduction mammoplasty with the nipple-areola on a single, narrow, inferior pedicle. *Ann Plast Surg*. 1980;5:167-177.
- Thorek M. Plastic reconstruction of the breast and free transplantation of the nipple. *J Intern Coll Surg*. 1946;9:194.
- Casas L, Byun MY, Depoli PA. Maximizing breast projection after free-nipple-graft reduction mammoplasty. *Plast Reconstr Surg*. 2001;107:955-960.
- Ribeiro L. *Pedículos Em Mamoplastia. Atlas e Texto*. Rio de Janeiro, Brazil: Guanabara Koogan; 2005.
- Ribeiro L. A new technique for reduction mammoplasty. *Plast Reconstr Surg*. 1975;55:330-334.
- Castro CC. Redução mamária pela técnica do retalho dermoadi-posito de pedículo inferior. *Rev Bras Cir*. 1983;73:47.
- Hall-Findlay EJ. Pedicles in vertical breast reduction and mastopexy. *Clin Plast Surg*. 2002;29:379-391.
- Caldeira AML, Lucas A, Grigalek G. Mastoplasty: the triple-flap interposition technique. *Aesthetic Plast Surg*. 1999;23:51-60.
- Daniel MJ. Mamoplastia com retalho de Músculo Peitoral. *Arq Catarinense de Medicina*. 1994;23:121-122.
- Graf R, de Araujo LRR, Rippel R, et al. Reduction mammoplasty and mastopexy using the vertical scar and thoracic wall flap technique. *Aesthetic Plast Surg*. 2003;27:6-12.
- Pereira Filho OJ. Dynamic muscular support for mammoplasty. Paper presented at: Transactions of the 11th Congress of the International Confederation; 1995:397-398; Yokohama, Japan.
- Swanson E. A retrospective photometric study of 82 published reports of mastopexy and breast reduction. *Plast Reconstr Surg*. 2011;128:1282-1301.

39. Swanson E. Ideal breast shape: women prefer convexity and upper pole fullness. *Plast Reconstr Surg.* 2015;135:641e–643e.
40. Saldanha O, et al. Mamoplastia redutora com implante de silicone. *Rev Bras Cir Plás.* 2010;25:317–324.
41. Pereira O, Bins-Ely J, Paulo E. A retrospective photometric study of 82 published reports of mastopexy and breast reduction. *Plast Reconstr Surg.* 2012;130:890e–891e.
42. Mallucci P, Brandford OA. Population analysis of the perfect breast. A morphometric analysis. *Plast Reconstr Surg.* 2014;134:436–447.
43. Franciosi LF. Harmonia e beleza. *31a. Jornada Sul-Brasileira de Cirurgia Plástica.* 2015.
44. Dufourmentel L, Mouly R. Plastie mammaire pour le méthode oblique. *Ann Chir Plast.* 1961;6:47.
45. Chiari Júnior A. The L short-scar mammoplasty. *Clin Plast Surg.* 2002;29:401–409.
46. Bozzola A, et al. *Mamoplastia em L.* Porto Alegre, Brazil: Rev. AMRIGS; 1982;26:207.
47. Tebbets JB. A process for quantifying aesthetic and functional breast surgery: I. Quantifying optimal nipple position and vertical and horizontal skin excess for mastopexy and breast reduction. *Plast Reconstr Surg.* 2013;132:1040.
48. Bozola AR, Longato FM, Bozola AP. Análise geométrica da forma da beleza da mama e da forma da prótese na proporção phi: aplicação prática. *Rev Bras Cir Plást.* 2011;26:94–103.
49. Pereira Filho OJ, Bins Ely J, Lee KH. Mamoplastia orientada pela proporção áurea(phi) associada à rafia interna com suturas progressivas. *Rev Bras Cir Plást.* 2012;27(3 Suppl 1):54.
50. Mahajan AL, Chapmann TW, McDiarmid J. Preventing “T” junction dehiscence in mammoplasty. *Plast Reconstr Surg.* 2006;117:2100.
51. Hoeflin SM. Using skin dart to improve breast reduction and mastopexy scars. *Plast Reconstr Surg.* 1992;89:996.