



## Patient specific implants in orbital reconstruction: A pilot study<sup>☆</sup>

Larissa A. Habib<sup>a</sup>, Michael K. Yoon<sup>b,c,\*</sup>

<sup>a</sup> Department of Ophthalmology, Yale School of Medicine, New Haven, CT, USA

<sup>b</sup> Ophthalmic Plastic Surgery, Massachusetts Eye and Ear Infirmary, Boston, MA, USA

<sup>c</sup> Department of Ophthalmology, Harvard Medical School, Boston, MA, USA

### ARTICLE INFO

#### Keywords:

Patient specific implant  
Orbital reconstruction  
Silent sinus syndrome  
Orbit fracture

### ABSTRACT

**Purpose:** Successful repair of the orbital skeleton restores function and cosmesis by normalizing globe position and allowing full motility of the extraocular muscles. Routine repairs are successful with standard implants. However, defects that are irregular or cause volume deficiency can be challenging to repair. The development of patient specific implants (PSI) offers an additional tool in complex cases. Herein, we report our experience using PSI for orbital reconstruction.

**Methods:** An IRB-approved review was conducted of consecutive patients who received PSI from 8/2016–9/2018. Demographic and examination findings were recorded. PSI was designed using high-density porous polyethylene or polyetheretherketone (PEEK) and implanted for repair. The postoperative course was reviewed for outcomes and complications.

**Results:** Eight patients were identified. Two had silent sinus syndrome, 3 were complex facial fracture revisions, and 3 were post-oncologic reconstruction. Seven received porous polyethylene implants, and 1 had a PEEK implant. Mean follow up time was 10.2 months (3.3–28.3). All had an improved functional and aesthetic result. Diplopia and enophthalmos completely resolved in 60% of fracture and silent sinus patients. All fracture and silent sinus patients were orthotropic without diplopia in primary gaze at last follow up. Tumor patients had improvement in symmetry and functionality. There were no complications.

**Conclusion and importance:** Complex orbital skeleton derangements can be difficult to repair and standard implants may incompletely resolve the anatomic problem. In challenging cases, PSI may better achieve an aesthetically and anatomically successful outcome and improve functionality.

### 1. Introduction

A “custom orbital implant” is an imprecise term that comprises a heterogenous number of materials and methods to fashion an implant that is made for an individual. With that moniker, all implants are technically “customized” since they are trimmed intraoperatively and shaped for one patient. Several similar terms are frequently used in the literature which do not specify an exact technique: “3D”, “digital”, “3D printing”, “pre-shaped”. Some of these are simply trimmed prior to surgery on a model, while others use a mold to press a sheet intraoperatively, while others used hot water baths intraoperatively to shape an implant.<sup>1–3</sup> The newest generation of these implants are custom manufactured using CT scans to mirror image the normal side (if there is one) to the abnormal side and create an implant to eliminate that difference. These have been termed “patient specific implants”, or PSI.

The evolution of implants or grafts used in the orbit has evolved from allografts of bone or cartilage (which are of irregular shape and/or volume) to alloplastic materials (e.g. porous polyethylene or titanium) that are uniform but largely flat. For use in the orbit, these flat implants have been widely used for decades with success, particularly in patients with isolated single wall fractures where a thin sheet is desirable to prevent globe dystopia.

However, in some cases, flat implants are not desirable, particularly when there is an irregular shape missing (e.g. a missing inferior orbital rim), or if an orbital wall is sunken down and a flat implant across it would create a “dead space” (e.g. silent sinus syndrome). Previously, this has been treated by hand bending a sheet or using multiple stacked implants. This has its own challenges, since the fit will be variable, the process can be time consuming, and the results inconsistent.<sup>4–8</sup>

With improved imaging technology and machinery, the ability to

<sup>☆</sup> Presented at American Society of Ophthalmic Plastic and Reconstructive Surgery Fall Symposium. October 26, 2018.

\* Corresponding author. 243 Charles Street, Boston, MA, 02114, USA.

E-mail address: [Michael.yoon@meei.harvard.edu](mailto:Michael.yoon@meei.harvard.edu) (M.K. Yoon).

create implants that are personalized to each patient and defect has been developed. PSIs are now being employed in a variety of surgical subspecialties and anatomic locations. Recent success has been noted in orbital reconstruction as well.<sup>9</sup> Several materials have been used to create these implants include titanium, methylmethacrylate, hydroxyapatite, porous polyethylene, and polyetheretherketone (PEEK).<sup>8-12</sup> Herein, we report our experience with this emerging technology in orbital reconstruction.

## 2. Materials and methods

This is an IRB approved retrospective review of all consecutive patients who received a patient specific implant by a single surgeon from 8/2016–9/2018. This study adhered to the tenets of the Declaration of Helsinki and was compliant with HIPAA regulations. Consent for use of photographs and imaging was obtained from patients included in study. The preoperative clinical data, including demographics, ophthalmic examination, globe position, and the presence of diplopia, was reviewed. Each patient underwent a CT with fine cuts (1.25 mm). The PSI was then designed with either porous polyethylene (Poriferous, Newnan, GA, USA) or with polyetheretherketone (PEEK) (Synthes, West Chester, PA, USA) based on this scan. The choice of implant was dependent on the material used at the institution in which the surgery took place. In patients undergoing tumor excision, the PSI was designed preoperatively to correlate with the planned excision. A mockup image of the implant was sent to the surgeon for final review and modifications prior to production (Fig. 1). Intraoperative revision of the implant was done if necessary. Intraoperative navigation was not used in the described cases as there was adequate intraoperative visualization for proper placement. The postoperative course was then reviewed for outcomes including vision, globe and eyelid position, extraocular motility, and symptomatic diplopia. Post-operative scans were not performed after surgery for the purposes of implant evaluation, as this is not the standard of care in our community.

## 3. Case report/findings

Eight consecutive patients received PSI (7 porous polyethylene implant, 1 PEEK). The indications included silent sinus syndrome (2), complex fracture revision (3), and post-oncologic excision reconstruction (3). The mean follow-up was 10.2 months (3.3–28.3 months). A summary of patient characteristics can be seen in Table 1.

Patients 1 and 2 had a history of silent sinus syndrome and had persistent diplopia and asymmetry 1 year after functional endoscopic sinus surgery. The PSI was designed to replace the increased orbital volume from the descended orbital floor. Subject number two was, in fact, referred for and recommended to have strabismus surgery prior to presentation in the oculoplastics clinic. In both patients, a swinging eyelid approach was used as the implants were wider and thicker than typical implant sheets. The implant was placed subperiosteally against bare, stable bone. Both patients had complete resolution of their diplopia and normalization of globe position (Fig. 2).

Patients 3–5 had undergone orbital fracture repair at outside institutions and, due to their persistent symptoms, revision and placement of a PSI was recommended. Patient 3 had persistent diplopia, enophthalmos, and a flattened malar eminence that persisted 7 months after inadequate primary repair. Two separate and interfacing implants were designed. One was placed subperiosteally along the orbital floor, and the second was secured into position over the inferior orbital rim with a single screw (Fig. 3). His diplopia resolved weeks after surgery, except in far right gaze, which was functionally insignificant. Patient 4 had an orbital floor fracture which was inadequately reduced (by a non-ophthalmologist) with titanium implant that was in direct contact with the inferior rectus muscle causing diplopia in primary gaze even 6 months after surgery. The titanium implant was removed, and the PSI was placed subperiosteally along the floor. Enophthalmos and diplopia in primary gaze resolved after surgery though she did suffer from persistent diplopia in up and downgaze which was corrected with prism lenses. Patient 5 presented 12 years after revision of orbital floor fracture repair. His initial implant was removed and replaced a few months after initial surgery due to infection at an outside institution. He presented with long standing enophthalmos and diplopia. Intraoperatively, he was found to have stacked porous polyethylene implants from his previous surgery which were removed. The PSI was placed subperiosteally along the orbital floor. This resulted in complete resolution of diplopia and enophthalmos. The outcomes of the silent sinus and fracture patients are summarized in Table 2.

Patients 6–8 were tumor patients, each with unique tumors and defects, as well challenging orbital anatomy. Patient 6 had a history of right maxillary squamous cell carcinoma status-post subtotal maxillectomy with removal of the orbital floor, placement of a titanium implant, and adjuvant chemotherapy and radiation. Postoperatively, he developed hyperglobus and diplopia. At the time of delayed cheek reconstruction, the titanium implant was removed. The zygoma and

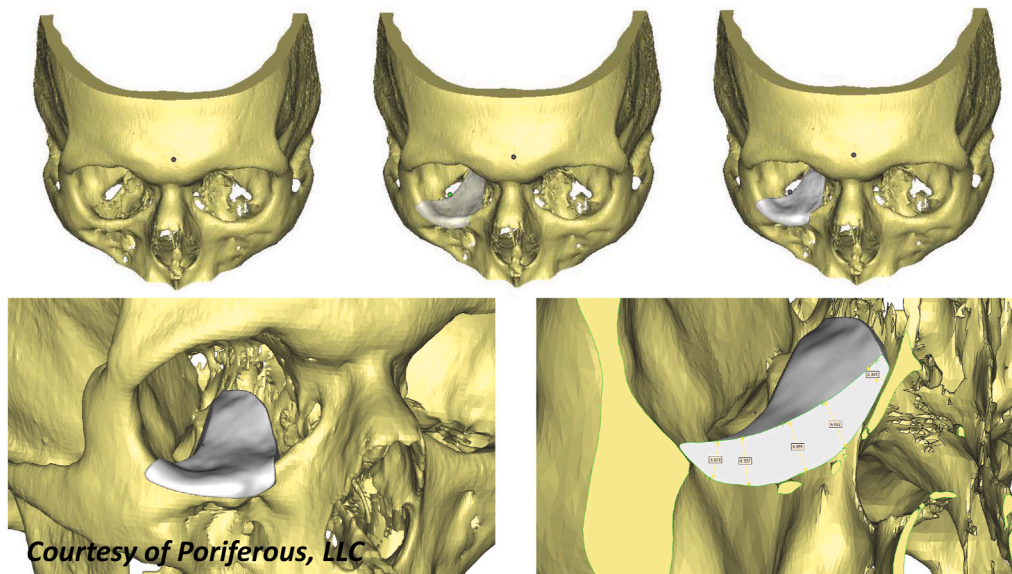
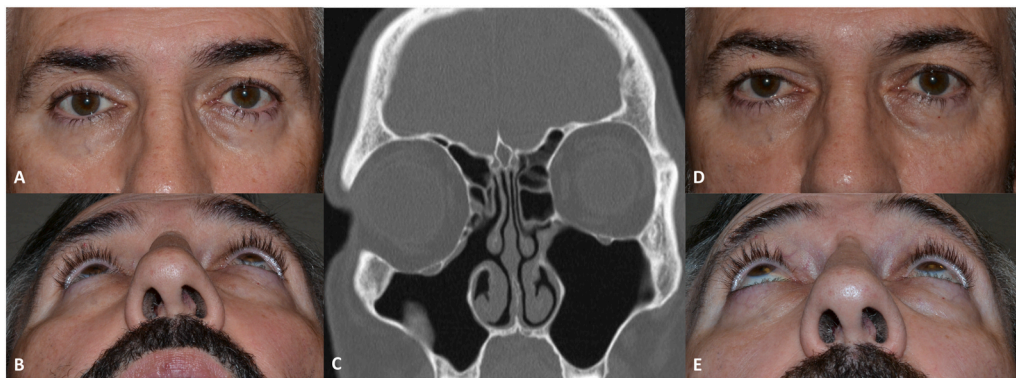


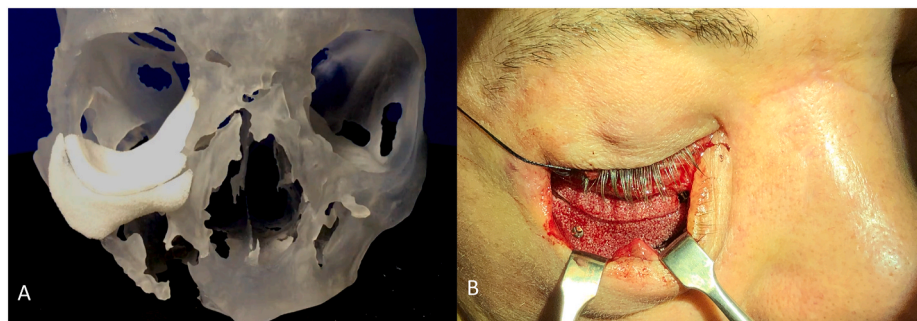
Fig. 1. Sample design of a right orbit implant for surgeon approval prior to manufacture.

**Table 1**  
Patient details.

Patient	Age Range	Sex	Diagnosis	Presentation	Location of Implant	Type of Implant	Follow Up (mths)
1	55–60	M	Silent sinus syndrome	Hypoglobus, enophthalmos, restriction in upgaze and abduction, diplopia	Orbital floor	Porous polyethylene	3.9
2	30–35	F	Silent sinus syndrome	Hypoglobus, enophthalmos, restriction in upgaze, diplopia	Orbital floor	Porous polyethylene	9.7
3	40–45	M	Zygomaticomaxillary complex fracture revision	Enophthalmos, lower lid retraction, flattened malar eminence, restricted abduction, diplopia	Orbital floor and malar eminence	Porous polyethylene	4.9
4	70–75	F	Orbital floor fracture revision	Hypoglobus, enophthalmos, restriction in up and downgaze, diplopia	Orbital floor	Porous polyethylene	3.3
5	30–35	M	Orbital floor fracture revision	Enophthalmos, hypoglobus, restricted upgaze, diplopia	Orbital floor	Porous Polyethylene	3.5
6	45–50	M	Maxillary squamous cell carcinoma s/p maxillectomy with titanium implant	Hyperglobus, restricted up and downgaze, diplopia	Malar implant	Porous polyethylene	14.7
7	35–40	F	Recurrent sphenoid wing meningioma	Optic neuropathy	Lateral orbital wall	PEEK	28.3
8	20–25	M	Juvenile nasopharyngeal angiofibroma s/p resection with porous polyethylene implant	Lower lid retraction, flattened malar eminence	Orbital floor and malar eminence	Porous polyethylene	12.9



**Fig. 2.** Patient 2 with right silent sinus syndrome. A – Pre-operative frontal photograph showing right hypoglobus. B – Pre-operative worm's eye view demonstrating right enophthalmos. C – coronal CT demonstrating the inferiorly displaced orbital floor associated with silent sinus syndrome (note, the correct sinus surgery was performed 1 year prior). D – Post-operative photograph showing resolution of right hypoglobus. E – Postoperative worm's eye view showing resolution of enophthalmos.



**Fig. 3.** Patient 4 with complex fracture. A – Model of patient with right orbit and maxillary implants in position. B – Intraoperative photograph showing inferior orbital floor implant overlying the inferior orbital rim and cheek implant in apposition.

**Table 2**  
Enophthalmos and diplopia outcomes silent sinus and fracture patients.

Patient	Indication	Preoperative relative enophthalmos (mm)	Postoperative relative enophthalmos (mm)	Preoperative diplopia	Postoperative diplopia	Subjective improvement in diplopia
1	Silent sinus syndrome	2	0	Yes	No	Yes
2	Silent sinus syndrome	2	1	Yes	No	Yes
3	Zygomaticomaxillary complex fracture revision	4	0	Yes	Yes	Yes
4	Orbital floor fracture revision	3	1	Yes	Yes	Yes
5	Orbital floor fracture revision	3	0	Yes	No	Yes

maxillary sinus were reconstructed with a porous polyethylene PSI which was secured to the lateral orbital rim with a miniplate. The implant was wrapped with a temporo-parietal fascial flap due to the history of radiation. Postoperatively, he did have resolution of his diplopia in primary gaze. Patient 7 had a temporo-parietal meningioma with multiple recurrences ultimately resulting in optic neuropathy. There was massive hyperostosis of the lateral orbital wall contributing to disfiguring proptosis. The PSI was designed to create a normal, thinner lateral orbital wall to reduce proptosis. The osteotomy incisions were pre-planned, and a cutting guide was fashioned in addition to the PSI. The implant was secured into position with mini-plates inferiorly and superiorly to successfully reform the anterior lateral orbital rim. Patient 8 had undergone numerous surgeries for a juvenile nasopharyngeal angiofibroma. He ultimately had persistent lower eyelid retraction and poor projection of the maxilla. A swinging eyelid approach was used, and PSI was placed at the inferior orbital rim and secured into position with self-drilling screws. This provided support for the lower eyelid. Postoperatively, the position of the lower eyelid was improved. With the multiple surgeries and radiation, substantial middle lamellar scar developed. This was lysed, injected with 5-fluorouracil, and the eyelid was supported with a lateral canthoplasty. Mild lower eyelid retraction persisted. The patient was no longer symptomatically bothered by irritation and tearing following the procedures.

#### 4. Results

All patients in this cohort had an improved functional and aesthetic result with placement of a patient specific implant. There were no implant related complications or extrusions. The vision and eyelid position were unchanged postoperatively for all patients. A summary of the results in the fracture and silent sinus syndrome patients can be found in [Table 2](#). The three tumor patients had restoration of their anatomy in using implants specifically designed for their defect after tumor excision. The one patient with tumor resection that suffered from diplopia also had resolution of his diplopia.

#### 5. Discussion

In this pilot study, the use of PSI resulted in functional as well as aesthetic improvement in patients with various orbital abnormalities. The common thread amongst these patients was the presence of large or irregular bone defects with secondary changes in orbital volume. In cases with previous fracture repair, traditional sheet implants had been used and were ultimately inadequate or insufficient causing enophthalmos and diplopia. Primary orbital floor fracture generally requires a two-dimensional repair and implant (e.g. 0.3 mm thick nylon sheet) that spans the defect. In this review, the orbits required thicker and non-regular implants ([Figs. 2 and 3](#)), making PSI an excellent option.

While we believe that successful orbital surgery requires meticulous surgical technique and proper placement of the implant, some cases would also benefit from a PSI. With this relatively new technology, finding the ideal or most beneficial applications is still being developed. Since the success rate of single wall primary orbital fracture repair with sheet implants is excellent, this was not used as an indication for PSI. As a pilot study, PSI were utilized in cases where we believed that this technology might be most useful – revision surgeries, irregular thickness defects, and orbital rims.

Silent sinus syndrome affects the orbit by inferiorly displacing floor, causing progressive enophthalmos and hypoglobus.<sup>13</sup> The gold standard correction of this is not yet determined, with multiple techniques employed.<sup>6,7</sup> It is known, however, that the alteration of the floor is different in each patient, in both degree and shape. A PSI can be fashioned to perfectly fit this shape to restore missing orbital volume and allow for normalization of the orbital floor. This “lock-and-key” type fit was seen during surgery and clinical results were excellent with resolution of enophthalmos and diplopia in both cases.

When late post-traumatic enophthalmos secondary to fracture occurs, surgical correction may still yield inadequate results.<sup>14–16</sup> A volumetric analysis of patients with late enophthalmos without surgery quantified that orbital fat loss added to an enlarged total orbital volume, exacerbating enophthalmos.<sup>17</sup> Thus, additional volume restoration beyond bony reduction may be necessary. PSI are able to address this by providing additional volume to compensate for the loss in fat volume. In the current pilot series, PSI successfully resolved enophthalmos and allowed for significant improvement or even resolution of diplopia. It remains unclear if persistent diplopia after normalization of orbital volume is due to volumetric undercorrection or trauma-related injury (e.g. scar formation or paresis).

Tumor excision, particularly maxillectomy or orbito-zygomatic craniotomy, results in irregularly shaped orbital defects that off-the-shelf implants do not address without significant modification. With use of these materials, the result may be functionally and aesthetically unsatisfactory. An implant which is designed for the specific bony resection holds the potential for improved reconstructive outcomes. While porous polyethylene and PEEK were used in the current series, the ideal implant material for oncologic reconstruction is unclear. Traditionally, titanium mesh or autologous tissue grafts were used in areas that have had or will have radiation therapy. It is believed, through anecdotal evidence, that other alloplastic implants may lead to extrusion or increased infection rate. To date, there is no prospective literature to support this and this should be further investigated given the advances in technology now available to these patients.

Although these PSI are manufactured to fit in an ideal setting, intraoperative realities may prevent an implant from fitting – e.g. scar tissue formation from previous surgery, lack of soft tissue compliance to accommodate an implant and retractor. Both PSI materials used in the current series can be modified as needed intraoperatively either with scissors (porous polyethylene) or a high speed burr (PEEK or porous polyethylene). The PSI designed extends beyond the extent of the defect and we found not altering this design helpful, knowing that intraoperative modification is possible. With greater experience in use of these implants preoperative design can be optimized.

Our pilot series is inherently limited by sample size and its retrospective nature. However, the improvement of diplopia and enophthalmos demonstrates promise in this technology. Our follow up time was just over 10 months as it was unchanged for the purposes of this study. A prospective study with longer follow up would be useful to evaluate for sustained effect. Our sample size was limited to complex patients and while there has been success of PSI in primary orbital fracture repair,<sup>10</sup> we believe the most benefit in utilizing PSI is in challenging defects where standard implants have been historically inadequate. A comparative group was not used, although this series was not a superiority study. Volumetric analysis was not performed in this retrospective series, but prospective studies can consider this to visualize post-operative anatomy. Finally, the cost of a PSI (approximately \$3000) is greater than non-custom implants (approximately \$300), making their use in areas with limited resources difficult, although likely less expensive than revision orbital or strabismus surgery.

#### 6. Conclusion

This pilot study demonstrates that PSI are safe in orbital surgery and excellent functional and aesthetic results may be achieved. In the authors' experience, this new technology shows potential in improving outcomes in select challenging orbital reconstruction.

#### Funding

This project was not supported financially

## Patient consent

All cases presented in this report gave written consent for publication.

## Declaration of competing interest

There was no funding or grant support for this series.

## Acknowledgments

The authors have no financial disclosures to report.

## References

- Callahan AB, Campbell AA, Petris C, Kazim M. Low-cost 3D printing orbital implant templates in secondary orbital reconstructions. *Ophthalmic Plast Reconstr Surg.* 2017;33(5):376–380. <https://doi.org/10.1097/IOP.0000000000000884>.
- Kang S, Kwon J, Ahn CJ, et al. Generation of customized orbital implant templates using 3-dimensional printing for orbital wall reconstruction. *Eye Lond. Engl.* 2018;32(12):1864–1870. <https://doi.org/10.1038/s41433-018-0193-1>.
- Menzel CL, Hammacher A, Lommen J, Schorn LKF, Handschel J, Holtmann H. Orbit in a box: a simplified technique for patient-specific virtually planned orbital floor reconstruction. *J Craniofac Surg.* 2020;31(4):1117–1119. <https://doi.org/10.1097/SCS.00000000000006158>.
- Kashkoui MB, Pakdel F, Sasani L, Hodjat P, Kaghazkanani R, Heirati A. High-density porous polyethylene wedge implant in correction of enophthalmos and hypoglobus in seeing eyes. *Orbit Amst. Neth.* 2011;30(3):123–130. <https://doi.org/10.3109/01676830.2011.558971>.
- Rubin PA, Bilyk JR, Shore JW. Orbital reconstruction using porous polyethylene sheets. *Ophthalmology.* 1994;101(10):1697–1708. [https://doi.org/10.1016/s0161-6420\(94\)31113-4](https://doi.org/10.1016/s0161-6420(94)31113-4).
- Dailey RA, Cohen JJ. Surgical repair of the silent sinus syndrome. *Ophthalmic Plast Reconstr Surg.* 1995;11(4):261–268. <https://doi.org/10.1097/00002341-199512000-00007>.
- Tieghi R, Malagutti N, Valente L, Carnevali G, Clauser LC. Combined endoscopic and trans palpebral orbital reconstruction for silent sinus syndrome. *J Craniofac Surg.* 2017;28(4):955–958. <https://doi.org/10.1097/SCS.00000000000003421>.
- Eufinger H, Wehmöller M, Machtens E, Heuser L, Harders A, Kruse D. Reconstruction of craniofacial bone defects with individual alloplastic implants based on CAD/CAM-manipulated CT-data. *J Cranio-Maxillo-Fac. Surg. Off. Publ. Eur. Assoc. Cranio-Maxillo-Fac Surg.* 1995;23(3):175–181. [https://doi.org/10.1016/s1010-5182\(05\)80007-1](https://doi.org/10.1016/s1010-5182(05)80007-1).
- Copperman TS, Idowu OO, Jalaj S, et al. Patient-specific implants in oculofacial plastic surgery. *Ophthalmic Plast Reconstr Surg.* 2021;37(3):241–247. <https://doi.org/10.1097/IOP.0000000000001765>.
- Kärkkäinen M, Wilkman T, Mesimäki K, Snäll J. Primary reconstruction of orbital fractures using patient-specific titanium milled implants: the Helsinki protocol. *Br J Oral Maxillofac Surg.* 2018;56(9):791–796. <https://doi.org/10.1016/j.bjoms.2018.08.008>.
- Ono I, Tateshita T, Satou M, Sasaki T, Matsumoto M, Kodama N. Treatment of large complex cranial bone defects by using hydroxyapatite ceramic implants. *Plast Reconstr Surg.* 1999;104(2):339–349. <https://doi.org/10.1097/00006534-199908000-00003>.
- Scolozzi P, Martinez A, Jaques B. Complex orbito-fronto-temporal reconstruction using computer-designed PEEK implant. *J Craniofac Surg.* 2007;18(1):224–228. <https://doi.org/10.1097/01.scs.0000249359.56417.7e>.
- Numa WA, Desai U, Gold DR, Heher KL, Annino DJ. Silent sinus syndrome: a case presentation and comprehensive review of all 84 reported cases. *Ann Otol Rhinol Laryngol.* 2005;114(9):688–694. <https://doi.org/10.1177/000348940511400906>.
- McRae M, Augustine HFM, Budning A, Antonyshyn O. Functional outcomes of late posttraumatic enophthalmos correction. *Plast Reconstr Surg.* 2018;142(2):169e–178e. <https://doi.org/10.1097/PRS.00000000000004600>.
- Yamashita M, Daizo H, Yamashita A, Kishibe M, Shimada K. Correction of late posttraumatic enophthalmos using an antral balloon. *J Craniofac Surg.* 2015;26(4):1365–1369. <https://doi.org/10.1097/SCS.00000000000001720>.
- Kim SM, Jeong YS, Lee IJ, Park MC, Park DH. Prediction of the development of late enophthalmos in pure blowout fractures: delayed orbital tissue atrophy plays a major role. *Eur J Ophthalmol.* 2017;27(1):104–108. <https://doi.org/10.5301/ejo.5000801>.
- Cohen LM, Habib LA, Yoon MK. Post-traumatic enophthalmos secondary to orbital fat atrophy: a volumetric analysis. *Orbit Amst. Neth.* 2020;39(5):319–324. <https://doi.org/10.1080/01676830.2019.169160>.