

Acute Intestinal Intussusception of the Infant and the Child: A 5-Year Study of 66 Cases

Aloïse Sagna, Souleymane Camara, Aïssata Ly¹, Ibrahima Fall²

Albert Royer Children's Hospital, Cheikh Anta Diop University, ¹Cheikh Anta Diop University, ²Department of Paediatric Surgery, Cheikh Anta Diop University, Dakar, Senegal

Abstract

Background: Acute intestinal intussusception (AII) is defined as the telescoping of part of the intestine into the intestinal segment beneath it. The consequence is an obstruction and strangulation which can lead to necrosis of the intestinal tract that has telescoped. The aim of our work is, on the one hand, to assess our management style throughout analysis of clinical different aspects and on the other hand to set up a strategy for early diagnosis and treatment. **Methods:** It is a retrospective study over 5 years from 2010 to 2015 including infants and children who had been treated for AII in Albert Royer Children's Hospital. The following variables such as age, sex, past time before the surgical consultation, initial diagnosis, imaging data view, treatment technique and results were itemised to bear comparison. Sixty-six records were reviewed. **Results:** The mean age was 5.73 months with a range of 2 and 144 months. Boys constituted the majority of patients with a ratio of 2:1. Children were referred to us with the diagnosis of intestinal obstruction or gastroenteritis in 50% of cases. Past time average before consultation was 5.3 days with a range of 14 h and 30 days. Most of the patients underwent surgery within 48 h after the beginning of the clinical picture. An abdominal ultrasound scan confirmed the diagnosis of AII in 57 cases, whereas in 9 cases, it was normal or not contributive. Non-operative reduction by retrograde pneumatic pressure or barium enema represented 33.4% of patients against 56.6% for surgical treatment. We registered 5 deaths and 2 recurrences. AII remains the main cause of intestinal obstruction in infants. **Conclusion:** Authors stressed on delay in diagnosis with the treatment consequences belonging to that status and put emphasis in the importance of close collaboration between paediatricians, surgeons and radiologist for early diagnosis and nonoperative systematic reduction.

Keywords: Diagnosis, infant, intussusception, non-operative reduction

INTRODUCTION

Acute intestinal intussusception (AII) in the infant and the child is defined by a condition where part of the intestinal tract telescopes into the part beneath it. This anatomical state causes occlusion by the mechanism of obstruction and strangulation which can lead rapidly to intestinal necrosis. AII constitutes, therefore, an emergency with two etiological types: infant idiopathic AII which is the most frequent and AII connected to a local or general lesion of the intestinal tract.^[1] Some factors which furthered this condition are known such as intestinal parietal malformation and involvement of viral gastroenteritis due particularly to rotavirus.^[2,3] Its prognosis in our regions is still a burden to the latest of diagnosis in the stage of intestinal necrosis. The aim of this study was to make a critical assessment of

medical and surgical dealing with this affection in Albert Royer Paediatrics' Hospital and furthermore to establish a diagnostic and therapeutic strategy.

MATERIALS AND METHODS

We have recorded, in a long-term study, all cases of AII in the infant and the child admitted to the surgical unit of Albert Royer Children's Hospital. This was a retrospective study, over 4 years from 2010 to 2015, including full cases histories, physical and imaging examinations with diagnosis and treatment management. The investigation was made to

Address for correspondence: Dr. Aloïse Sagna,
Albert Royer Children's Hospital, Cheikh Anta Diop University,
Dakar, Senegal.
E-mail: alosagna109@yahoo.fr

Received: 24-11-2015 Revised: 14-02-2016 Accepted: 23-01-2018 Available Online: 05-08-2020

Access this article online

Quick Response Code:



Website:
www.afripaedurg.org

DOI:
10.4103/ajps.AJPS_127_15

This is an open access journal, and articles are distributed under the terms of the Creative Commons Attribution-NonCommercial-ShareAlike 4.0 License, which allows others to remix, tweak, and build upon the work non-commercially, as long as appropriate credit is given and the new creations are licensed under the identical terms.

For reprints contact: WKHLRPMedknow_reprints@wolterskluwer.com

How to cite this article: Sagna A, Camara S, Ly A, Fall I. Acute intestinal intussusception of the infant and the child: A 5-year study of 66 cases. Afr J Paediatr Surg 2018;15:138-41.

the following variables: age, sex, past time before the surgical consultation, initial diagnosis, imaging data view, treatment technique and results.

RESULTS

A population of 65 children was treated from April 2010 to April 2015. Our cohort was composed of 48 males and 18 females. The majority of the patients were found to be originating from the capital outlying. Epidemiological analysis had shown a peak of AII occurrence around a mean age of 5.73 months with a range of 2 and 144 months while the sex-ratio was 2:1 in favour of male with idiopathic origin in 90% of cases. The incidence of infants was at a rate of 81.8%, whereas 18.2% were between 3 and 5 years old. Most patients of that last group of older children presented secondary AII due to an intestinal tumour or Meckel's diverticulum. The study of seasonal distribution found no peak of frequency in the year.

Children were referred to us with the diagnosis of intestinal obstruction or gastroenteritis in 50% of cases. Past time average before consultation was 5.3 days with a range of 14 h and 30 days. The majority of patients underwent surgery within 48 h after the beginning of the clinical picture. The classic triad of Ombredane occurred in 35% associating paroxysmal abdominal pain, vomiting and jelly stool, but palpation of sausage-shaped mass was noticed in 15% of cases with 2 patients presenting prolapse of the telescopic intestine.

Abdominal X-ray contributed to diagnosis by showing "meniscus sign" beneath liver in 50% of cases, whereas in 50% of patients, acute bowel obstruction was diagnosed [Figure 1]. An ultrasound scan confirmed the diagnosis of AII in 56% contrary to 14% of patients of whom it was normal or not contributive [Figure 2]. Anatomical precision was made by Doppler ultrasound to 18 ileocolic, 3 ileoileas and 1 colocolic types of intussusception. The type was not defined before surgery in the vast majority of cases, namely, 57%. In one child, the diagnosis was made throughout laparoscopic investigation for appendicitis.

Non-operative treatment by retrograde pneumatic pressure, barium enema or laparoscopic reduction represented 36.6% for 24 children against 56.6% of surgical treatment [Figures 3 and 4]. Indications for open surgery were unsuccessful enema reduction or complications such as intestinal perforation, huge abdominal distension and a bad general condition due to dehydration and possibly intestinal necrosis. We noticed failure of Enema reduction three times with flatulence in 2 cases and perforation complication in 1 case. Three children faced recurrence which had been reduced by enema. Resorting to surgery in 42 patients had led to bowel segmental resection in 19 cases with 5 deaths registered following 2 hemicolectomy and 3 ileoileas anastomosis [Figures 5 and 6].

DISCUSSION

The study found out the male incidence of idiopathic AII in the infant in a sex ratio of 2:1 with a peak of frequency around 5 months-old and confirms the scarcity of AII connected to pathological lead point of the intestinal tract. Authors as Mouafo Tambo in Cameroon and Galifer in France had noticed a peak of frequency around age 1 year.^[4,5] Seasonal peaks in spring and autumn revealed by some authors such as Applegate in America were not registered in our setting.^[6]

The average past time of 5.3 days we noticed before surgery reference seemed too long. Delay in diagnosis is especially because gastroenteritis could be easily diagnosed by paediatricians when facing the condition of vomiting and diarrhoea in the infant. Thus, surgical hypothesis is evoked only when bowel obstruction is confirmed on X-ray following picture of gastroenteritis. Many authors in the literature had shown variable features explaining the delay in diagnosis, but Mirilas noticed in 50% of cases Ombredane's classic triad.^[7,8]

Abdominal ultrasound particularly when associated to coloured Doppler and lead by paediatrician radiologist is the key element of diagnosis' rapidity which constitutes the only prognostic factor influencing therapeutic outcomes. The others prognostic elements such as abdominal distension,

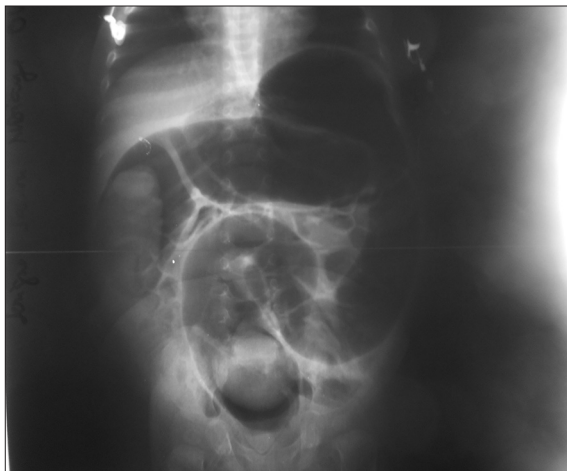

Figure 1: Meniscus sign beneath liver's shadow

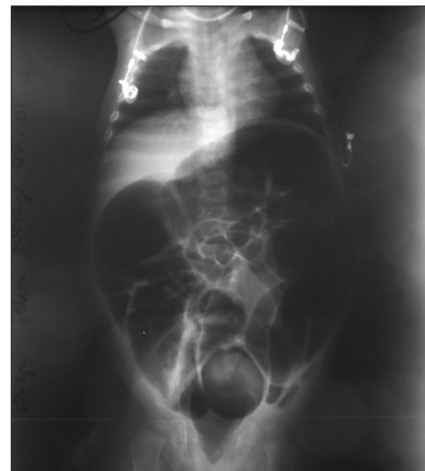

Figure 2: Air enema reduction

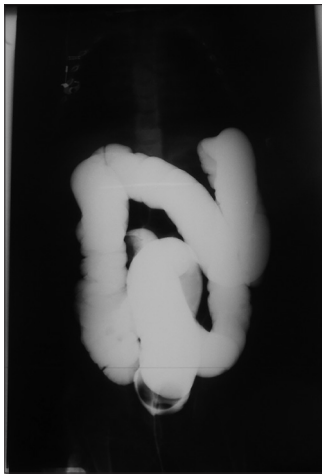

Figure 3: Barium enema reduction

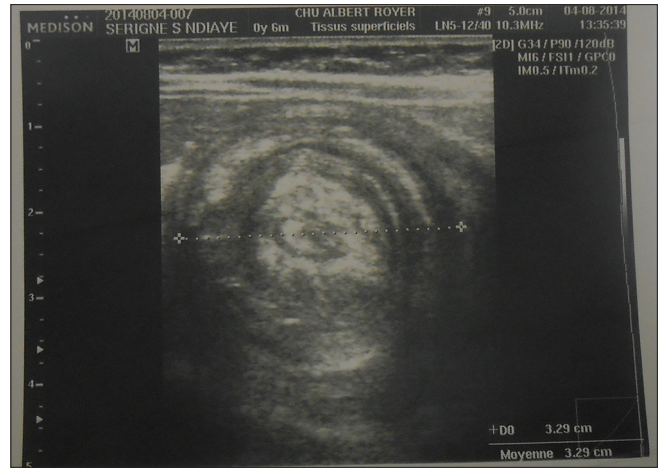


Figure 4: Ultrasound diagnosis

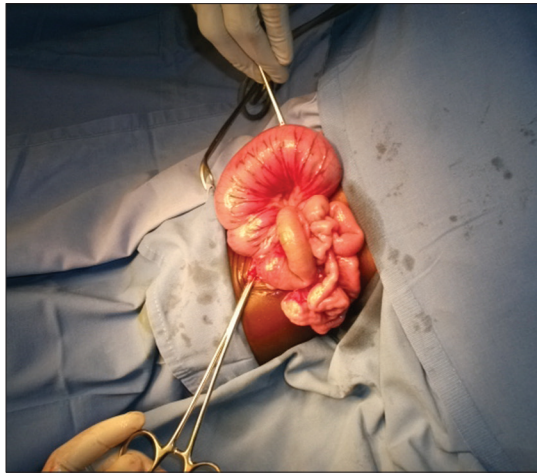


Figure 5: Surgical opening

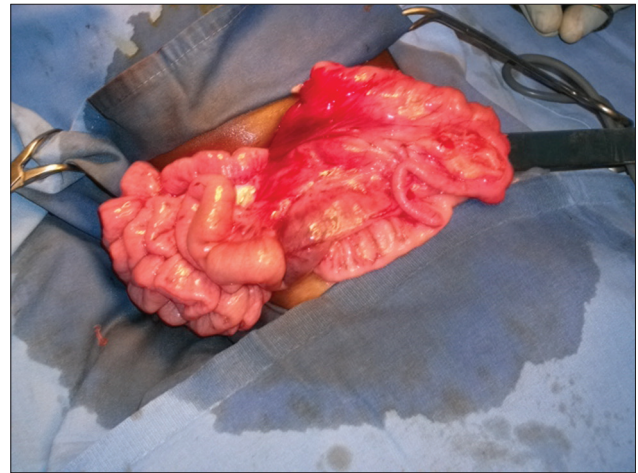

Figure 6: Conservative procedure

ischaemia and intestinal obstruction are secondary factors and reflect the low level of medical skill as well as the lack of type definition.^[9,10] The “Doughnut sign” was found in all cases in which the diagnosis of IAI was made. In 8 cases, rule out ischaemia of involved bowel was mentioned, but air enema reduction was successful. In 3 cases in which ischaemia was diagnosed by Doppler with the associated bad condition, open surgery was first indicated and did not find ischaemia but easy manual reduction. The abdominal X-ray sensitivity remains controversial, and our work has noticed ultrasound diagnosis in 55% of cases contrary to X-ray one which stands only for 5% of cases.

Success of nonsurgical treatment was obtained above fluoroscopic guidance using air enema in 20 cases or barium enema in 3 cases. The procedure was carried out in collaboration with paediatrician radiologist and anaesthetist. The patient was placed in a position of dorsal decubitus, under the cardiopulmonary monitor and fluoroscopic guidance. Sedation with diazepam was given intravenously at the rate of 0.5 mg/kg of weight, and a nasogastric tube was necessary for decompression of the stomach. A Foley catheter, 20 Fr size,

was introduced rectally and its balloon pumped up with water. The injection of air or barium was made using a 60 ml feeding syringe with the patient’s buttock hold tight. The reduction was obtained between 5 and 10 syringes under fluoroscopic and abdominal X-ray control. In one case, laparoscopic reduction was realised while performing appendectomy for appendicitis. Medical supervision was required under adequate parenteral hydration until digestion recovery and ultrasound control within 24 h. The perforation we noticed occurred with barium and the two cases of failure were linked to enormous abdominal flatulence interfering with respiratory movements. Mouafo in Cameroon reported 80% of open surgery linked to delay in diagnosis. In France, Galifer’s study about 99 cases revealed 60% of non-operative treatment while Gauthier noticed 55% regarding 119 cases.

Our mortality rate of 7% seems too high compared to that of western countries valued at around 0.6%, but still strongly charged with delay in diagnosis and lack of medical technical plate. This condition had resulted in a high rate of bowel segmental resection which is the key factor of morbidity in our study. It empowers us to define a strategy for early diagnosis

and fitting non-operative treatment. The draft protocol is based on:

- A wide range of indications for abdominal ultrasound AII screening in infant with paroxysmal abdominal pain, persistent gastroenteritis or any unexplained condition such as dehydration and shock
- An abdominal ultrasound examination performed by a well-trained paediatrician radiologist
- A systematic air enema reduction healing by the 1st intention in any case of AII with cardiopulmonary monitoring, general anaesthesia and fluoroscopic guidance.

CONCLUSION

Intussusception is one of the most frequent causes of bowel obstruction in infancy and childhood and requires emergency treatment. The authors report a 5 years' study with a great number of serious complications due to the delay in diagnosis which lead to radical surgery resulting in a high rate of mortality. Thus, a strategy based on large ultrasonic AII screening indications in infancy and childhood in collaboration with well-trained Paediatrician radiologist should allow systematic pneumatic reduction under adequate resuscitation.

Financial support and sponsorship

Nil.

Conflicts of interest

There are no conflicts of interest.

REFERENCES

1. Franchi S, Martelli H, Paye-Jaouen A, Goldszmidt D, Pariente D. Invagination intestinale aiguë du nourrisson et de l'enfant. *EMC Pédiatr* 2005;2:45-57.
2. Hervas JA, Alberti P, Bregante JI, Boya E, Reina J, Gil J. Chronic intussusception associated with yersinia enterocolitica mesenteric adenitis. *J Pediatr Surg* 1992;27:1591-2.
3. Pisacane A, Caracciolo G, de Luca U, Grillo G, Simeone C, Impagliazzo N, *et al.* Infant feeding and idiopathic intussusception. *J Pediatr* 1993;123:593-5.
4. Galifer RB, Bosc O, Couture A, Veyrac C, Baud C, Ramanoudjame P. Invagination intestinale aiguë du nourrisson et de l'enfant, evaluation critique de la stratégie diagnostique et thérapeutique: A propos d'une série de 163 cas. *Chir Pediatr* 1987;28:270-84.
5. Mouafo Tambo FF, Andze OG. Acute intestinal invagination in infants and children in the African setting: Role of early diagnosis. *Mali Med* 2009;24:46-9.
6. Applegate KE. Clinically suspected intussusception in children: Evidence-based review and self-assessment module. *AJR Am J Roentgenol* 2005;185:S175-83.
7. Mirilas P, Koumanidou C, Vakaki M, Skandalakis P, Antypas S, Kakavakis K, *et al.* Sonographic features indicative of hydrostatic reducibility of intestinal intussusception in infancy and early childhood. *Eur Radiol* 2001;11:2576-80.
8. Mangete ED, Allison AB. Intussusception in infancy and childhood: Analysis of 69 cases. *East Afr Med J* 1993;70:734-6.
9. Roussy M, Michaux F, Lemaintre G. Echographic Aspects of Intestinal Invagination. *J Radiol* 1982;63:703-5.
10. Schwischuk LE, Hayden CK, Boulden T. Intussusception: Indications for ultrasonography and explanation of the donut and pseudokidney signs. *Pediatr Radiol* 1985;15:388-91.