

ENHANCEMENT OF EPIDERMAL REGENERATION BY
BIOSYNTHETIC EPIDERMAL GROWTH FACTOR

BY GREGORY L. BROWN,* LUKE CURTSINGER, III,*
JOSEPH R. BRIGHTWELL,* DOUGLAS M. ACKERMAN,‡
GORDON R. TOBIN,* HIRAM C. POLK, JR.,*
CARLOS GEORGE-NASCIMENTO,§ PABLO VALENZUELA,§ AND
GREGORY S. SCHULTZ¹

*From the Departments of *Surgery, ‡Pathology, and ¹Biochemistry, University of Louisville,
Louisville, Kentucky 40292; and §Chiron Research Laboratories, Chiron Corporation,
Emeryville, California 94608*

Normal regeneration of the epidermis after a split-thickness injury requires mitosis and migration of epidermal cells from the residual epidermal appendages within the wound as well as from the intact epithelium surrounding the injury (1). Acceleration of epidermal regeneration by a pharmacologic agent may result in more rapid wound healing. Epidermal growth factor (EGF), a well-described (2) small peptide hormone, is a potent mitogen for human epidermal cells in vitro (3). A limited number of clinical and experimental attempts to show enhanced epidermal regeneration of split-thickness injuries using mouse EGF have been unsuccessful (4–6). The purpose of this study was to evaluate the in vivo effectiveness of biosynthetic human EGF obtained from genetically engineered yeast in accelerating epidermal regeneration in split-thickness wounds and partial-thickness burns in an experimental animal model.

Materials and Methods

Reagents. Human EGF (hEGF) was produced as described (7). Lanolin was from Squibb Pharmaceutical Co. (Princeton, NJ) and 1% silver sulfadiazine in a water-miscible base (Silvadene) was from Marion Laboratories (Kansas City, MO).

Split-thickness Epidermal Wounds. 84 split-thickness wounds (0.005 inches thick, 1 × 1 cm) were made on the dorsal thorax of four adult miniature pigs (Vita-Vet Laboratories, Marion, ID). Twice a day, 28 wounds on each pig were treated with hEGF in cream (lanolin or Silvadene), 28 were treated with the cream alone, and 28 were untreated. Four wounds from each group on each pig were randomly selected daily and entirely excised at a depth of 0.007 inches, including 5 mm of surrounding normal skin. Epidermis and dermis were readily separated from excised specimens after incubation in trypsin, and wounds were considered healed when no defect was present (8).

Partial-thickness Burns. A brass template (3 × 5 cm, 430 g) was heated to 70°C in a constant-temperature water bath and then pressed for 10 s in contact with depilated dorsal skin of Yorkshire piglets (14–20 pounds); the resultant blister was removed. Histological evaluation of biopsy specimens confirmed that partial-thickness burns were produced. On each pig, two burns were treated twice a day with hEGF in Silvadene (0.5 ml cream per square centimeter of burn), two burns were treated with Silvadene alone, and two were untreated.

This work was supported in part by the U.S. Army Medical Research Acquisition Activity, Contract DAMD17-85-C-5197. Address correspondence to G. S. Schultz, Department of Biochemistry, University of Louisville, Louisville, KY 40292.

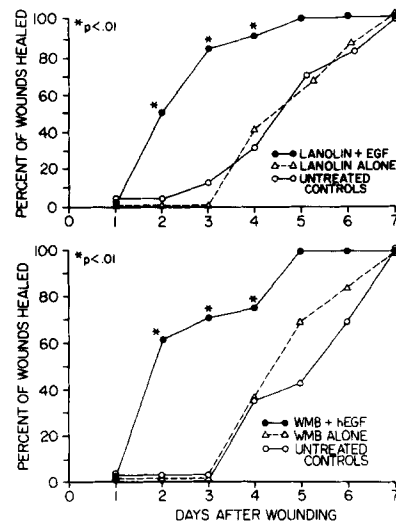


FIGURE 1. Effects of hEGF and vehicles on healing of split-thickness wounds. Each point represents the data from 16 wounds treated with hEGF ($10 \mu\text{g}/\text{ml}$) in the indicated vehicles, with vehicles alone, or with no treatment. Values were compared for statistical significance by χ^2 analysis. WMB, water-miscible base (Silvadene).

Identities of the creams were masked. After 7 d, the fibrinous coagulum was removed and burns were photographed. The percentage of the original burn area that was judged to be epithelialized was calculated by computerized planimetry of enlarged photographs. Results were analyzed by one-way analysis of variance. Random biopsies were evaluated histologically for extent of epithelial regeneration.

The effects of varying concentrations of hEGF on epithelial regeneration were evaluated using similar techniques. 10 burns ($3 \times 3 \text{ cm}$) were made on the dorsal thorax of individual Yorkshire piglets; one pair was treated twice daily with Silvadene alone, one pair was untreated. The remaining three pairs of wounds were treated twice daily, with one pair receiving $10 \mu\text{g}/\text{ml}$ hEGF Silvadene, one pair receiving $1 \mu\text{g}/\text{ml}$, and one pair receiving $0.1 \mu\text{g}/\text{ml}$. After 7 d, the extent of epithelial regeneration was determined.

Results

Split-thickness Epidermal Wounds. As shown in Fig. 1, 50% of the hEGF-lanolin-treated wounds ($n = 16$) were healed at 2 d, whereas the untreated and lanolin-treated control groups required >4 d for 50% of the wounds to heal. All wounds in each group ($n = 16$) were healed by day 7. Similarly, 60% of wounds treated with hEGF in Silvadene were healed at 2 d, whereas for 60% of the untreated wounds and 60% of controls treated with Silvadene alone, >4 d were required for the wounds to heal. All wounds were healed at the end of 1 wk. In both cases the wounds treated with hEGF significantly ($p < 0.01$) accelerated epidermal regeneration, compared with untreated wounds or wounds treated with the creams alone.

Of the wounds that healed, both control wounds and hEGF-treated wounds were similar in histologic appearance from 7 d, with no evidence of metaplastic transformation in the hEGF-treated wounds. All three groups showed a 10–12-cell layer of stratified squamous epithelium characteristic of normal pig skin.

Partial-thickness Burns. A representative photograph of the three treatment groups is shown in Fig. 2. After 7 d, virtually complete epidermal regeneration

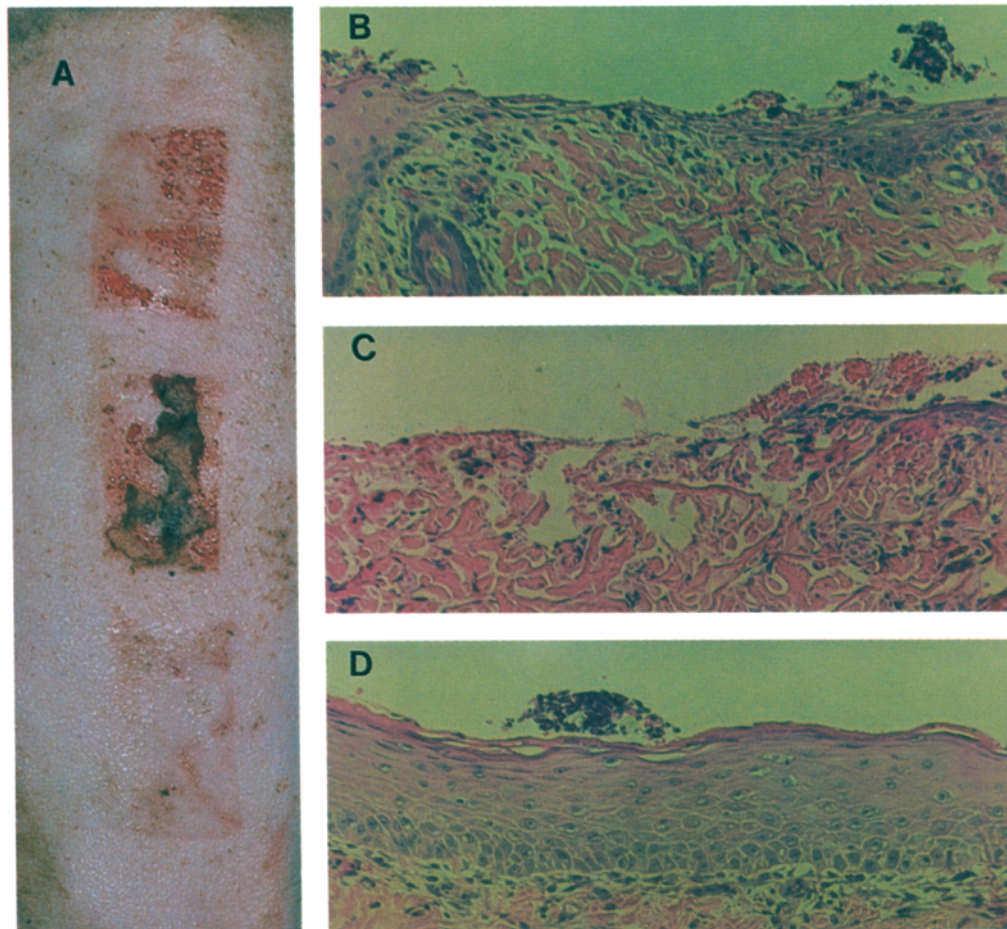


FIGURE 2. Effects of hEGF and vehicles on healing of partial-thickness burns. A shows the gross appearance of 3×5 cm burns after 7 d of treatment with Silvadene (top burn), untreated (middle burn), or treated with hEGF ($10 \mu\text{g}/\text{ml}$) in Silvadene (bottom burn). Microscopic histology of these burns is shown in panels B, C, and D, respectively. $\times 200$.

TABLE I
Effect of hEGF and Vehicle on Healing of Partial-thickness Burns

Treatment	Percentage of burn area healed
hEGF	93 ± 6
Control	36 ± 18
Untreated	17 ± 11

$p < 0.01$ using one-way analysis of variance and Tukey's Honest Statistical Difference (HSD) test. Quantitative planimetry measurements were performed on photographs of partial-thickness burns that were treated for 7 d with hEGF in Silvadene ($10 \mu\text{g}/\text{ml}$), Silvadene alone (control) or untreated. Values are mean \pm SD for eight wounds.

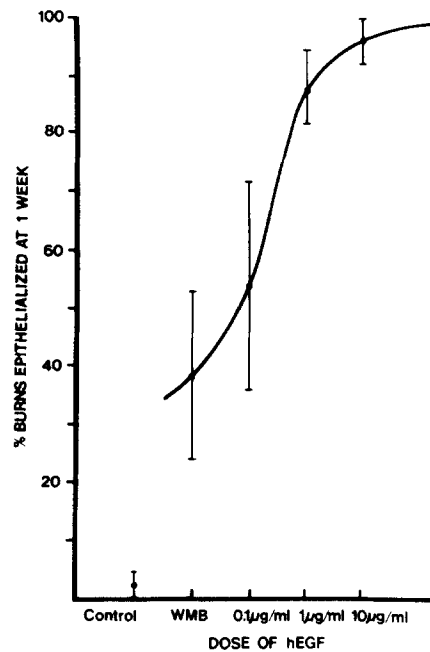


FIGURE 3. Response of partial-thickness burns to varying doses of hEGF. Partial-thickness burns (3×3 cm) were treated for 7 d with Silvadene alone, Silvadene containing hEGF (10 $\mu\text{g}/\text{ml}$, 1 $\mu\text{g}/\text{ml}$, 0.1 $\mu\text{g}/\text{ml}$), or were not treated. The percentage of original burn area that had healed was measured by quantitative planimetry of photographs. Each data point is the mean \pm SD for four burns. WMB, water miscible base (Silvadene).

occurred in partial-thickness burns treated with hEGF in Silvadene, while substantial areas of the untreated burns or burns treated with base cream alone were not healed. Results of quantitative planimetry are shown in Table I.

Biopsy specimens taken 7 d after burn injury confirmed complete epidermal regeneration in those areas judged to be healed in the photographs (Fig. 2). Regenerated epidermis of hEGF-treated burns showed stratification, prominent nucleoli within cells, limited intercellular edema, and a moderate dermal inflammatory response that is typical of proliferating epidermis. In contrast, very little epidermal regeneration was observed in burns treated with Silvadene alone, or in untreated burns. Biopsy specimens taken 35 d after burn injury revealed normal epidermal and dermal architecture in all groups with no evidence of metaplasia in burns treated with hEGF.

As shown in Fig. 3, all concentrations of hEGF, as well as Silvadene alone, significantly ($p < 0.05$) increased the percentage of healed burn surface area compared with untreated controls. However, only burns treated with hEGF at 10 $\mu\text{g}/\text{ml}$ were significantly ($p < 0.05$) more healed than the burns treated with Silvadene alone. Histological evaluation of representative biopsy specimens confirmed the complete epidermal regeneration in areas judged to be healed in photographs of the burns.

Discussion

The mitogenic effect of EGF has been shown *in vitro* to require the continuous exposure of target cells to EGF for a minimum of 6–12 h (9). Previous studies

(4-6), which failed to show an acceleration of healing by EGF for partial-thickness epidermal wounds, may have used conditions that did not provide sufficient continuous exposure of residual epithelial cells to EGF. Greaves (4) applied mouse EGF at a final concentration of 50 $\mu\text{g}/\text{ml}$ in saline to the base of suction blisters on volunteers for 5 min once daily, then the excess solution was removed and the areas were covered with sterile occlusive dressings. In a similar manner, Arturson (5) used either a single daily application of mouse EGF (0.5 mg/ml in saline) as a topical mist or a single daily intraperitoneal injection of EGF (3 $\mu\text{g}/\text{g}$ body weight) for treatment of epidermal wounds made in rats by repeated strippings with adhesive tape or by immersion in 90°C water for 20 s. Thornton et al. (6) applied mouse EGF topically (1.5 $\mu\text{g}/\text{cm}^2$ burn surface area) as a mist once daily, then applied Silvadene to partial-thickness burns produced on rats by immersion in 90°C water for 5 s. All three of these studies reported no significant increase in epithelial regeneration by EGF treatment. In a separate set of pilot experiments, we also were unable to show an effect with hEGF applied topically in a mist or in saline to partial-thickness wounds (unpublished data).

In this study, hEGF was mixed with topical cream and the mixtures were applied twice daily. The highly significant increase in healing of these wounds was most likely due to the creams providing more continuous exposure of residual epidermal cells to hEGF, and thus increasing their mitotic activity. Similar results have been obtained by others (L. Nanney, Vanderbilt Univ. Dept. of Surgery, personal communication) using EGF topically for the treatment of partial-thickness wounds. Also, Buckley et al. (10) recently reported that sustained release of EGF from subcutaneous pellets accelerated processes of wound repair in rats, whereas daily injections of EGF were much less effective. In an earlier study of full-thickness wound healing, Franklin and Lynch (11) applied mouse EGF in a water-miscible ointment to full-thickness wounds in rabbit ears and reported a qualitative enhancement of wound healing. In terms of understanding how EGF accelerates epidermal regeneration in vivo, Rhinewald and Green (3) showed that, in vitro, EGF recruits a higher percentage of cells to leave the resting state (G_0) and enter and remain in the mitotic cycle. Assuming a similar effect of EGF on epidermal cells in vivo, the primary mechanism of enhanced wound healing produced by hEGF in these experiments is most likely due to increased proliferation of epidermal cells.

An important physiological distinction exists between healing of partial-thickness and full-thickness epidermal wounds: full-thickness wounds heal predominantly by contracture, with epidermal regeneration playing a minor role (12). There is evidence to suggest that EGF plays an important role in normal healing of full-thickness cutaneous wounds as well. Removal of mouse submandibular glands, which synthesize and secrete high levels of EGF, reduced the rate of healing of full-thickness wounds in mice housed individually (13). Both repeated topical application of mouse EGF to the wounds or communal licking by intact mice promoted wound closure (14). Other factors from mice submandibular glands, such as the protease subunit of the high-mol-wt nerve growth factor complex, also may stimulate closure of full-thickness wounds (15, 16).

Occlusive dressings, such as polyethylene film, have been shown (17) clinically to accelerate healing of selected partial-thickness injuries. However, occlusive dressings are virtually limited to use on sterile skin graft donor sites, because they produce an environment favorable to increased bacterial growth.

Summary

Epidermal regeneration depends on mitosis and migration of keratinocytes. Epidermal growth factor is known to stimulate growth of keratinocytes in vitro, thus it might be expected to promote wound healing. The results of this study show that topical application of biosynthetic human epidermal growth factor accelerates epidermal regeneration in split-thickness wounds and partial-thickness burns. The significant enhancement of epidermal regeneration suggests the potential for clinical use of epidermal growth factor for accelerating healing of burns, wounds from trauma, diabetic ulcers, skin graft donor sites, and others.

Received for publication 30 October 1985.

References

1. Krawczyk, W. S. 1971. A pattern of epidermal cell migration during wound healing. *J. Cell Biol.* 49:247.
2. Cohen, S., and J. Carpenter. 1975. Human epidermal growth factor: Isolation and chemical and biological properties. *Proc. Natl. Acad. Sci. USA.* 72:1317.
3. Rheinwald, J. G., and H. Green. 1977. Epidermal growth factor and the multiplication of cultured human epidermal keratinocytes. *Nature (Lond.)*. 265:421.
4. Greaves, M. W. 1980. Lack of effect of topically applied epidermal growth factor (EGF) on epidermal growth in man in vivo. *Clin. Exp. Dermatol.* 5:101.
5. Arturson, G. 1984. Epidermal growth factor in the healing of corneal wounds, epidermal wounds, and partial-thickness scalds. *Scand. J. Plast. Reconstr. Surg.* 18:33.
6. Thornton, J. W., C. A. Hess, V. Cassingham, and R. H. Bartlett. 1981. Epidermal growth factor in the healing of second degree burns: A controlled animal study. *Burns.* 8:156.
7. Brake, A. J., D. J. Julius, and J. Thorner. 1984. α -factor directed synthesis and secretion of mature foreign proteins in *Saccharomyces cerevisiae*. *Proc. Natl. Acad. Sci. USA.* 81:4642.
8. Eaglstein, W. H., and P. M. Mertz. 1981. Effect of topical medicaments on the rate of repair of superficial wounds. In *The Surgical Wound*. P. Dineen and G. Hildick-Smith, editors. Lea and Feibiger, Philadelphia, PA. pp. 150-170.
9. Carpenter, G., and S. Cohen. 1975. Human epidermal growth factor and the proliferation of human fibroblasts. *Cell Physiol.* 88:227.
10. Buckley, A., J. M. Davidson, C. D. Kamerath, T. B. Wolt, and S. C. Woodward. 1985. Sustained release of epidermal growth factor accelerates wound repair. *Proc. Natl. Acad. Sci. USA.* 82:7340.
11. Franklin, J. D., and J. B. Lynch. 1979. Effects of topical applications of epidermal growth factor on wound healing. *Plast. Reconstr. Surg.* 64:766.
12. Abercrombie, M., D. W. James, and J. F. Newcombe. 1961. In *Wound Healing*. D. Slome, editor. Pergamon Press, London. pp. 10-25.
13. Hutson, J., M. Niall, D. Evans, and R. Fowler. 1979. Effect of salivary glands on wound contraction in mice. *Nature (Lond.)*. 279:793.
14. Niall, M., G. B. Ryan, and B. McC. O'Brien. 1982. The effect of epidermal growth factor on wound healing in mice. *J. Surg. Res.* 33:164.
15. Li, A. K. C., M. J. Koroly, M. E. Schattenkerk, R. A. Malt, and M. Young. 1980. Nerve growth factor: Acceleration of the rate of wound healing in mice. *Proc. Natl. Acad. Sci. USA.* 77:4379.
16. Li, A. K. C., and M. J. Koroly. 1981. Mechanical and humoral factors in wound healing. *Br. J. Surg.* 68:738.
17. Hinman, C. D., and H. Maibach. 1963. Effect of air exposure and occlusion on experimental human skin wounds. *Nature (Lond.)*. 200:377.