Review Article

Intraoperative lung ultrasound: A clinicodynamic perspective

Amit Kumar Mittal, Namrata Gupta

Department of Anesthesiology and Critical Care, Rajiv Gandhi Cancer Institute and Research Centre, New Delhi, India

Abstract

In the era of evidence-based medicine, ultrasonography has emerged as an important and indispensable tool in clinical practice in various specialties including critical care. Lung ultrasound (LUS) has a wide potential in various surgical and clinical situations for timely and easy detection of an impending crisis such as pulmonary edema, endobronchial tube migration, pneumothorax, atelectasis, pleural effusion, and various other causes of desaturation before it clinically ensues to critical level. Although ultrasonography is frequently used in nerve blocks, airway handling, and vascular access, LUS for routine intraoperative monitoring and in crisis management still necessitates recognition. After reviewing the various articles regarding the use of LUS in critical care, we found, that LUS can be used in various intraoperative circumstances similar to Intensive Care Unit with some limitations. Except for few attempts in the intraoperative detection of pneumothorax, LUS is hardly used but has wider perspective for routine and crisis management in real-time. If anesthesiologists add LUS in their routine monitoring armamentarium, it can assist to move a step ahead in the dynamic management of critically ill and high-risk patients.

Key words: Alveolar interstitial syndrome, atelectasis, intraoperative desaturation, lung ultrasound, pneumothorax

Introduction

Once considered inaccessible, lung ultrasonography has emerged as an indispensible tool in critical care practice. Evidence suggests that clinicians outside radiology can be quickly skilled in limited area of ultrasonography,[1,2] similarly anesthesiologist can easily adopt lung ultrasound (LUS), in routine anesthesia practice and explore its true potential for perioperative care, allowing the anesthesiologist to diagnose various critical conditions precisely to implement therapeutic measures before the catastrophe ensues.

Adequacy of intraoperative lung function is assessed by monitoring vital parameters, spirometry, and sometimes radiography with variable outcomes.[3] Spirometry and radiography has been acknowledged with low accuracy and limitations.[4-6] In the last decade, ultrasonography has emerged as a new promising monitoring aid to improve anesthesiologists diagnostic and interventional skills,[7] and moving a step ahead in dynamic management of critically ill and high-risk patients. The aim of this article is to review the scientific basis of LUS (analysis of artifacts generated due to the admixture of air and lung tissue) and its clinical applications in day-to-day anesthesia practice. Search for articles was carried out using search engines such as Google Scholar and PubMed. Words used for the search were "lung ultrasound," "pneumothorax," "pulmonary edema," "atelectasis," "endobronchial intubation," "alveolar interstitial syndrome," and "intraoperative desaturation."

History of Lung Ultrasound

Pierre Curie and Jacques Curie in 19th century discovered piezoelectric effect of certain crystals (e.g., Quartz), which were later developed by Langevin.[8] In middle of 20th century Dussik brothers[9] described the diagnostic properties of

Address for correspondence: Dr. Amit Kumar Mittal, Department of Anesthesiology and Critical Care, Rajiv Gandhi Cancer Institute and Research Centre, Sector 5, Rohini, New Delhi, India.
E-mail: amitrgci@gmail.com

Access this article online	
Quick Response Code:	Website: www.joacp.org
	DOI: 10.4103/0970-9185.188824

This is an open access article distributed under the terms of the Creative Commons Attribution-NonCommercial-ShareAlike 3.0 License, which allows others to remix, tweak, and build upon the work non-commercially, as long as the author is credited and the new creations are licensed under the identical terms.

For reprints contact: reprints@medknow.com

How to cite this article: Mittal AK, Gupta N. Intraoperative lung ultrasound: A clinicodynamic perspective. J Anaesthesiol Clin Pharmacol 2016;32:288-97.

ultrasound and Joyner *et al.*[10] in 1967 studied utility of thoracic ultrasound for diagnosing pleural effusion. In 1978 La Grange *et al.*[11] used ultrasound for guiding needle placement in nerve blocks. Lichtenstein and Axler the pioneer of LUS, in the early 90s evaluated the scientific principle of LUS.[7]

Principle of Lung Artifacts

Reflection of the ultrasound beam by an interface between the media of different acoustic impedance is the basis of LUS, succeeding which Lichtenstein[12] gave seven basic principles of lung sonography. No impedance to air was detected in aerated lung. Hence no visible image is generated, but pleura is the only structure, visualized as the hyperechoic horizontal line[13] [Figure 1]. The anatomical configuration of the thorax is such that air and water inherently mix to invoke artifacts. Apart from these intrinsic properties both air and water have divergent gravitational dynamics (air rises and water descends). This pivotal interface classify water rich pathologies as "Dependent disorders" (pleural effusion, atelectasis, and alveolar consolidations), and air rich pathologies as "nondependent disorders" (interstitial syndromes, pneumothorax).[14]

Methodology

LUS can be performed using any commercially available portable ultrasound machine with acceptable image quality. The high-frequency linear probe (5-12 MHz) is well-suited for pleural analysis while deeper structures can be analyzed with convex and micro-convex probes (2-5 MHz). Conventional B-mode imaging is adequate, and can be aided with M-mode or color Doppler in some difficult situations. Lung pathologies have two main components that is, air and water, which according to gravitational law are either on top (air) or bottom (water), thus probe should be positioned in accordance to suspected pathology. For water containing pathology (pleural effusion) probe should be placed at bases and for air containing pathology (pneumothorax) at apices, scanning should be done in systematic manner for unsuspected pathology (from apex to base and from anterior to lateral chest). Intraoperative LUS can be performed in supine and semilateral position by placing transducer along the longitudinal axis in anterior and lateral upper chest between second to fourth intercostal spaces on both sides of hemithorax.[15] Most practical intraoperative approach for LUS is to scan 4 areas on each hemithorax[16] [Figure 2].

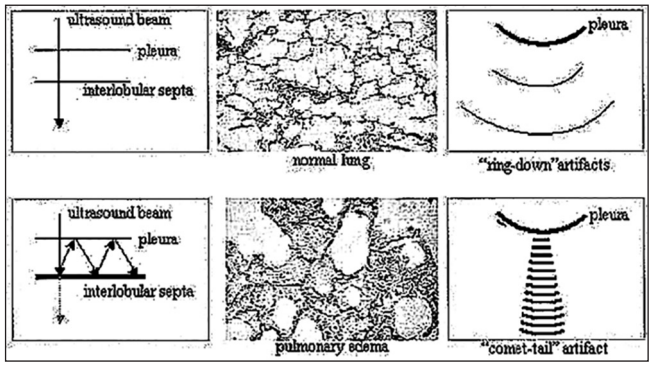

Figure 1: Physical and anatomic basis of echo lung comets. Reflections of the ultrasound beam by the thickened interlobular septa proved comet-tail artifact in patients with extravascular lung water (reprinted with permission from Jambrik *et al.*)

Normal lung semiology

On scanning chest, adjacent ribs produces black shadow while pleura appears as a horizontal hyperechoic line, roughly 0.5 cm below ribs, suggestive of the parietopulmonary interface. These typical ribs and pleural interface illustrate typical "Bat Sign" appearance [Figure 3].

Pleura on LUS produces a scintillating synchronized movement with respiration, known as "Lung Sliding" which is a dynamic sign indicative of normal lung anatomy. Movement of pleura in relation to immobile superficial chest wall, produces air artifact as regular repetition of horizontal lines, known as "A-lines," which is a static sign and physiological artifacts associated with lung sliding.[17] In some clinical situations (morbidly obese, advance age, emphysema, etc.), when lung sliding is not appreciated, "A-lines" can be objectified on M-mode as superficial motionless chest wall layers mimics waves while deeper layer artifacts creates sandy pattern, called "Sea Shore" sign [Figure 4].

After revealing normal semiology, artifacts used to diagnose pathological conditions are clarified below, which are important to diagnose intraoperative emergencies that warrant immediate intervention. A preoperative lung scanning is must to diagnose any intraoperative aberrations.

Alveolar Interstitial Syndrome

Diverse etiological factors have been found to be associated with perioperative pulmonary edema [Table 1]. Arieff[18] in his study of elective surgery patients, reported the incidence of perioperative pulmonary edema as 7.6%, and mortality due to it to be 11.9%.

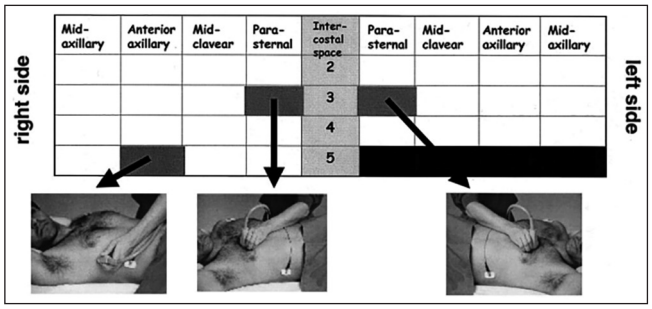

Figure 2: Methods of lung scanning (reprinted with permission from Jambrik *et al.*)

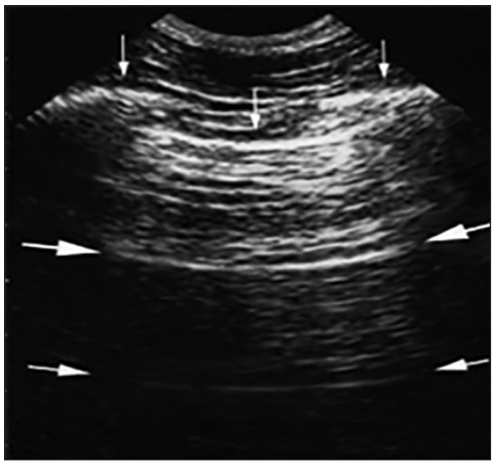

Figure 3: "Bat sign" appearance (small vertical arrows, central arrow is pleura while lateral arrows indicates rib shadow) and A-lines (big horizontal arrows)

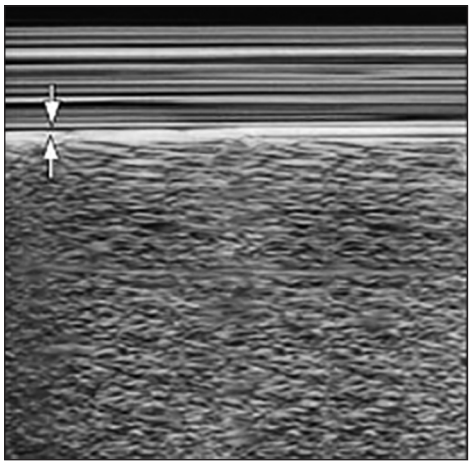

Figure 4: "Sea Shore sign" (M-mode, arrow indicates pleural line, above the arrow is chest wall, and sandy is lung parenchyma)

Table 1: Factors leading to peri-operative pulmonary edema

Left heart failure
Impaired systolic and/or diastolic function (ischemia/infarction; cardiomyopathy)
Pericardial tamponade/effusion
Iatrogenic volume overload
Drug-induced (e.g., Anesthetic overdose)
Aortic cross clamp
Low-output syndrome (after cardio-pulmonary by pass)
Post cardioversion
Overactive adrenergic state (naloxone for opioid reversal)
Adult respiratory distress syndrome
Sepsis
Pulmonary aspiration
Pulmonary embolism (air, fat, thrombus)
Amniotic fluid embolism
Eclampsia of pregnancy
Post pneumonectomy or lobectomy
Neurogenic pulmonary edema
Negative pressure pulmonary edema

Alveolar interstitial syndrome (AIS) is a radiological entity, manifests on LUS as B-lines, which develops due to seepage which of extra fluid into the interstitium, and it correlates with pulmonary edema. The presence of diffuse AIS is highly indicative of pulmonary edema (sensitivity 93.6%, specificity 84%, positive predictive value 87.9%, and negative predictive value 91.3%).[19]

Methodology

B-line artifact (comet-tail artifact) on LUS are found to be correlated with Kerley B-lines on chest radiography,[15] with extravascular lung water (EVLW),[20] and with severity of diastolic dysfunction.[21]

B-lines are vertical lines originating from pleura and formed due to water thickened or fibrotic interlobular septa,[22] with specific peculiarities [Figure 5]. These are well defined, hyperechoic, laser-like reverberation, extending indefinitely up to the bottom of the screen, erasing A-lines, and is synchronous with lung sliding. In the presence of EVLW, ultrasound beam finds thickened subpleural interlobular septa that are an area of low impedance, with a high acoustic mismatch, causing reflectance of the beam and creates resonance. Such successive reverberations creates the time lag and is interpreted behaves like a persistent source and generating a series of closely spaced interfaces.[23]

Interpretation of B-lines and should be done cautiously for diagnosis and evaluation of AIS, and ideally scanning should be done in eight regions of anterior and lateral chest wall. Scanning of 28 rib technique given by Jambrik *et al.*[15] should be implemented for semi quantification of the interstitial syndrome. In an emergency situation, scanning of anterior two regions may suffice for rapid detection of the interstitial syndrome. This test is defined negative, when either B-lines are absent, solitary or <3 in number of isolated scanned field or present only in last intercostal space above diaphragm (which may be a normal variant observed in 27% healthy subjects[22]). When the distance between two B-lines is <7 mm or count of B-lines are >3 in each scanned area, it is considered positive B-profile.[24] If these B-profiles are present in two or more areas bilaterally or all over the lung surface, it is specific of AIS. Picano *et al.*[14] gave the scoring system to yield a score of B-lines, denoting the extent of EVLW, score ≥6 is suggestive of a mild degree of AIS while score ≥30 indicates severe AIS [Table 2]. Twenty-eight rib scanning technique to yield a score of B-lines is most informative, but impractical intraoperatively and can be used in postoperative period. Eight area scanning technique given by Volpicelli *et al.*[16] is more practical approach for intraoperative use.

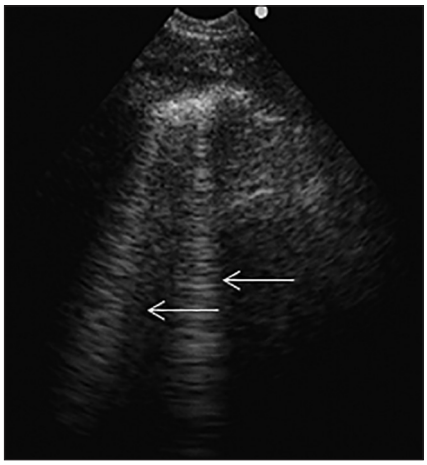

Figure 5: "Comet-tail" or B-lines (white arrows)

Table 2: Scoring of B-lines

Score	No. of B-lines	Extravascular lung water
0	≤5	No Sign
1	6-15	Mild degree
2	16-30	Moderate degree
3	>30	Severe degree

Reprinted with permission from Picano et al.

Clinical Implication

Intraoperative intravascular volume assessment is one of the most difficult tasks and is pivotal to the perioperative outcome. Superiority of goal-directed therapy to restrictive fluid strategy is still debatable,[25] and even advanced hemodynamic monitoring aids (both static and dynamic) used for intraoperative fluids assessment, come with variable inference. None of monitors for fluid assessment is gold standard for intraoperative use with uniformity in all patients, as the preference depends on ASA physical status of patients, the extent of surgery, and major fluid shifts.[26,27] Furthermore, dynamic indices have their own limitations in presence of arrhythmias and patients on spontaneous breathing. Sometimes, patients may be at responsive part of Fick's cardiac output curve, and are unable to tolerate the transfused fluid, probably due to leaky lung capillaries, which can be detected as B-lines, hence EVLW. LUS detects quiescent pulmonary edema much earlier before the patient desaturates or clinically evident heart failure ensues. Thus, it can keep real-time vigilance on fluid transfusion and its tolerance. LUS aids in restricting fluid, planning to decongest the lung and following the response of therapeutic intervention. Before interpreting and concluding LUS findings, these scans should be compared with preoperative scans, as these focal or diffuse B-lines can be seen in pneumonia, atelectasis, pulmonary contusion, pulmonary infarction, neoplasms, and pleura disorders.

Pneumothorax

Pneumothorax is a potentially serious perioperative complication, due to numerous surgical, iatrogenic, and medical etiologies.[28] It presents as acute desaturation and cardiorespiratory instability, and if not diagnosed timely can progress to life-threatening tension pneumothorax.

Methodology

Pneumothorax is a nondependent pathology, thus can be located in least dependent areas of chest.[29,30] Transducer probe is first placed longitudinally in third and fourth intercostal space, and then gradually scanning these spaces from anterior to inferior areas of the chest between parasternal to the midclavicular line.[31] The focus should be emphasized to locate parietal pleura, which usually lies 0.5 cm below the rib shadow.[32]

Sonographic signs of pneumothorax

Sonographic diagnosis of pneumothorax is not straight forward, but requires sequential recognition and exclusion of different artifacts in protocol-based manner. Though LUS artifacts, appear complex to identify, even brief training can allow easy recognition of pneumothorax.[33] Identification of following four sonographic signs: Absence of lung sliding, B-lines, and lung pulse and the presence of lung point are required for diagnosis.[17]

Lung sliding

Lung sliding has a negative predictive value of 100% in pneumothorax.[32] Absence of lung sliding can also be found in numerous other clinical scenarios such as adult respiratory distress syndrome (ARDS), massive atelectasis, pleural adhesions, endobronchial intubations, cardiopulmonary resuscitations, and phrenic nerve palsy[34] Due to these various confounding conditions, the specificity of LUS in critical scenarios varies from 91% in general population,[31] 78% in all critically ill patients, and 60% in ARDS patients.[35] Positive predicted value of LUS is 22% in all critically ill patients.[36] Lung sliding appears as a blush of color under the pleura in color Doppler mode, whenever in doubt, it can be used to confirm lung sliding.[37] It can also be objectified on M-mode as multiple horizontal lines known as "Stratosphere" sign[13] [Figure 6].

B-Lines

It is one of the key sign to be checked for disregarding diagnosis of pneumothorax and has an indirect interpretation, as the presence of B-lines indicates intact/adherent pleura. The presence of even single B-line can safely be used to rule out pneumothorax with 100% true negative rate.[38]

Lung pulse

Lung pulses are tenuous, rhythmic, vertical movement of visceral upon parietal pleura synchronous with cardiac pulsations, and are caused by transmission of cardiac oscillations through motionless lung and can be objectified on M-mode[34,39] [Figure 7]. Lung pulse is also evident in massive atelectasis, consolidations, endobronchial intubations, One lung ventilation or simply in apneic breath holdings.[34] The presence of lung pulse can safely rule out pneumothorax in the absence of lung sliding with sensitivity of 93%.[34] Conversely absence of lung pulse with absence of lung sliding goes in favor of pneumothorax.

Lung point

Lung point represents transitional area of absence of lung sliding to area of presence of lung sliding, or absence of B-lines to area of presence of B-lines, or is the point from motionless pleura to normal respiratory pattern [Figure 8]. This lung point should be mapped from anterior inferior area to lateroinferior area, where it can confidently be used to define the physical limits of pneumothorax.[36,40] Thus more lateral the lung point more extensive is the pneumothorax. Lung point is a pathognomonic sign of pneumothorax with 100% specificity.[35] Unfortunately, the sensitivity of this sign is very low, as there is no lung point in complete retraction of lung, and sometimes it is not possible to define desired chest area intraoperatively. That's why it is recommended to incorporate all LUS sign in the sequential and protocol-based manner before reaching any conclusion as given by Volpicelli.[41]

Clinical Implications

The exact incidence of intraoperative pneumothorax is not known, and it varies from 0.01% in laproscopic surgeries[42] to 14% in mechanical ventilation.[43] Its incidence is likely to upsurge in modern clinical practice due to increased use of invasive monitoring and newer modes of mechanical ventilation. The diagnosis of pneumothorax in an anesthetized patient is always difficult, due to the subdued clinical presentation and its resemblance to bronchospasm. In an unexplained intraoperative desaturation, with or without cardiorespiratory instability, pneumothorax should be suspected and ruled out especially if the patient is undergoing procedures prone to pneumothorax. Pneumothorax once suspected should be confirmed, and chest X-ray is always the preferred method in diagnosis of pneumothorax, but recently, LUS has emerged as a new bedside diagnostic tool for diagnosis of pneumothorax, and various studies have proven its utility in emergency department,[44] critical care[32,45] and for intraoperative diagnosis of pneumothorax.[28] Sensitivity and specificity of LUS in the diagnosis of pneumothorax had been reported to vary from 86-100% to 97-100%, respectively, whereas 28-75% and 100% reported for chest X-ray.[44,46] LUS can be used to quantify pneumothorax and to evaluate its extension for planning the therapeutic modality (conservative management vs. intercostal drainage [ICD] insertion), especially in clinical

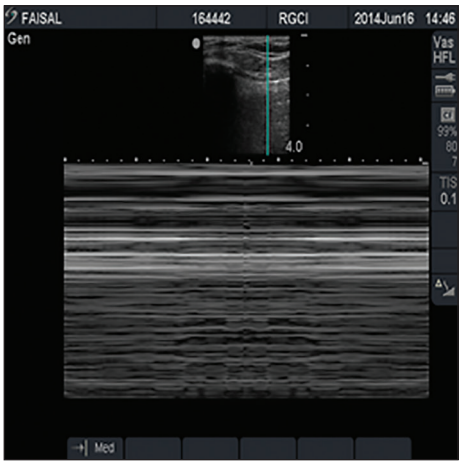

Figure 6: "Stratosphere sign" of pneumothorax

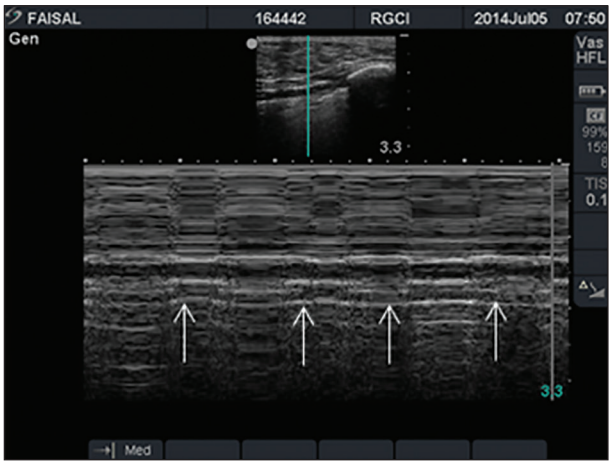

Figure 7: Lung pulse (arrows shows transmitted heart pulsations)

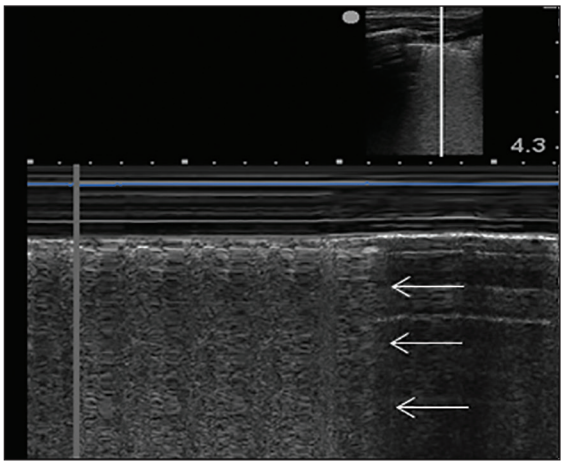

Figure 8: Lung point (arrows show interface of normal lung from pneumothorax)

scenario where bedside computed tomography (CT) scan is not a feasible option. Serial LUS scans can be used to evaluate changes in volume and extension of pneumothorax, and hence aids in decision making for removal of ICD.

Atelectasis

Atelectasis is one of the frequently encountered postoperative pulmonary complication (PPC), with wide spectrum of causes related to perioperative events. General anesthesia causes atelectasis within the first few minutes of induction in the most dependent part of lung.[47,48] Approximately, 15-20% of lung tissue near diaphragm or about 10% of total lung mass in supine posture may develop atelectasis during surgery, which may extend up to 50% of lung tissue in open heart surgery.[49]

Lung Semiology of Atelectasis

Scanning for atelectasis should start by placing the probe on lateral and inferior chest longitudinally, eventually should move anteriorly in a supine posture, to outline the extent of atelectasis. Sensitivity and specificity of LUS to detect atelectasis is 93% and 100%, respectively.[34] The absence of lung sliding with lung pulse and standstill cupola (absence of lung expansion) are the early signs of atelectasis.[50] With progressive absorption of air, there is a loss of volume leading to a hypoechoic pattern known as static air bronchogram (late sign).[50] Static air bronchogram is the most valuable sign to diagnose atelectasis and to differentiate from consolidation. Air trapped in bronchus of consolidated lung, appears either linear or lentil sized punctiform image, produces centrifugal inspiratory movement (dynamic bronchogram), and is pathognomonic of nonretractile consolidation.[51]

Clinical Application

Postoperative atelectasis, a self-limiting lung aberration, can progress to a critical level in high-risk patients. Initial presentation is hypoxemia, which can even progress to pneumonia as a continuum of intraoperative atelectasis.[52,53] Mild to moderate perioperative atelectasis usually occurs in nearly half of elective surgical patients, approximately 20% patients may develop severe atelectasis (oxygen saturation <81% up to 5 min) intraoperatively[54] and 13% in the Postanesthesia Care Unit.[55] The frequency of PPC were comparable to cardiac complications in patients undergoing abdominal surgeries (9.6% vs. 5.7%, respectively)[56] and was associated with increased length of hospital stay, increased cost of treatment, and approximately one-fourth of mortality within 6 days of surgery.[52]

Conventional chest radiography does not detect minimal atelectasis in the early postoperative period unless it becomes massive.[57] CT scan is a gold standard tool to detect minimal atelectasis, but unfeasible in the operation theater,[58,59] LUS is a reliable, real-time alternative tool to detect and review the progression of atelectasis. Apart from its diagnostic use, it can also help in the evaluation of the effectiveness of therapeutic measures taken for its prevention.[60]

Pleural Effusion

A pleural effusion is a manifestation of various diseases, commonly associated with respiratory and nonrespiratory pathology. Pleural effusion can be asymptomatic to full blown respiratory failure, depending on the amount of effusion. Since, the sentinel work of Joyner *et al*.[10] for diagnosis and assessment of pleural effusion in 1967, LUS as a diagnostic modality is underutilized, probably due to more inclination of clinicians toward chest radiography[3] and faith in accuracy of CT scan. Real-time ultrasonography offers more effectual and expedient diagnosis of pleural effusion in the supine position than traditional radiography,[61] with comparable diagnostic accuracy to CT scan.[62]

Methodology and Semiology of Pleural Effusion on Lung Ultrasound

In supine posture, USG probe should be placed longitudinally on the inferior chest near diaphragm in mid or posterior axillary line. Sizeable effusion can be easily visualized, but the patient can be further scanned posteriorly in supine position or in dependent posture. In accordance to gravitational principle, scanning should start with localization of diaphragm and looking for a pattern of pleural effusion, the probe should then move anterior and cephalic to outline the extent of effusion. The sonographic pattern of pleural effusion varies depending on consistency of effusion, and can be subclassified from anechoic in transudate to echoic, complex nonseptated, complex septate, or homogenous in exudates, empyema or postoperative organized clots.[63] Pleural effusion is confined by four boundaries formed superiorly by pleural line (parietal pleura), inferiorly by smooth and regular lung line (visceral pleura) and laterally by upper and lower rib in the form of a sharp, that's why it is also known as "Sharp" sign [Figure 9]. "Sinusoidal sign" is a dynamic sign, which depicts sinusoidal movement on M-mode reflecting the compressibility and distensibility of effusion with respiration [Figure 10]. The presence of these two signs has 97% diagnostic specificity.[62] Compared to CT scan as standard diagnostic modality, sensitivity, and specificity of ultrasound is 93% in detecting the minimal pleura effusion.[3]

Clinical Implications

LUS provides a prompt and visual diagnosis of pleural effusion in several perioperative clinical scenarios.[64] LUS has more advanced and better proficiency in quantifying the volume of pleural effusion, describing its nature, and locating the area for thoracocentesis as compared to radiograph. Volume up to 525 ml can be missed on traditional radiography as false positive results can be produced.[65]

Massive to large symptomatic pleural effusions with compromised pulmonary functions are treated preoperatively. In patients with moderate pleural effusion and compromised cardiac reserve, dilemma persists regarding their preoperative optimization. ICD insertion before surgery is still a debatable issue. Asymptomatic patients with more than 1 L of effusion, have to be clinically assessed by positioning them in lateral decubitus posture, on the side opposite to effusion, worsening of preexisting dyspnea or new onset of dyspnea, warrants chest drain insertion preoperatively.[66] Radiologists rather recommend an ultrasound to quantify the volume and the need of chest drain. To overcome such dubious situations, intraoperative LUS can be decisive for further management. Fifty percent of patients will not require chest drain if the inspiratory expansion of the interpleural space is ≥15 mm on LUS.[13] Correlation of clinical test with LUS makes anesthetist more decisive regarding the placement of preoperative chest drain, intraoperative lung recruitment strategy and need for postoperative ventilator support.

The sinusoidal sign also predicts the safe removal of chest drains when the interpleural expansion is more than 15 mm with inspiration in association with stable hemodynamic parameters. Hemothorax and empyema are echoic and can be septated, nonseptated, or organized. It requires precise chest drain positioning for optimal drainage. Real-time sonography not only increases the success rate to place proper drain but also prevents procedure related complications or re-explorations.[67] LUS can also be used to check the patency of chest drain. When the lung line approximates pleural line it indicates near complete lung expansion, but with nonapproximating lung line to pleural line and static air column, suggests drain blockage and warrants chest drain to be changed.

Intraoperative Desaturation

There are a number of causes of intraoperative desaturation, which requires early recognition and prompt management to prevent any catastrophe. Depending on criteria used to define desaturation, heterogeneity of sample, demographics of patients, anesthesia equipment's error, and complexity of surgical procedures, the incidence of intraoperative desaturation varies from 0.5% to 2.74%, whereas postoperative desaturation varies from 0.32% to 55%.[68] Probability of intraoperative desaturation is maximum at maintenance (or induction) of general anesthesia and is accountable for approximately 50% of all intraoperative desaturations.[69]

Runciman *et al.* in 1993 applied checklist with mnemonic "COVER ABCD — A SWIFT" for intraoperative crisis management for desaturation by analysis of 2000 incidents reports. Of all incidents "COVER" would diagnose and correct in the 60% of cases.[70]

Szekely *et al.* in 2005 re-evaluated the algorithm's role in crisis management and concluded that "COVER" includes approximately 41% of all causes of intraoperative desaturation, whereas ABCD includes approximately 48% of all causes of intraoperative desaturation, remaining 11% does not come

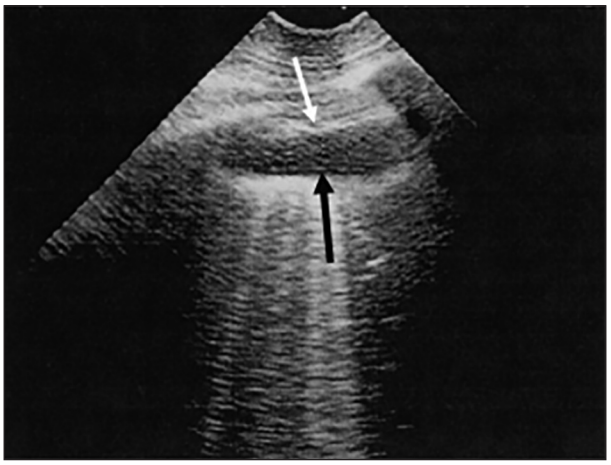

Figure 9: "Sharp Sign" (white arrow shows parietal pleura and black arrow visceral pleura, in between two are pleural effusion)

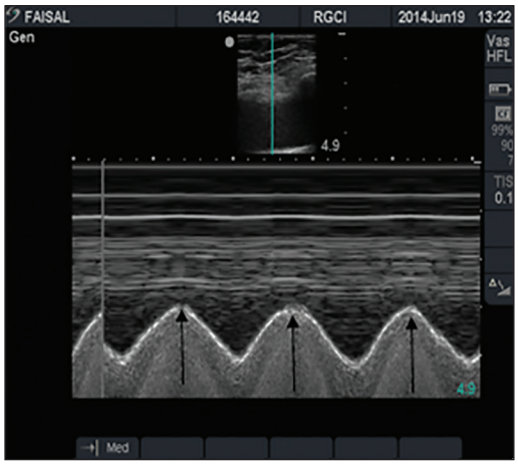

Figure 10: Sinusoidal sign (on M-Mode arrow shows the approximation of visceral pleura to parietal pleura with inspiration)

under either of the category. Fifth of these desaturations were due to endobronchial intubations and were late to diagnose.[69]

Various causes of desaturation have been discussed previously and can be diagnosed with the help of LUS by stepwise use of "BLUE" protocol given by Lichtenstein.[36] There are various measures to confirm proper endotracheal intubation; some of the traditionally used are bilateral chest movement, five point auscultation, tidal volume loops, and endotracheal tube cuff maneuvers.[71] Confirmation of tube placement with $EtCO_2$ is among the most reliable method, but still 7% false negative failure rate (tube in trachea but capnography indicates esophageal intubation) and 3% false positive rate (tube in esophagus but capnography indicates tracheal intubation) was reported during intraoperative period.[72] Fiberoptic bronchoscopy remains the gold standard for confirmation of proper tube placement.[73]

Endobronchial intubation or dislodgement of the endotracheal tube can be easily identified on LUS, and can be decisive in ruling out these as a cause of acute desaturation. Bilateral lung sliding is highly specific and indicates the correct tube placement and when lung sliding is inconclusive, other signs can be applied. In order to diagnose the causes of intraoperative desaturation, the first sign to look for is lung sliding, followed by an assessment of other lung signs. Diagnosis of other causes of acute desaturation (pulmonary edema, pneumothorax, bronchospasm, or pulmonary embolism) can be elucidated according to Table 3.

If echocardiography (for cardiac assessment) is incorporated with LUS, the source behind most of the acute desaturations could be clarified. LUS according to BLUE protocol exhibits high concordance with CT scan[36] and radiography[3] for schematic diagnosis of acute intraoperative desaturation, it can be easily repeated whenever required and is informative regarding the progression or regression of diagnosed etiology.

Table 3: Intraoperative diagnosis of desaturation by LUS

Causes	Lung signs	
	Present	Absent
Pneumothorax	Lung point	Lung sliding, B-lines, lung pulse
Endobronchial intubation	Lung pulse in opposite lung	Lung sliding, lung point both in opposite lung
Bronchospasm	Lung sliding,	Lung pulse, lung point, B-lines
Atelectasis without pleural effusion	Lung sliding, lung pulse	Lung point
Pulmonary edema	B-lines, lung sliding	Lung pulse, lung point
Pulmonary embolism	Lung sliding, A-profile	Lung pulse, lung point, B-lines

Conclusion

LUS has already established its utility in intensive care and emergency situations. After reviewing in detail the shortcomings of standard methods still being used and the scope of LUS in intraoperative anesthetic management, it is clear that LUS is an indispensible tool. In modern anesthesia practice incorporation of LUS can help the clinicians to manage critical situation swiftly in real-time.

Financial support and sponsorship
Nil.

Conflicts of interest
There are no conflicts of interest.

References

1. Buzzas GR, Kern SJ, Smith RS, Harrison PB, Helmer SD, Reed JA. A comparison of sonographic examinations for trauma performed by surgeons and radiologists. J Trauma 1998;44:604-6.
2. Smith RS, Kern SJ, Fry WR, Helmer SD. Institutional learning curve of surgeon-performed trauma ultrasound. Arch Surg 1998;133:530-5.
3. Lichtenstein D, Goldstein I, Mourgeon E, Cluzel P, Grenier P, Rouby JJ. Comparative diagnostic performances of auscultation, chest radiography, and lung ultrasonography in acute respiratory distress syndrome. Anesthesiology 2004;100:9-15.
4. Greenbaum DM, Marschall KE. The value of routine daily chest x-rays in intubated patients in the medical intensive care unit. Crit Care Med 1982;10:29-30.
5. Janower ML, Jennas-Nocera Z, Mukai J. Utility and efficacy of portable chest radiographs. AJR Am J Roentgenol 1984;142:265-7.
6. Ivatury RR, Sugerman HJ. Chest radiograph or computed tomography in the intensive care unit? Crit Care Med 2000;28:1234-5.
7. Lichtenstein D, Axler O. Intensive use of general ultrasound in the intensive care unit. Prospective study of 150 consecutive patients. Intensive Care Med 1993;19:353-5.
8. Langevin P. Piezoelectric Signaling Apparatus. U.S. Patent 2,248,870, Issued July 8, 1941.
9. Dussik KT. On the possibility of using ultrasound waves as a diagnostic aid. Neurol Psychiatr 1942;174:153-68.
10. Joyner CR Jr, Herman RJ, Reid JM. Reflected ultrasound in the detection and localization of pleural effusion. JAMA 1967;200:399-402.
11. La Grange P, Foster PA, Pretorius LK. Application of the Doppler ultrasound bloodflow detector in supraclavicular brachial plexus block. Br J Anaesth 1978;50:965-7.
12. Lichtenstein D. Lung ultrasound in the critically ill. In: Yearbook of Intensive Care and Emergency Medicine. Heidelberg: Springer; 2004. p. 625-44.
13. Lichtenstein DA. Ultrasound in the management of thoracic disease. Crit Care Med 2007;35 5(Suppl):S250-61.
14. Picano E, Frassi F, Agricola E, Gligorova S, Gargani L, Mottola G. Ultrasound lung comets: A clinically useful sign of extravascular lung water. J Am Soc Echocardiogr 2006;19:356-63.
15. Jambrik Z, Monti S, Coppola V, Agricola E, Mottola G, Miniati M, *et al.* Usefulness of ultrasound lung comets as a nonradiologic sign of extravascular lung water. Am J Cardiol 2004;93:1265-70.
16. Volpicelli G, Mussa A, Garofalo G, Cardinale L, Casoli G, Perotto F, *et al.* Bedside lung ultrasound in the assessment of alveolar-interstitial syndrome. Am J Emerg Med 2006;24:689-96.
17. Volpicelli G, Elbarbary M, Blaivas M, Lichtenstein DA, Mathis G, Kirkpatrick AW, *et al.* International evidence-based

recommendations for point-of-care lung ultrasound. Intensive Care Med 2012;38:577-91.
18. Arieff AI. Fatal postoperative pulmonary edema: Pathogenesis and literature review. Chest 1999;115:1371-7.
19. Cibinel GA, Casoli G, Elia F, Padoan M, Pivetta E, Lupia E, *et al.* Diagnostic accuracy and reproducibility of pleural and lung ultrasound in discriminating cardiogenic causes of acute dyspnea in the emergency department. Intern Emerg Med 2012;7:65-70.
20. Enghard P, Rademacher S, Nee J, Hasper D, Engert U, Jörres A, *et al.* Simplified lung ultrasound protocol shows excellent prediction of extravascular lung water in ventilated intensive care patients. Crit Care 2015;19:36.
21. Agricola E, Bove T, Oppizzi M, Marino G, Zangrillo A, Margonato A, *et al.* Ultrasound comet-tail images: A marker of pulmonary edema: A comparative study with wedge pressure and extravascular lung water. Chest 2005;127:1690-5.
22. Lichtenstein D, Mezière G. A lung ultrasound sign allowing bedside distinction between pulmonary edema and COPD: The comet-tail artifact. Intensive Care Med 1998;24:1331-4.
23. Lichtenstein D, Mézière G, Biderman P, Gepner A, Barré O. The comet-tail artifact. An ultrasound sign of alveolar-interstitial syndrome. Am J Respir Crit Care Med 1997;156:1640-6.
24. Gargani L. Lung ultrasound: A new tool for the cardiologist. Cardiovasc Ultrasound 2011;9:6.
25. Corcoran T, Rhodes JE, Clarke S, Myles PS, Ho KM. Perioperative fluid management strategies in major surgery: A stratified meta-analysis. Anesth Analg 2012;114:640-51.
26. National Heart, Lung, and Blood Institute Acute Respiratory Distress Syndrome (ARDS) Clinical Trials Network, Wheeler AP, Bernard GR, Thompson BT, *et al.* Pulmonary-artery versus central venous catheter to guide treatment of acute lung injury. N Engl J Med 2006;354:2213-24.
27. Cheung AT, Savino JS, Weiss SJ, Aukburg SJ, Berlin JA. Echocardiographic and hemodynamic indexes of left ventricular preload in patients with normal and abnormal ventricular function. Anesthesiology 1994;81:376-87.
28. Ueda K, Ahmed W, Ross AF. Intraoperative pneumothorax identified with transthoracic ultrasound. Anesthesiology 2011;115:653-5.
29. Soldati G, Testa A, Pignataro G, Portale G, Biasucci DG, Leone A, *et al*. The ultrasonographic deep sulcus sign in traumatic pneumothorax. Ultrasound Med Biol 2006;32:1157-63.
30. Ball CG, Kirkpatrick AW, Laupland KB, Fox DL, Litvinchuk S, Dyer DM, *et al.* Factors related to the failure of radiographic recognition of occult posttraumatic pneumothoraces. Am J Surg 2005;189:541-6.
31. Tocino IM, Miller MH, Fairfax WR. Distribution of pneumothorax in the supine and semirecumbent critically ill adult. AJR Am J Roentgenol 1985;144:901-5.
32. Lichtenstein DA, Menu Y. A bedside ultrasound sign ruling out pneumothorax in the critically ill. Lung sliding. Chest 1995;108: 1345-8.
33. Monti JD, Younggren B, Blankenship R. Ultrasound detection of pneumothorax with minimally trained sonographers: A preliminary study. J Spec Oper Med 2009;9:43-6.
34. Lichtenstein DA, Lascols N, Prin S, Mezière G. The "lung pulse": An early ultrasound sign of complete atelectasis. Intensive Care Med 2003;29:2187-92.
35. Lichtenstein D, Mezière G, Biderman P, Gepner A. The "lung point": An ultrasound sign specific to pneumothorax. Intensive Care Med 2000;26:1434-40.
36. Lichtenstein DA, Mezière GA. Relevance of lung ultrasound in the diagnosis of acute respiratory failure: The BLUE protocol. Chest 2008;134:117-25.
37. Cunningham J, Kirkpatrick AW, Nicolaou S, Liu D, Hamilton DR, Lawless B, *et al.* Enhanced recognition of "lung sliding" with power color Doppler imaging in the diagnosis of pneumothorax. J Trauma 2002;52:769-71.
38. Lichtenstein D, Mezière G, Biderman P, Gepner A. The comet-tail artifact: An ultrasound sign ruling out pneumothorax. Intensive Care Med 1999;25:383-8.
39. Copetti R, Soldati G, Copetti P. Chest sonography: A useful tool to differentiate acute cardiogenic pulmonary edema from acute respiratory distress syndrome. Cardiovasc Ultrasound 2008; 6:16.
40. Gillman LM, Alkadi A, Kirkpatrick AW. The "pseudo-lung point" sign: All focal respiratory coupled alternating pleural patterns are not diagnostic of a pneumothorax. J Trauma 2009;67:672-3.
41. Volpicelli G. Sonographic diagnosis of pneumothorax. Intensive Care Med 2011;37:224-32.
42. Prystowsky JB, Jericho BG, Epstein HM. Spontaneous bilateral pneumothorax — complication of laparoscopic cholecystectomy. Surgery 1993;114:988-92.
43. Steier M, Ching N, Roberts EB, Nealon TF Jr. Pneumothorax complicating continuous ventilatory support. Surv Anesthesiol 1974;18:480.
44. Wilkerson RG, Stone MB. Sensitivity of bedside ultrasound and supine anteroposterior chest radiographs for the identification of pneumothorax after blunt trauma. Acad Emerg Med 2010;17: 11-7.
45. Bouhemad B, Zhang M, Lu Q, Rouby JJ. Clinical review: Bedside lung ultrasound in critical care practice. Crit Care 2007;11:205.
46. Rowan KR, Kirkpatrick AW, Liu D, Forkheim KE, Mayo JR, Nicolaou S. Traumatic pneumothorax detection with thoracic US: Correlation with chest radiography and CT — initial experience. Radiology 2002;225:210-4.
47. Loring SH, Butler JP. Gas exchange in body cavities. In: Farhi LE, Tenney SM, editors. Handbook of Physiology. The Respiratory System. Gas Exchange. Vol. 4. Sec. 3. Bethesda, Maryland: American Physiology Society; 1987. p. 283-95.
48. Lundquist H, Hedenstierna G, Strandberg A, Tokics L, Brismar B. CT-assessment of dependent lung densities in man during general anaesthesia. Acta Radiol 1995;36:626-32.
49. Tenling A, Hachenberg T, Tydén H, Wegenius G, Hedenstierna G. Atelectasis and gas exchange after cardiac surgery. Anesthesiology 1998;89:371-8.
50. Lichtenstein D, Mezière G, Seitz J. The dynamic air bronchogram. A lung ultrasound sign of alveolar consolidation ruling out atelectasis. Chest 2009;135:1421-5.
51. Volpicelli G, Silva F, Radeos M. Real-time lung ultrasound for the diagnosis of alveolar consolidation and interstitial syndrome in the emergency department. Eur J Emerg Med 2010;17:63-72.
52. Brooks-Brunn JA. Postoperative atelectasis and pneumonia. Heart Lung 1995;24:94-115.
53. Brooks-Brunn JA. Predictors of postoperative pulmonary complications following abdominal surgery. Chest 1997;111:564-71.
54. Moller JT, Johannessen NW, Berg H, Espersen K, Larsen LE. Hypoxaemia during anaesthesia — An observer study. Br J Anaesth 1991;66:437-44.
55. Møller JT. Anesthesia related hypoxemia. The effect of pulse oximetry monitoring on perioperative events and postoperative complications. Dan Med Bull 1994;41:489-500.
56. Lawrence VA, Hilsenbeck SG, Mulrow CD, Dhanda R, Sapp J, Page CP. Incidence and hospital stay for cardiac and pulmonary complications after abdominal surgery. J Gen Intern Med 1995;10:671-8.
57. Ashizawa K, Hayashi K, Aso N, Minami K. Lobar atelectasis: Diagnostic pitfalls on chest radiography. Br J Radiol 2001;74:89-97.
58. Gunnarsson L, Strandberg Å, Brismar B, Tokics L, Lundquist H, Hedenstierna G. "Atelectasis and gas exchange impairment during enflurane/nitrous oxide anaesthesia." Acta Anaesthesiologica

Scandinavica 1989;33:629-37.
59. Hachenberg T, Lundquist H, Tokics L, Brismar B, Hedenstierna G. Analysis of lung density by computed tomography before and during general anaesthesia. Acta Anaesthesiol Scand 1993;37:549-55.
60. Weinberg B, Diakoumakis EE, Kass EG, Seife B, Zvi ZB. The air bronchogram: Sonographic demonstration. AJR Am J Roentgenol 1986;147:593-5.
61. Hirsch JH, Rogers JV, Mack LA. Real-time sonography of pleural opacities. AJR Am J Roentgenol 1981;136:297-301.
62. Lichtenstein D, Hulot JS, Rabiller A, Tostivint I, Mezière G. Feasibility and safety of ultrasound-aided thoracentesis in mechanically ventilated patients. Intensive Care Med 1999;25:955-8.
63. Yang PC, Luh KT, Chang DB, Wu HD, Yu CJ, Kuo SH. Value of sonography in determining the nature of pleural effusion: Analysis of 320 cases. AJR Am J Roentgenol 1992;159:29-33.
64. Mattison LE, Coppage L, Alderman DF, Herlong JO, Sahn SA. Pleural effusions in the medical ICU: Prevalence, causes, and clinical implications. Chest 1997;111:1018-23.
65. Colins JD, Burwell D, Furmanski S, Lorber P, Steckel RJ. Minimal detectable pleural effusions. A roentgen pathology model. Radiology 1972;105:51-3.
66. Lee BB, Critchley LA. Pleural effusions and anaesthesia. Anaesthesia 1994;49:178-9.
67. Mayo PH, Goltz HR, Tafreshi M, Doelken P. Safety of ultrasound-guided thoracentesis in patients receiving mechanical ventilation. Chest 2004;125:1059-62.
68. Raksakietisak M, Chinachoti T, Vudhikamraksa S, Svastdi-Xuto O, Surachetpong S. Perioperative desaturation: Incidence, causes, management and outcome. J Med Assoc Thai 2002;85(Suppl 3): S980-6.
69. Szekely SM, Runciman WB, Webb RK, Ludbrook GL. Crisis management during anaesthesia: Desaturation. Qual Saf Health Care 2005;14:e6.
70. Runciman WB, Webb RK, Klepper ID, Lee R, Williamson JA, Barker L. The Australian Incident Monitoring Study. Crisis management — validation of an algorithm by analysis of 2000 incident reports. Anaesth Intensive Care 1993;21:579-92.
71. Birmingham PK, Cheney FW, Ward RJ. Esophageal intubation: A review of detection techniques. Anesth Analg 1986;65:886-91.
72. Li J. Capnography alone is imperfect for endotracheal tube placement confirmation during emergency intubation. J Emerg Med 2001;20:223-9.
73. Smith GB, Hirsch NP, Ehrenwerth J. Placement of double-lumen endobronchial tubes. Correlation between clinical impressions and bronchoscopic findings. Br J Anaesth 1986;58:1317-20.

Conference Calendar July 2016

Name of conference	Dates	Venue	Name of organising Secretary with contact details
32nd Annual South Zone ISA Conference 2016 and 32nd Annual Karnataka State Conference ISACON South 2016	August 18th-21st 2016	KLES Centenary Convention Centre, JNMC Campus, Belgaum, India	Dr. Manjunath C. Patil Organizing Secretary, ISACON SOUTH - 2016. Department of Anaesthesiology, KLE'S Dr. Prabhakar Kore Hospital and MRC, Belagavi - 590 010, Karnataka. Email ID: isaconsouth2016@gmail.com Contact No:+919743110637, 0831-2551292/2551293
World Congress of Ophthalmic Anaesthesia, (WCOA 2016)	September 2nd-4th, 2016	ITC Grand Chola, Chennai	Organised by: Sankara Netralaya Chennai Sept. Dr. V. V. Jaichandran Contact: +91 9884096860, wcoa2016@gmail.com Website: pwww.sankaranethralaya.org/wcoa2016
ISACON TAMILNADU – 2016 Annual State Conference of ISA Tamil Nadu State Chapter	September 3rd-4th, 2016	Curtalam, Tirunalveli	Org Secretary: Dr. A. Balakrishnan Mobile No.: +91-9443138800 Email: nelcon2016@gmail.com Website: http://www.isacontamilnadu2016.com/
18th Annual Rajasthan State Conference of Indian Society of Anaesthesiologists 2016 ISACONRAJASTHAN2016	September 3rd-4th, 2016	Government Medical College Auditorium, Kota, India	Dr. Mukesh Somvanshi Dr. Usha Daria 91-9461182793 +91-9414286314 E-mail isaconraj2016@gmail.com www.isaconrajasthan2016.com