



Analysis of the curative effect and prognostic factors in patients with scapular fracture with surgical indications after conservative treatment: a case series and clinical outcomes

Xi Chen^{1,2#}, Ya-Dian Deng^{3#}, Xu-Sheng Qiu⁴, Yi-Xin Chen^{1,4}, Zi-Tao Zhang^{1,4}

¹Department of Orthopedic Surgery, Nanjing Drum Tower Hospital Clinical College of Nanjing University of Chinese Medicine, Nanjing, China; ²Department of Shoulder and Elbow Surgery, Luoyang Orthopedic Hospital of Henan Province (Orthopedic Hospital of Henan Province), Zhengzhou, China; ³Department of Emergency, The First Affiliated Hospital, Henan Traditional Chinese Medicine University, Zhengzhou, China; ⁴Department of Orthopedic Surgery, Nanjing Drum Tower Hospital, The Affiliated Hospital of Nanjing University Medical School, Nanjing, China

Contributions: (I) Conception and design: ZT Zhang, YX Chen; (II) Administrative support: YX Chen, ZT Zhang; (III) Provision of study materials or patients: XS Qiu, ZT Zhang; (IV) Collection and assembly of data: X Chen, YD Deng; (V) Data analysis and interpretation: X Chen, YD Deng; (VI) Manuscript writing: All authors; (VII) Final approval of manuscript: All authors.

#These authors contributed equally to this work and should be considered as co-first authors.

Correspondence to: Zi-Tao Zhang, PhD; Yi-Xin Chen, PhD. Department of Orthopedic Surgery, Nanjing Drum Tower Hospital Clinical College of Nanjing University of Chinese Medicine, Zhongshan Road No. 321, Gulou District, Nanjing 210008, China; Department of Orthopedic Surgery, Nanjing Drum Tower Hospital, The Affiliated Hospital of Nanjing University Medical School, Nanjing 210008, China. Email: nanjingzhangzitao@126.com; Chenyixin93@126.com.

Background: The choice of treatment for scapular fractures is a topic worth discussing. The type of scapular fracture is often complex, and more and more scholars prefer surgical treatment to obtain better shoulder joint function. In addition, because of the rich blood supply and muscles of the scapula, some scholars believe that simple suspension can also achieve satisfactory clinical effects. The aim of this study was to investigate the curative effect and prognostic factors of patients with scapular fracture with indications for surgery after receiving conservative treatment.

Methods: Patients with scapular fracture who did not receive surgical treatment from July 2016 to May 2021 were recruited from the orthopedic trauma database of Nanjing Gulou Hospital, and the data from patients with indications for surgery were screened out for a retrospective analysis. The data were obtained from the database of orthopaedic trauma patients in Nanjing Drum Tower Hospital. The relevant data were recorded during telephone and video follow-up visits. Linear regression was used to analyze the factors associated with disabilities of the arm, shoulder and hand (DASH) score after receiving conservative treatment.

Results: A total of 21 patients were included in the final statistical analysis. All patients were followed up for 31.0±20.3 (range, 6–63) months, aged 52.9±12.7 (range, 27–71) years. All fractures had clinical healing with a 100% recovery satisfaction rate. Outcome measures of efficacy [both DASH scores and visual analogue scale (VAS) scores], were correlated with whether the fracture involved the superior border of the scapular, were not associated with the following variables: age ($P=0.18$), Injury Severity Score (ISS) score ($P=0.10$), the glenopolar angle (GPA) value ($P=0.76$), superior shoulder suspensory complex (SSSC) injury ($P=0.82$), and glenoid fracture ($P=0.84$). The range of motion of the affected shoulder was significantly reduced compared to the healthy shoulder ($P<0.01$), but the range of forward flexion and elevation was not significantly different from that of the healthy shoulder ($P>0.05$). Patients with fractures not involving the superior border of the scapula had a much lower range of motion in the affected shoulder than in the healthy shoulder during abduction ($P<0.05$).

Conclusions: The range of surgical indications for scapular fractures with scapular fractures involving the lower margin of the scapular can be appropriately narrowed. Some patients with scapular fracture who have surgical indications can regain satisfactory shoulder function after receiving conservative treatment.

Keywords: Scapular fracture; conservative treatment; surgical indications; fracture healing; shoulder function

Submitted Mar 06, 2023. Accepted for publication Jun 05, 2023. Published online Jun 13, 2023.

doi: 10.21037/qims-23-278

View this article at: <https://dx.doi.org/10.21037/qims-23-278>

Introduction

Injuries to the scapular are rare due to the rich muscle coverage of this area, and scapular fractures account for only about 0.5% of all fractures (1). Among scapular fractures, extra-articular fractures are the most common, accounting for 62% to 98% of all such cases (2,3). Scapular fractures are often caused by high-energy trauma and are accompanied by a variety of injuries (4). As a result of the insufficient bone mass, complex three-dimensional anatomy, and difficult surgical exposure of the scapula, open reduction and internal fixation are especially challenging and many complications can develop (5). Therefore, it is a matter of urgency that effective treatment options for patients with scapular fractures are explored.

With the development of orthopedic surgical techniques and the improvements of implants, the number of clinical studies on surgery for scapular fracture has gradually increased. In several studies, patients with scapular fractures who received surgery had positive outcomes (3,6); however, there are still controversies about the surgical indications for scapular fractures in clinical practice. In the clinical management of scapular fractures, there is a lack of standardized criteria for surgical margins. Moreover, the most immediate symptom after injury, such as disturbance of consciousness, difficulty breathing, is the primary emphasis of clinical and nursing attention in patients with multiple trauma who are in an acute condition. In such cases, the initial diagnosis and treatment of scapular fractures is often delayed or neglected (4).

Life-improvement and a positive therapeutic effect are possible for patients after conservative treatment for scapular fracture. For example, Dimitroulias *et al.* reported that conservative treatment had a satisfactory effect, and the severity of Injury Severity Score (ISS) and the presence of rib fractures adversely affect the clinical outcome (7). Further, a systematic review of 1,237 patients with scapular

fractures in 32 studies performed by Kannan *et al.* showed that patients with scapular neck fractures displaced by <10 mm had satisfactory outcomes following conservative treatment (8).

Conservative treatment has the advantage of avoiding the general risks of surgery, which include pain, infection, brachial plexus palsy, and hematoma, as well as risks associated with the Judet posterior approach (9,10). Moreover, some scapular fracture patients with surgical indications are also more inclined to select conservative treatment due to various economic, conceptual, and psychological considerations. The indications for operative treatment of displaced fractures of the glenoid fossa (9) are well accepted. The operative indications for extra-articular scapular fractures remain controversial. However, the efficacy and influencing factors of conservative treatment in patients with scapular fractures who have surgical indications are unknown. This study retrospectively analyzed the factors associated with scapular fracture in patients with surgical indications but without surgical treatment, in an attempt to find the factors that might influence the prognosis of scapular fracture.

In this study, we retrospectively analyzed the efficacy and treatment satisfaction of scapular fracture patients with surgical indications who received conservative treatment in Nanjing Drum Tower Hospital between July 2016 and May 2021, and analyzed the factors associated with disabilities of the arm, shoulder and hand (DASH). Taking surgical risks, postoperative rehabilitation, and patient needs into account, we reconsidered the limits of surgical indications in the clinical treatment of scapular fractures and whether or not some patients with surgical indications could achieve a more satisfactory therapeutic effect with conservative treatment. We present this article in accordance with the STROBE reporting checklist (available at <https://qims.amegroups.com/article/view/10.21037/qims-23-278/rc>).

Methods

The study was conducted in accordance with the Declaration of Helsinki (as revised in 2013). The study protocol was reviewed and approved by the Ethics Committee of Nanjing Drum Tower Hospital (No. 2020-370-01), and the research was performed following the approval guidelines. Written informed consent was obtained from each participant before their inclusion in the study.

Study participants

Patients with scapular fracture who had not received surgical treatment from July 2016 to May 2021 were recruited from the orthopedic trauma database of Nanjing Drum Tower Hospital, and the data of patients with surgical indications were screened out for a retrospective analysis. Twenty-one patients with scapular fractures who were admitted to the Department of Orthopedics and Traumatology of Nanjing Drum Tower Hospital from July 2016 to May 2021 and met the inclusion and exclusion criteria were enrolled in this study. The information of the patients was retrieved using a combination of the department's database and the hospital's electronic medical record system. The retrieval time was set as "from July 2016 to May 2021" and the diagnosis as "scapular fracture".

Inclusion criteria

Imaging data were used to determine whether the patients had surgical indications. Patients meeting one or more of the following criteria were considered to have surgical indications (I): (I) intra-articular fracture displacement ≥ 4 mm; (II) joint involvement $>20\%$ to 25% ; (III) glenopolar angle (GPA) $\leq 22^\circ$; (IV) fracture angulation $\geq 45^\circ$; (V) fracture displacement of the lateral margin >20 mm, or >15 mm with angulation $>30^\circ$; and (VI) two or more injuries of superior shoulder suspensory complex (SSSC). Patients who met the above criteria for surgical indications and had not undergone scapular surgery were included in the study.

Exclusion criteria

The following patients were excluded from the study: (I) patients with severe nerve injuries (brachial plexus, cervical spinal cord, traumatic brain injury) or amputation of the upper limb; and (II) patients who had undergone scapular

surgery.

Treatment regimen

The upper limbs of all patients were immobilized with a sling for 2 weeks. Active and passive training was performed alternately from weeks 2 to 8, and active functional training was mainly performed after week 8. The regimen was adjusted based on the maximum pain level the patient was able to bear, without fixed procedures. The criteria for rehabilitation referred to the condition of healthy patients.

Follow-up

Patients were followed up by telephone and video call. The telephone follow-up included the following indicators: self-perception, recovery satisfaction, DASH score on the affected and unaffected sides, visual analogue scale (VAS) score, and information on whether the patient had returned to their pre-injury work. Due to the implications of the coronavirus disease 2019 (COVID-19) pandemic, the shoulder range of motion of the affected and unaffected sides, including the range of forward flexion, abduction, and extension, was evaluated through video call after obtaining the consent of the patients and their families.

Evaluation indicators

The GPA value, number of SSSC injuries and injury sites, AO Foundation/Orthopaedic Trauma Association (AO/OTA) fracture classification, and condition of combined injuries were collected from patients at admission. The DASH scores of the affected and unaffected sides, VAS score, and shoulder range of motion were collected at follow-up.

In adherence with the criteria described in the AO/OTA classification, fractures were classified based on the imaging data of patients. As shown in *Table 1*, different codes are set for different fractures. Using this classification system, 14 is the skeletal code of the scapula; A indicates extra-articular (including acromion, coracoid process, and scapular spine) injuries, B indicates fractures of the scapular body, and F indicates fractures involving the glenoid cavity (glenoid neck, intra-articular glenoid); the number followed by letters indicate the region of fracture (9,11,12). In addition, the imaging data could also display whether the scapular fracture involved the superior border of the scapula (the scapular spine, supraspinous fossa, acromion, and coracoid

Table 1 Surgical indications and fracture classification of patients

Surgical indications and fracture classification	Cases (n)
Surgical indications	
Intra-articular fracture displacement ≥ 4 mm	9
Joint involvement $>20\%$ to 25%	4
GPA $\leq 22^\circ$	9
Fracture angulation $\geq 45^\circ$	0
Fracture displacement of lateral margin >20 mm, or >15 mm with angulation $>30^\circ$	3
≥ 2 injuries of the SSSC	9
AO/OTA fracture classification	
Acromion fracture (14A1)	3
Coracoid fracture (14A2)	2
Fracture of the scapular body (14B1)	3
Fracture of the scapular body (14B2)	1
Fracture of the scapular body (14B3)	14
Extra-articular glenoid fracture (F1)	3
Intra-articular glenoid split fracture (F2)	8
Intra-articular glenoid comminuted fracture (F3)	0

GPA, glenopolar angle; SSSC, superior shoulder suspensory complex; AO/OTA, AO Foundation/Orthopaedic Trauma Association.

process) or involved the scapular glenoid cavity. All imaging data were analyzed and judged by two associate chief physicians, and controversial cases were determined by one chief physician after discussion.

The degree of scapular injury in patients was evaluated using the ISS score (13). The ISS scores were extracted from the department's databases. Scores range from 0 to 75, with a score ≤ 16 representing a minor injury, a score >16 and <25 representing a serious injury, and a score >25 representing a severe injury. The VAS score is commonly used to assess pain. Scores range from 0 to 10, with a score of 0 representing no pain, a score of 1 to 3 representing mild pain, 4–6 is moderate pain, and 7–10 is severe pain (14). The DASH score is a responsive, valid, and reliable scale for assessing disability of the upper limbs. A score of 0 indicates no disability and a score of 100 indicates complete disability; the higher the score, the greater the disability (15).

Statistical analysis

Statistical analyses were performed using the SPSS 26.0 software (IBM, America). Measurement data were expressed as mean \pm standard deviation, and the *t*-test was used for comparison between two groups. Count data were presented as percentages. Linear regression was adopted for analysis of correlations between DASH score and other variables in patients. A 2-sided P value of <0.05 was deemed significant.

Results

Clinical data of patients before treatment

Twenty-eight patients with scapular fracture were treated in Nanjing Drum Tower Hospital between July 2016 and May 2021. Of them, 7 patients (6 without surgical indications and 1 with craniocerebral injury) were excluded, and 21 patients with surgical indications who did not undergo scapular surgery were included in the study.

The included patients were predominantly male (18 males, 3 females), and their GPA values ranged from 12.2° to 38.1° (mean $25.4^\circ \pm 8.9^\circ$) (Figure 1). There were 9 patients with SSSC injuries, including 6 patients with 2 SSSC injuries and 3 patients with 3 SSSC injuries. In terms of the AO/OTA fracture classification, 3 patients had extra-articular scapular fractures (of the glenoid cavity), 11 patients had fractures involving the glenoid cavity (including extra-articular glenoid fractures and intra-articular glenoid split fractures), and 5 patients had fractures involving the superior border of the scapula (including acromion and coracoid fractures) (Table 1).

Combined injuries included rib fracture ($n=14$), pulmonary contusion ($n=5$), hemopneumothorax ($n=3$), closed cranio-cerebral injury ($n=6$), clavicle fracture ($n=15$), vertebral fracture ($n=7$), ulnoradial fracture ($n=2$), maxillofacial fracture ($n=5$), pelvic fracture ($n=3$), humerus fracture ($n=1$), femoral fracture ($n=4$), tibiofibula fracture ($n=3$), and ankle fracture ($n=1$) (Table 2). Notably, 20 patients presented with closed injuries, and 1 patient presented with an open fracture with a healed open wound.

Evaluation indicators and shoulder range of motion after conservative treatment

All 21 patients were successfully followed up. The follow-

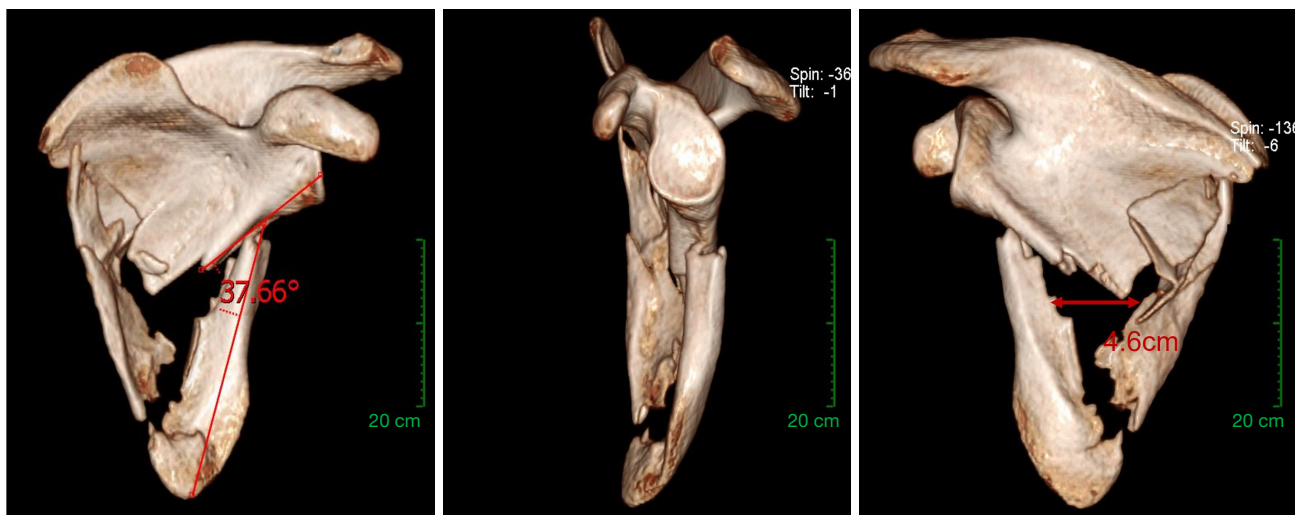

Figure 1 Type B1 fracture. The maximum displacement of the fracture is approximately 4.6 cm, the angle of the fracture is approximately 37.66°.

Table 2 Combined injuries of the patients

Combined injury	Cases, n [%]
Rib fracture	14 [67]
Pulmonary contusion	5 [24]
Hemopneumothorax	3 [14]
Closed cranio-cerebral injury	6 [29]
Clavicle fracture	15 [71]
Vertebral fracture	7 [33]
Ulnoradial fractures	2 [10]
Maxillofacial fracture	5 [24]
Pelvic fracture	3 [14]
Humerus fracture	1 [5]
Femoral fracture	4 [19]
Tibiofibula fracture	3 [14]
Ankle fracture	1 [5]

up duration was 6 to 63 (mean 31.0 ± 20.3) months, and the patients ranged in age from 27 to 71 (mean 51.9 ± 12.7) years. All the scapular fractures healed clinically after conservative treatment, and the recovery satisfaction of patients reached 100%. The mean ISS was 13.9 (range, 5–29), and the mean VAS score was 0.6 (range, 0–2). The mean DASH score on the affected and unaffected side was 9.5 (range, 0.0–56.8) and 5.0 (range, 0.0–18.2), respectively, and there was no

Table 3 Evaluation indicators of patients after conservative treatment

Evaluation indicators	Values, mean \pm SD [range] or n
Age (years)	51.9 ± 12.7 [27–71]
Follow-up duration (months)	31.0 ± 20.3 [6–63]
ISS	13.9 ± 6.9 [5–29]
DASH score (affected side)	9.5 ± 17.3 [0.0–56.8]
DASH score (unaffected side)	5.0 ± 4.9 [0.0–18.2]
VAS score	0.6 ± 0.8 [0–2]
Job change (n)	2

SD, standard deviation; ISS, injury severity score; DASH, disability of the arm, shoulder and hand; VAS, visual analogue scale.

statistically significant difference between the two sides. Of the 21 patients, 19 patients continued to engage in their pre-injury work, but 2 patients changed their jobs due to being physically unable to carry out their pre-injury work (Table 3).

Based on their imaging data, the patients were divided into a subgroup with fractures involving the superior border of the scapular and a subgroup with fractures not involving the superior border of the scapular spine. In the subgroup with involvement of the superior border of the scapular spine, the mean range of motion of the unaffected and affected side was: 133.6° and 128.2° , respectively, for forward flexion; 110.9° and 98.2° , respectively, for abduction; and 11.4° and 5.5° , respectively, for extension.

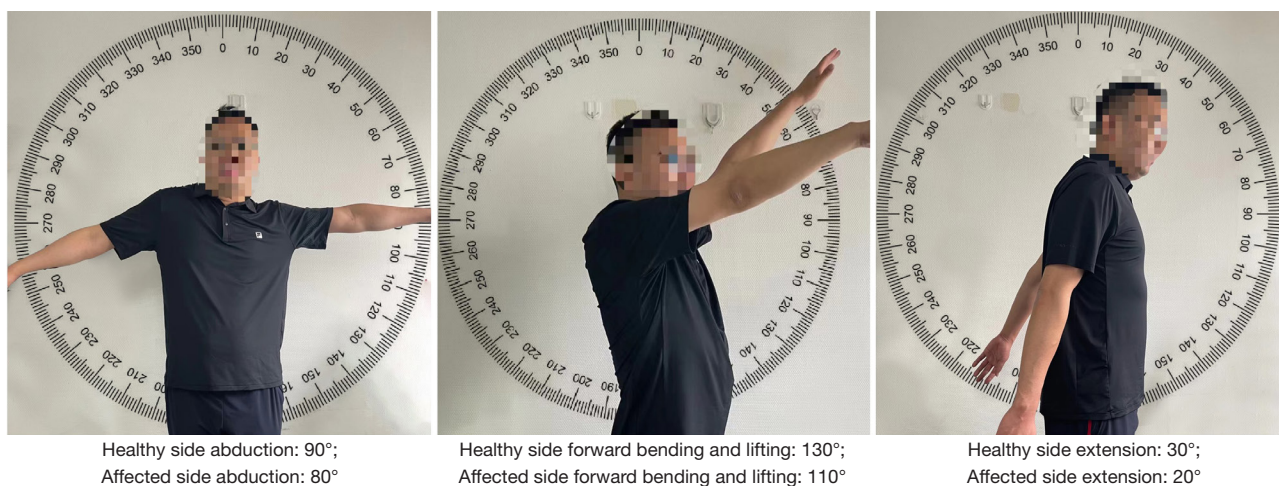


Figure 2 Motion image of a patient after follow-up. Written informed consent was obtained from the patient for publication of this image.

Table 4 Comparison of the shoulder range of motion after conservative treatment between the two groups

Shoulder movement	Subgroup with superior border of scapular spine involvement			Subgroup without superior border of scapular spine involvement		
	Unaffected side	Affected side	P	Unaffected side	Affected side	P
Forward flexion (°)			0.28			0.62
Mean	133.6	128.2		138.0	135.5	
95% CI	127.6–139.7	119.0–137.4		129.7–146.3	127.9–143.1	
Abduction (°)			0.02			0.24
Mean	110.9	98.2		117.0	113.5	
95% CI	108.4–113.4	87.5–108.8		113.2–120.8	109.0–118.0	
Extension (°)			<0.01			<0.01
Mean	11.4	5.5		17.0	8.5	
95% CI	7.8–14.8	4.4–6.5		14.0–20.0	5.6–11.4	

CI, confidence interval.

For the subgroup without involvement of the superior border of the scapula, the mean range of motion of the unaffected and affected side was: 138.0° and 135.5°, respectively, for forward flexion; 117.0° and 113.5°, respectively, for abduction; and 17.0° and 8.5°, respectively, for extension (*Figure 2*). Importantly, in the subgroup with involvement of the superior border of scapular spine, no statistically significant differences were observed in the range of motion between the unaffected and affected shoulders during forward flexion ($P>0.05$); however, during

abduction and extension, the range of motion of the affected shoulder was significantly lower than that of the unaffected shoulder ($P<0.05$). Likewise, in the subgroup without involvement of the superior border of the scapular spine, there was no statistically significant difference in the range of motion between the unaffected and affected shoulders during forward flexion and abduction ($P>0.05$); however, during extension, the range of motion of the affected shoulder was significantly reduced compared to that of the unaffected shoulder ($P<0.01$) (*Table 4*).

Table 5 Correlations of Quick Disability of the Arm, Shoulder, and Hand score with age, ISS, GPA, VAS score, SSSC, glenoid fracture, and fracture of the superior border of the scapula

Variables	r	P
Age	0.31	0.18
ISS	0.37	0.10
GPA	0.07	0.76
VAS	0.83	<0.0001
SSSC	–	0.82
Glenoid fracture	–	0.84
Fracture of the superior border of the scapula	–	0.02

ISS, injury severity score; GPA, glenopolar angle; VAS, visual analogue scale; SSSC, superior shoulder suspensory complex.

Table 6 Correlation of Quick Disability of the Arm, Shoulder, and Hand score with combined injuries

Combined injuries	P
Rib fracture	0.28
Pulmonary contusion	0.34
Hemopneumothorax	0.41
Closed cranio-cerebral injury	0.80
Clavicle fracture	0.92
Vertebral fracture	0.99
Ulnoradial fractures	0.56
Maxillofacial fracture	0.42
Pelvic fracture	0.70
Humerus fracture	0.80
Femoral fracture	0.65
Tibiofibula fracture	0.30
Ankle fracture	0.65

Correlation analysis of DASH score

Statistical analysis indicated that the DASH score after conservative treatment was not associated with the following variables: age ($P=0.18$), ISS score ($P=0.10$), GPA value ($P=0.76$), SSSC injury ($P=0.82$), and glenoid fracture ($P=0.84$). Besides, the DASH and VAS scores ($P<0.0001$) were correlated with fractures involving the superior border of the scapula ($P=0.02$) (Table 5). However, there

were no correlations between combined injuries and the DASH score (Table 6). The basic information and clinical characteristics of the patients are shown in Table 7.

Discussion

The scapula is a crucial bone that joins the upper limb to the axial skeleton. It is covered with thick muscle fibers and suspended from the chest by tendons (16). For the shoulder joint to move through its full range of motion, the glenohumeral, acromioclavicular, and scapulothoracic joints must work together. Shoulder motion requires the use of 18 separate muscles, all of which originate at or insert on the scapula. These muscles coordinate six fundamental movements of the scapula: elevation, depression, upward rotation, downward rotation, protraction, and retraction (17). The muscles encircling the scapula have the ability to absorb external forces. These forces, however, can disrupt the scapular integrity, and if they are strong enough, can cause scapular fractures. The unique anatomy of the scapula allows the fracture fragment to be encapsulated within a blood-rich muscle fiber capsule, which provides early stability to the scapula. Furthermore, the abundant muscle groups around the scapula offer plenty of power to support shoulder joint function compensation. Therefore, most scapular fractures are able to heal with early immobilization, and dysfunction brought on by healing deformities or early immobilization can be improved through staged exercise (18). In our study, the outcomes of 21 patients with scapular fractures with surgical indications after conservative treatment were retrospectively analyzed. Following conservative treatment, the VAS and return-to-work status of the patients revealed satisfactory results, and the patients also expressed satisfaction with their outcomes directly.

The structure of the superior border of the scapula includes the scapular spine, acromion, coracoid process, attached muscle tissues (including the supraspinatus, deltoid, and trapezius), and coracoacromial ligament. Among them, the coracoid process, acromion, and scapular spine are irregular protrusions of the scapula as well as attachment structures of the muscles around the shoulder joint, and their malunion affects the balance of the surrounding muscles and tendons (19,20). The stability of the humeral head anteriorly over the glenohumeral joint is significantly maintained by the coracoacromial ligament (21). Loss of shoulder mobility during lifting and abduction may result

Table 7 Patients profile and clinical characteristics

Subject	Gender	Age (years)	Surgical indications	ISS	Dominant	Superior border of scapular involvement	Return back to work	Δ DASH
1	M	57	V, VI	22	Right	No	Yes	0
2	M	51	I	19	Right	Yes	Yes	2.27
3	M	55	V	9	Right	No	Yes	4.55
4	F	63	III, VI	9	Left	No	Yes	6.82
5	M	27	I, II, VI	22	Right	Yes	Yes	6.82
6	M	52	III, VI	14	Left	No	Yes	31.82
7	M	50	III	9	Right	No	Yes	2.27
8	M	67	I, II	24	Right	Yes	Yes	6.82
9	M	50	III, VI	17	Right	Yes	Yes	0
10	M	43	III, VI	5	Right	No	Yes	0
11	M	42	III	22	Right	No	Yes	6.82
12	M	37	I, II	6	Right	Yes	Yes	0
13	M	42	V	17	Right	Yes	Yes	0
14	M	50	III, VI	5	Right	No	Yes	0
15	M	51	I, VI	6	Right	Yes	Yes	0
16	M	63	I, VI	14	Right	Yes	No	34.09
17	M	66	III	14	Right	No	Yes	6.82
18	M	70	I	9	Right	Yes	Yes	4.55
19	M	33	I	22	Right	Yes	Yes	0
20	F	71	I, II	29	Right	Yes	No	38.64
21	F	56	III	9	Right	No	Yes	2.27

Surgical indications: (I) intra-articular fracture displacement ≥ 4 mm; (II) joint involvement $>20\%$ to 25% ; (III) GPA $\leq 22^\circ$; (IV) fracture angulation $\geq 45^\circ$; (V) fracture displacement of lateral margin >20 mm, or >15 mm with angulation $>30^\circ$; (VI) ≥ 2 injuries of the SSSC. Δ DASH: the DASH score difference between the affected and unaffected sides. ISS, injury severity score; DASH, disabilities of the arm, shoulder and hand; M, male; F, female; GPA, glenopolar angle; SSSC, superior shoulder suspensory complex.

from alterations in moment of force when muscles contract (22). In this study, we found that during extension, the range of motion of the affected shoulder was reduced compared with that of the unaffected shoulder. However, there was no significant difference in the range of motion between the affected and unaffected shoulders during forward flexion or lifting. In a nutshell, after conservative treatment, the affected shoulder demonstrated normal forward flexion and lifting but its extension was restricted. In addition, we found that whether or not the fracture involved the superior border of scapular spine was related to the range of motion of the affected shoulder during abduction as well as the

DASH score after conservative treatment. Moreover, plate fixation had been performed on 15 patients with combined clavicular fractures and 1 patient with proximal humerus a proximal humerus fracture. Loss of shoulder mobility in these patients may be associated with injury to the acromioclavicular, coracoclavicular, or coracoacromial ligament, or to the rotator cuff tendon. However, the lack of preoperative magnetic resonance imaging (MRI) data made it challenging to evaluate the integrity of the tendons and ligaments.

Romero *et al.* highlighted that conservative treatment could result in malunion of scapular neck fractures in patients with severe displacement of glenoid cavity, and

that patients would have glenohumeral instability and poor long-term prognosis if their GPA $<20^\circ$ (23). This study found that after conservative treatment, none of the patients with glenoid fractures developed glenohumeral instability, and neither the presence nor the absence of glenoid fracture was associated with DASH score. Naturally, if the patient develops glenohumeral instability during treatment, we recommend open reduction and internal fixation to prevent complications such as glenohumeral dislocation after malunion. Unfortunately, there were no independent acromion or coracoid fractures in this study, which made it impossible to assess the efficacy of conservative treatment in the subgroup of patients with these fractures.

The treatment of scapular fractures should be comprehensively assessed and determined based on the mechanism of injury, imaging characteristics, fracture classification, and the actual functional needs of patients. A meta-analysis of available data performed by Limb *et al.* showed that surgical treatment of scapular fractures was not necessarily advantageous (16). Therefore, we selected patients who had surgical indications but did not receive surgical treatment as the subjects of our study. Conservative treatment was performed on patients with multiple systemic injuries and low demand for shoulder function. After conservative treatment, 19 patients returned to their pre-injury work; in these cases, the work did not require the patients to lift their hands over the top of head. Two patients who were older and had more severe injuries were unable to return to their pre-injury work. A satisfactory therapeutic effect was achieved in all cases. Importantly, conservative treatment regimens not only avoid surgical complications but also allow patients to regain satisfactory shoulder function. Nevertheless, further clinical research is required to explore the boundaries of indications for scapular fracture surgery. For a professional orthopaedic technician, it is necessary to fully weigh up the advantages and disadvantages of surgery and conservative treatment, and to avoid expanding the indications for surgery in clinical practice, increasing the pain of patients, and wasting medical resources.

There were some limitations in this study. Firstly, it was difficult to compare the outcomes of surgical and conservative treatment for scapular fractures in the study due to the lack of information on individuals who underwent surgery. Secondly, there was a lack of pre-

treatment data, such as data on the weight-bearing ability of the affected shoulder, and imaging examination data of the affected shoulder at follow-up.

Conclusions

Some patients with scapular fracture who have surgical indications can achieve satisfactory shoulder joint function following conservative treatment. However, patients with scapular fractures involving the superior border of the scapula who receive conservative treatment experience poor functional recovery of the affected shoulder. When the fracture does not accumulate at the superior border of the scapula, the indication of conservative treatment can be appropriately widened. When the fracture accumulates at the superior edge of the scapula, the surgical indications should be more strictly controlled.

Acknowledgments

Funding: This work was supported by National Natural Science Foundation of China (No. 81871762) and The Key Project supported by the Medical Science and Technology Development Foundation, Nanjing Department of Health (No. QRX17050).

Footnote

Reporting Checklist: The authors have completed the STROBE reporting checklist. Available at <https://qims.amegroups.com/article/view/10.21037/qims-23-278/rc>

Conflicts of Interest: All authors have completed the ICMJE uniform disclosure form (available at <https://qims.amegroups.com/article/view/10.21037/qims-23-278/coif>). The authors have no conflicts of interest to declare.

Ethical Statement: The authors are accountable for all aspects of the work in ensuring that questions related to the accuracy or integrity of any part of the work are appropriately investigated and resolved. The study was conducted in accordance with the Declaration of Helsinki (as revised in 2013). The study protocol was reviewed and approved by the Ethics Committee of Nanjing Drum Tower Hospital (approval No. 2020-370-01), and the research was performed following the approval guidelines. Written

informed consent was obtained from each participant before their inclusion in the study.

Open Access Statement: This is an Open Access article distributed in accordance with the Creative Commons Attribution-NonCommercial-NoDerivs 4.0 International License (CC BY-NC-ND 4.0), which permits the non-commercial replication and distribution of the article with the strict proviso that no changes or edits are made and the original work is properly cited (including links to both the formal publication through the relevant DOI and the license). See: <https://creativecommons.org/licenses/by-nc-nd/4.0/>.

References

1. Tatro JM, Gilbertson JA, Schroder LK, Cole PA. Five to Ten-Year Outcomes of Operatively Treated Scapular Fractures. *J Bone Joint Surg Am* 2018;100:871-8.
2. Cole PA, Schroder LK. Scapula fractures. In: Bhandari M. editor. *Evidence-Based Orthopedics*. 2nd edition. John Wiley & Sons; 2021:457-61.
3. Schroder LK, Gauger EM, Gilbertson JA, Cole PA. Functional Outcomes After Operative Management of Extra-Articular Glenoid Neck and Scapular Body Fractures. *J Bone Joint Surg Am* 2016;98:1623-30.
4. Ropp AM, Davis DL. Scapular Fractures: What Radiologists Need to Know. *AJR Am J Roentgenol* 2015;205:491-501.
5. Jones CB, Cornelius JP, Sietsema DL, Ringler JR, Endres TJ. Modified Judet approach and minifragment fixation of scapular body and glenoid neck fractures. *J Orthop Trauma* 2009;23:558-64.
6. Bartoníček J, Frič V. Scapular body fractures: results of operative treatment. *Int Orthop* 2011;35:747-53.
7. Dimitroulias A, Molinero KG, Krenk DE, Muffly MT, Altman DT, Altman GT. Outcomes of nonoperatively treated displaced scapular body fractures. *Clin Orthop Relat Res* 2011;469:1459-65.
8. Kannan S, Singh HP, Pandey R. A systematic review of management of scapular fractures. *Acta Orthop Belg* 2018;84:497-508.
9. Meinberg EG, Agel J, Roberts CS, Karam MD, Kellam JF. Fracture and Dislocation Classification Compendium-2018. *J Orthop Trauma* 2018;32 Suppl 1:S1-S170.
10. Ström P. Glenoid fractures of the shoulder. *EFORT Open Rev* 2020;5:620-3.
11. Jaeger M, Lambert S, Südkamp NP, Kellam JF, Madsen JE, Babst R, Andermahr J, Li W, Audigé L. The AO Foundation and Orthopaedic Trauma Association (AO/OTA) scapula fracture classification system: focus on glenoid fossa involvement. *J Shoulder Elbow Surg* 2013;22:512-20.
12. Audigé L, Kellam JF, Lambert S, Madsen JE, Babst R, Andermahr J, Li W, Jaeger M. The AO Foundation and Orthopaedic Trauma Association (AO/OTA) scapula fracture classification system: focus on body involvement. *J Shoulder Elbow Surg* 2014;23:189-96.
13. Algan Kaya H, Eroğlu O, Günal N, Coşkun F, Deniz T. The relation between scapula fracture and the severity of trauma in blunt thoracic trauma. *Turk J Med Sci* 2018;48:1228-33.
14. Kokkalis ZT, Papanikos E, Bavelou E, Togias G, Sioutis S, Mavrogenis AF, Panagopoulos A. Arthroscopic reduction and fixation of greater tuberosity fractures of the humerus. *Eur J Orthop Surg Traumatol* 2021;31:1055-60.
15. Gummesson C, Atroshi I, Ekdahl C. The disabilities of the arm, shoulder and hand (DASH) outcome questionnaire: longitudinal construct validity and measuring self-rated health change after surgery. *BMC Musculoskelet Disord* 2003;4:11.
16. Limb D. Scapula fractures: a review. *EFORT Open Rev* 2021;6:518-25.
17. Jaikish S, Sambandam B. Functional Outcome of Open Reduction and Internal Fixation of Displaced Extra-Articular Scapula Fractures. *Indian J Orthop* 2020;55:708-13.
18. Paterson WH, Throckmorton TW, Koester M, Azar FM, Kuhn JE. Position and duration of immobilization after primary anterior shoulder dislocation: a systematic review and meta-analysis of the literature. *J Bone Joint Surg Am* 2010;92:2924-33.
19. Frich LH, Larsen MS. How to deal with a glenoid fracture. *EFORT Open Rev* 2017;2:151-7.
20. Wu J, Fu XJ, Sha M, Liu H, Chen ZD, Kang LQ. Treating Eyres type IV and V coracoid fracture using the acromion osteotomy approach. *Int Orthop* 2016;40:377-84.
21. Kolber MJ, Beekhuizen KS, Cheng MS, Hellman MA. Shoulder joint and muscle characteristics in the recreational weight training population. *J Strength Cond Res* 2009;23:148-57.

22. Taylor SA, Shah SS, Chen X, Gentile J, Gulotta LV, Dines JS, Dines DM, Cordasco FA, Warren RF, Kontaxis A. Scapular Ring Preservation: Coracoacromial Ligament Transection Increases Scapular Spine Strains Following Reverse Total Shoulder Arthroplasty. *J Bone Joint Surg Am* 2020;102:1358-64.
23. Romero J, Schai P, Imhoff AB. Scapular neck fracture--the influence of permanent malalignment of the glenoid neck on clinical outcome. *Arch Orthop Trauma Surg* 2001;121:313-6.

Cite this article as: Chen X, Deng YD, Qiu XS, Chen YX, Zhang ZT. Analysis of the curative effect and prognostic factors in patients with scapular fracture with surgical indications after conservative treatment: a case series and clinical outcomes. *Quant Imaging Med Surg* 2023;13(8):5130-5140. doi: 10.21037/qims-23-278