



# Severe Immediate and Delayed Hypersensitivity Reactions to Biologics in a Toddler With Systemic Juvenile Idiopathic Arthritis

Journal of Investigative Medicine High Impact Case Reports  
Volume 10: 1–6  
© 2022 American Federation for Medical Research  
DOI: 10.1177/23247096221077836  
journals.sagepub.com/home/hic  


D. Sofia Villacis-Nunez, MD<sup>1,2</sup>, Kassahun Bilcha, MD<sup>1,2</sup>,  
Mary Spraker, MD<sup>1,2</sup>, Kelly Rouster-Stevens, MD<sup>1,2</sup>,  
and Anthony Cooley, MD<sup>1,2</sup>

## Abstract

Many pediatric rheumatic diseases can be safely managed with biologic therapy. Severe allergic reactions to these medications are uncommon. We report the case of a 2-year-old male with systemic-onset juvenile idiopathic arthritis and secondary macrophage activation syndrome (MAS), whose treatment was complicated by severe allergic reactions to biologics, including drug reaction with eosinophilia and systemic symptoms (DRESS)/drug-induced hypersensitivity reaction (DIHR) likely due to anakinra, and anaphylactoid reaction to intravenous tocilizumab. These required transition to canakinumab, cyclosporine, and corticosteroids, with later development of interstitial lung disease and MAS flare needing transition from canakinumab to tofacitinib, which led to disease control. Whether lung disease is a manifestation of DRESS/DIHR to canakinumab remains unclear. High index of suspicion of hypersensitivity reactions for timely diagnosis and drug discontinuation is critical, especially in patients with active disease who might be at increased risk of these adverse events.

## Keywords

anakinra, tocilizumab, drug reaction, eosinophilia, anaphylactoid reaction

## Introduction

Biologics are widely used for the treatment of pediatric rheumatic diseases, with uncommon severe hypersensitivity reactions, but an overall favorable safety profile. We present the case of a 2-year-old male with systemic-onset juvenile idiopathic arthritis (sJIA) and macrophage activation syndrome (MAS) who developed drug reaction with eosinophilia and systemic symptoms (DRESS)/drug-induced hypersensitivity reaction (DIHR) syndrome likely induced by anakinra, and tocilizumab-induced anaphylactoid reaction, an unusual combination of both delayed and immediate hypersensitivity reactions to biologic drugs.

## Case Report

The patient is a 2-year-old male with an extensive past medical history, including prematurity, trisomy 21, chronic lung disease of prematurity, hypothyroidism, and adrenal insufficiency. He originally presented with 21 days of intermittent fever, evanescent rash, irritability, diarrhea, and lip peeling, failing therapy with several antibiotics for suspected pneumonia, including

trimethoprim-sulfamethoxazole, clarithromycin, ampicillin, amoxicillin, and clindamycin. After extensive evaluation ruling out infectious and oncologic etiologies, the diagnosis of sJIA with subclinical MAS was established. Anakinra was started (maximum dose 5 mg/kg/dose subcutaneous twice daily), with clinical and serologic improvement. The patient was discharged on day 15 on anakinra monotherapy.

Eleven days after starting anakinra, the patient developed a pruritic, erythematous rash on the extremities and chest, which progressed to involve the face within 24 hours with subsequent fever, prompting reevaluation. The mother had discontinued anakinra on the day of admission due to

<sup>1</sup>Emory University School of Medicine, Atlanta, GA, USA

<sup>2</sup>Children's Healthcare of Atlanta, GA, USA

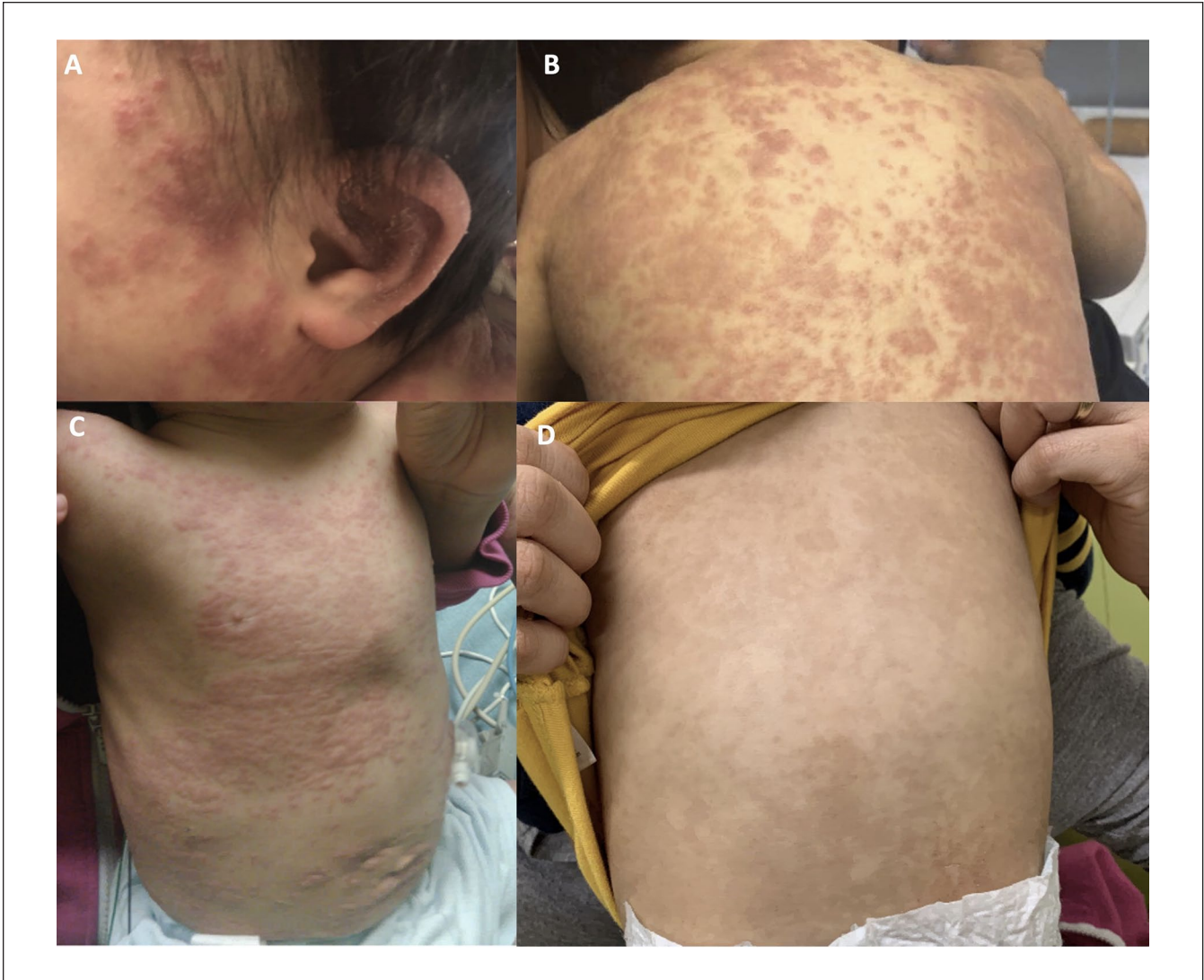Received November 30, 2021. Revised January 8, 2022. Accepted January 16, 2022.

### Corresponding Author:

D. Sofia Villacis-Nunez, MD, Division of Pediatric Rheumatology, Department of Pediatrics, Emory University, 1400 Tullie Rd, Atlanta, GA 30329, USA.

Email: [dvillac@emory.edu](mailto:dvillac@emory.edu)





**Figure 1.** Cutaneous manifestations of anakinra-induced drug reaction with eosinophilia and systemic symptoms/drug-induced hypersensitivity reaction: Panels A, B, and C show generalized morbilliform rash during acute phase. Panel D shows residual hyperpigmentation after stopping anakinra.

concern for an allergic reaction. Upon presentation in the emergency room, vital signs were significant for tachycardia (185 beats per minute), tachypnea (40 breaths per minute), and fever (39°C). Skin examination was remarkable for diffuse morbilliform rash affecting 60% of the total body surface area (BSA) with predilection to the central chest, back, face, and external ears; the proximal extremities were also mildly involved (Figure 1, panels A, B, and C). Swollen hands, edematous face, and external ears, as well as scaling and xerosis of extensor surfaces were also noted. No lymphadenopathy, scleral icterus, or additional abnormalities were appreciated on physical examination. Laboratory evaluation showed peripheral eosinophilia (13.2% [normal range = 0%-5%]; absolute eosinophil count = 1716/ $\mu$ L), presence of atypical lymphocytes (1% [normal range = 0%-10%]), and

elevated interleukin (IL)-18 level (471 768 pg/mL [normal range = 89-540 pg/mL]) while other MAS markers remained stable (Table 1). Chest X-ray showed chronic lung changes and atelectasis with bilateral pleural effusions, without new consolidation.

The diagnosis of definite DRESS/DIHR secondary to anakinra was made based on a European Registry of Severe Cutaneous Adverse Reactions to Drugs and Collection of Biological Samples (RegiSCAR) score of 6 (Table 2). Infectious causes were excluded. Therapy with intravenous (IV) methylprednisolone 30 mg/kg IV daily for 3 days was initiated, with clinical improvement; this was followed by a prednisolone taper, to be continued after discharge. In addition, intravenous tocilizumab infusions (12 mg/kg/dose) every 2 weeks were started in lieu of anakinra; the patient

**Table 1.** Complete Blood Count, Inflammatory Markers, and Liver Function Studies at During Disease Course.

Laboratory parameter (units)	Normal range	First hospital admission	Second hospital admission		Second tocilizumab infusion	Adenovirus-induced MAS
			Day 1	Day 5		
WBC ( $10^3/\mu\text{L}$ )	5-15.5	22.1	13.2	14	14.5	10.8
Eosinophils (%)	0-5	0.8	13	5	0	0
Hb (g/dL)	11.5-13.5	8.8	8.9	10	8.5	10.8
Platelets ( $10^3/\mu\text{L}$ )	175-525	277	257	468	617	260
CRP (mg/dL)	<1	15.3	4.1	0.8	7.8	10.2
ESR (mm/h)	0-15	94	34	9	42	57
Ferritin (ng/dL)	10-99	5368	793	466	186	5257
Fibrinogen (mg/dL)	200-400	472	313	231	509	383
LDH (U/dL)	192-321	788	1553	715		686
AST (U/L)	22-55	52	58	52	30	79
ALT (U/L)	11-30	18	10	30	18	36
Albumin (g/dL)	3.5-4.5	1.7	0.8	2.7	3.2	2.6

Abbreviations: MAS, macrophage activation syndrome; WBC, white blood cell count; Hb, hemoglobin; CRP, C-reactive protein; ESR, erythrocyte-sedimentation rate; LDH, lactate dehydrogenase; AST, aspartate aminotransferase; ALT, alanine aminotransferase.

received the first infusion on hospital day 3 (premedicated with acetaminophen and diphenhydramine) and was subsequently discharged.

Twelve days later, the acute component of the rash had resolved, leaving residual hyperpigmentation (Figure 1, panel D). His second tocilizumab dose was delayed by 2 weeks. Immediately after starting the second infusion, the patient developed an anaphylactoid reaction, manifesting as cyanosis and respiratory distress, requiring intramuscular epinephrine 0.01 mg/kg, followed by symptom resolution. Laboratory evaluation at the time demonstrated leukocytosis, thrombocytosis, and elevated inflammatory markers (Table 1). He received 30 mg/kg of IV methylprednisolone; enteral cyclosporine 4 mg/kg/dose twice daily was started and prednisolone was continued. Subcutaneous canakinumab 4 mg/kg/dose every 4 weeks was initiated several weeks later (delayed due to insurance approval) and well tolerated.

Three months after starting canakinumab, the patient had an episode of adenovirus-induced MAS after prednisolone discontinuation; laboratory values at the time are detailed in Table 1. Concurrently, a chest X-ray and subsequent chest tomography demonstrated radiologic changes consistent with sJIA-related interstitial lung disease (Figure 2); no bronchoalveolar lavage or biopsy performed. Class II human leukocyte antigen (HLA) testing was performed; HLA-DRB1\*15 was not identified. Oral prednisolone was reintroduced, cyclosporine was continued, and tofacitinib (3.2 mg twice daily) was prescribed in lieu of canakinumab for pulmonary disease and breakthrough MAS episode while on this medication. Tofacitinib insurance approval was delayed by 6 months and digital clubbing appeared in the interim, without additional respiratory symptoms or oxygen requirement. After the start of tofacitinib administration, prednisolone was gradually tapered down to 0.5 mg/kg/day and cyclosporine was continued. Digital clubbing has improved and the patient remains without respiratory symptoms. He

**Table 2.** Patient's RegiSCAR Score Calculation (Based on Kardaun et al<sup>1</sup>).

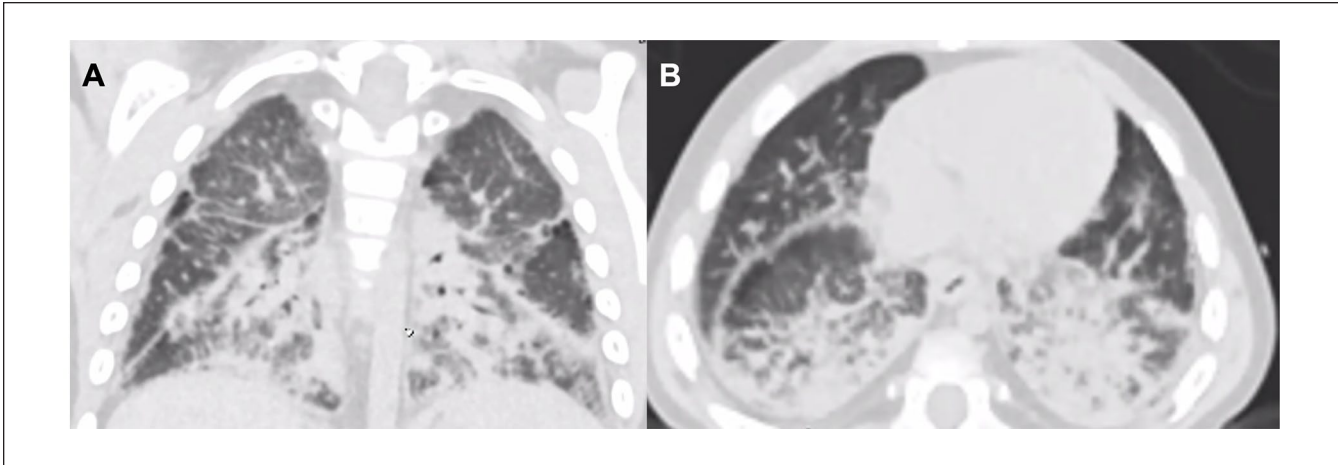
Criterion	Patient's result	Score
Fever $\geq 38.5^\circ\text{C}$	Present	0
Enlarged lymph nodes	Absent	0
Eosinophilia	$\geq 1500/\mu\text{L}$	2
Atypical lymphocytes	Present	1
Skin involvement		
Body surface area	$>50\%$	1
Skin rash suggesting DRESS/DIHR	Present	1
Biopsy suggesting DRESS/DIHR	Unknown (not performed)	0
Organ involvement		
Liver	Absent	0
Kidney	Absent	0
Lung	Present	1
Muscle/heart	Absent	0
Pancreas	Absent	0
Other organs	Absent	0
Resolution time	Less than 15 days	-1
Other potential causes	Excluded	1
<b>Total Score</b>		<b>6</b>

Abbreviations: RegiSCAR, Registry of Severe Cutaneous Adverse Reactions to Drugs and Collection of Biological Samples; DRESS, drug reaction with eosinophilia and systemic symptoms; DIHR, drug-induced hypersensitivity reaction.

will continue current therapy pending follow-up chest tomography 6 months into tofacitinib therapy.

## Discussion

Most biologic medications have been associated with local or generalized hypersensitivity reactions.<sup>2</sup> Allergic reactions to multiple biologic agents are anecdotally less common. We



**Figure 2.** Chest computed tomography without contrast. (A) Sagittal and (B) coronal views of the chest show interstitial reticulation and mild bronchiectasis, with patchy ground-glass opacities in a basilar predominance, as well as subpleural cystic changes. Findings were consistent with systemic juvenile idiopathic arthritis–related interstitial lung disease, superimposed to underlying chronic lung disease of prematurity and trisomy 21.

present the case of a patient with DRESS/DIHR likely induced by anakinra, with subsequent development of anaphylactoid reaction to tocilizumab, an unusual combination of both delayed and immediate hypersensitivity reactions to biologic medications.

The DRESS/DIHR is a unique and rare form of drug reaction often due to the exposure to aromatic anticonvulsants and sulfonamides. Re-activation of some viral infections, including human herpes virus (HHV)-6, HHV-7 and Epstein-Barr virus, has also been incriminated, as well as some medications.<sup>3</sup> Immune mechanisms and genetic polymorphism that affect detoxification of drugs are proposed mechanisms in the pathogenesis of this condition.<sup>4</sup> Clinical DRESS/DIHR typically occurs within 2 to 6 weeks of drug exposure though earlier occurrence is possible with reexposure. Most patients will have fever and rash that starts as a morbilliform eruption and progresses to skin edema. Internal organ involvement, including respiratory compromise, gastrointestinal symptoms, hepatitis, renal failure, bone marrow involvement, and meningoencephalitis, has been reported in association with DRESS/DIHR.<sup>5</sup>

There is a significant overlap between signs and symptoms of DRESS/DIHR and of sJIA flare; therefore, distinguishing between these 2 entities can be challenging. The widely accepted RegiSCAR scoring system uses a combination of biological and laboratory values for validating the diagnosis of potential cases of DRESS/DIHR as definite, probable, possible, or no case.<sup>1</sup> Our patient fell into a definite case, thus avoiding the need for an invasive procedure (biopsy) given high degree of suspicion for diagnosis based on clinical presentation. Although rash, fever and systemic inflammation are also features of sJIA, the presence of eosinophilia, atypical lymphocytes, and fixed morbilliform (non-evanescent) rash strongly favored DRESS/DIHR over sJIA

flare. The patient was on multiple antibiotics before the sJIA diagnosis was made, which could potentially cause DRESS/DIHR. However, a few weeks had already lapsed before he developed symptoms of DRESS/DIHR, making anakinra the most probable culprit, although definitive confirmation of the causative agent is not feasible.

Anakinra is frequently associated with localized injection site reactions and less commonly with generalized rash as side effects.<sup>6,7</sup> In recent years, DRESS/DIHR syndrome has emerged as a rare potential complication from the use of IL-1 and IL-6 blockers (including anakinra). The presence of HLA-DRB1\*15 alleles has been identified as a potential risk factor for these hypersensitivity reactions, although the pathophysiology is not well understood.<sup>8</sup> Additional factors are likely implicated, as our patient did not carry this risk allele. Active disease has been proposed as another possible risk factor.<sup>9</sup> However, most patients receiving anakinra have active systemic inflammation at the time the medication is started and not all present this complication; thus, larger samples would be needed to corroborate this assumption. An interesting feature shared by our case and previous reports by Polivka et al is the short latency period (less than 2 weeks) between drug exposure and evolution of DRESS/DIHR syndrome; as such, DRESS/DIHR in patients receiving anakinra should not be ruled out based on timeline alone and high suspicion should prompt drug discontinuation.

Our patient not only had signs of delayed hypersensitivity but also had a severe immediate hypersensitivity reaction to tocilizumab. Tocilizumab has been uncommonly reported to trigger infusion reactions, including anaphylaxis and anaphylactoid reactions.<sup>10-12</sup> Patients who are younger, of shorter stature, underweight, with active disease, and on intermittent tocilizumab therapy may have a greater predisposition to experience infusion reactions to subsequent tocilizumab

infusions.<sup>12-14</sup> Several of these were present in our patient at the time of anaphylactoid reaction to tocilizumab. Furthermore, he had an elevated IL-18 level at the time of DRESS/DIHR syndrome diagnosis and start of tocilizumab. The IL-18 level, a marker of MAS activity, was not measured when the reaction developed, but high levels would have been expected based on other abnormal disease markers at the time. The IL-18 could contribute to create an ideal environment for the generation of allergen and IgE-mediated responses, as it interacts with IL-3 to induce mast cell and basophil activation and promote the production of Th2 cytokines.<sup>15</sup> This could play a role in the coexistence of severe allergic reactions to different biologic agents with separate mechanisms of action in a patient with active sJIA. Alternatively, this patient's anaphylactoid reaction could have been IgE-independent, as IgG/IgM anti-drug antibodies against monoclonal antibodies, such as tocilizumab, have been implicated in the production of anaphylatoxins and activation of the complement system, mast cell, and basophils, leading to severe immediate hypersensitivity reactions that mimic IgE-mediated anaphylactic phenomena.<sup>16-18</sup> However, this appears less likely as the patient had only received one previous dose of tocilizumab and anti-drug antibodies tend to develop after multiple exposures.<sup>16</sup>

Interestingly, severe lung disease has emerged as a prominent, life-threatening complication in some individuals with sJIA exposed to IL-1 and IL-6 blockers, especially young patients with trisomy 21 and history of severe immediate hypersensitivity reaction to tocilizumab; whether lung disease is a consequence of sJIA pulmonary involvement or another manifestation of delayed hypersensitivity to these drugs remains under study.<sup>19-21</sup> Our patient fulfilled all the aforementioned risk factors for lung disease, and although severe respiratory compromise was absent at the time of DRESS/DIHR diagnosis, interstitial lung disease was later identified. Thus, it is possible that despite apparent good tolerance to canakinumab based on the absence of cutaneous and other systemic manifestations while on this therapy, an ongoing delayed hypersensitivity reaction to IL-1 blockade may have played a role in the development of lung disease. Drug removal has led to improvement of lung involvement in some patients.<sup>21</sup> The outcome in our patient is yet to be elucidated based on follow-up imaging. Tofacitinib and cyclosporine have thus far proven to be a safe alternative in this case.

## Conclusion

Despite their reported overall safety, biologic agents have the potential to cause severe allergic reactions, which may not manifest immediately after starting therapy. Providers should remain vigilant to this potential complication from biologic therapy.

## Declaration of Conflicting Interests

The author(s) declared no potential conflicts of interest with respect to the research, authorship, and/or publication of this article.

## Funding

The author(s) received no financial support for the research, authorship, and/or publication of this article.

## Ethics Approval

Our institution does not require ethical approval for reporting individual cases or case series.

## Informed Consent

Written informed consent was obtained from a legally authorized representative(s) for anonymized patient information to be published in this article.

## ORCID iD

D. Sofia Villacis-Nunez  <https://orcid.org/0000-0001-9182-6067>

## References

1. Kardaun SH, Sekula P, Valeyrie-Allanore L, et al. Drug reaction with eosinophilia and systemic symptoms (DRESS): an original multisystem adverse drug reaction. *Br J Dermatol*. 2013;169(5):1071-1080. doi:10.1111/bjd.12501.
2. Tarp S, Amarilyo G, Foeldvari I, et al. Efficacy and safety of biological agents for systemic juvenile idiopathic arthritis: a systematic review and meta-analysis of randomized trials. *Rheumatology (Oxford)*. 2016;55(4):669-679. doi:10.1093/rheumatology/kev382.
3. Beukelman T, Xie F, Chen L, et al. Rates of hospitalized bacterial infection associated with juvenile idiopathic arthritis and its treatment. *Arthritis Rheum*. 2012;64(8):2773-2780. doi:10.1002/art.34458.
4. Chen CB, Abe R, Pan RY, et al. An updated review of the molecular mechanisms in drug hypersensitivity. *J Immunol Res*. 2018;2018:6431694. doi:10.1155/2018/6431694.
5. Shiohara T, Mizukawa Y. Drug-induced hypersensitivity syndrome (DiHS)/drug reaction with eosinophilia and systemic symptoms (DRESS): an update in 2019. *Allergol Int*. 2019;68(3):301-308. doi:10.1016/j.alit.2019.03.006.
6. Lequerre T, Quartier P, Rosellini D, et al. Interleukin-1 receptor antagonist (anakinra) treatment in patients with systemic-onset juvenile idiopathic arthritis or adult onset Still disease: preliminary experience in France. *Ann Rheum Dis*. 2008;67(3):302-308. doi:10.1136/ard.2007.076034.
7. Sota J, Vitale A, Insalaco A, et al. Safety profile of the interleukin-1 inhibitors anakinra and canakinumab in real-life clinical practice: a nationwide multicenter retrospective observational study. *Clin Rheumatol*. 2018;37(8):2233-2240. doi:10.1007/s10067-018-4119-x.
8. Saper VE, Ombrello MJ, Tremoulet AH, et al. Severe delayed hypersensitivity reactions to IL-1 and IL-6 inhibitors link to common HLA-DRB1\*15 alleles. *Ann Rheum Dis*. 2021. doi:10.1136/annrheumdis-2021-220578.

9. Polivka L, Diana JS, Soria A, et al. Probable DRESS syndrome induced by IL-1 inhibitors. *Orphanet J Rare Dis.* 2017;12:8720170513. doi:10.1186/s13023-017-0645-x.
10. Horneff G, Schulz AC, Klotsche J, et al. Experience with etanercept, tocilizumab and interleukin-1 inhibitors in systemic onset juvenile idiopathic arthritis patients from the BIKER registry. *Arthritis Res Ther.* 2017;19:25620171124. doi:10.1186/s13075-017-1462-2.
11. Machado SH, Xavier RM. Safety of tocilizumab in the treatment of juvenile idiopathic arthritis. *Expert Opin Drug Saf.* 2017;16:493-500. doi:10.1080/14740338.2017.1303479.
12. Yokota S, Itoh Y, Morio T, et al. Tocilizumab in systemic juvenile idiopathic arthritis in a real-world clinical setting: results from 1 year of postmarketing surveillance follow-up of 417 patients in Japan. *Ann Rheum Dis.* 2016;75(9):1654-1660. doi:10.1136/annrheumdis-2015-207818.
13. Yasuoka R, Iwata N, Abe N, et al. Risk factors for hypersensitivity reactions to tocilizumab introduction in systemic juvenile idiopathic arthritis. *Mod Rheumatol.* 2019;29(2):324-327. doi:10.1080/14397595.2018.1457490.
14. Soyer O, Demir S, Bilginer Y, et al. Severe hypersensitivity reactions to biological drugs in children with rheumatic diseases. *Pediatr Allergy Immunol.* 2019;30(8):833-840. doi:10.1111/pai.13114.
15. Park EH, Lee EY, Shin K, Kim HA. Tocilizumab-induced anaphylaxis in patients with adult-onset Still's disease and systemic juvenile idiopathic arthritis: a case-based review. *Rheumatol Int.* 2020;40(5):791-798. doi:10.1007/s00296-019-04456-9.
16. Mori F, Saretta F, Bianchi A, et al. Hypersensitivity reactions to monoclonal antibodies in children. *Medicina (Kaunas).* 2020;56. doi:10.3390/medicina56050232
17. Pinteau I, Petricau C, Dumitrascu D, et al. Hypersensitivity reactions to monoclonal antibodies: classification and treatment approach (Review). *Exp Ther Med.* 2021;22(3):949. doi:10.3892/etm.2021.10381.
18. Vultaggio A, Perlato M, Nencini F, Vivarelli E, Maggi E, Matucci A. How to prevent and mitigate hypersensitivity reactions to biologicals induced by anti-drug antibodies. *Front Immunol.* 2021;12:765747. doi:10.3389/fimmu.2021.765747.
19. Saper V, Mellins E, Kwong B. Drug reaction and high fatality lung disease in Systemic Onset Juvenile Idiopathic Arthritis (sJIA). *J Allergy Clin Immunol.* 2020;145. doi:10.1016/j.jaci.2019.12.598.
20. Saper VE, Chen G, Deutsch GH, et al. Emergent high fatality lung disease in systemic juvenile arthritis. *Ann Rheum Dis.* 2019;78:1722-1731. doi:10.1136/annrheumdis-2019-216040.
21. Saper VE, Prahalad S, Canna S, et al. Effect of drug withdrawal on interleukin-1 or interleukin-6 inhibitor associated diffuse lung disease. ACR Convergence 2021. Abstract No. 1629. Virtual Meeting; November 3-November 9 2021. All Virtual.