



Sccleral Fixation of the Fluocinolone Acetonide Implant in Eyes with Severe Iris–Lens Diaphragm Disruption and Recalcitrant CME: The Fluocinolone-Loop-Anchoring Technique (FLAT)

Tina R. Herold · Raffael Liegl · Susanna Koenig · Ahmed Almarzooqi ·
Siegfried G. Priglinger · Armin Wolf

Received: December 9, 2019 / Published online: February 13, 2020
© The Author(s) 2020, corrected publication 2021

ABSTRACT

Introduction: While proven to be an effective treatment for cystoid macular edema (CME) and diabetic macular edema, intravitreal steroid implants (IVSI) may cause undesirable side effects, including steroid-related glaucoma or migration into the anterior chamber in the case of iris–lens diaphragm disruption. Here we present a new surgical technique that allows for the easy implantation and subsequent fixation of the fluocinolone acetonide intravitreal implant

without the risk of migration as a feasible and possibly reversible approach in the treatment of persistent CME in severely damaged eyes.

Methods: In this single-center, prospective off-label, proof of principle, scleral fixation of the fluocinolone implant was performed in two eyes with disrupted anterior–posterior segment border and persistent CME. Both eyes were then followed monthly in accordance to a detailed protocol.

Results: The procedure was overall well tolerated without severe side effects. There was no migration of the implant in the anterior chamber in either eye.

Conclusion: Scleral fixation of the fluocinolone implant proved to be a safe and feasible approach in eyes with persistent CME and disrupted anterior–posterior segment border. This new technique also allows for the possible removal of the implant and may therefore be suitable even for eyes at higher risk for side effects, such as glaucoma.

Enhanced digital features To view enhanced digital features for this article go to <https://doi.org/10.6084/m9.figshare.11673996>.

Electronic supplementary material The online version of this article (<https://doi.org/10.1007/s40123-020-00232-2>) contains supplementary material, which is available to authorized users.

T. R. Herold (✉) · R. Liegl · S. Koenig ·
S. G. Priglinger · A. Wolf
Department of Ophthalmology, University
Hospital, Ludwig Maximilian University of Munich,
Munich, Germany
e-mail: tina.herold@med.uni-muenchen.de

A. Almarzooqi
Department of Ophthalmology, University
Hospital, Technical University of Munich, Munich,
Germany

Keywords: Cystoid macular edema;
Fluocinolone implant; Iris–lens diaphragm
disruption; Scleral fixation

Key summary points

Why carry out this study?

Recalcitrant macular edema is difficult to treat in eyes that have undergone complicated cataract surgery or experienced trauma for several reasons.

Treatment of such eyes with intravitreal steroid implants can cause severe corneal decompensation in case of implant migration into the anterior chamber.

The study was carried out to prove that the scleral fixation of the fluocinolone acetonide implant is a feasible and possibly reversible approach, without the risk of migration into the anterior chamber for such severely damaged eyes with persistent cystoid macular edema (CME).

What was learnt from the study?

The scleral fixation of the fluocinolone acetonide implant proved to be a well-tolerated and technically feasible new technique in severely damaged eyes and those with persistent CME after complicated cataract surgery or trauma.

INTRODUCTION

The use of intravitreal steroid implants (IVSI), such as the dexamethasone implant (Ozurdex®; Allergan, Inc., Irvine, CA, USA) and the fluocinolone implant (Iluvien®; Alimera Sciences Ltd., Alpharetta, GA, USA), has been proven to be of long-term benefit for patients with diabetic macular edema, but also to patients with post-operative cystoid macular edema (CME) or Irvine–Gass syndrome [1, 2].

In particular, eyes which have undergone complicated cataract surgery or posterior capsule rupture have an increased risk for CME and therefore require a sustainable medical

treatment in the long term. At the same time, such eyes are at high risk of developing complications in terms of the migration of an IVSI into the anterior chamber, which can lead to severe corneal decompensation through mechanic and toxic effects [3, 4]. Therefore, scleral fixation of IVSI might be a reasonable approach for eyes with severe iris–lens diaphragm disruption and persistent CME. The fixation of the dexamethasone implant has been described, but eventual biodegradation of the implant may lead to loosening of the scleral fixation with time and ultimately to migration of the implant [5].

Here, we outline a simple surgical technique for scleral fixation of the fluocinolone implant that is well tolerated and a potentially reversible approach in the treatment of persistent CME in eyes with severe iris–lens diaphragm disruption.

METHODS

For this single-center, prospective off-label, proof of principle, this surgical technique was used to treat two eyes with disrupted anterior–posterior segment border and persistent CME. Both eyes were pseudophakic or aphakic and had experienced previous dexamethasone implant-related problems or migration of the dexamethasone implant into the anterior chamber. Exclusion criteria were a single eye condition or medical history or clinical evidence of glaucoma.

The two patients underwent a full clinical examination, including best corrected visual acuity (BCVA), measurement of the intraocular pressure (IOP), spectral domain optic coherence tomography (OCT) (Spectralis OCT; Heidelberg Engineering GmbH, Heidelberg, Germany) and photo documentation of the anterior segment and the posterior segment with the Optos Ultrawidefield Camera (Optos, Inc., Marlborough, MA, USA).

The procedure was performed under local anaesthesia with a retrobulbar injection of lidocaine. Figure 1 shows a schematic representation of the whole procedure. Prio to implantation, the fluocinolone implant was prepared for placement using a 10.0 Prolene suture in

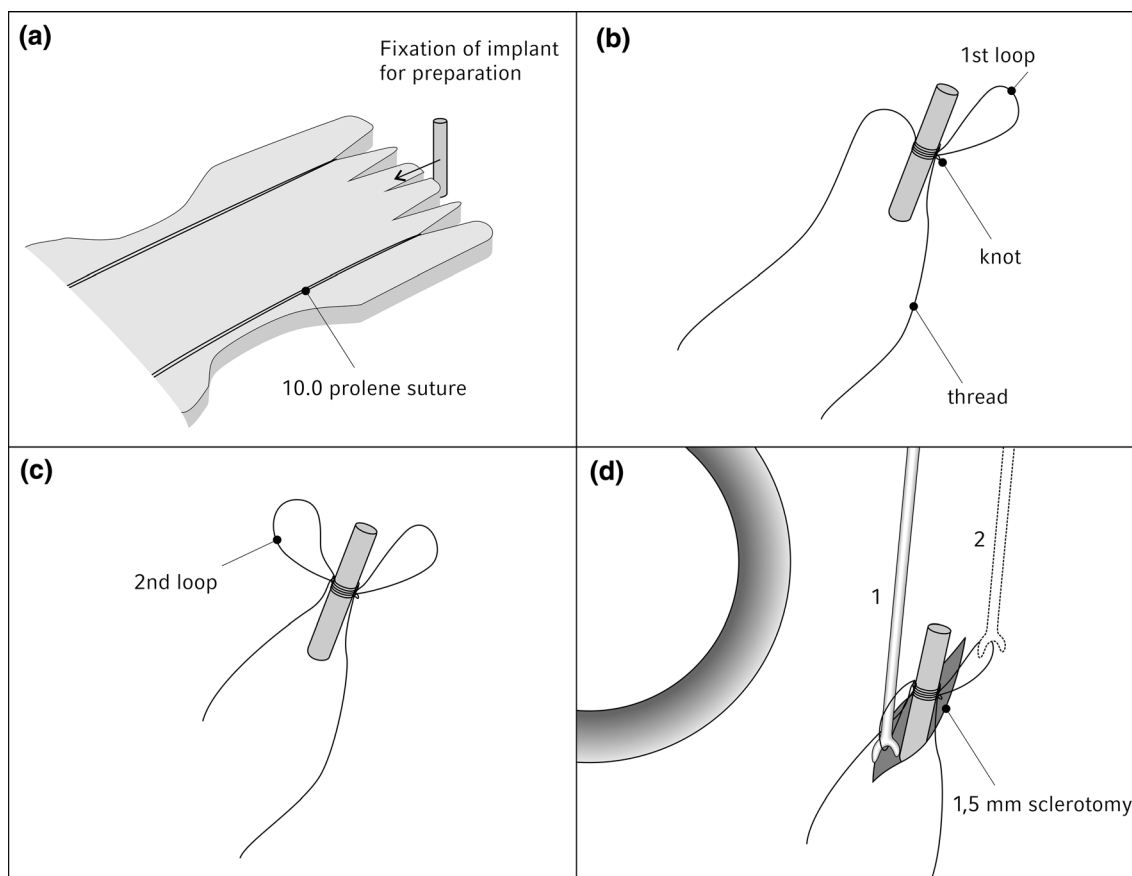


Fig. 1 Schematic representation of “the fluocinolone-loop-anchoring technique (FLAT)”. **a** Preparation of the implant with a 10.0 Prolene suture, **b**, **c** creation of two loop-like handles with thread, **d** insertion of the fixated

implant into the eye by pushing the two loop-like handles with a nucleus rotator

which a knot with two loops was created that allows handling of the thread-fixated implant during the following procedure (see video in Electronic Supplementary Material [EMS] Digital Content 1).

The conjunctiva and the eyelids were then disinfected and a sterile covering was applied. After placement of a Barraquer eye speculum, a 1.5-mm sclerotomy at a distance of 3.5 mm from the limbus was performed using a VR knife stab incision.

A flat-headed lens nucleus rotator (Geuder AG, Heidelberg, Germany) was used to insert the fluocinolone implant into the eye through the sclerotomy, pushing the two loop-like handles and subsequently pulling the implant into the vitreous cavity. The use of these two loops prevents the implant from slipping off the

fixated suture. The implant was pushed a minimum of 3 mm in order to create some distance from the ciliary body. Thereafter, the thread was fixed to the sclera. After trimming of the thread ends, the conjunctiva was closed with Vicryl 7.0. (see video EMS Digital Content 2).

For this single-center, prospective off-label proof of principle of a new surgical technique, no ethics committee approval was required. The study was however performed in accordance with the Helsinki Declaration of 1964 and its later amendments. The included patients signed written informed consent for this off-label surgical procedure and off-label use of the fluocinolone implant and provided consent to publication of their anonymized data and images.

RESULTS

The procedure was overall well tolerated in both patients' eyes. Both patients experienced subjective discomfort in the suture area post-operatively due to mechanical disturbance; however these side effects were resolved within 4 weeks post-operatively in both cases. There was no prolapse of vitreous through the incision, and neither of the patients' eyes developed a retinal tear. There were no problems with increased IOP or hypotonia during the first 4 weeks post-operatively. No dislocation or migration of the fixated implants was observed.

Both patients showed first morphological improvement in terms of reduction of central retinal thickness in the spectral domain OCT of > 10% during the first 4 weeks after the procedure. BCVA increased in one patient by one line and remained stable in the other patient in the first 4 weeks of the follow-up period.

A further prospective study is needed to evaluate the long-term safety and complication rate of this new technique, as well as the functional and anatomical outcomes of the medical treatment with IVSI or fluocinolone implants in a larger case series.

DISCUSSION

Eyes with a disrupted iris–lens diaphragm after complicated cataract surgery or after trauma are challenging in terms of clinical management for several reasons. On the one hand, such eyes are at a high risk to develop CME; on the other hand, the use of steroid implants in such eyes carries the risk of migration of the implant into the anterior chamber [3, 4]. Due to conflict, many eyes with CME are left untreated.

Scleral fixation of IVSI has been described in previous studies and may represent a reasonable approach to treating CME in those severely damaged eyes without the risk of migration [5]. We also have employed this technique for scleral fixation of dexamethasone implants; however, these implants are larger and tend to break during implantation using this technique (data not shown). Also, the biodegradation of the dexamethasone implant may result in a

loosening and subsequent migration of parts of the implant. Here, we present a technically feasible procedure for scleral fixation of the fluocinolone implant in eyes with disrupted anterior/posterior diaphragm.

By creating two loops that may be used as a handle, the implantation can be performed by using a 20-G sclerotomy with only minimal touching or manipulation of the implant and therefore minimal risk of implant damage. Additionally, with this special technique of creating two loop-like handles, the implant can be prevented from slipping of the fixated thread. In the two cases reported, we did not observe any procedure-related complications.

Furthermore, due to scleral fixation with the same thread, this technique also appears to allow for an atraumatic removal of the implant in a fish-rod-like manner in case it is required. Therefore, this simple and novel surgical technique may be even more suitable for those severely damaged eyes which otherwise would be at a higher risk of side effects, such as glaucoma or steroid-related increase of IOP.

CONCLUSION

This technique represents an easy approach for minimal invasive scleral fixation of the fluocinolone implant. Further studies are needed to evaluate the long-term safety and complication rate of this new technique, as well as the clinical effects of the medical treatment with IVSI in such eyes.

ACKNOWLEDGEMENTS

Funding. No funding or sponsorship was received for this study, or publication of this article. The Rapid Service Fee was funded by the authors themselves.

Authorship. All named authors meet the International Committee of Medical Journal Editors (ICMJE) criteria for authorship for this article, take responsibility for the integrity of

the work as a whole, and have given their approval for this version to be published.

Authorship Contributions. We are grateful to Felicitas Cinkler for her technical assistance and support.

Prior Presentation. This study was partly presented at the DOC Congress 2018, Nürnberg, Germany, the Floretina Congress 2019, Florence, Italy and at the DOG Congress 2019, Berlin, Germany.

Disclosures. Tina R Herold: Novartis Pharma, Allergan Pharm, Bayer (honoraria). Raffael Liegl: Novartis (honoraria). Siegfried G Priglinger: Novartis Pharma GmbH (advisory boards/honoraria), Pharm Allergan (advisory board/honoraria), Zeiss (advisory boards/honoraria), Bayer (honoraria), Alcon (honoraria), Oxurion (honoraria) and Rayner (honoraria). Armin Wolf: Novartis Pharma GmbH, Bayer, Alimera, Allergan, Oertli (travel cost, honoraria, consulting), Roche and Appellis (ongoing clinical trials). Susanna Koenig and Ahmed Almarzooqi have nothing to declare.

Compliance with Ethics Guidelines. For this single-center, prospective off-label proof of principle of a new surgical technique, no ethics committee approval was required. The study was however performed in accordance with the Helsinki Declaration of 1964 and its later amendments. The included patients signed written informed consent for this off-label surgical procedure and off-label use of the fluocinolone implant and provided consent to publication of their anonymized data and images.

Open Access. This article is licensed under a Creative Commons Attribution-NonCommercial 4.0 International License, which permits

any non-commercial use, sharing, adaptation, distribution and reproduction in any medium or format, as long as you give appropriate credit to the original author(s) and the source, provide a link to the Creative Commons licence, and indicate if changes were made. The images or other third party material in this article are included in the article's Creative Commons licence, unless indicated otherwise in a credit line to the material. If material is not included in the article's Creative Commons licence and your intended use is not permitted by statutory regulation or exceeds the permitted use, you will need to obtain permission directly from the copyright holder. To view a copy of this licence, visit <http://creativecommons.org/licenses/by-nc/4.0/>.

REFERENCES

1. Cunha-Vaz J, Ashton P, Iezzi R, et al. Sustained delivery fluocinolone acetonide vitreous implants: long-term benefit in patients with chronic diabetic macular edema. *Ophthalmology*. 2014;121(10):1892–903.
2. Mayer WJ, Kurz S, Wolf A, et al. Dexamethasone implant as an effective treatment option for macular edema due to Irvine–Gass syndrome. *J Cataract Refract Surg*. 2015;41(9):1954–61.
3. Rahimy E, Khurana RN. Anterior segment migration of dexamethasone implant: risk factors, complications, and management. *Curr Opin Ophthalmol*. 2017;28(3):246–51.
4. Papastavrou VT, Zambarakji H, Dooley I, et al. Observation: fluocinolone acetonide (Iluvien) implant migration in to the anterior chamber. *Retin Cases Brief Rep*. 2017;11(1):44–6.
5. Mateo C, Alkabes M, Burés-Jelstrup A. Scleral fixation of dexamethasone intravitreal implant (OZURDEX®) in a case of angle-supported lens implantation. *Int Ophthalmol*. 2014;34(3):661–5.