

# Nasopharyngeal Angiofibroma: A Forgotten Entity in Older Patients

Vanessa C Stubbs<sup>1</sup>, Lauren E Miller<sup>2</sup>, Arjun K Parasher<sup>1,3</sup>, Jordan T Glicksman<sup>1,4</sup>, Nithin D Adappa<sup>1</sup> and James Palmer<sup>1</sup>

<sup>1</sup>Department of Otorhinolaryngology—Head and Neck Surgery, University of Pennsylvania, Philadelphia, PA, USA. <sup>2</sup>Perelman School of Medicine, University of Pennsylvania, Philadelphia, PA, USA. <sup>3</sup>Department of Otolaryngology—Head & Neck Surgery, University of South Florida, Tampa, FL, USA. <sup>4</sup>North Shore Ear Nose and Throat, Danvers, MA, USA.

Clinical Medicine Insights: Case Reports  
Volume 12: 1–5  
© The Author(s) 2019  
Article reuse guidelines:  
sagepub.com/journals-permissions  
DOI: 10.1177/1179547619841062



## ABSTRACT

**INTRODUCTION:** Nasopharyngeal angiofibroma (NA) characteristically affects adolescent men. Although benign, these tumors can cause local destruction and surgical resection is warranted.

**OBJECTIVE:** We present a case of a 62-year-old man with nasal congestion and epistaxis, found to be a right NA on pathology. We also present a review of the available NA staging systems.

**FINDINGS:** In this case of NA, imaging revealed an aggressive, hypervascular mass in the nasal cavity with involvement of the middle cranial fossa and cavernous sinus. The patient underwent complete endoscopic surgical resection following vascular embolization.

**CONCLUSIONS:** Although it is rare, NA should not be disregarded in the elderly population.

**KEYWORDS:** Nasopharyngeal angiofibroma, vascular tumor, elderly

**RECEIVED:** February 7, 2019. **ACCEPTED:** February 12, 2019.

**TYPE:** Case Report

**FUNDING:** The author(s) received no financial support for the research, authorship, and/or publication of this article.

**DECLARATION OF CONFLICTING INTERESTS:** The author(s) declared no potential conflicts of interest with respect to the research, authorship, and/or publication of this article.

**CORRESPONDING AUTHOR:** Vanessa C Stubbs, Department of Otorhinolaryngology—Head and Neck Surgery, University of Pennsylvania, 3400 Spruce Street, Philadelphia, PA 19104, USA. Email: Vanessa.stubbs@uphs.upenn.edu

## Introduction

Nasopharyngeal angiofibromas (NAs) are rare tumors, found in less than 0.5% of all head and neck neoplasms.<sup>1</sup> These tumors are classically seen in adolescent men presenting with epistaxis or unilateral nasal obstruction and, despite their overall rarity, represent the most frequent head and neck tumor of adolescence.<sup>1</sup> Histologic features include highly vascular fibrous proliferation with variable vessel walls ranging from a thin layer to smoother muscular layers, as well as abundant stromal collagenized tissue and mast cells.<sup>2</sup> Although NA tumors are histologically benign, this neoplasm can be locally invasive causing bony remodeling and can produce problematic severe bleeding. Complete surgical excision is the current standard of treatment; however, due to reported intraoperative hemorrhage, preoperative embolization is frequently implemented.<sup>3–5</sup>

The average age of patients with NA is reported to range from 10 to 25 years,<sup>6</sup> with few case reports published discussing NA in the elderly male and female population<sup>7–12</sup> (Table 1). The oldest reported case is in a 79-year-old patient.<sup>8</sup> Whereas the previously reported cases in adults have been treated with open surgical resection or endoscopic assisted approaches, here, we describe a 62-year-old patient who underwent preoperative embolization followed by a fully endoscopic approach for resection of the lesion.

## Case Report

A 62-year-old man initially presented with a 2-year history of decreased sense of smell, increasing right-sided nasal congestion, and recurrent right-sided epistaxis requiring control in a local emergency department (ED). Imaging in the ED noted a right-sided skull base lesion with intracranial extension. Biopsy subsequently performed by a local otolaryngologist showed capillary hemangioma with atypical features. The patient had subsequent bleeding and packing remained in place for several days with resolution. The patient was then referred to our institution for further treatment. Computed tomography (CT) demonstrated an aggressive, avidly enhancing hypervascular mass centered in the right nasal cavity with extension into the maxillary sinus, masticator space, nasopharynx, and orbit. Magnetic resonance imaging (MRI) revealed additional perineural intracranial extension into the right middle cranial fossa and cavernous sinus (Figure 1).

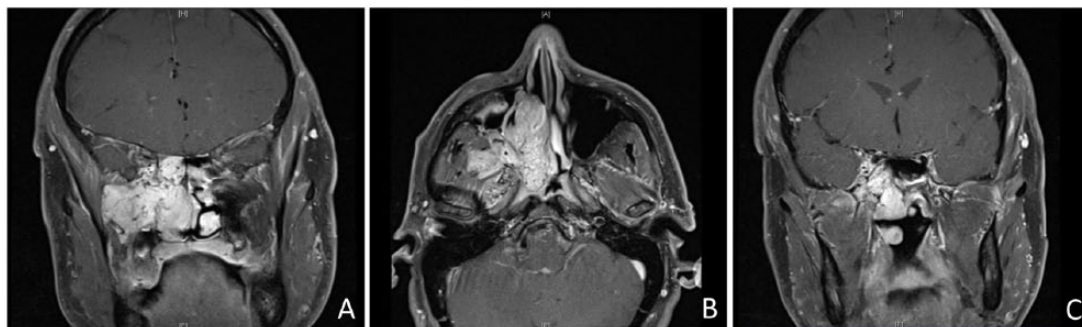
At 2 weeks following presentation, the patient underwent preoperative vascular embolization (Figure 2), followed by an endoscopic resection of the anterior cranial fossa lesion. For endoscopic approach to the tumor, bilateral medial maxillectomy, sphenoethmoidectomy, frontal sinusotomy, right middle turbinectomy, and posterior septectomy were performed. Once bimanual access was obtained, attention was then turned to ligation of the main blood supply to the tumor. The posterior



**Table 1.** Characteristics of prior reports of nasopharyngeal angiofibroma in elderly patients.

REFERENCE	PUBLICATION YEAR	PATIENT AGE	SEX	IMAGING AND HISTOLOGY FEATURES	RESECTION AND FOLLOW-UP
Zhang et al <sup>7</sup>	2015	72	Male	CT demonstrated highly vascular nasopharyngeal mass, and histopathology demonstrated proliferating vasculature in a fibrous stroma consistent with angiofibroma	Endoscopy-assisted sublabial and buccolabial approach with preoperative embolization and incomplete resection followed by subsequent resection and no recurrence at 6 months
Conley et al <sup>8</sup>	1968	79	Male	No histology confirmation	Open transpalatine approach
Ewing and Shively <sup>9</sup>	1981	71	Female	N/A; histology indicated angiofibroma	Lateral rhinotomy and antrotomy, no recurrence at 2-year follow-up
Shaheen <sup>10</sup>	1930	70	Male	No histology confirmation	Open approach via Moure's lateral rhinotomy incision
Szymanska et al <sup>11</sup>	2006	57	Female	CT and MRI demonstrated right nasopharyngeal mass with nasal septum erosion and without ethmoid, sphenoid, or maxillary sinus wall erosion	Preoperative internal maxillary artery embolization with sublabial degloving approach, follow-up at 6 years without recurrence
Ralli et al <sup>12</sup>	2018	68	Female	MRI demonstrated a polypoid lesion in posterior nasal cavity without invasion of the roof or posterior wall	Endoscopic and complete resection without recurrence at 3 years

CT, computed tomography; MRI, magnetic resonance imaging; N/A, not available.

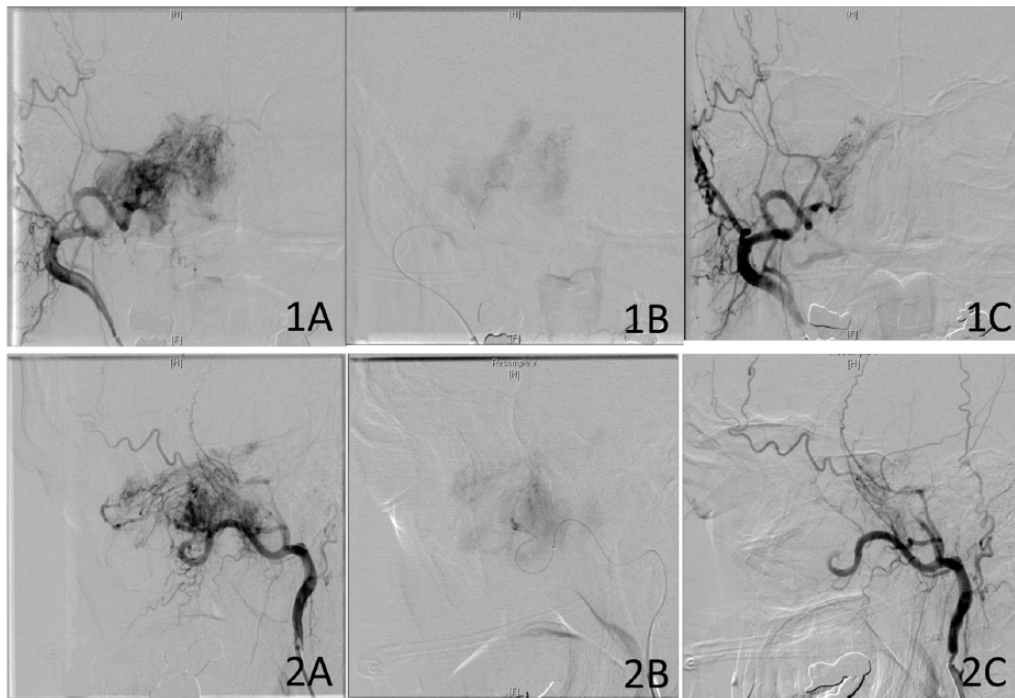


**Figure 1.** Preoperative T1-weighted, coronal and axial, post-contrast MRI images illustrating extension into pterygopalatine fossa (A, B) and cavernous sinus involvement (C). MRI, magnetic resonance imaging.

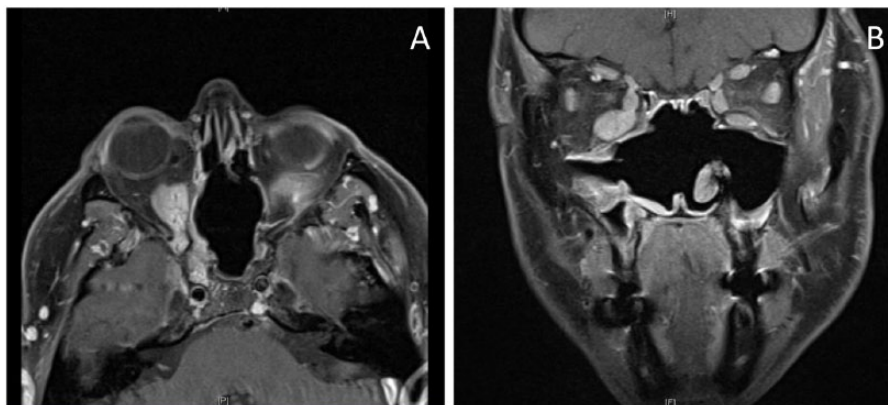
wall of the maxillary sinus was removed to ligate the right internal maxillary artery and remove the tumor occupying the pterygopalatine fossa. The tumor was then dissected along the skull base back to the sphenoid sinus and the nasopharynx, where it was released from the fascia above the eustachian tube. Dissection was then performed along the orbit and cavernous sinus. Given extension into the orbit and through to the cavernous sinus, the tumor was ligated at the level of the inferior orbital fissure with portions remaining both in the orbit and posteriorly where it was attached in the cavernous sinus. For reconstruction of the defect, a free septal graft was placed over the raw surgical bed and the nasal cavity was then packed with fibrin glue, gelfoam, and xeroform gauze. Total blood loss was estimated to be 700 mL. Stereotactic computer-assisted surgical navigation was used for the entirety of this procedure.

Histopathologic examination of the excised lesion demonstrated NA. The vascular neoplasm was characterized by vessels with varying caliber (large vessels with muscular walls to thin vessels lacking vascular walls). There was no cytologic atypia to the vascular endothelium, no anastomosing channels to the vasculature, and a low Ki67 rate. S-100 and Melan-A testing were negative, whereas the tissue was CD34 and CD68 positive. No morphologic features of a hemangioendothelioma were identified. Immunohistochemical stains were performed with adequate controls.

Postoperative imaging was obtained 3 months following surgical resection showing a small residual neoplasm in the right orbit, right middle cranial fossa abutting the right cavernous sinus, and right upper masticator space (Figure 3). At follow-up, the patient noted an improvement in nasal congestion



**Figure 2.** Preoperative interventional neuroradiology embolization. Coronal (1) and sagittal (2) images displaying angiogram pre-embolization (A) illustrating blush of lesion's vasculature, during embolization (B) illustrating the wire used, and post-embolization (C) showing a decrease in vascular flow.



**Figure 3.** Postoperative, axial and coronal, T1-weighted, post-contrast MRI image showing residual tumor in the right posterior orbit (A) and cavernous sinus (B).

MRI, magnetic resonance imaging.

and smell, but reported persistent facial numbness in the right maxillary sinus area. His most recent appointment at his 2-year follow-up noted trace growth of the lesion in the infratemporal fossa. On endoscopic examination, his sinuses were patent and clear without obvious visualization of the lesion. It was decided to continue observation and possible endoscopic re-resection if continued growth or worsening symptoms occur.

### Discussion

This study reports a rare case of a 62-year-old man with confirmed NA. Despite his age, this patient presented with a

common clinical presentation for NA, including bleeding, obstruction, and loss of smell. He also demonstrated features on CT and MRI typical for NA including hypervascularity, nasopharyngeal site of origin, and local bony destruction. In this case, the patient had a stage V medial tumor using the UPMC (University of Pittsburgh Medical Center) staging system (an NA staging system that accounts for both route of cranial base extension and vascularity),<sup>13</sup> which would typically require open resection due to significant challenges for surgical access and a high risk of residual disease.<sup>13</sup> However, endoscopic access was selected in this patient due to his age and

**Table 2.** Unique features and considerations of nasopharyngeal angiofibroma staging systems.

CLASSIFICATION SYSTEM	SNYDERMAN ET AL/UPMC <sup>13</sup>	ONERCI ET AL <sup>18</sup>	RADKOWSKI ET AL <sup>19</sup>	ANDREWS ET AL <sup>20</sup>	CHANDLER ET AL <sup>21</sup>	SESSIONS ET AL <sup>22</sup>
STAGES	I-V	I-IV	IA-IIIIB	I-IVB	I-IV	I-III
Unique features	Includes route of intracranial extension and vascularity of the tumor; acknowledges paranasal sinus involvement not impediment to surgical excision; strong correlation between staging and number of operations, residual tumor	Includes tumor extension posterior to the pterygoid plates as a higher risk factor due to surgical challenge; considers endoscopic approach in staging	A modification of Session's classification; first to propose a system that highlighted the presence of extension posterior to the pterygoid plates as a higher risk factor	Notes surgical treatment up to stages IVa whereas radiotherapy recommended for managing IVb lesions	Combines clinical and radiographic features; any intracranial extension is stage IV	First staging system; any intracranial extension is stage III
Considerations	Assumes that almost all tumors will undergo preoperative embolization; designed based on patients who underwent endoscopic resection	Does not consider vascularity of the tumor	Does not account for endoscopic technique	Does not account for endoscopic technique	Does not account for the degree of skull base involvement; does not account for endoscopic technique	Does not account for the degree of skull base involvement; does not incorporate preoperative imaging studies

potentially increased morbidity from an open resection. Given his age, lack of orbital symptoms, and potential morbidity, the decision was made with the patient to leave the intraorbital and cavernous sinus portions of the tumor. If this patient were younger, a more aggressive approach may have been attempted.

A literature review by Dahl et al<sup>14</sup> noted recurrence following endoscopic resection to range from 4.7% to 10.8%, whereas open resection had a recurrence rate ranging from 14.5% to 20.6%. In general, endoscopic approaches have been observed to be effective in patients with NA (Radkowski stage II or less) who have undergone preoperative embolization, without recurrence for up to almost 4 years.<sup>15</sup> Another study cited cases of endoscopic resection of NA with intracranial extension, without recurrence for up to 4 years and encompassing all Radkowski stages.<sup>16,17</sup> However, conclusions from these studies are challenging to determine given the variety in surgical treatment approaches as well as a lack of consistent use across the available staging systems (Table 2). As Snyderman et al<sup>13</sup> noted, 51% of tumors in their series were characterized as UPMC stage III; 74% of these same tumors would be characterized as Radkowski stage III.

NA is a rare disease in the elderly, with few cited reports of patients with NA after the second decade of life.<sup>7</sup> Of all the studies citing older patients with NA, surgical excision occurred by either traditional open approaches<sup>8–11</sup> or a combined endoscopic and open approach,<sup>7</sup> but none with a fully endoscopic excision as in this case. Although more data are needed regarding surgical approach and recurrence rates to determine the

best outcomes, this case highlights that the endoscopic approach is certainly a viable option in elderly patients.

## Conclusions

NA, while classically in adolescent men, can be seen in older populations and should be considered with appropriate clinical presentation. In the elderly population, the risks and benefits of total resection in the case of orbital and intracranial extension may be weighed differently than in the younger population. This case highlights the option of endoscopic management of NA in an elderly man.

## Authors' note

Jordan T Glicksma is also affiliated to Department of Otolaryngology, Harvard Medical School, Massachusetts Eye and Ear Infirmary, Boston, MA, USA.

## Author Contributions

VCS, LEM: Conception of study, acquisition, interpretation of data, drafting the article, final approval, accountability for all aspects of the work. AKP, JTG, NDA, JP: Conception of study, interpretation of data, critical revision of manuscript, final approval, accountability for all aspects of the work.

## REFERENCES

- Nicolai P, Schreiber A, Bolzoni Villaret A. Juvenile angiofibroma: evolution of management. *Int J Pediatr.* 2012;2012:412545.
- Sanchez-Romero C, Carlos R, Diaz Molina JP, Thompson LDR, de Almeida OP, Rumayor Pina A. Nasopharyngeal angiofibroma: a clinical, histopathological

- and immunohistochemical study of 42 cases with emphasis on stromal features. *Head Neck Pathol.* 2018;12:52–61.
3. Martins MB, de Lima FV, Mendonca CA, et al. Nasopharyngeal angiofibroma: our experience and literature review. *Int Arch Otorhinolaryngol.* 2013;17:14–19.
  4. Liu L, Wang R, Huang D, et al. Analysis of intra-operative bleeding and recurrence of juvenile nasopharyngeal angiofibromas. *Clin Otolaryngol Allied Sci.* 2002;27:536–540.
  5. Garcia-Cervigon E, Bien S, Rufenacht D, et al. Pre-operative embolization of naso-pharyngeal angiofibromas. *Neuroradiology.* 1988;30:556–560.
  6. Roberson GH, Biller H, Sessions DG, Ogura JH. Presurgical internal maxillary artery embolization in juvenile angiofibroma. *Laryngoscope.* 1972;82:1524–1532.
  7. Zhang HK, Wang JJ, Liu ZF, Wang DH. Management of nasopharyngeal angiofibroma in a 72-year-old male through a sublabial and buccolabial incision approach: a case report and literature review. *Oncol Lett.* 2015;10:1267–1270.
  8. Conley J, Healey WV, Blaugrund SM, Erzin KH. Nasopharyngeal angiofibroma in the juvenile. *Surg Gynecol Obstet.* 1968;126:825–837.
  9. Ewing JA, Shively EH. Angiofibroma: a rare case in an elderly female. *Otolaryngol Head Neck Surg.* 1981;89:602–603.
  10. Shaheen HB. Nasopharyngeal fibroma. *J Laryngol Otol.* 1930;45:259–264.
  11. Szymanska A, Korobowicz E, Golabek W. A rare case of nasopharyngeal angiofibroma in an elderly female. *Eur Arch Otorhinolaryngol.* 2006;263:657–660.
  12. Ralli M, Fusconi M, Visconti IC, Martellucci S, de Vincentiis M, Greco A. Nasopharyngeal angiofibroma in an elderly female patient: a rare case report. *Mol Clin Oncol.* 2018;9:702–704.
  13. Snyderman CH, Pant H, Carrau RL, Gardner P. A new endoscopic staging system for angiofibromas. *Arch Otolaryngol Head Neck Surg.* 2010;136:588–594.
  14. Dahl JP, Zopf DA, Parikh SR. Do open and endoscopic resection approaches to juvenile nasopharyngeal angiofibroma result in similar blood loss and recurrence rates. *Laryngoscope.* 2015;125:2436–2437.
  15. Wormald PJ, Van Hasselt A. Endoscopic removal of juvenile angiofibromas. *Otolaryngol Head Neck Surg.* 2003;129:684–691.
  16. Nicolai P, Berlucchi M, Tomenzoli D, et al. Endoscopic surgery for juvenile angiofibroma: when and how. *Laryngoscope.* 2003;113:775–782.
  17. Ardehali MM, Samimi Ardestani SH, Yazdani N, Goodarzi H, Bastaninejad S. Endoscopic approach for excision of juvenile nasopharyngeal angiofibroma: complications and outcomes. *Am J Otolaryngol.* 2010;31:343–349.
  18. Onerci M, Ogretmenoglu O, Yucel T. Juvenile nasopharyngeal angiofibroma: a revised staging system. *Rhinology.* 2006;44:39–45.
  19. Radkowski D, McGill T, Healy GB, Ohlms L, Jones DT. Angiofibroma: changes in staging and treatment. *Arch Otolaryngol Head Neck Surg.* 1996;122:122–129.
  20. Andrews JC, Fisch U, Valavanis A, Aepli U, Makek MS. The surgical management of extensive nasopharyngeal angiofibromas with the infratemporal fossa approach. *Laryngoscope.* 1989;99:429–437.
  21. Chandler JR, Goulding R, Moskowitz L, Quencer RM. Nasopharyngeal angiofibromas: staging and management. *Ann Otol Rhinol Laryngol.* 1984;93:322–329.
  22. Sessions RB, Bryan RN, Naclerio RM, Alford BR. Radiographic staging of juvenile angiofibroma. *Head Neck Surg.* 1981;3:279–283.