

Wrapping of an Ascending Aortic Aneurysm with the Multiple Boot-Straps Technique in a Patient Undergoing Off-Pump Coronary Artery Bypass Grafting

Kwon Joong Na, M.D., Jun Sung Kim, M.D., Kay-Hyun Park, M.D., Ph.D., Cheong Lim, M.D., Ph.D.

Ascending aortic aneurysms are usually treated with graft replacement under cardiopulmonary bypass. However, if a candidate for off-pump coronary artery bypass grafting has an enlarged ascending aorta, surgeons may consider wrapping it without cardiopulmonary bypass. Here, we report a 78-year-old female who underwent successful wrapping of the ascending aorta concomitant with off-pump coronary artery bypass grafting, using a new wrapping technique that involves multiple bootstraps.

Key words: 1. Aortic aneurysm, thoracic
2. Coronary artery bypass
3. Off-pump

CASE REPORT

A 78-year-old female presented to another hospital with a complaint of recently aggravated exertional chest pain. The patient was diagnosed with unstable angina and exhibited triple-vessel disease upon undergoing coronary angiography, and she was subsequently referred to Seoul National University Bundang Hospital for further management. Surgical intervention was considered for the patient's coronary artery disease, and she therefore underwent preoperative computed tomography, which showed an ascending aortic aneurysm with a maximal diameter of 48 mm (Fig. 1A). Since she had some risk factors, including old age and hypertension, and she was a suitable candidate for off-pump coronary artery bypass grafting (CABG), we determined that aortic wrapping without cardiopulmonary bypass (CPB) would be a better option for her than replacement of the ascending aorta.

We performed uneventful off-pump CABG with a Y-composite graft, using bilateral internal thoracic arteries. After the adventitial tissue around the ascending aorta was fully mobilized, the ascending aorta was encircled from the innominate artery to the aortic root with a longitudinally divided, 32-mm Hemashield vascular graft (Maquet Holding GmbH & Co, Rastatt, Germany). Multiple bootstraps were evenly positioned along both edges using an interrupted mattress suture of 3/0 polypropylene (Fig. 2A, B). Under permissive hypotension (systolic blood pressure < 70 mmHg), we snared down all the bootstraps (Fig. 2C, D). We then tied the straps with a Teflon-pledget buttress placed inside the graft, preventing an incidental cut-through of the aorta. Intraoperative transesophageal echocardiography showed normal cardiac function without aortic regurgitation. The patient's postoperative course was uneventful, and she was discharged on the 11th postoperative day without any complications. Postoperative com-

Departments of Thoracic and Cardiovascular Surgery, Seoul National University Bundang Hospital, Seoul National University College of Medicine
Received: July 29, 2014, Revised: September 12, 2014, Accepted: September 15, 2014, Published online: June 5, 2015

Corresponding author: Cheong Lim, Department of Thoracic and Cardiovascular Surgery, Seoul National University Bundang Hospital, Seoul National University College of Medicine, 82 Gumi-ro 173beon-gil, Bundang-gu, Seongnam 463-707, Korea
(Tel) 82-31-787-7139 (Fax) 82-31-787-4050 (E-mail) mluemoon@snuh.org

© The Korean Society for Thoracic and Cardiovascular Surgery. 2015. All right reserved.

© This is an open access article distributed under the terms of the Creative Commons Attribution Non-Commercial License (<http://creativecommons.org/licenses/by-nc/4.0>) which permits unrestricted non-commercial use, distribution, and reproduction in any medium, provided the original work is properly cited.

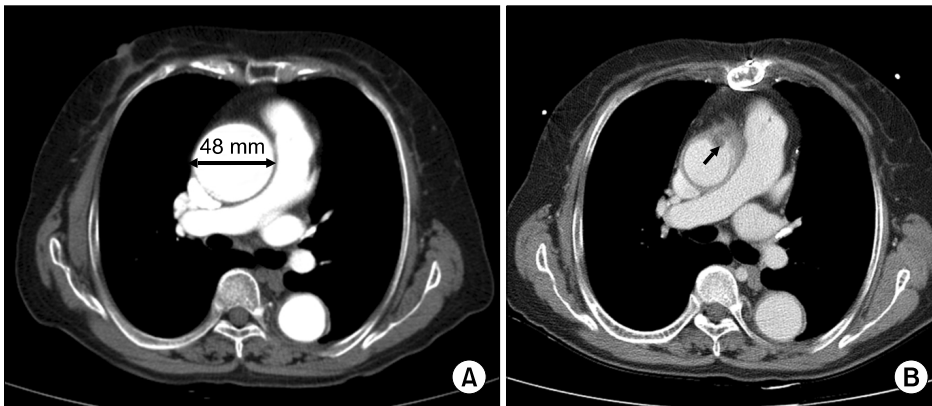


Fig. 1. Computed tomography (CT) findings of the patient. (A) Preoperative CT showing the ascending aorta aneurysm with a maximal diameter of 48 mm. (B) Postoperative CT showing a normally sized ascending aorta. Inward folding of the intima is marked with a black arrow.

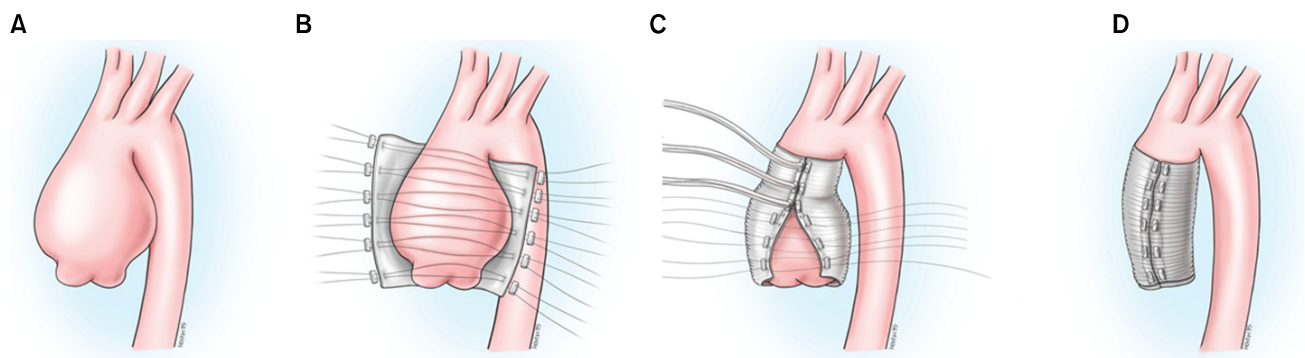


Fig. 2. The multiple bootstraps technique for wrapping of the ascending aorta. (A) The dilated ascending aorta. (B) Wrapping of the ascending aorta with a prosthetic vascular graft and the positioning of multiple bootstraps along both edges using an interrupted mattress suture. (C) Snaring down the bootstraps. (D) The wrapped ascending aorta.

puted tomography was performed six months after the operation, showing a normally sized ascending aorta with mild inward folding of the intima (Fig. 1B).

DISCUSSION

Ascending aortic aneurysms are one of the most common findings in patients undergoing cardiac surgery, and they usually require surgical treatment along with other concomitant cardiac procedures. As observed in our case, it is common for cardiac surgeons to encounter an ascending aortic aneurysm in patients undergoing CABG, or to determine that CABG should be performed in a patient undergoing treatment for an ascending aortic aneurysm [1]. Concomitant CABG may be performed in up to 30% of patients undergoing either ascending aortic or aortic arch surgeries, according to previous studies [1-4]. There are several treatment options for

ascending aortic aneurysms, and replacement of the ascending aorta with a prosthetic vascular graft is the most common surgical procedure currently performed. This procedure offers good perioperative results, due to remarkable advancements in both CPB and surgical technique; however, the hospital mortality and morbidity rates still remain high, ranging up to 10% [5,6]. For these reasons, many cardiac surgeons have sought to use simple and safe surgical techniques when treating ascending aortic aneurysms along with concomitant cardiac procedures, especially in patients with multiple comorbidities in whom prolonged CPB and aortic cross-clamping time cannot be tolerated [1-3].

Wrapping of the ascending aorta, with or without aortoplasty, is an alternative surgical procedure that can be performed to treat ascending aortic aneurysms. It has several advantages over graft replacement, such as less bleeding, shorter CPB and aortic cross-clamping time, and lower rates of mor-

bidity and mortality. Recent studies demonstrated the safety and durability of ascending aorta wrapping based on medium-term and long-term follow-up data [1-3]. Cohen et al. [2] reported the longest follow-up results, and their data were promising; no early or in-hospital mortality was reported, and, most importantly, they reported no significant increases in the diameter of the ascending aorta, the incidence of dissection, or the incidence of rupture during the follow-up period. Moreover, a histologic examination found no evidence of infection, erosion, or invasion of the synthetic graft.

Off-pump surgery is likely to be indicated for patients with multiple comorbidities such as old age, difficulty in early mobilization, or chronic renal failure. In these situations, if patients have both coronary artery disease and an ascending aortic aneurysm requiring surgical intervention, wrapping of the ascending aorta may be a good option for patients who are suitable candidates for off-pump CABG. As presented in our case as well as in previous reports, wrapping of the ascending aorta may be performed in a simple manner using a prosthetic vascular graft, and it may be performed safely without CPB support. Furthermore, this method is even simpler when the multiple bootstraps technique is used, because the surgeon may reduce the size of the ascending aorta by simply securing the bootstraps under permissive hypotension. Therefore, we believe that this technique may be a good choice for many cardiac surgeons considering wrapping of the ascending aorta, and it may be especially promising for older patients with multiple comorbidities, in whom prolonged CPB and aortic cross-clamping time may increase mortality and morbidity.

Although favorable medium-term and long-term results of wrapping of the ascending aorta have been reported in the previous literature, some concerns about this technique still exist. Akgun et al. [7] reported the occurrence of an aortic root aneurysm and preliminary dissection a few years after wrapping of the ascending aorta. Additionally, Polvani et al. [8] reported a 7.5% rate of redilatation and showed that preoperative diameter was a significant risk factor for redilatation. Based on their study, ascending aorta wrapping should not be considered if the aneurysm is primarily due to aortic pathology, if the internal diameter of the aneurysm is >55 mm, if the patient has a connective tissue disorder such as

Marfan syndrome, or if the aneurysm has heavy calcification, atherosclerosis, or penetrating ulcers [2-4,7,8]. Therefore, in order to optimize the long-term outcome, cardiac surgeons should implement strictly defined indications when considering this technique. Moreover, in addition to the above counterindications, the choice of using this surgical technique may be a matter of surgical preference.

We successfully performed wrapping of the ascending aorta using the multiple bootstraps technique for an ascending aortic aneurysm in a patient who underwent concomitant off-pump CABG. This type of off-pump aortic wrapping is technically simple and safe, and can therefore represent a good alternative to ascending aorta replacement in select patients with moderately dilated ascending aortic aneurysms. The size of the ascending aorta was not an absolute indication for surgery; however, we think that it was reasonable to perform wrapping of the ascending aorta for a moderately dilated aneurysm since the patient required off-pump CABG and since the wrapping procedure has been reported to be safe. Although the early outcome of the present case was satisfactory, long-term follow-up is warranted, particularly to address concerns about the inward folding of the intima.

CONFLICT OF INTEREST

No potential conflict of interest relevant to this article was reported.

REFERENCES

1. Arsan S. *Off-pump reduction aortoplasty and concomitant coronary artery bypass grafting*. Ann Thorac Surg 2004;78:316-9.
2. Cohen O, Odum J, De la Zerda D, et al. *Long-term experience of girdling the ascending aorta with Dacron mesh as definitive treatment for aneurysmal dilation*. Ann Thorac Surg 2007;83:S780-4.
3. Arsan S, Akgun S, Kurtoglu N, Yildirim T, Tekinsoy B. *Reduction aortoplasty and external wrapping for moderately sized tubular ascending aortic aneurysm with concomitant operations*. Ann Thorac Surg 2004;78:858-61.
4. Okada K, Omura A, Kano H, et al. *Short and midterm outcomes of elective total aortic arch replacement combined with coronary artery bypass grafting*. Ann Thorac Surg 2012;94:530-6.

5. Safi HJ, Miller CC 3rd, Lee TY, Estrera AL. *Repair of ascending and transverse aortic arch.* J Thorac Cardiovasc Surg 2011;142:630-3.
6. Lytle BW, Mahfood SS, Cosgrove DM, Loop FD. *Replacement of the ascending aorta: early and late results.* J Thorac Cardiovasc Surg 1990;99:651-7.
7. Akgun S, Atalan N, Fazliogullari O, Kunt AT, Basaran C, Arsan S. *Aortic root aneurysm after off-pump reduction aortoplasty.* Ann Thorac Surg 2010;90:e69-70.
8. Polvani G, Barili F, Dainese L, et al. *Reduction ascending aortoplasty: midterm follow-up and predictors of redilatation.* Ann Thorac Surg 2006;82:586-91.