

## Successful Surgical Resection of Advanced Gastrointestinal Stromal Tumor Post Neoadjuvent Therapy

Kamil SM, Biswas M, Imran AK, Islam R, Mukhtar AA and Joshi SC

Advanced Medical & Dental Institute, Universiti Sains Malaysia, Penang, Malaysia

**Abstract:** We report a case of a 48-year-old Indian male who presented with swelling and firmness in his left upper part of the abdomen of one month duration with anorexia and weight loss. Initial examination revealed an intra abdominal mass of around 16.8x11.0x24.5cm with minimal left sided pleural effusion. A biopsy from the mass confirmed the diagnosis of gastrointestinal stromal tumour (GISTs) as supported by immunohistochemistry results which showed strong positivity for c-kit while stains for smooth muscle actin, desmin, myoglobin, S100 Protein and cytokerstin remained negative. The patient was not suitable for surgical intervention in view of advanced tumor, and Imatinib Mesylate 400mg daily was started with the aim of making the tumor operable. Such therapy lasted for twenty months and was tolerated well by the patient. It then resulted in gradual tumor regression, following which the patient underwent successful tumor resection. Post surgical resection patient had no radiological evidence of intra abdominal tumor but mild left sided pleural effusion with left lower lobe atelectasis. The patient had uneventful post operative recovery and he is currently on Imatinib mesylate and tolerating treatment well with mild skin rash. The experience with preoperative imatinib on surgical resection rates and post operative outcomes is limited especially with primary locally advanced GISTs. In our case successful surgical resection was possible for a huge locally advanced GIST with unusually prolonged treatment of twenty months with imatinib preoperatively.

**Key words:** *Imatinib mesylate, Immunohistochemistry, Gastrointestinal stromal tumor, Surgery*

### Introduction

Gastrointestinal stromal tumors (GISTs) are considered the most common mesenchymal tumors of gastrointestinal tract (GI), arising from the mesenchymal stem cells that latter on differentiate in to pacemaker cells of GI tract (cells of Cajal), responsible for peristaltic activity in GI tract. Demonstration of KIT tyrosine kinase activity in GIST tumorigenesis has identified a target for therapy. Imatinib is an inhibitor of mutated activated isoform of KIT tyrosine kinase [1].

The literature about GISTs remains confusing because tumor classification and terminology are being continually refined. Furthermore, the exact definition of GISTs varies among authors. Some use the term to describe any GI submucosal mesenchymal tumor that is not myogenic (e.g, leiomyosarcoma) or neurogenic (eg, schwannoma) in origin. Others are more restrictive and use the term when specifically referring [2].

Histologically, the number of mitotic figures is used to decide on grading of GISTs, but no standard exists for classification. In general, tumors with less than 1 mitotic figure per 50HPFs are considered benign, while 1-5 per 10HPFs as potential malignant and more than 5 per 10HPFs as malignant. Clinical presentation ranges from asymptomatic tumors being discovered during surgery for other indication to tumors as big as 30cm [3].

Before the availability of imatinib complete surgical resection of metastatic or recurrent GIST was achieved in only one third of patients with overall five year survival approximately 20% [2]. Current trend is to use imatinib for locally advanced metastatic or recurrent GIST as first line and then consider surgical resection for residual disease. Use of imatinib preoperatively to make tumor operable has variable response rates. In our case, the unusually prolonged treatment for twenty months resulted in significant tumor reduction to allow surgical resection.

### Case report

A 48-year-old Indian male presented with history of swelling and firmness in his left upper part of abdomen of one month duration associated with lethargy and loss of appetite. The swelling gradually enlarged over the period of time and involved left hypochondriac and lumbar regions before presentation. He denied any bowel symptoms but gradual weight loss was noted, which was not documented by the patient.

On Examination he was mildly pale but neither jaundice nor lymphadenopathy were noticed, abdominal examination revealed a huge mass extending from left hypochondriac region down to left iliac fossa and up to umbilicus medially but no ascites detected.

Workup showed Hemoglobin of 9.4gm/dl but renal and liver function tests were within normal range.

A CT scan abdomen and thorax was ordered which showed a large fairly well circumscribed heterogeneously enhancing mass in the left side of the abdomen extending up to the left iliac fossa measuring 16.8x11.0x24.5cm. The mass was displacing the stomach to the right side and pancreas posteriorly, liver, spleen and kidneys appeared normal (Fig. 1). A differential diagnosis of leiomyosarcoma, fibrous histiocytoma and fibrosarcoma was suggested.

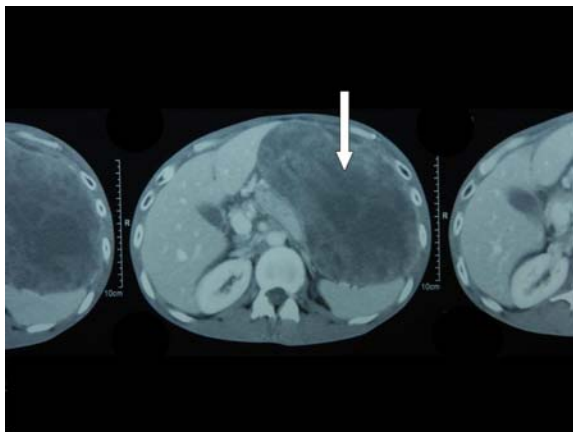
Biopsy from the mass suggested the diagnosis of malignant gastrointestinal stromal tumor as supported by high expression for c-kit, vimentin and negative staining for smooth muscle actin, desmin, myoglobin, S100 and cytokeratin on immunohistochemistry.

Because the patient was not keen for surgical intervention, he was given a trial of neoadjuvent imatinib mesylate at a dose of 400mg daily to be continued till tumor became operable.

Therapy was continued for twenty months and patient reassessment was done in between for tumor response

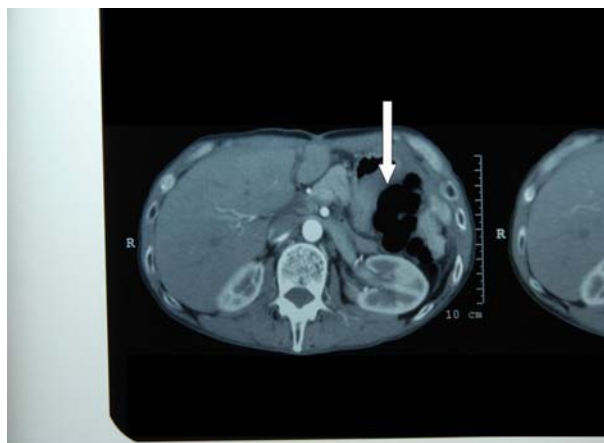
with repeated C.T. scan every two to three months. Only after twenty months of therapy the tumor was reduced to 15.2x7x23cm, which was then considered for surgical excision.

The patient tolerated therapy well and apart from mild desquamating rash no serious side effect was noted, and he underwent repeated liver function tests throughout the study period.



**Figure 1** Intra abdominal tumor at presentation

A surgical attempt was made after the patient consented to the procedure and the tumor was successfully removed. The patient had an uneventful surgical outcome and repeated C.T. scan post operatively did not show any residual tumor (Fig. 2). The patient is currently followed up with no symptoms at present and he is tumor-free.



**Figure 2** Successful surgical resection of intra abdominal tumor post imatinib treatment.

## Discussion

So far surgery has been the standard treatment for primary resectable GISTs [4]. We have limited data on the role of neoadjuvant imatinib mesylate for the treatment of GISTs and most evidence comes from anecdotal cases or case series demonstrating benefits of neoadjuvant imatinib mesylate [5-6]. Ongoing trials by radiation therapy and oncology group (RTOG-S-0132) [7] and M.D Anderson [8]. are evaluating the role of preoperative imatinib on the treatment of localized or metastatic GISTs.

Patients treated with preoperative imatinib tend to have better median disease free survival compared to previously reported eighteen month-survival before the availability of imatinib [9].

The role of tumor debulking is not established in GISTs. The median postoperative survival has ranged from two to twenty months after tumor resection in this situation.

Although complete surgical resection is possible in patients receiving preoperative (Neoadjuvant) imatinib for recurrent or metastatic GISTs but optimal timing for surgical resection is not known. In view of encouraging results with preoperative imatinib many centres are now adopting the strategy.

Scaife et al. studied 126 patients, of these, 17 have subsequently undergone surgical resection after a median of 10 months of treatment with imatinib. Based on computed tomographic (CT) scanning, 1 (6%) patient had evidence of a complete tumor response, 12 (70%) patients had a partial response, 3 (24%) patients had stable disease, and 1 (6%) patient had progressive disease [10].

As per ESMO (European Society for Medical Oncology) recommendation, neoadjuvant imatinib is advised for cytoreduction to decrease tumor bleeding and risk of tumor rupture, a usual 6-12 months period of neoadjuvant therapy is advised. Standard treatment for GIST is complete surgical resection, without dissection of clinically negative nodes. Given the efficacy of imatinib in the disease, adjuvant treatment with the drug has been studied but so far no definitive evidence is available to recommend the drug in this setting. In locally advanced inoperable tumors and metastatic tumors, imatinib is the standard treatment, this applies to metastatic patients who have been completely free of disease by virtue of previous surgery and discovered unexpectedly.

The standard dose of imatinib is 400mg daily. Patients carrying mutation in exon 9 KIT fare better with a higher dose of up to 800mg daily, which is therefore a standard treatment in this subgroup. Close monitoring of tumor response is needed since the risk of secondary progression persists. Complete excision of residual has been related to good prognosis but the possibility of selection bias cannot be ruled out, therefore surgery in metastatic tumors responding to imatinib remains investigational. The standard approach in case of tumor progression is to increase the dose of imatinib up to 800mg daily especially with tumors carrying exon 9 KIT mutations. Patients who are non-compliant to treatment should be ruled out [11].

So far, the reported usual median time for treatment response in locally advanced tumor is up to 6 to 12 months, neoadjuvant therapy with imatinib should be attempted in locally advanced GISTs [11].

The reason for tumor response in our case was likely due to high positivity for c-kit tyrosine kinase. This case reinforces the evolving role of neoadjuvant therapy for locally advanced or metastatic GISTs. Preoperative treatment should be continued if no disease progression is noted. Tumor density change on CT scan or MRI scans is

an indicator of tumor response, however PET scan is a better tool for tumor response assessment. Tumor size may not decrease although tumor may be responding [11]. In our case it took twenty months of therapy with imatinib to make tumor excision possible.

### References

1. Buchdunger E, Cioffi CL, Law N, et al: Abl protein -tyrosine kinase inhibitor ST1571 Inhibits in vitro signal transduction mediated by c-kit and platelet -derived growth factor receptors. *J Pharmacol Exp Ther.* 2000;295(1):139-45.
2. Cichoż-Lach H, Kasztelan-Szczerbinska B, Słomka M. Gastrointestinal stromal tumors: epidemiology, clinical picture, diagnosis, prognosis and treatment. *Pol Arch Med Wewn.* Apr 2008; 118(4):216-21.
3. Miettinen M, Lasota J. Gastrointestinal stromal tumors--definition, clinical, histological, immunohistochemical, and molecular genetic features and differential diagnosis. *Virchows Arch.* Jan 2001; 438(1):1-12.
4. Mudan SS, Conlon KC, Woodruff JM, Lewis JJ, Brennan MF. Salvage surgery for patients with recurrent gastrointestinal sarcoma: prognostic factor to guide patient selection. *Cancer.* 2000; 88(1):66-74.
5. Katz D, Segal A, Alberton Y, et al. Neoadjuvant imatinib for unresectable gastrointestinal stromal tumor. *Anticancer Drugs.* 2004; 15(6):599-602.
6. Bummig P, Andersson J, Meis kindblom JM, et al. Neoadjuvant, adjuvant and palliative treatment of gastrointestinal stromal tumors with imatinib: a centre-based study of 17 patient. *Br J cancer.* 2003; 89(3):460-4
7. Trent J, Hunt KK. A prospective, randomized, phase II study of preoperative plus postoperative imatinib mesylate (Gleevec, formerly STI-571) in patients with primary, recurrent or metastatic resectable, kit expressing, gastrointestinal stromal tumor (GIST). Available: <http://www.utm-ext01a.mdacc.tmc.edu/dept/prot/clinical/trialswp.nsf/index/id03-0023>.
8. Eisenberg B. A phase II trial neoadjuvant /adjuvant STI 571(Gleevec NSC 716051) for primary and recurrent operable malignant GIST expressing KIT receptor tyrosine kinase(CD117). Available: <http://www.rtog.org/members/protocols/s0132/s0132.pdf>
9. Ng EH, Pollok RE, Romsdahl MM. Prognostic implications of patterns of failure for gastrointestinal leiomyosarcomas. *Cancer.* 1992; 69(6):1334-41.
10. Scaife CL, Hunt KK, et al. Is there a role for surgery in patients with "unresectable" cKIT+ gastrointestinal stromal tumors treated with imatinib mesylate?. *Am J Surg.* 2003 Dec; 186(6):665-9.
11. P.G. Casali, et al. Gastrointestinal stromal tumors: ESMO clinical recommendation for diagnosis, treatment and follow-up. *Ann of oncology.* 2008; 19(supplement 2):1135-1138.