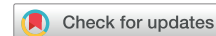

Expanding the Spectrum of *FAT1* Nephropathies by Novel Mutations That Affect Hippo Signaling



Francesca Fabretti^{1,2,3,9}, Nikolai Tschernoster^{4,5,9}, Florian Erger⁴, Andrea Hedergott⁶, Anja K. Buescher⁷, Claudia Dafinger^{1,8}, Bjoern Reusch⁴, Vincent K. Körtges^{1,2,3}, Stefan Kohl⁸, Malte P. Bartram^{1,2}, Lutz Thorsten Weber⁸, Holger Thiele⁵, Janine Altmueller⁵, Bernhard Schermer^{1,2,3}, Bodo B. Beck⁴ and Sandra Habbig⁸

¹Department II of Internal Medicine, University of Cologne, Faculty of Medicine and University Hospital Cologne, Cologne, Germany; ²Center for Molecular Medicine Cologne (CMMC), University of Cologne, Faculty of Medicine and University Hospital Cologne, Cologne, Germany; ³Cologne Excellence Cluster on Cellular Stress Responses in Aging-Associated Diseases (CECAD), University of Cologne, Cologne, Germany; ⁴Institute of Human Genetics, University of Cologne, Faculty of Medicine and University Hospital Cologne, Cologne, Germany; ⁵Cologne Center for Genomics, University of Cologne, Cologne, Germany; ⁶Department of Ophthalmology, University of Cologne, Faculty of Medicine and University Hospital Cologne, Cologne, Germany; ⁷Children's Hospital, Pediatrics II, University of Duisburg-Essen, Essen, Germany; and ⁸Department of Pediatrics, University of Cologne, Faculty of Medicine and University Hospital Cologne, Cologne, Germany

Introduction: Disease-causing mutations in the protocadherin *FAT1* have been recently described both in patients with a glomerulotubular nephropathy and in patients with a syndromic nephropathy.

Methods: We identified 4 patients with *FAT1*-associated disease, performed clinical and genetic characterization, and compared our findings to the previously published patients. Patient-derived primary urinary epithelial cells were analyzed by quantitative polymerase chain reaction (qPCR) and immunoblotting to identify possible alterations in Hippo signaling.

Results: Here we expand the spectrum of *FAT1*-associated disease with the identification of novel *FAT1* mutations in 4 patients from 3 families (homozygous truncating variants in 3, compound heterozygous missense variants in 1 patient). All patients show an ophthalmologic phenotype together with heterogeneous renal phenotypes ranging from normal renal function to early-onset end-stage kidney failure. Molecular analysis of primary urine-derived urinary renal epithelial cells revealed alterations in the Hippo signaling cascade with a decreased phosphorylation of both the core kinase MST and the downstream effector YAP. Consistently, we found a transcriptional upregulation of *bona fide* YAP target genes.

Conclusion: A comprehensive review of the here identified patients and those previously published indicates a highly diverse phenotype in patients with missense mutations but a more uniform and better recognizable phenotype in the patients with truncating mutations. Altered Hippo signaling and depressed YAP activity might be novel contributing factors to the pathomechanism in *FAT1*-associated renal disease.

Kidney Int Rep (2021) 6, 1368–1378; <https://doi.org/10.1016/j.ekir.2021.01.023>

KEYWORDS: children; genetic kidney disease; Hippo signaling; podocyte; TAZ; YAP

© 2021 International Society of Nephrology. Published by Elsevier Inc. This is an open access article under the CC BY-NC-ND license (<http://creativecommons.org/licenses/by-nc-nd/4.0/>).

The rapid development of novel sequencing technologies has substantially improved molecular diagnosis of genetic kidney diseases in children and adults. The continuous identification of novel disease-

causing genes and new genotypes in established monogenic disorders is a powerful and effective approach to gain deeper insights in underlying pathogenic mechanisms of renal disease. This is the prerequisite to ultimately develop specific therapeutic strategies to improve the treatment of these genetic diseases. Affected proteins in genetic kidney diseases show a huge variety of different expression patterns and molecular functions. Subsequently, phenotypes can range from an isolated kidney pathology with only 1 specific cell type affected (e.g., podocytes in *NPHS1*-associated congenital nephrotic syndrome¹) to a syndromic

Correspondence: Sandra Habbig, Department of Pediatrics, University of Cologne, Faculty of Medicine and University Hospital Cologne, Kerpener Str. 62, 50935 Cologne, Germany. E-mail: sandra.habbig@uk-koeln.de

⁹FF and NT are co-first authors.

Received 19 October 2020; revised 15 January 2021; accepted 18 January 2021; published online 29 January 2021

phenotype with 2 or more organ systems involved (e.g., autosomal dominant or recessive polycystic kidney disease (ADPKD, ARPKD), or nephronophthisis (NPH) and nephronophthisis-related ciliopathies).² As to the kidney, the disease-causing phenotype is often restricted to 1 distinct population of epithelial cells and leads to pathologies, for example, in either podocytes or tubular epithelial cells in specific segments of the nephron. Interestingly, mutations in the gene encoding for the giant protocadherin FAT1 have been identified in a subset of patients, with very heterogeneous phenotypes displaying isolated kidney disease in some and multisystemic disorders in other cases.^{3–7} This kidney disease has been characterized as a glomerulotubular nephropathy because both podocytes and tubular cells are affected.⁵ Consistently, podocyte-specific loss of *FAT1* in mice leads to severe glomerular disease,⁵ whereas loss of *FAT1* in zebrafish causes cyst formation in the pronephros which is ameliorated by depletion of the Hippo effector Yap1.⁸ Interestingly, somatic mutations in *FAT1* have been identified in numerous tumor diseases and, consistent with the observation in zebrafish,⁸ *FAT1* has been shown to be a potent regulator of Hippo signaling,^{9–12} a well-established tumor-suppressor pathway. The Hippo pathway has also been shown to be associated to several kidney diseases,^{8,13–22} with evidence for both overactivation and inactivation of Hippo signaling as possible pathomechanisms.

We here report 4 patients from 3 families with *FAT1*-associated syndromic nephropathy caused by novel mutations that have been identified within the framework of our clinical research unit (CRU329) during the last 12 months. In addition, we present first evidence that loss of *FAT1* leads to dysregulation of the Hippo pathway.

PATIENTS AND METHODS

Patients

All patients were analyzed within an interdisciplinary approach of our clinical research unit (CRU329). The study was approved by the ethics committee of the University Hospital Cologne, Germany (15-215). DNA samples were obtained with written informed consent from their guardians, and clinical and biochemical data were collected retrospectively from medical charts.

Genetic Analysis

A custom gene panel consisting of 122 genes that are associated with monogenic forms of proteinuria, as well as other nephropathies with possible concomitant proteinuria, was used (CRU329 Nephropathy Plus Proteinuria Gene Panel; see [Supplementary Table S1](#)).

Whole exome sequencing was performed using the Agilent SureSelect Human All Exom V7 enrichment (Agilent Technologies Inc., Santa Clara, CA) followed by next-generation sequencing on an Illumina HiSeq 4000 sequencing platform (Illumina, San Diego, CA). TruSight One gene panel sequencing was performed on an Illumina HiSeq 2500 sequencing platform. WES and gene panel data analysis and filtering of variants were carried out using the exome and genome analysis pipeline “Varbank2, varpipe v.3.3” of the Cologne Center for Genomics (University of Cologne). Variants were classified in accordance with the ACMG standards and guidelines for the interpretation of sequence variants.²³

Ophthalmologic Examination

Ophthalmologic examination comprised refraction, best-corrected visual acuity (BCVA), anterior segment examination, funduscopy with dilated pupil and fundus photography, cycloplegic refraction, and an orthoptic examination. The orthoptic examination included measurement of binocular functions with Bagolini striated glasses test, Lang test, and evaluation of oculomotor findings such as smooth pursuit and saccades. Strabismus was examined by prism-cover test and by alternating cover test with prism at near and far fixation.

Isolation and Culture of Patient-Derived Primary Urine-Derived Renal Epithelial Cells

The protocol for the generation of primary urinary epithelial cells was performed as previously described.²⁴ Urine-derived epithelial cells were cultured from patients 2 and 3 and from 6 healthy controls. Briefly, the urine collected was transferred in 1 or more 50-ml tubes and centrifuged at 400 × *g* for 10 minutes at room temperature. The pellets were washed in wash buffer (1X phosphate-buffered saline + 100 U/ml penicillin + 100 µg/ml streptomycin + 500 ng/ml amphotericin B) and centrifuged at 200 × *g* for 10 minutes at room temperature. After that, the pellets were resuspended in 2 ml of Dulbecco’s modified Eagle’s medium (DMEM)–nutrient mixture F-12 ham (Sigma D6421; Sigma-Aldrich, St. Louis, MO) containing 10% fetal bovine serum, 1% GlutaMAX, 100 U/ml penicillin, 100 µg/ml streptomycin, 500 ng/ml amphotericin B, REGM renal epithelial cell growth medium SingleQuots Kit supplements (Lonza CC-4127; Lonza, Basel, Switzerland) and transferred in a 12-well plate, previously coated with 0.1% sterile gelatin for 30 minutes at 37 °C. The plates were then incubated at 37 °C in the presence of 5% CO₂, and the first colonies were visible after 4 to 5 days. Once colonies were visible, the cells were switched to proliferation medium (1:1

mixture from renal epithelial and mesenchymal cells medium). The renal epithelial medium was purchased (CC-3190 + Supplements; Lonza). The mesenchymal cell medium was prepared with DMEM with high glucose (Gibco, Waltham, MA) containing 10% fetal bovine serum, 100 U/ml penicillin, 100 µg/ml streptomycin, 1% nonessential amino acid solution (Gibco), 5 ng/ml fibroblast growth factor–basic (PeproTech, Rocky Hill, NJ), 5 ng/ml platelet-derived growth factor–AB (PeproTech) and 5 ng/ml epidermal growth factor (PeproTech). When the cells reached a confluency of 70% to 80%, they were passaged using TrypsinLE (Gibco).

Quantitative Real-Time PCR

The primary urine-derived renal epithelial cells were harvested and frozen at -80°C in TRI Reagent (Sigma). RNA was extracted with Direct-zol RNA Miniprep kit (Zymo Research, Irvine, CA) following manufacturer instructions and cDNA was reverse transcribed using a high-capacity cDNA reverse transcription kit (Thermo Fisher Scientific, Waltham, MA) according to manufacturer instructions. Quantitative real-time PCR was performed on a QuantStudio 12K Flex system cyclometer (Thermo Fisher Scientific) using 2 ng of reverse-transcribed RNA per well and TaqMan Gene Expression Master Mix (Thermo Fisher Scientific) according to manufacturer instructions. The probe-based assays used are listed in [Supplementary Table S2](#).

The relative quantity was calculated using the $\Delta\Delta\text{Ct}$ method. Briefly, the expression of each gene was normalized vs the amplification of either *HPRT*, *GAPDH*, or *POLR2A*, calculating the ΔCt . The relative quantity was calculated using as reference the average ΔCt of all 5 healthy controls. Relative quantities were then transformed in \log_2 and analyzed for significance using *t* test (GraphPad Prism 8; GraphPad Software Inc., San Diego, CA).

Immunoblotting

Whole protein lysates were prepared from primary urine-derived renal epithelial cells resuspending cell pellets in $1\times$ sodium dodecyl sulfate (SDS) sample buffer and boiling at 95°C for 5 minutes. Proteins were separated by SDS polyacrylamide gel electrophoresis. After transfer onto a polyvinylidene fluoride membrane, and blocking in 5% bovine serum albumin, the membranes were stained with anti phospho-Mst1 (Thr183) / Mst2 (Thr180), anti-MST1, anti-GAPDH, anti-phospho-YAP (Ser127), anti-YAP, and anti-CDC42 (Cell Signaling Technology, Inc., Danvers, MA, catalog nos. 3681, 3682, 5174, 13008, 14074; and BD Biosciences, Franklin Lakes, NJ, catalog no. 610928). The signal was visualized using enhanced

chemiluminescence after incubation of the membranes with secondary antibodies conjugated to horseradish peroxidase. Images were acquired with a Fusion Solo S (Vilber Lourmat Germany GmbH, Eberhardzell, Germany). Densitometric analysis was performed using the software Image Studio, version 5.2 (LI-COR Biosciences GmbH, Hamburg, Germany).

Systematic Literature Review

A systematic literature review on patients with mutations in the *FAT1* gene was performed. The genotypes and phenotypes identified in this study were discussed in relation to the previously described patients.

RESULTS

Genetic Data

Patient 1 (*2006) is the offspring of consanguineous parents ([Figure 1a](#)). By gene panel analysis, a novel homozygous nonsense variant (c.5648T>A) in exon 10 of the *FAT1* gene was identified. This variant results in a premature stop codon at position 1883 (p.Leu1883*) ([Figure 1b](#)). Segregation analysis confirmed the variant in a heterozygous state in both healthy parents. The homozygous stop mutation was also identified in his younger sister (patient 2, *2015). The variant was absent from the genome aggregation database (gnomAD, last accessed in December 2020; [Table 1](#)).

In patient 3, gene panel analysis identified the homozygous frameshift variant c.8446_8447dupGC in exon 10 of the *FAT1* gene (p.Phe2817Hisfs*13). This variant has not been described before and was not found in the gnomAD database. Segregation analysis confirmed the variant in a heterozygous state in both consanguineous parents. In patients 1 to 3, no other causative mutation was identified in the gene panel analysis.

Patient 4 is the son of nonconsanguineous partners and had previously received comprehensive genetic testing with karyotyping, array comparative genomic hybridization, targeted Sanger sequencing of the genes *LAMB2*, *LAMC1*, *PLCE1*, *WT1*, and *SMARCA1* and TruSight One gene panel sequencing, which all yielded unremarkable results. The most recent gene panel analysis identified 2 missense variants in the *FAT1* gene, later confirmed to be in a compound-heterozygous state: c.2563G>A (p.Gly855Arg) in exon 2 and c.5539G>A (p.Val1847Ile) in exon 10. Because both variants were classified as variants of unknown significance, a trio exome (both parents and the patient) analysis was performed. This analysis confirmed the compound-heterozygosity for the aforementioned *FAT1* variants, but identified no *de novo* variants in the patient. Biallelic variants in only 4 other OMIM annotated genes (*RLF*, *ASAP3*, *DNAH14*, and

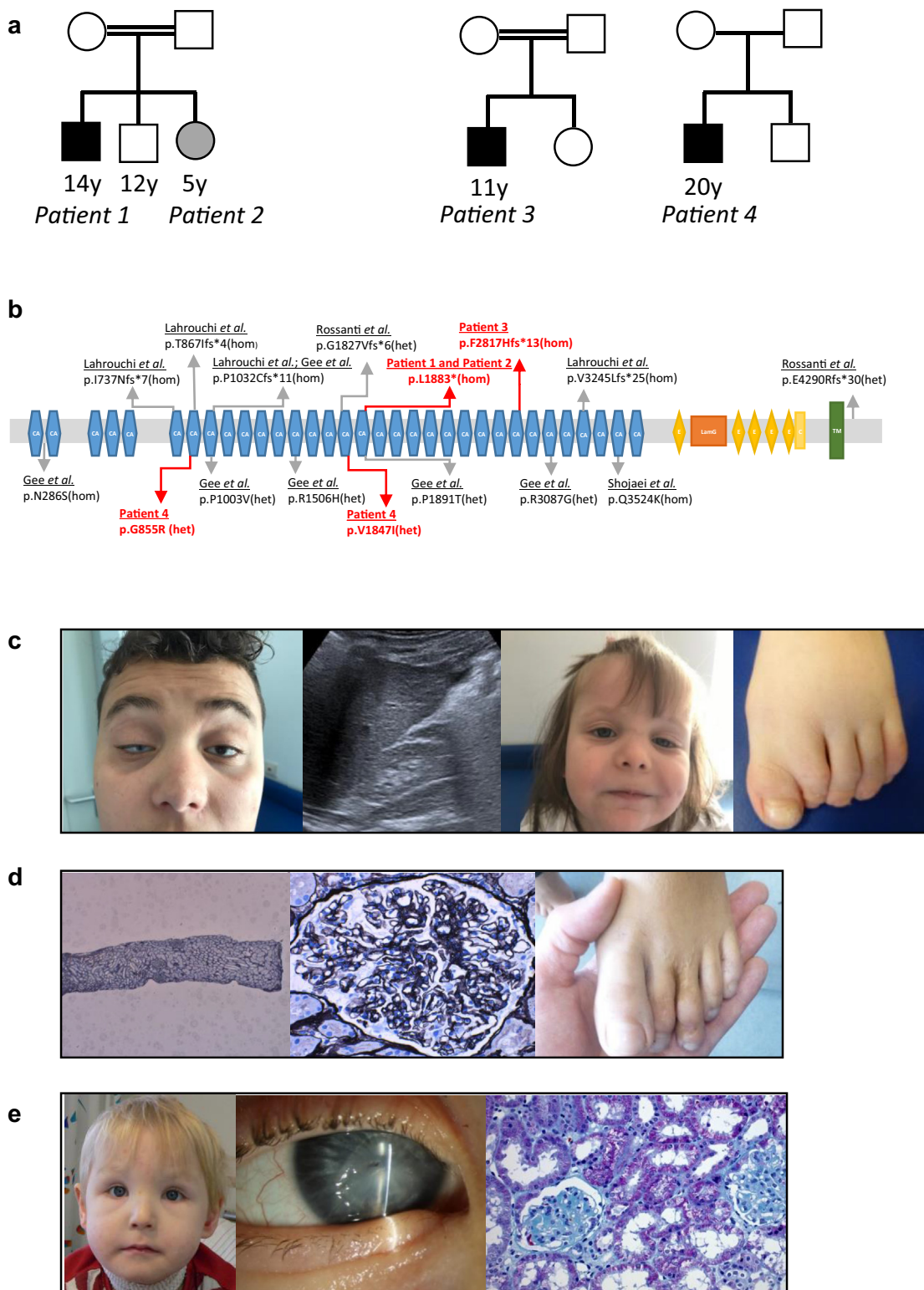


Figure 1. Genetic and clinical overview of the 4 patients with *FAT1*-associated disease. (a) Pedigrees of the 3 families. (b) Schematic view of the *FAT1* protein domains. The *FAT1* protein consists of 33 cadherin domains (CA), 1 laminin G domain (LamG), 5 epidermal growth factor–like domains (E), a calcium-binding domain (C) and the transmembrane domain (TM). Mutations previously described are labeled in black, novel mutations identified in this study are labeled in red. Truncating mutations are indicated above the protein scheme, missense mutations below the protein scheme. (c) Bilateral ptosis, highly arched eyebrows, and ultrasonography of the hypodysplastic right kidney of patient 1 and typical eye phenotype and feet syndactyly of patient 2. (d) Kidney biopsy in patient 3 showed low glomerular density and glomerular hypertrophy (300 μ m). Syndactyly was surgically resolved in patient 3. (e) Highly arched eyebrows in patient 4 (left), anterior segment changes: micropupil, shallow anterior chamber, and trophic corneal ulcer (middle) OD; kidney biopsy in patient 4 showed diffuse mesangial sclerosis (DMS). hom, homozygous; het, heterozygous.

Table 1. Detected *FAT1* variants in 4 patients from 3 families

Patient, sex, age at investigation	Ethnic origin	Consanguinity	Nucleotide change	Exon (zygosity)	Amino acid change	Cadherin domain	Mutation taster	Frequency in gnomAD database
Patient 1, male, 14 yr	Syrian	Yes	c.5648T>A (novel)	10 (homozygous)	p.Leu1883*; truncating			
Patient 2, female, 5 yr, sister of patient 1	Syrian	Yes	c.5648T>A (novel)	10 (homozygous)	p.Leu1883*; truncating	17	Disease causing	None
Patient 3, male, 5 yr	Turkish	Yes	c.8446_8447dupGC (novel)	10 (homozygous)	p.Phe2817Hisfs*13; truncating	26	Disease causing	None
Patient 4, male, 20 yr	German	No	c.2563G>A (novel) c.5539G>A (novel)	2 10 (compound heterozygous)	p.Gly855Arg p.Val1847Ile 2 missense mutations	7 16	Disease causing Disease causing	0.21% 0.002%

FBN3) were identified. Variants in *RLF*, *ASAP3*, and *DNAH14* have not been associated with a human disease phenotype so far. Two other compound-heterozygous variants in *FBN3*—different from the variants identified in patient 4—were previously reported to segregate in a Chinese family in 2 siblings affected with a Bardet-Biedl syndrome-associated disease without renal manifestation.²⁵

The homozygous truncating mutations identified in patients 1 to 3 and the compound heterozygous missense mutations identified in patient 4 are located to the cadherin repeats as outlined in the schematic of the FAT1 protein (Figure 1b).

Clinical Presentation

The diagnosis of bilateral kidney hypodysplasia in patient 1 was made at the age of 2 years. He was then lost to follow-up and presented to the hospital with acute appendicitis at the age of 9 years. Laboratory evaluation revealed end-stage kidney disease, and peritoneal dialysis was initiated immediately. The

family then moved to Germany, and the patient received a living donor kidney transplant from his mother at the age of 11 years. At first clinical evaluation in Germany, his protein-creatinine ratio was elevated (3000 mg/g creatinine) with normal serum albumin. Kidney graft function is optimal at current investigation at the age of 14 years. Extrarenal symptoms are summarized in Table 2. His sister (patient 2) was born in 2015 and presented with bilateral ptosis (Figure 1c). Webbed toes (1 and 2) on the left foot were revised surgically (Figure 1c). At current investigation at the age of 5 years, there is no sign of proteinuria, arterial hypertension, or decreased kidney function in patient 2, and kidney ultrasonography shows no abnormality.

Patient 3 presented at the age of 6 months with recurrent urinary tract infections. A voiding cystourethrography identified a bilateral vesicoureteral reflux grade 3 that spontaneously resolved. At the age of 2 years, he was diagnosed with gross albuminuria (albumin-creatinine ratio 1000 mg/g creatinine) and arterial

Table 2. Synopsis of clinical findings in the patients with *FAT1* mutations

	Renal phenotype (age of onset)		Ocular manifestation	Further (extrarenal/extraocular) manifestations
	Glomerular	Other		
Patient 1	Proteinuria (protein-creatinine: 3000 mg/g at ESKD)	Kidney hypodysplasia ESKD/peritoneal dialysis (9 yr) Living-donor KTx (11 yr)	Congenital ptosis OD>OS Highly arched eyebrows Microphthalmos OD>OS with corneal opacity OD>OS, shallow anterior chamber, corectopia Lower eyelid entropion (OS) Visual impairment OD>OS	Syndactyly toes 2 and 3 (bilateral) Brachytelephalangy digitus 3, left hand Small pineal cyst Elevation of transaminases and LDH (with normal liver synthesis)
Patient 2	None	None	Congenital ptosis OS>OD	Syndactyly toes 1 and 2, left foot Mild psychomotor delay
Patient 3	Proteinuria (2 yr) Glomerular hypertrophy, low glomerular density (biopsy, 5 yr) CKD 3 (10 yr)	Vesicoureteral reflux (6 mo), spontaneous resolution at 2 yr of age	Myopia OD/OS Astigmatism OS Mild ptosis OS>OD Highly arched eyebrows	Recurrent pulmonary infections (first years of life) Bronchial asthma Syndactyly toes 1 and 2, right foot and Syndactyly toes 2 and 3, left foot
Patient 4	Nephrotic range proteinuria (6 yr) Diffuse mesangial sclerosis (biopsy, 6 yr) ESKD/hemodialysis (7 yr) KTx (9 yr)	Tubular ectasia and atrophy (biopsy, 6 yr)	Anterior segment dysgenesis Bilateral microcoria Shallow anterior chamber Bilateral neurotrophic keratopathy with trophic corneal ulcer OD and mild ptosis OD High hyperopia OD/OS Astigmatism OS Reduced visual acuity	Severe psychomotor developmental delay Epileptic seizures Deafness Congenital hypothyroidism Hypophyseal adenoma Post-transplant diabetes

CKD 3, chronic kidney disease stage 3; ESKD, end-stage kidney disease; KTx, kidney transplant; LDH, lactate dehydrogenase; OD, oculus dexter; OS, oculus sinister.

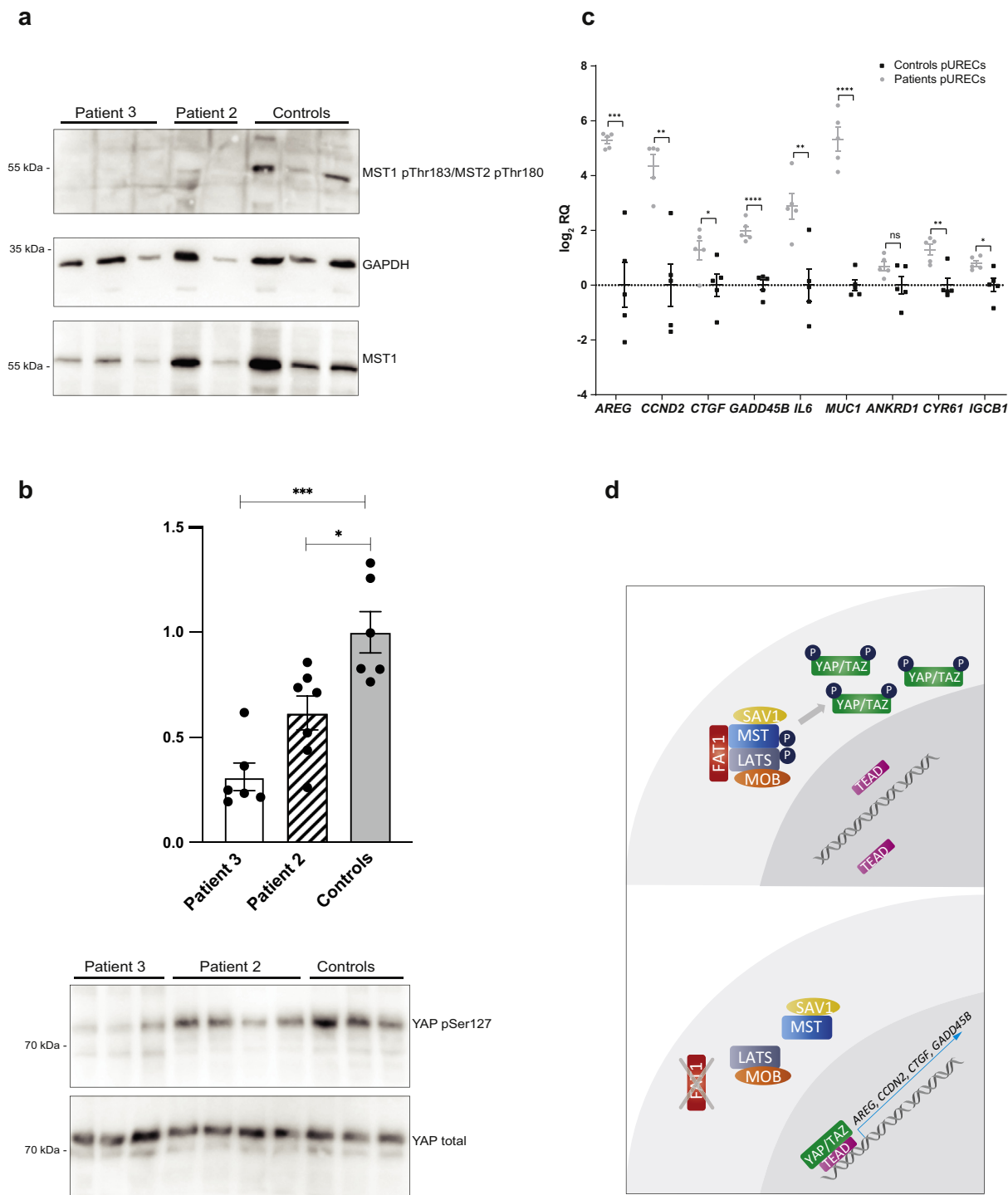


Figure 2. Dysregulation of Hippo signaling in patient-derived cells. Protein extracts from primary urine-derived renal epithelial cells (pURECs) derived from patients 3 and 2 showed a decreased phosphorylation of the central Hippo kinase MST (MST1 pThr183/MST2 pThr180) in Western blot, compared with cells derived from healthy individuals. (a) Western blot for MST1 and GAPDH was performed as loading control. (b) Protein extracts from pURECs derived from patients 3 and 2 showed a significantly decreased phosphorylation on YAP Ser127 relative to the total amount of YAP ($P < 0.05$) as shown in the Western and in the densitometric analysis. Bars show the SEM, and asterisks indicate statistical significance: * $P < 0.05$ and *** $P < 0.005$. (c) qPCR performed on RNA derived from those cells confirmed the upregulation of the Hippo target genes. Bars show the SEM, and statistical significance is indicated by asterisks as follows: * $P < 0.05$, ** $P < 0.01$, *** $P < 0.005$, **** $P < 0.001$. (d) Schematic representation of a possible pathomechanism in FAT1 nephropathy. In healthy individuals (upper panel), Hippo signaling is active: the core kinase MST is phosphorylated, resulting in phosphorylation (and inactivation) of the effector proteins YAP and TAZ that are retained in the cytoplasm. Loss of FAT1 results in inactivation of MST1/2 (decreased phosphorylation) and subsequent nuclear translocation of the active (dephosphorylated) effector proteins YAP and TAZ, which act as transcriptional coactivators (lower panel). ns, not significant; SEM, standard error of the mean.

hypertension. Kidney function was normal. Therapy with renin-angiotensin-aldosterone system inhibition and β -blockers resulted in normalized blood pressure and temporarily decreased proteinuria. Renal biopsy was performed at the age of 5 years because of increased albuminuria and showed severe glomerular hypertrophy and low glomerular density without any signs of focal segmental glomerulosclerosis (Figure 1d). Since the age of 10 years, patient 3 presents with nephrotic range proteinuria and constantly decreasing kidney function (current glomerular filtration rate [full age spectrum equation] 50–60 ml/min). Syndactyly on both feet (syndactyly toes 1+2 right, 2+3 left) was surgically managed in early childhood. His eye phenotype includes the typical bilateral ptosis and highly arched eyebrows.

Patient 4 presented at the age of 6 years to our unit with nephrotic range proteinuria. Kidney biopsy showed diffuse mesangial sclerosis and partial tubular ectasia (Figure 1e). Renal function rapidly declined and hemodialysis was initiated at the age of 7 years. The patient received a cadaveric-donor kidney transplant at the age of 9 years with good transplant function during the last 12 years. Furthermore, the patient presents with a severe psychomotor delay, deafness, and recurrent epileptic seizures. His eye phenotype comprises anterior segment dysgenesis, bilateral microcoria, shallow anterior chamber, bilateral neurotrophic keratopathy with trophic corneal ulcer and mild ptosis (oculus dexter), bilateral high hyperopia, astigmatism, and severely reduced visual acuity (Figure 1e). These findings were consistent with microphthalmos, but determination of the axial length was not possible because of a lack in cooperation.

Analysis of Primary Urine-Derived Renal Epithelial Cells From Patients

As *FAT1* is known to regulate the Hippo signaling pathway in the fly¹² and in certain types of cancer cells,⁹ we aimed to analyze possible alterations in Hippo signaling activity in our patients and therefore isolated primary urine-derived renal epithelial cells from the 2 patients with naïve kidneys (patients 2 and 3) and from healthy controls. Protein lysates from those cells were analyzed for expression and phosphorylation of components of the Hippo pathway. This revealed decreased phosphorylation of MST1/2, the ortholog of the Hippo kinase in *Drosophila*, in cells from the patients as compared with those from healthy individuals (Figure 2a). In addition, the phosphorylation of YAP as the main downstream effector protein of Hippo signaling was significantly decreased in patient cells as compared with controls (Figure 2b). Consistent with these data, target genes of the Hippo effector proteins YAP and TAZ were significantly upregulated in the

patient cells (Figure 2c). Quantitative PCR analysis also revealed a significant upregulation of the Hippo pathway core kinases on the mRNA level, whereas expression of the Hippo effector protein YAP was not altered (Supplementary Figure S1A). Interestingly, the level of CDC42 mRNA did not significantly differ between patient and control cells, whereas immunoblot analysis revealed a significant reduction of CDC42 protein levels in patient cells compared with healthy individuals (Supplementary Figures S1B and S1C).

Literature Review

To date, 15 patients with *FAT1* mutations have been described, among these 11 with a truncating mutation and 4 with homozygous or compound heterozygous missense mutations.^{3–7} The mutations identified in these patients are inserted in the gene scheme in Figure 1b. Table 3 gives an overview on the clinical characteristics of the patients published recently and of the patients of this study.

DISCUSSION

We here expand the clinical spectrum of *FAT1*-associated disease by reporting 4 further patients from 3 families. A comprehensive review of the clinical phenotypes of these patients indicates a highly diverse phenotype in patients with missense mutations but a more uniform and therefore better recognizable phenotype in the patients with truncating mutations (Table 3):

Including the present study, the cohort of patients with homozygous truncating mutations comprises 14 individuals from 8 families.^{3,6} The majority of these patients presented with a specific ocular phenotype: uni- or bilateral ptosis in nearly all patients (12/14), uni- or bilateral coloboma in 9 patients (iris $n=3$ and retinal coloboma $n=6$) and microphthalmia in 4 of the 14 patients. In addition, 11 of the 14 patients presented with feet syndactyly. Intriguingly, the kidney phenotype, however, is quite variable, with absence of renal manifestations in 6 of 14 patients, asymptomatic proteinuria in 4 of 14 patients, nephrotic syndrome/proteinuria plus chronic kidney disease in 3 of 14 and bilateral renal hypodysplasia and end-stage kidney disease in 1 of 14 patients. In summary, the co-occurrence of ptosis (with or without coloboma) and webbed toes seems to be highly suggestive of a *FAT1*-truncating mutation, irrespective of the presence and the kind of associated kidney disease.

The cohort of patients with *FAT1* missense mutations comprises only 5 patients: 3 patients described by Gee *et al.*,⁵ 1 described by Shojaei *et al.*,⁴ and patient 4 from this study. These patients do not display the above-mentioned hallmark combination of an ocular phenotype combined with feet syndactyly. However,

all patients presented with steroid-resistant nephrotic syndrome. Kidney biopsy performed in 3 of the patients yielded minimal-change nephrotic syndrome ($n=1$) and diffuse mesangial sclerosis ($n=2$). The type of extrarenal involvement in patients with missense mutations seems to be highly variable: Gee *et al.* (2016) reported 2 patients presenting with tumors (Ewing sarcoma at the age of 13 years and Hodgkin lymphoma at the age of 10 years) and 1 girl with hydrocephalus.⁵ There was no comment on extrarenal disease in the Iranian case. The patient reported in this study (patient 4) suffers from a severe multisystemic disorder with psychomotor delay, deafness, a severe eye phenotype, and endocrinologic disease features (Table 2), which prompted us to perform a trio exome analysis to look for further variants to explain this severe phenotype.

After a careful analysis of the data, we are confident that the mutation in the gene *FAT1* is the most likely explanation for the disease in patient 4 because of the following reasons: The type of kidney disease with evidence of diffuse mesangial sclerosis is in line with the previously published patients. The mutation affects one of the cadherin domains, which has been described for other disease-causing missense mutations as well. Comprehensive trio exome analysis did not identify any alternative monogenic disorder or additional pathogenic sequence variants that could contribute to the complex phenotype. Still, we note that one of the identified variants in this patient (c.2563G>A) has an allele frequency of 0.21%, which is higher than expected in the healthy reference population, with 2 homozygous individuals listed in the gnomAD database. A possible explanation for the hypothesized disease-causing effect of this variant in our patient may be a negative epistatic effect in conjunction with the second variant *in trans* (c.5539G>A). Such epistatic effects of common variants have been shown in other monogenic nephropathies including *NPHS2*-associated steroid-resistant nephrotic syndrome.²⁶

A thorough phenotype review of the patients identified so far suggests a genotype-phenotype correlation, with missense mutations being commonly associated with nephrotic syndrome with variable extrarenal disease. In contrast, truncating variants result in the hallmark combination of ptosis and feet syndactyly with variable kidney disease.

Interestingly, the kidney phenotype previously described was a primarily glomerular phenotype with proteinuria ranging from early-onset proteinuria with ESKD in early childhood (e.g., patient 4) to proteinuria with a slowly progressive chronic kidney disease (e.g., patient 3 or F3IV1 with focal segmental glomerulosclerosis at the age of 20 years³) to asymptomatic proteinuria. Tubular ectasia was found in biopsies

(without clinical evidence of a tubular disease) resulting in the classification as a glomerulotubular nephropathy.⁵ Remarkably, 2 patients of our study also presented with CAKUT features: patient 1 with bilateral kidney hypodysplasia and patient 3 with bilateral vesicoureteral reflux, which was also reported in 1 patient by Gee *et al.*⁵

Further genotype-phenotype studies will be definitely needed to understand the broad and heterogenic spectrum of *FAT1*-associated disease, related to the type of kidney disease but also to the variety of extrarenal manifestations.

This study adds dysregulation of Hippo signaling to the possible pathomechanisms underlying *FAT1*-associated disease. The giant protocadherin *FAT1* was described as a component of the glomerular slit diaphragm in rats as early as 2001²⁷ (at the time referred to as *FAT*) and, shortly after, *FAT1* was localized to the intercellular junctions of podocytes.²⁸ A conventional knockout mouse of *Fat1* showed perinatal lethality with defect forebrain development, failure of eye development, and foot process effacement.²⁹ Podocyte-specific deletion of *Fat1* resulted in proteinuria and focal segmental glomerulosclerosis at the age of 4 months with abnormal foot process and slit-diaphragm development already shortly after birth.⁵ The same study suggested decreased cell adhesion and migration in podocytes due to reduced Rho-like small GTPase activity as one potential mechanism involved in the pathogenesis of the *FAT1* nephropathy.⁵ We here confirmed these data and show a reduced level of CDC42 in urinary cells derived from our patients (Supplementary Figure S1C). Interestingly, the Rho-GTPase *Cdc42* has been linked to Hippo signaling since kidney-specific knock-out of *Cdc42* results in developmental defects that phenocopy loss of *Yap*.^{17,30} The authors therefore already speculated about a possible role of Hippo signaling in *FAT1*-associated disease.⁵ Shortly after that study, Martin *et al.* reported that *FAT1* assembles a Hippo signaling complex, which results in the activation (phosphorylation) of the Hippo core kinases (MST, MOB, LATS) with subsequent repression of YAP/TAZ transcriptional activity.⁹

We therefore decided to analyze Hippo signaling in our patients harboring *FAT1* mutations and used patient-derived renal epithelial cells from the 2 patients with naïve kidneys, one of them (patient 2) without any sign of kidney disease and one (patient 3) with nephrotic range proteinuria and chronic kidney disease stage 3. Intriguingly, Hippo signaling was dysregulated on several levels: First, loss of *FAT1* resulted in decreased phosphorylation (inactivation) of MST as one of the Hippo core kinases. Second, the main effector protein YAP was activated as shown by reduced phosphorylation in patient cells. Third, as a result of the inactivated Hippo signaling cascade and

Table 3. Synopsis of phenotypes associated with truncating and phenotypes associated with missense mutations in *FAT1*

Truncating Mutations					
Study	<i>n</i>	Ocular features	Feet syn-dactyly	Kidney disease	Intellectual disability
Lahrouchi et al. (2019)	10	9/10	8/10	5/10	3/10
pat. #1 (F1,IV:1)		ptosis, coloboma,	-	proteinuria	no
pat. #2 (F1,IV:3)		ptosis	bilateral	-	no
pat. #3 (F1,IV:5)		ptosis, coloboma, microphthalmia	bilateral	proteinuria	no
pat. #4 (F2,III:2)		ptosis, coloboma	unilateral	none	no
pat. #5 (F2,IV:1)		ptosis, coloboma, microphthalmia	unilateral	none	no
pat. #6 (F2,IV:3)		ptosis, coloboma, microphthalmia	bilateral	none	no
pat. #7 (F3,IV:1)		-	unilateral	FSGS, proteinuria, CKD	no
pat. #8 (F3,IV:3)		ptosis, coloboma, microphthalmia	unilateral	proteinuria	yes
pat. #9 (F4,II:2)		ptosis	bilateral	none	yes
pat. #10 (F4,II:2)/A4623, Gee et al (2016)		ptosis	-	proteinuria; SRNS	yes
Rossanti (2020)	1	0/1	0/1	1/1	0/1
one patient		-	-	proteinuria	no
Our study	3	3/3	3/3	2/3	0/3
patient #1		ptosis	bilateral	proteinuria, hypodysplasia, ESKD	no
patient #2		ptosis	unilateral	none	no
patient #3		ptosis	bilateral	proteinuria, VUR, CKD	no
all	14	12/14 (ptosis 12/14; coloboma 6/14)	11/14	8/14 (proteinuria 8/14, CAKUT/VUR 2/14)	3/14
Missense Mutations					
Gee (2016)	3	0/3	0/3	3/3	0/3
A3027		-	-	nephrotic syndrome, VUR, ESKD	no
A789		-	-	nephrotic syndrome, MCNS	no
A3507		-	-	nephrotic syndrome, DMS	no
Serajpour (2019)	1	0/1	0/1	1/1	0/1
one patient		-	-	nephrotic syndrome, SRNS	-
Our study	1	1/1	0/1	1/1	1/1
patient#4		ptosis	-	nephrotic syndrome, DMS, ESKD	Yes
all	5	1/5 (ptosis 1/5)	0/5	5/5 (nephrotic syndrome 5/5, VUR 1/5)	1/5

CAKUT, congenital anomalies of the kidney and urinary tract; CKD, chronic kidney disease; DMS, diffuse mesangial sclerosis; ESKD, end-stage kidney disease; FSGS, focal segmental glomerulosclerosis; MCNS, minimal change nephrotic syndrome; SRNS, steroid resistant nephrotic syndrome; VUR, vesicourethral reflux.

de-repressed YAP signaling, numerous YAP target genes were significantly upregulated in the cells derived from patients with *FAT1*-associated disease compared with those from healthy controls. The potential pathomechanism based on our findings is illustrated in [Figure 2d](#).

Our observations are completely in line with the above-mentioned data derived from cancer cells and confirm the central role of Hippo signaling in kidney development and disease. Besides the role of the Hippo pathway in cystic kidney disease, recent studies also demonstrated the importance of the pathway in podocytes.^{8,16,31–35} Interestingly, both Hippo inactivation and subsequent YAP activation as well as YAP inactivation or depletion resulted in glomerular disease and a very well-regulated balance seems to be indispensable for normal podocyte function. It is therefore tempting to speculate that dysregulation of Hippo signaling with variable compensatory mechanisms in several kidney cell types could explain the broad phenotypic spectrum of kidney disease in *FAT1*-associated disease. Of note, the dysregulation of Hippo signaling could be

used as a diagnostic measure in *FAT1*-associated disease by applying the Hippo qPCR panel used in this study to urinary cells from patients suspected to harbor mutations in *FAT1*. Intriguingly, the Hippo pathway dysregulation was observed in both patients, in the one without any kidney disease phenotype (patient 2) and in the one with nephrotic range proteinuria and chronic kidney disease (patient 3).

Although the Hippo signaling pathway might represent a potential target of future therapeutic strategies, our findings have 1 additional implication. Notably, none of the patients with truncating mutations and complete loss of *FAT1* presented with any type of cancer. Whether the described tumors in 2 patients with missense mutations (Ewing sarcoma and Hodgkin lymphoma) are associated with the loss of the established tumor suppressor *FAT1* and the consecutive dysregulation of Hippo signaling remains unclear. The role of the compensatory upregulation of other Hippo components such as LATS, MST, MOB, and Salvador (on mRNA level) as tumor suppressors and

possible protective factors remains as speculative as the question whether any type of tumor might have a more aggressive course or a higher incidence in FAT1 patients. Thorough clinical follow-up of patients with mutations in *FAT1* is therefore indispensable and might allow assessing the risk of tumors in the future.

In summary, this study extends the spectrum of mutations in *FAT1* and provides a detailed genotype-phenotype correlation. In addition, our data provide evidence that genetic alterations of a Hippo regulator are in a prime position to cause defects in multiple renal cell types, which could explain the broad spectrum of renal phenotypes observed in patients carrying a *FAT1* mutation.

DISCLOSURE

All the authors declared no competing interests.

ACKNOWLEDGMENTS

We thank the study's participants for their willingness to contribute to this project. We additionally thank M. Brütting and S. Keller for excellent technical support.

This work was supported by the Deutsche Forschungsgemeinschaft (DFG [German Research Foundation]), Clinical research unit (CRU 329). JA (AL901/2-1 and AL901/3-1), BBB (BE6072/2-1 and BE6072/3-1), BS (SCHE 1562/7-1 and 1562/8-1), and SH (HA8479/1-1) received funding from the DFG.

AUTHOR CONTRIBUTIONS

FF: data analysis and generation, manuscript writing; NT: data analysis and generation, manuscript writing; FE: sample collection, data generation, and manuscript writing; AH: clinical care, ophthalmologic investigation and manuscript writing; AKB: clinical care and sample collection; CD: sample collection; BR: data generation; VKK: sample collection; SK: clinical care; MPB: sample collection, data interpretation, and manuscript writing; LTW: clinical care; HT: data generation; JA: data generation and interpretation and manuscript writing; BS: study conception, data generation and interpretation, and manuscript writing; BBB: study conception, sample collection, data generation and interpretation, and manuscript editing; SH: study conception, sample collection, data generation and interpretation, manuscript writing, and final approval. SH confirms to have full access to all data.

All authors read and approved the final manuscript.

SUPPLEMENTARY MATERIAL

[Supplementary File \(PDF\)](#)

Table S1. Screening panel of 122 genes that are associated with monogenic forms of proteinuria, as well as other nephropathies with possible concomitant proteinuria.

Table S2. List of probe-based assays.

Figure S1. qPCR analysis of RNA extracted from pURECs derived from patients 2 and 3.

REFERENCES

1. Kestilä M, Lenkkeri U, Männikkö M, et al. Positionally cloned gene for a novel glomerular protein—nephrin—is mutated in congenital nephrotic syndrome. *Mol Cell*. 1998;1:575–582.
2. Hildebrandt F, Benzing T, Katsanis N. Ciliopathies. *N Engl J Med*. 2011;364:1533–1543.
3. Lahrouchi N, George A, Ratbi I, et al. Homozygous frameshift mutations in *FAT1* cause a syndrome characterized by colobomatous-microphthalmia, ptosis, nephropathy and syndactyly. *Nat Commun*. 2019;10:1180.
4. Shojaei A, Serajpour N, Karimi B, et al. Molecular genetic analysis of steroid resistant nephrotic syndrome, detection of a novel mutation. *Iran J Kidney Dis*. 2019;13:165–172.
5. Gee HY, Sadowski CE, Aggarwal PK, et al. *FAT1* mutations cause a glomerulotubular nephropathy. *Nat Commun*. 2016;7:10822.
6. Rossanti R, Watanabe T, Nagano C, et al. *FAT1* biallelic truncating mutation causes a non-syndromic proteinuria in a child. *CEN Case Rep*. 2021;10:100–105.
7. Nagano C, Yamamura T, Horinouchi T, et al. Comprehensive genetic diagnosis of Japanese patients with severe proteinuria. *Sci Rep*. 2020;10:270.
8. Skouloudaki K, Puetz M, Simons M, et al. Scribble participates in Hippo signaling and is required for normal zebrafish pronephros development. *Proc Natl Acad Sci U S A*. 2009;106:8579–8584.
9. Martin D, Degese MS, Vitale-Cross L, et al. Assembly and activation of the Hippo signalome by *FAT1* tumor suppressor. *Nat Commun*. 2018;9:2372.
10. Ahmed AF, de Bock CE, Lincz LF, et al. *FAT1* cadherin acts upstream of Hippo signalling through TAZ to regulate neuronal differentiation. *Cell Mol Life Sci CMLS*. 2015;72:4653–4669.
11. Katoh M. Function and cancer genomics of FAT family genes. *Int J Oncol*. 2012;41:1913–1918.
12. Willecke M, Hamaratoglu F, Kango-Singh M, et al. The fat cadherin acts through the hippo tumor-suppressor pathway to regulate tissue size. *Curr Biol*. 2006;16:2090–2100.
13. Habbig S, Bartram MP, Müller RU, et al. NPHP4, a cilia-associated protein, negatively regulates the Hippo pathway. *J Cell Biol*. 2011;193:633–642.
14. Frank V, Habbig S, Bartram MP, et al. Mutations in *NEK8* link multiple organ dysplasia with altered Hippo signalling and increased c-MYC expression. *Hum Mol Genet*. 2013;22:2177–2185.
15. Habbig S, Bartram MP, Sägmüller JG, et al. The ciliopathy disease protein NPHP9 promotes nuclear delivery and activation of the oncogenic transcriptional regulator TAZ. *Hum Mol Genet*. 2012;21:5528–5538.
16. Rinschen MM, Grahammer F, Hoppe AK, et al. YAP-mediated mechanotransduction determines the podocyte's response to damage. *Sci Signal*. 2017;10, eaa8165.
17. Reginensi A, Scott RP, Gregorieff A, et al. Yap- and Cdc42-dependent nephrogenesis and morphogenesis during mouse kidney development. *PLoS Genet*. 2013;9, e1003380.

18. Happé H, van der Wal AM, Leonhard WN, et al. Altered Hippo signalling in polycystic kidney disease. *J Pathol.* 2011;224:133–142.
19. Müller RU, Schermer B. Hippo signaling—a central player in cystic kidney disease? *Pediatr Nephrol Berl Ger.* 2020;35:1143–1152.
20. Ma S, Guan KL. Polycystic kidney disease: a Hippo connection. *Genes Dev.* 2018;32:737–739.
21. Wong JS, Meliambro K, Ray J, Campbell KN. Hippo signaling in the kidney: the good and the bad. *Am J Physiol Renal Physiol.* 2016;311:F241–F248.
22. Xu D, Lv J, He L, et al. Scribble influences cyst formation in autosomal-dominant polycystic kidney disease by regulating Hippo signaling pathway. *FASEB J.* 2018;32:4394–4407.
23. Richards S, Aziz N, Bale S, et al. Standards and guidelines for the interpretation of sequence variants: a joint consensus recommendation of the American College of Medical Genetics and Genomics and the Association for Molecular Pathology. *Genet Med.* 2015;17:405–424.
24. Bartram MP, Habbig S, Pahmeyer C, et al. Three-layered proteomic characterization of a novel ACTN4 mutation unravels its pathogenic potential in FSGS. *Hum Mol Genet.* 2016;25:1152–1164.
25. Wang Y, Garraoui A, Zeng L, et al. FBN3 gene involved in pathogenesis of a Chinese family with Bardet-Biedl syndrome. *Oncotarget.* 2017;8:86718–86725.
26. Tory K, Menyhárd DK, Woerner S, et al. Mutation-dependent recessive inheritance of NPHS2-associated steroid-resistant nephrotic syndrome. *Nat Genet.* 2014;46:299–304.
27. Inoue T, Yaoita E, Kurihara H, et al. FAT is a component of glomerular slit diaphragms. *Kidney Int.* 2001;59:1003–1012.
28. Yaoita E, Kurihara H, Yoshida Y, et al. Role of Fat1 in cell-cell contact formation of podocytes in puromycin aminonucleoside nephrosis and neonatal kidney. *Kidney Int.* 2005;68:542–551.
29. Ciani L, Patel A, Allen ND, French-Constant C. Mice lacking the giant protocadherin mFAT1 exhibit renal slit junction abnormalities and a partially penetrant cyclopia and anophthalmia phenotype. *Mol Cell Biol.* 2003;23:3575–3582.
30. Huang Z, Zhang L, Chen Y, et al. Cdc42 deficiency induces podocyte apoptosis by inhibiting the Nwasp/stress fibers/YAP pathway. *Cell Death Dis.* 2016;7:e2142.
31. Keyvani Chahi A, Martin CE, Jones N. Nephtrin suppresses Hippo signaling through the adaptor proteins Nck and WTIP. *J Biol Chem.* 2016;291:12799–12808.
32. Kann M, Ettou S, Jung YL, et al. Genome-wide analysis of Wilms' tumor 1-controlled gene expression in podocytes reveals key regulatory mechanisms. *J Am Soc Nephrol.* 2015;26:2097–2104.
33. Bonse J, Wennmann DO, Kremerskothen J, et al. Nuclear YAP localization as a key regulator of podocyte function. *Cell Death Dis.* 2018;9:850.
34. Wennmann DO, Vollenbröcker B, Eckart AK, et al. The Hippo pathway is controlled by Angiotensin II signaling and its reactivation induces apoptosis in podocytes. *Cell Death Dis.* 2014;5:e1519.
35. Chung JJ, Goldstein L, Chen YJJ, et al. Single-cell transcriptome profiling of the kidney glomerulus identifies key cell types and reactions to injury. *J Am Soc Nephrol JASN.* 2020;31:2341–2354.