

[ ORIGINAL ARTICLE ]

# Changes in the Body Composition and Nutritional Status after Long-term Rifaximin Therapy for Hyperammonemia in Japanese Patients with Hepatic Encephalopathy

Toru Ishikawa, Saori Endo, Michitaka Imai, Motoi Azumi, Yujiro Nozawa, Tomoe Sano, Akito Iwanaga, Terasu Honma and Toshiaki Yoshida

## Abstract:

**Objective** Rifaximin has become available for treating hyperammonemia in patients with hepatic encephalopathy. This study analyzed the changes in the body composition and nutritional status after long-term rifaximin therapy.

**Methods** Twenty-one patients who underwent rifaximin therapy at 1,200 mg/day for more than 24 weeks were evaluated for the changes in the controlling nutritional status (CONUT) scores for the nutritional assessment, albumin-bilirubin (ALBI) scores for the liver function assessment, and skeletal muscle index (SMI) for the body composition assessment.

**Results** There were 17 men and 4 women, with a mean age of  $67.14 \pm 8.32$  years. Eleven cases had a porto-systemic shunt (52.3%), and 10 had hepatocellular carcinoma (47.6%). The Child-Pugh class was A in 9 cases (42.9%), B in 9 cases (42.9%), and C in 3 cases (14.2%). The blood ammonia levels in the rifaximin group improved significantly upon rifaximin therapy, from  $124.76 \pm 28.68$   $\mu\text{g/dL}$  at baseline to  $47.00 \pm 14.43$   $\mu\text{g/dL}$  after 2 weeks ( $p < 0.001$ ) and  $49.81 \pm 15.02$   $\mu\text{g/dL}$  after 24 weeks ( $p < 0.001$ ). The CONUT scores improved significantly during rifaximin therapy, from  $6.47 \pm 3.25$  at baseline to  $3.33 \pm 2.65$  after 24 weeks ( $p = 0.0007$ ). The ALBI scores also improved significantly from  $-0.39 \pm 1.89$  at baseline to  $-2.20 \pm 0.55$  after 24 weeks ( $p = 0.0002$ ). The SMI scores showed that the body composition had been maintained in response to rifaximin therapy ( $50.20 \pm 7.67$  at baseline and  $51.29 \pm 7.62$  after 24 weeks).

**Conclusion** Rifaximin administration for hepatic encephalopathy improved the CONUT and ALBI scores. It may have a secondary effect on the improvement in the nutritional status and hepatic reserve.

**Key words:** hepatic encephalopathy, rifaximin, body composition, CONUT score, ALBI score

(Intern Med 59: 2465-2469, 2020)

(DOI: 10.2169/internalmedicine.5094-20)

## Introduction

The risk of the first bout of overt hepatic encephalopathy is 5% to 25% within the first 5 years after a cirrhosis diagnosis, depending on the presence of risk factors (1). It manifests with atypical psychoneurotic symptoms and produces various alterations in consciousness, from mild symptoms to a coma (2). Hepatic encephalopathy is known to be one of the factors leading to a poor patient prognosis (3). Improving hepatic encephalopathy is of crucial importance to man-

aging cirrhosis.

Rifaximin is a poorly absorbable oral antibiotic that has a broad spectrum of activity with infrequent bacterial resistance (4). Rifaximin has been used for the treatment of hepatic encephalopathy in many countries (5). In Japan, rifaximin (Rifxima<sup>®</sup>; ASKA Pharmaceutical, Tokyo, Japan) has been available since November 2016, based on the data on its safety and efficacy for improving hyperammonemia in Japanese patients with hepatic encephalopathy (6). However, the safety and efficacy of long-term rifaximin administration in Japanese patients remains to be elucidated. Malnutrition

**Table 1. Characteristics of 21 Patients with Hepatic Encephalopathy.**

Variable	Data
Age (years)	67.14±8.32
Gender (male:female)	17:4
Body mass index	23.92±3.67
Etiology (HBV/HCV/Alc/NASH/PBC)	5/7/5/3/1
AST (IU/L)	37.95±21.78
ALT (IU/L)	27.14±15.79
Albumin (g/dL)	3.52±0.58
Total bilirubin (mg/dL)	1.13±0.55
Ammonia (mg/dL)	124.76±28.67
Child-Pugh score	7.19±1.53
ALBI score	-0.39±1.89
CONUT score	6.47±3.25
Fib-4 index	3.99±1.17
M2BPGi	3.66±3.08
History of hepatocellular carcinoma	10:11
Portosystemic shunts	11:10

HCV: hepatitis C virus, HBV: hepatitis B virus, Alc: alcohol abuse, NASH: nonalcoholic steatohepatitis, PBC: primary biliary cholangitis, AST: aspartate aminotransaminase, ALT: alanine aminotransaminase, ALBI: Albumin-Bilirubin, CONUT: controlling nutritional status, Fib-4: fibrosis 4, M2BPGi: Mac-2 binding protein glycan isomer

in patients with hepatic encephalopathy associated with cirrhosis is also a factor reportedly contributing to a poor prognosis (7).

In the present study, we therefore investigated the safety and efficacy of 24-week long-term rifaximin therapy for hyperammonemia in Japanese patients with hepatic encephalopathy associated with cirrhosis and explored whether or not the therapy was secondarily involved in changes to the nutritional status and body composition.

## Materials and Methods

### Patients

Of 87 Japanese patients who received rifaximin at our hospital between November 2016 and December 2019, there were 21 long-term administration cases that met all of the selection criteria and none of the exclusion criteria.

These cases were studied retrospectively. The selection criteria were as follows: 1) having cirrhosis or a portosystemic shunt and 2) having a hepatic encephalopathy at the start of rifaximin treatment. The exclusion criteria were as follows: 1) acute hepatic failure, 2) a dosage period of less than 24 weeks, 3) hyperammonemia with serum ammonia  $\leq$  80  $\mu$ g/dL at the start of rifaximin, 4) no serum ammonia assessment conducted prior to rifaximin therapy, 5) a dosage of <1,200 mg/day at the start of rifaximin administration, 6) no computed tomography performed during follow-up observation, 7) additional treatment for hepatic encephalopathy and sarcopenia and the liver reserve during follow-up obser-

vation, and 8) the recurrence of hepatocellular carcinoma during follow-up.

Rifaximin (1,200 mg/day) was administered orally after each meal, with administration being continued until the progression of the underlying disease made oral ingestion impossible.

Analyses included changes in blood ammonia levels at the start of rifaximin therapy, 2 weeks later, and 24 weeks later as well as changes in the albumin-bilirubin (ALBI) score (8), controlling nutritional status (CONUT) score (9), fibrosis 4 (Fib-4) index (10), and CT findings at the start and 24 weeks later.

The skeletal muscle index (SMI) at the L3 vertebral level for body composition were measured by cross-sectional enhanced-CT (Aquilion ONE; Toshiba Medical Systems, Tokyo, Japan). The SMI was determined using the SYNAPSE VINCENT V3.3 software program (Fuji Film Medical, Tokyo, Japan) that enables specific tissue demarcation using previously reported Hounsfield unit (HU) thresholds. The skeletal muscle mass was normalized to the height ( $m^2$ ) and expressed as the SMI ( $cm^2/m^2$ ). Using these values for the SMI, muscle depletion was defined as  $<42 cm^2/m^2$  in men and  $<38 cm^2/m^2$  in women, in accordance with the Japan Society of Hepatology (JSH) criteria (11).

The present study was approved by our hospital's ethics committee. Each patient was offered the opportunity to decline to participate in the study via an opt-out option.

### Statistical analyses

Fisher's exact test or the Kruskal-Wallis exact test was used to compare categorical variables, and the Mann-Whitney U test was used to compare the median values of continuous variables. Wilcoxon's signed-rank test was used to compare paired continuous variables. Statistical comparisons were performed using the EZR software program (12), and p values of  $<0.05$  by a two-tailed test were considered statistically significant.

## Results

The patient characteristics are outlined in Table 1. There were 17 men and 4 women, with a mean age of 67.14±8.32 years. The causes of liver cirrhosis were hepatitis C virus antibody-positive (HCV) in seven cases, hepatitis B virus antigen positive (HBV) in five cases, alcohol abuse in five cases, nonalcoholic steatohepatitis (NASH) in three cases, and primary biliary cholangitis (PBC) in one case. Eleven cases had a portosystemic shunt (52.3%), and 10 had hepatocellular carcinoma (47.6%).

The Child-Pugh score was 7.19±1.53, and the Child-Pugh class was A in 9 cases (42.9%), B in 9 cases (42.9%), and C in 3 cases (14.2%), with an ALBI score of -0.39±1.89 and an ALBI grade of 1 in 2 cases (9.5%), 2 in 6 cases (28.6%), and 3 in 13 cases (61.9%). The concomitant medications during rifaximin administration were branched-chain amino acid preparations in 19 cases (90.1%), carnitine

**Table 2. Concomitant Oral Medications during Rifaximin Treatment.**

Variables	n=21
Oral branched-chain amino acid	19 (90.1%)
Synthetic disaccharides	19 (90.1%)
Carnitine	15 (71.4%)
Zinc supplementation	2 (9.5%)
Proton pump inhibitor	5 (23.8%)
Diuretics	4 (19.0%)

**Table 3. Changes in Body Composition, Clinical Data and Nutritional Status after Administration of Rifaximin.**

Categories	Baseline	Post 24Week	p value
SMI	50.20±7.67	51.29±7.62	0.5228
AST (IU/L)	37.95±21.78	39.23±39.28	0.8122
ALT (IU/L)	27.14±15.79	27.67±18.87	0.8768
Albumin (g/dL)	3.52±0.58	3.53±0.52	0.8715
Total bilirubin (mg/dL)	1.13±0.55	1.31±0.31	0.4357
Child-Pugh score	7.19±1.53	6.71±1.70	0.0291
ALBI score	-0.39±1.89	-2.20±0.55	0.0002
CONUT score	6.47±3.25	3.33±2.65	0.0007
Fib-4 index	3.99±1.17	3.98±1.19	0.9037
M2BPGi	3.66±3.08	3.53±2.62	0.7755

SMI: skeletal muscle index, AST: aspartate aminotransaminase, ALT: alanine aminotransaminase, ALBI: Albumin-Bilirubin, CONUT: controlling nutritional status, Fib-4: fibrosis 4, M2BPGi: Mac-2 binding protein glycan isomer

preparations in 15 cases (71.4%), zinc preparations in 2 cases (9.5%), non-absorbable synthetic disaccharides in 19 cases (90.1%), and proton pump inhibitors in 5 cases (23.8%), with diuretics used in 4 cases (19.0%) (Table 2).

The ammonia levels improved significantly after rifaximin therapy, from 124.76±28.68 µg/dL at baseline to 47.00±14.43 µg/dL after 2 weeks and 49.81±15.02 µg/dL after 24 weeks (p<0.001) (Figure).

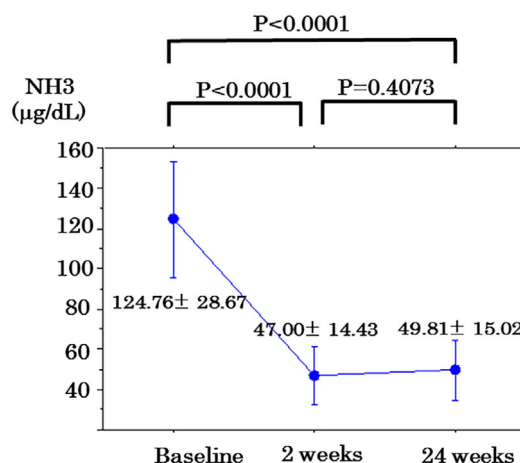
The mean CONUT score, used for the nutritional assessment, improved significantly from 6.47±3.25 at baseline to 3.33±2.65 after 24 weeks of therapy (p=0.0007). The mean ALBI scores also improved significantly from -0.39±1.89 at baseline to -2.20±0.55 after 24 weeks (p=0.0002) (Table 3).

The SMI that was used for the body composition analysis did not show a significant difference but was relatively well maintained (50.20±7.67 at baseline and 51.29±7.62 after 24 weeks).

In terms of adverse events from rifaximin, there was 1 case of grade 1 diarrhea (4.7%) and 1 case of grade 1 abdominal pain (4.7%), both of which improved with conservative treatment.

## Discussion

Cirrhosis is a condition where progressive, chronic liver damage causes long-term, repeated chronic inflammation as well as hepatocyte destruction in the liver, resulting in the



**Figure.** Changes in serum ammonia levels after rifaximin initiation. The ammonia levels improved significantly post-rifaximin therapy, from 124.76±28.68 µg/dL at baseline to 47.00±14.43 µg/dL and 49.81±15.02 µg/dL after 2 weeks and after 24 weeks, respectively (p<0.001). A statistically significant difference was observed between the blood concentrations of ammonia at baseline and after 2 weeks (p<0.001).

development of highly fibrotic tissue and a hardened, atrophic liver (13). Clinically, it is classified into compensated and decompensated stages. The compensated stage, where the liver function has largely been maintained, is often asymptomatic, whereas the decompensated stage that follows may involve jaundice, edema, ascites, hepatic encephalopathy, gastrointestinal bleeding associated with portal hypertension, and other symptoms. Patients with cirrhosis have experienced progressive liver damage over many years, often resulting in chronic malnutrition that is caused by anorexia, a decreased digestive absorption function, energy use restrictions based on liver damage, and increased basic energy consumption. An especially prevalent problem is defective protein metabolism associated with the decreased liver function, manifesting as protein-energy malnutrition (PEM) (14). The presence of PEM in a patient with cirrhosis is reflective of the severity not only of the malnutrition but also the liver disease (15). Patients with cirrhosis are at a high risk nutritionally, with their malnutrition having a decisive influence on their prognosis. When patients with decompensated cirrhosis develop hepatic encephalopathy, their food intake also suffers, causing their nutritional status to further deteriorate.

The mechanism underlying sarcopenia in patients with liver cirrhosis is thus multifactorial and can include hyperammonemia (16). Hyperammonemia in skeletal muscle induces transcriptional up-regulation of myostatin (17) and increases autophagy (18), both of which contribute to sarcopenia in patients with liver cirrhosis. Furthermore, it is reported that ammonia-lowering therapy improved the skeletal muscle phenotype, function, and molecular perturbations of hyperammonemia in *in vitro* and *in vivo* models (19).

A small but controlled clinical study outside of Japan found that rifaximin had an equivalent or better effect in im-

proving hepatic encephalopathy than non-absorbable synthetic disaccharides. A meta-analysis also showed that rifaximin has outcomes equivalent to those of non-absorbable synthetic disaccharides (20). A phase II/III trial performed on Japanese patients with hyperammonemia who had a portosystemic shunt or cirrhosis compared lactitol and rifaximin and reportedly showed an improvement in the day-15 portal systemic encephalopathy index (PSE) (rifaximin group: from  $0.33 \pm 0.11$  to  $0.20 \pm 0.14$ ;  $p < 0.0001$ , lactitol group: from  $0.33 \pm 0.10$  to  $0.23 \pm 0.17$ ;  $p < 0.0001$ ) and hepatic encephalopathy coma level (rifaximin group: from  $1.2 \pm 0.4$  to  $0.6 \pm 0.6$ ;  $p < 0.0001$ , lactitol group: from  $1.2 \pm 0.4$  to  $0.6 \pm 0.7$ ;  $p < 0.0001$ ) for both groups (6).

In a phase II/III trial on Japanese patients, the decrease in blood ammonia was maintained at least until week 12. In the present study as well, the blood ammonia levels improved significantly ( $p < 0.05$ ) after 2 weeks, and the downward trend was maintained even after 12 weeks (6).

The advent of rifaximin has thus expanded the methods of controlling hyperammonemia in patients with hepatic encephalopathy. Nevertheless, there has been an insufficient assessment of the nutrition, hepatic reserve, and changes in the body composition during the long-term administration of rifaximin. We therefore conducted the present study to assess the therapeutic effects of rifaximin in actual clinical practice.

The CONUT score is a novel, simple evaluation measure that is calculated using the serum albumin level, total cholesterol concentration, and total lymphocyte count measurement (9). In the present study, we used the CONUT score to objectively assess nutrition as a secondary effect of rifaximin against hepatic encephalopathy. The CONUT score, which uses multiple parameters related to nutrition, including the lymphocyte count, is regarded as being especially useful in this context. The use of serum albumin levels, total lymphocyte count, and total cholesterol to classify the nutritional status into four groups, from severe to normal, has garnered growing attention in recent years, as it makes the comprehensive assessment of nutrition possible.

Cirrhosis produces sarcopenia and a decrease in muscle mass over time. Hanai et al. reported the annual rates of the decrease in the mass of skeletal muscle corresponding to the liver disease severity classified by Child-Pugh A, B, and C as -1.3%, -3.5%, and -6.1% respectively, which warrants intervention (21). Sarcopenia as muscle depletion predicts hepatic encephalopathy in patients with liver cirrhosis (22).

In terms of nutrition, the improvement of the CONUT score in the present study is believed to be responsible for the SMI maintenance, according to the analysis of the body composition following long-term rifaximin administration for hepatic encephalopathy. We speculate that rifaximin for hepatic encephalopathy potentially improves the CONUT score and may lead to a positive effect by maintaining an SMI that naturally declines over time.

Another recent proposal is the ALBI grade, which is a method of assessing the hepatic reserve based on the ALBI

score, a continuous variable calculated using albumin and total bilirubin. The ALBI grade is regarded as being superior to the Child-Pugh classification at extracting cases with a good hepatic reserve. It is a particularly useful method for assessing the hepatic reserve in cases where the prothrombin time (PT) cannot be determined due to the use of anticoagulant therapy, cases with objective encephalopathy, and cases with ascites that are difficult to assess.

Our finding that rifaximin, which is a treatment for hyperammonemia in patients with hepatic encephalopathy, also improved the ALBI score may be largely due to the improvement in nutritional status. Long-term rifaximin administration for hepatic encephalopathy produced a short-term decrease in blood ammonia and maintained low ammonia levels, resulting in an improvement in the nutritional status as assessed by the CONUT score.

The curative effect of rifaximin on improving the dietary intake may be due in part to the improvement of hepatic encephalopathy and small intestinal bacterial overgrowth (SIBO). Patients with hepatic encephalopathy have a high prevalence of SIBO and are often encountered with cirrhosis as a result of an impaired intestinal motility and delayed transit time, including malabsorption (23). Rifaximin is the best studied antibiotic for SIBO treatment, as it is a poorly absorbed oral antibiotic, which allows for local enteric antibacterial activity with a minimal risk of systemic toxicity.

However, it may be necessary to consider other factors. An improvement in the hepatic reserve was also seen, which made it possible to maintain the SMI. In addition, any adverse events associated with rifaximin were mild and improved with conservative treatment.

Several limitations associated with the present study warrant mention. First, it was a single-center study; thus, there is a possibility of selection bias by area. Second, given the cross-sectional nature of the study, inferring causality was not possible. Third, it is necessary to examine the validity of 24 weeks as a long-term therapy.

In the present study, the long-term use of rifaximin to control hepatic encephalopathy improved the CONUT and ALBI scores after 24 weeks. It also made it possible to maintain the SMI, showing the potential for long-term rifaximin administration to improve the prognosis of patients with decompensated cirrhosis nutritionally, by improving their hepatic reserve and maintaining the body composition. More long-term studies with a greater number of cases will be needed to assess whether or not rifaximin can also improve the prognosis of sarcopenia.

**The authors state that they have no Conflict of Interest (COI).**

## References

1. Vilstrup H, Amodio P, Bajaj J, et al. Hepatic encephalopathy in chronic liver disease: 2014 Practice Guideline by the American Association for the Study of Liver Diseases and the European Association for the Study of the Liver. *Hepatology* **60**: 715-735,

- 2014.
2. Wijndicks EF. Hepatic encephalopathy. *N Engl J Med* **375**: 1660-1670, 2016.
  3. Iwasa M, Takei Y. Pathophysiology and management of hepatic encephalopathy 2014 update: ammonia toxicity and hyponatremia. *Hepatol Res* **45**: 1155-1162, 2015.
  4. Bass NM, Mullen KD, Sanyal A, et al. Rifaximin treatment in hepatic encephalopathy. *N Engl J Med* **362**: 1071-1081, 2010.
  5. Jiang Q, Jiang XH, Zheng MH, et al. Rifaximin versus nonabsorbable disaccharides in the management of hepatic encephalopathy: a meta-analysis. *Eur J Gastroenterol Hepatol* **20**: 1064-1070, 2008.
  6. Suzuki K, Endo R, Takikawa Y, et al. Efficacy and safety of rifaximin in Japanese patients with hepatic encephalopathy: A phase II/III, multicenter, randomized, evaluator-blinded, active-controlled trial and a phase III, multicenter, open trial. *Hepatol Res* **48**: 411-423, 2018.
  7. Lattanzi B, D'Ambrosio D, Merli M. Hepatic encephalopathy and sarcopenia: two faces of the same metabolic alteration. *J Clin Exp Hepatol* **9**: 125-130, 2019.
  8. Johnson PJ, Berhane S, Kagebayashi C, et al. Assessment of liver function in patients with hepatocellular carcinoma: a new evidence based approach—the ALBI grade. *J Clin Oncol* **33**: 550-558, 2015.
  9. Ignacio de, Ulbarri J, González-Madroño A, et al. First validation in a hospital population. *Nutr Hosp* **20**: 38-45, 2005.
  10. Vallet-Pichard A, Mallet V, Nalpas B, et al. FIB-4: an inexpensive and accurate marker of fibrosis in HCV infection, comparison with liver biopsy and fibrotest. *Hepatology* **46**: 32-36, 2007.
  11. Nishikawa H, Shiraki M, Hiramatsu A, Moriya K, Hino K, Nishiguchi S. Japan Society of Hepatology guidelines for sarcopenia in liver disease (1st edition): recommendation from the working group for creation of sarcopenia assessment criteria. *Hepatol Res* **46**: 951-63, 2016.
  12. Kanda Y. Investigation of the freely available easy-to-use software 'EZ' for medical statistics. *Bone Marrow Transplant* **48**: 452-458, 2013.
  13. Schuppan D, Afdhal NH. Liver cirrhosis. *Lancet* **371**: 838-851, 2008.
  14. Shergill R, Syed W, Rizvi SA, Singh I. Nutritional support in chronic liver disease and cirrhotics. *World J Hepatol* **10**: 685-694, 2018.
  15. Moriwaki H, Shiraki M, Fukushima H, et al. Long-term outcome of branched-chain amino acid treatment in patients with liver cirrhosis. *Hepatol Res* **38**: S102-S106, 2008.
  16. Dasarathy S. Consilience in sarcopenia of cirrhosis. *J Cachexia Sarcopenia Muscle* **3**: 225-237, 2012.
  17. Qiu J, Thapaliya S, Runkana A, et al. Hyperammonemia in cirrhosis induces transcriptional regulation of myostatin by an NF- $\kappa$ B-mediated mechanism. *Proc Natl Acad Sci U S A* **110**: 18162-18167, 2013.
  18. Qiu J, Tsien C, Thapalaya S, et al. Hyperammonemia-mediated autophagy in skeletal muscle contributes to sarcopenia of cirrhosis. *Am J Physiol Endocrinol Metab* **303**: 983-993, 2012.
  19. Kumar A, Davuluri G, Silva RNE, et al. Ammonia lowering reverses sarcopenia of cirrhosis by restoring skeletal muscle proteostasis. *Hepatology* **65**: 2045-2058, 2017.
  20. Kimer N, Krag A, Møller S, Bendtsen F, Gluud LL. Systematic review with meta-analysis: the effects of rifaximin in hepatic encephalopathy. *Aliment Pharmacol Ther* **40**: 123-132, 2014.
  21. Hanai T, Shiraki M, Ohnishi S, et al. Rapid skeletal muscle wasting predicts worse survival in patients with liver cirrhosis. *Hepatol Res* **46**: 743-751, 2016.
  22. Hanai T, Shiraki M, Watanabe S, et al. Sarcopenia predicts minimal hepatic encephalopathy in patients with liver cirrhosis. *Hepatol Res* **47**: 1359-1367, 2017.
  23. Ghosh G, Jesudian AB. Small intestinal bacterial overgrowth in patients with cirrhosis. *J Clin Exp Hepatol* **9**: 257-267, 2019.

The Internal Medicine is an Open Access journal distributed under the Creative Commons Attribution-NonCommercial-NoDerivatives 4.0 International License. To view the details of this license, please visit (<https://creativecommons.org/licenses/by-nc-nd/4.0/>).