

Chronic nodules of sigmoid perforation caused by incarcerated intrauterine contraception device

Xiaohui Huang, MD^a, Rui Zhong, MD^b, Liqin Zeng, PhD^a, Xuhui He, PhD^a, Qingshan Deng, BA^a, Xiuhong Peng, BA^a, Jieming Li, BA^a, Xiping Luo, MD^{a,*}

Abstract

Rationale: It is extremely rare for an intrauterine contraception device (IUD) to cause uterine perforation and Sigmoid perforation for a long time without being detected.

Patient concerns: We present a case of a patient who has suffered from abdominal pain after 4 years of placement of an IUD, and found that the IUD was incarcerated by ultrasound.

Diagnoses: Laparoscopic and hysteroscopic examination revealed that the incarcerated IUD caused uterine perforation and sigmoid perforation for a long time. One end of the intrauterine device completely penetrated the anterior wall muscle layer of the uterus and the full layer of the sigmoid colon, located in the intestinal lumen, and the perforated portion of the sigmoid colon formed a chronic nodule.

Interventions: We extended the sigmoid colon perforation and uterine perforation by laparoscopy, removed the incarcerated IUD from the uterus through the vagina, trimmed the chronic nodules of the sigmoid perforation, repaired the sigmoid colon, and repaired the uterine perforation.

Outcomes: The patient was cured and discharged 22 days after surgery. The patient was naturally pregnant 3 months after surgery and delivered by cesarean section 12 months after surgery. We saw a good recovery of the uterus and sigmoid colon during cesarean section.

Lessons: The patient was placed with an intrauterine device made of a special material and was not monitored after placement, causing the uterus and sigmoid perforation to be undetected for a long time. The IUD placed in the patient should be monitored regularly. If the IUD is found to be incarcerated or displaced, attention should be paid to uterine perforation and intestinal perforation.

Abbreviations: cm = centimeter, IUD = intrauterine contraceptive device, IUDs = intrauterine contraceptive devices, mm = millimeter.

Keywords: chronic nodule, complication, intrauterine contraceptive device, sigmoid perforation, uterine perforation

1. Introduction

Intrauterine contraceptive devices (IUDs) are widely used throughout the world for their safe, economical, efficient, and reversible family planning long-term tools. In addition to contraceptive failure, complications of intrauterine devices include displacement, shedding, uterine embedding, partial or complete uterine perforation, and perforation of the intestine, bladder, or adjacent vessels.^[1,2] Among them, perforation is a

rare but serious complication, and the reported incidence rate is 0.2 to 3.6 per 1000 insertions.^[2-4] We reported an extremely rare case in which the patient was placed with an intrauterine device made of a special material and was not monitored after placement, causing the uterus and sigmoid perforation to be undetected for a long time. The patient has provided written consent for the publication of this case report.

2. Case report

A 26-year-old woman, gravida 1 para 1, received the M₂CuIUD (Fig. 1) insertion 12 months after the first child was born when she was 22 years old. She did not have any symptoms and did not perform routine examinations after insertion into the device to determine its position within the uterine cavity. Her surgical history includes a vaginal delivery and an appendectomy. She is healthy and has no obvious past medical history. One day, after installing the IUD 4 years late, She had lower abdominal pain and back pain without obvious cause, but these symptoms just last for 1 day and spontaneously subsided, and she had no other discomfort.

A pelvic ultrasound showed that the size of the uterus was normal. Part of the IUD was seen in the uterine cavity. The other part of the IUD was located in the muscular layer of the anterior wall of the uterus, the end of it appeared to be outside the serosa layer, and the periphery seemed to be surrounded by a low echo. The IUD was incarcerated and penetrated the uterine serosa.

Editor: N/A.

The authors have no conflicts of interest to disclose.

^a Department of Gynecology, Guangdong Women and Children Hospital,

^b Department of Ultrasound, Guangdong Province Traditional Chinese Medical Hospital, Guangzhou, Guangdong, China.

* Correspondence: Xiping Luo, Department of Gynecology, Guangdong Women and Children Hospital, No. 13, Guangyuan West Road, Yuexiu District, Guangzhou 510010, Guangdong, China (e-mail: 16544176@qq.com).

Copyright © 2019 the Author(s). Published by Wolters Kluwer Health, Inc. This is an open access article distributed under the terms of the Creative Commons Attribution-Non Commercial License 4.0 (CCBY-NC), where it is permissible to download, share, remix, transform, and buildup the work provided it is properly cited. The work cannot be used commercially without permission from the journal.

Medicine (2019) 98:4(e14117)

Received: 28 August 2018 / Received in final form: 17 December 2018 /

Accepted: 21 December 2018

<http://dx.doi.org/10.1097/MD.00000000000014117>

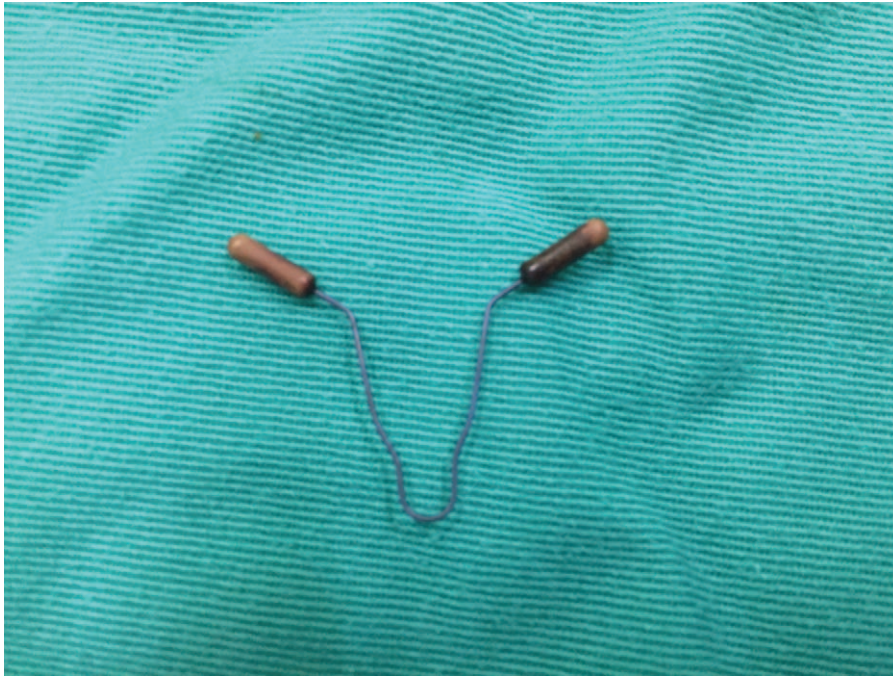


Figure 1. MCuIUD: This IUD is made of a shape memory alloy smart material with copper particles at both ends. IUD=intrauterine contraceptive device.

Abdominal x-ray confirmed the presence of the IUD in the pelvis (Fig. 2). Hysteroscopy showed that the forearm of the IUD was incarcerated in the left anterior wall of the uterus, and the hind arm was located in the uterine cavity (Fig. 3). Laparoscopy showed adhesion of the left anterior wall of the uterus to the intestinal tract (Fig. 4). The adhesive tape was separated from the myometrium with an ultrasonic scalpel and scissors. It could be seen that the forearm of the IUD penetrates the left anterior wall muscle layer of the uterus and the sigmoid colon (Fig. 5). The IUD was removed from the uterine cavity via the vagina. The IUD perforated through the entire bowel wall from the serosa to the mucosa and the hole was about 0.5×0.5 cm. The tissue around the rupture was nodular hyperplasia and was repaired with scissors (Fig. 6), then the sigmoid colon and the uterus perforation were stitched (Fig. 7).

The patient's operative and postoperative courses were successful, and she was discharged to home on a postoperative day 22 without complications. After 2 years of uneventful follow-up, the patient had an uncomplicated pregnancy. The patient was naturally pregnant 3 months after surgery and delivered by cesarean section 12 months after surgery. We saw a good recovery of the uterus and sigmoid colon during cesarean section (Fig. 8).

3. Discussion

IUD is made of different materials, such as stainless steel, plastic, and silicone rubber, and can be round, T-shaped, V-shaped, Y-shaped, or chain-shaped.^[5] Perforation appears to be related to the type of device, insertion time, breastfeeding, uterine position,

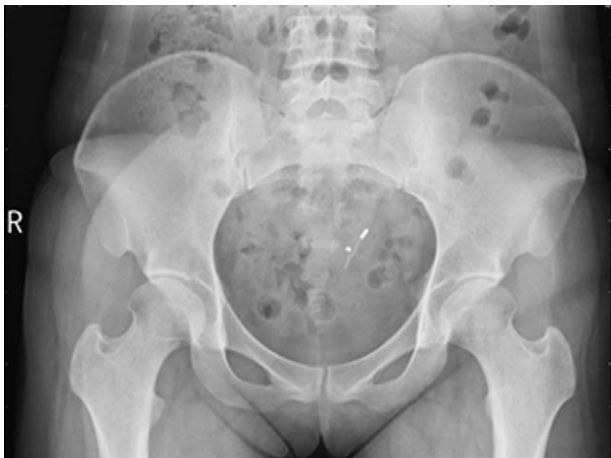

Figure 2. Abdominal x-ray confirmed the presence of the IUD in the pelvis. IUD=intrauterine contraceptive device.

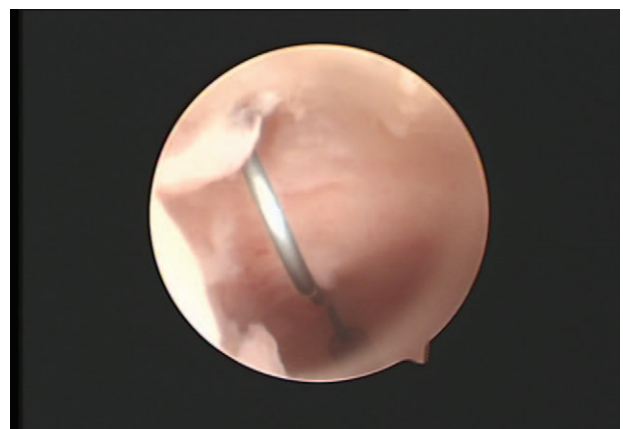


Figure 3. Hysteroscopy showed that the forearm of the IUD was incarcerated in the anterior wall of the uterus, and the hind arm located in the uterine cavity. IUD=intrauterine contraceptive device.

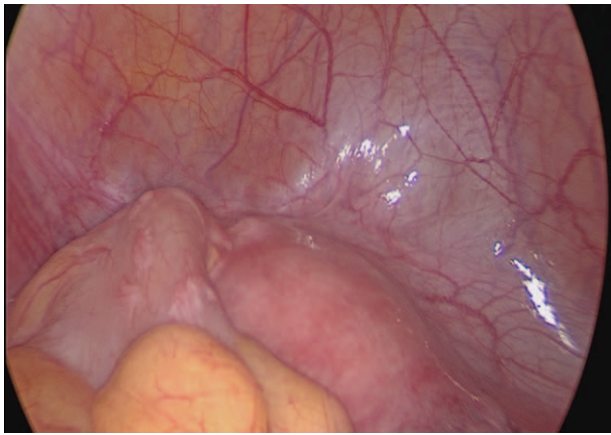


Figure 4. Laparoscopy showed the adhesion of the left anterior wall of the uterus to the intestinal tract.

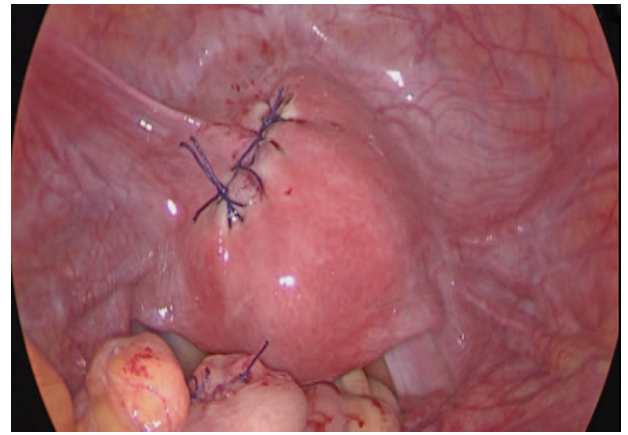


Figure 7. The sigmoid colon and the uterus perforation were stitched.

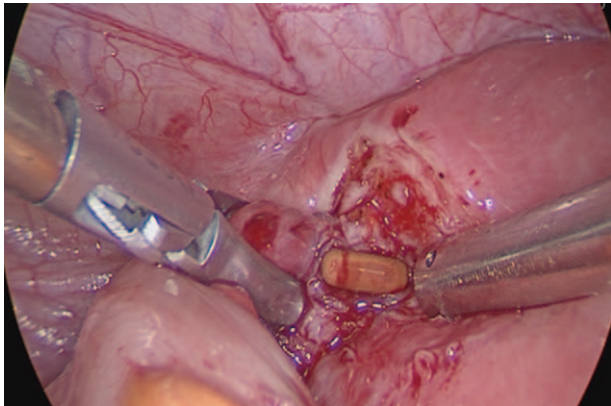


Figure 5. The forearm of the IUD penetrates the left anterior wall muscle layer of the uterus and the sigmoid colon. IUD=intrauterine contraceptive device.

operator skill, and follow-up compliance.^[6] Although perforation most often occurs when the IUD is placed,^[7,8] subsequent instrument displacement may occur spontaneously, resulting in

dislocation into the abdominal cavity, making detection extremely difficult.^[9,10] However, common symptoms are abdominal pain, fever, and diarrhea, but some patients do not have any symptoms. Therefore, most IUD manufacturers recommend that the recipient perform a routine check 3 months after insertion to determine that they are in the uterine cavity.

The perforation of the uterus by the IUD is a relatively rare complication whose incidence is estimated between 1.3 and 1.6 per 1000 insertions, but the consequences can be very serious.^[8] The exact mechanism and timing of the sigmoid penetration in our patient's case is unclear. The patient had a history of appendicitis surgery, which may cause the sigmoid colon to adhere to the anterior wall of the uterus. One possible mechanism for causing uterine perforation and sigmoid perforation is the perforation of the uterus and the perforation of the sigmoid colon close to the uterus when the IUD was placed. Due to the special material of the IUD placed and the perforation being relatively small, no intestinal contents flowed into the abdominal cavity, and no symptoms such as abdominal pain were caused. The

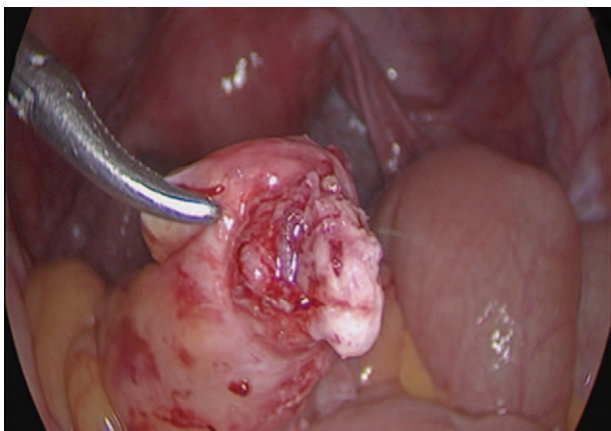


Figure 6. The IUD perforated through the entire bowel wall from the serosa to the mucosa and the hole was about 0.5×0.5 cm. The tissue around the rupture was nodular hyperplasia and was repaired with scissors. IUD=intrauterine contraceptive device.

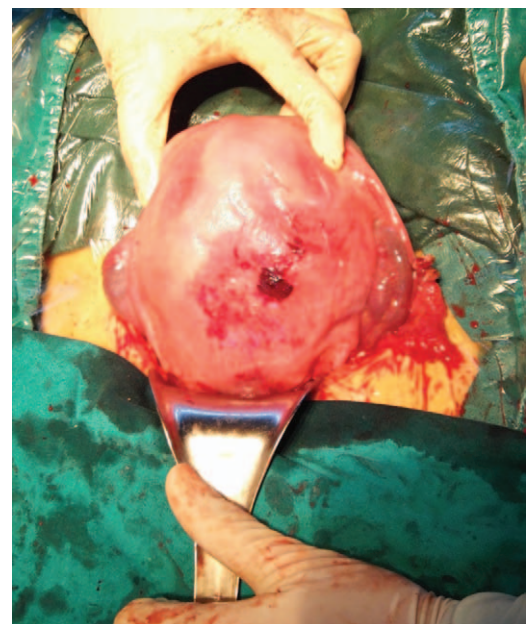


Figure 8. The uterus recovered well during cesarean section.

patient did not monitor regularly after placing the IUD. The intestinal perforation caused by the IUD was not discovered until 4 years later, and the sigmoid colon perforation formed a chronic nodule. Another possible mechanism of intestinal perforation is due to factors such as sexual intercourse, increased abdominal pressure, and uterine contraction after placement. The mechanism of uterine perforation in this patient is more inclined to the former.

The IUD placed in this patient is a new contraceptive product with memory function. It was approved by the State Food and Drug Administration in 2009 (Registration No.: National Food and Drug Administration (Quasi) Word No. 2009 No. 3461002) The IUD is a scaffold made of a shape memory alloy smart material, which is in the shape of a V-shaped uniform with the shape of the uterine cavity, and the ends of the 2 arms are copper particles, which are not easy to fall off. This intrauterine device maintains a designed shape within the body temperature range and is superelastic and less prone to deformation. The corrosion resistance of shape memory alloys is far superior to that of stainless steel and silica gel materials. In the physiological solution of a human body, the dissolution rate is $<1 \times 10$ mm/year. This may be the reason why the IUD penetrates the myometrium and the sigmoid colon in the whole layer without causing the outflow of intestinal contents without symptoms. Therefore, it is best to use ultrasound to check whether the IUD is placed correctly after placing the IUD. If it is found that the placement position is wrong, it needs to be treated in time.^[11] Follow-up was performed 1, 3, 6, and 12 months after placement, and once a year thereafter. If dislocation, shedding, and pregnancy are found, measures should be taken in a timely manner.

4. Conclusion

In summary, we present a case of this special material of the intrauterine device leading to asymptomatic uterine perforation and sigmoid perforation. If routine monitoring is not performed after placement, uterine perforation and sigmoid perforation may not be detected for a long time. At the same time, compared to IUDs of other shapes and materials, this IUD is more likely to be

incarcerated and cause perforation of the uterus and adjacent tissues. Therefore, special care should be taken when placing this IUD, which must be monitored regularly after placement.

Author contributions

Resources: Rui Zhong, Liqin Zeng, Xiukui He, Qingshan Deng, Xiuhong Peng, Jieming Li.

Writing – original draft: Xiaohui Huang.

Writing – review & editing: Xiping Luo.

References

- [1] Kaislasuo J, Suhonen S, Gissler M, et al. Intrauterine contraception: incidence and factors associated with uterine perforation—a population-based study. *Hum Reprod* 2012;27:2658–63.
- [2] Heinemann K, Reed S, Moehner S, et al. Risk of uterine perforation with levonorgestrel-releasing and copper intrauterine devices in the European Active Surveillance Study on Intrauterine Devices. *Contraception* 2015;91:274–9.
- [3] Cetinkaya K, Kumtepe Y, Ingeç M. Minimally invasive approach to cases of lost intra-uterine device: a 7-year experience. *Eur J Obstet Gynecol Reprod Biol* 2011;159:119–21.
- [4] Kho KA, Chamsy DJ. Perforated intraperitoneal intrauterine contraceptive devices: diagnosis, management, and clinical outcomes. *J Minim Invasive Gynecol* 2014;21:596–601.
- [5] Melo J, Tschannen M, Soon R, et al. Women's willingness and ability to feel the strings of their intrauterine device. *Int J Gynecol Obstet* 2017;137:309–13.
- [6] Xin S, Min X, Deng X, et al. Clinical characteristic and intraoperative findings of uterine perforation patients in using of intrauterine devices (IUDs). *Gynecol Surg* 2018;15:3.
- [7] Zeino MY, Wietfeldt ED, Advani V, et al. Laparoscopic removal of a copper intrauterine device from the sigmoid colon. *J Soc Laparoend Surg* 2011;15:568–70.
- [8] Toumi O, Ammar H, Ghdira A, et al. Pelvic abscess complicating sigmoid colon perforation by migrating intrauterine device: a case report and review of the literature. *Int J Surg Case Rep* 2018;42:60–3.
- [9] Ye H, Huang S, Zhou Q, et al. Migration of a foreign body to the rectum: a case report and literature review. *Medicine* 2018;97:e11512.
- [10] Rowlands S, Oloto E, Horwell D. Intrauterine devices and risk of uterine perforation: current perspectives. *Open Access J Contracept* 2016;7:19–32.
- [11] Huh JM, Kim KS, Cho YS, et al. Colonoscopic removal of an intrauterine device that had perforated the rectosigmoid colon. *Ann Coloproctol* 2018;34:106.