

Case Report**Ulcerative colitis and neurofibromatosis type 1 with bilateral psoas muscle neurofibromas: a case report***Hamid Tavakkoli^{*a}, Mehrnaz Asadi^b, Parvin Mahzouni^c, Abdolali Foroozmehr^d***Abstract**

The most common gastrointestinal involvement in neurofibromatosis is due to tumoral lesions which may present with gastrointestinal bleeding or obstruction. We report a case of concurrent ulcerative colitis and neurofibromatosis.

A 39 year-old woman, known case of neurofibromatosis, was admitted to our department with complaint of chronic bloody diarrhea. After thorough clinical examination and paraclinical assessments, including colonoscopy and biopsy, ulcerative colitis was confirmed as the cause of gastrointestinal bleeding. Another rare finding in this patient was bilateral neurofibroma in psoas muscle that was detected on abdominal spiral Computer Tomography scan.

KEYWORDS: Ulcerative Colitis, Neurofibromatosis, Von Recklinghausen's Disease, Mast Cells, Bilateral Neurofibroma, Psoas Muscle.

JRMS 2009; 14(4): 261-265

Gastrointestinal abnormalities in patients with neurofibromatosis type 1 (NF1) are reported to occur in up to 10%-25% of patients and consist of four groups of lesions: mesenchymal neoplasms, hyperplasia of intestinal neural tissue, neuroendocrine tumors of the duodenum, and rarely, neoplasms such as adenocarcinoma. Neurofibroma is the most commonly encountered mesenchymal neoplasm in these patients and occurs most frequently in the stomach and jejunum, but the colon may also be involved.^{1,2} Gastrointestinal neurofibroma may cause gastrointestinal bleeding,²⁻⁴ intussusceptions,³ gastric outlet obstruction,⁴ volvulus, intestinal perforation,⁵ or bowel obstruction.⁶ Also, neurofibromatosis with intermittent episodes of intestinal pseudo-obstruction has been reported.⁷

According to our knowledge, only one report has been published about neurofibromatosis and associated ulcerative hemorrhagic colitis.⁸ Here, we report a case of concurrent neurofibromatosis and ulcerative colitis.

Case Report

A 39 year-old woman, known case of neurofibromatosis from childhood, was admitted to the emergency department because of one-week history of intractable bloody diarrhea. She had suffered from chronic intermittent bloody diarrhea for eight years. Within these years, she received 5-aminosalicylate drugs irregularly with only slight improvements in her complaints. In our first visit, her major complaint was bloody diarrhea and colicky abdominal pain. Symptoms such as nausea, vomiting, anorexia, fever, or fecal incontinence

^a Associate Professor of Gastroenterology, Department of Gastroenterology, Alzahra Hospital, Isfahan University of Medical Sciences, Isfahan, Iran.

^b Internist, Department of Internal Medicine, Alzahra Hospital, Isfahan University of Medical Sciences, Isfahan, Iran.

^c Associate Professor of Pathology, Department of Pathology, Alzahra Hospital, Isfahan University of Medical Sciences, Isfahan, Iran.

^d Assistant Professor of Radiology, Department of Radiology, Alzahra Hospital, Isfahan University of Medical Sciences, Isfahan, Iran.

* Corresponding Author

E-mail: h_tavakkoli@med.mui.ac.ir

were not mentioned. She had more than eight episodes of diarrhea each day and also nocturnal episodes, interfering with her sleep, for a week prior to the visit. Her stool was mixed with bright red blood.

She remembered no important childhood or adulthood illness except a systolic hypertension diagnosed eight months ago and controlled by metoprolol 25 mg/day. She was not a smoker and did not mention alcohol consumption. She had a history of three admissions for resection of schwannoma of peripheral nerves in lower extremities. One of her daughters had skin lesions compatible with neurofibromatosis. There was no positive family history for Inflammatory Bowel Disease (IBD).

The patient was a middle-aged woman, ill appearing and cachectic. Her vital signs were stable. Physical findings on examination of heart and lung were normal. Abdomen was soft and on superficial palpation, a plenty of freely movable, soft, and non-tender subcutaneous and intradermal nodules of varying sizes were detected. She had left lower quadrant tenderness. On skin examination, there were widely distributed freckles and hyperpigmented macula and patches with sharp border of variable sizes (Figure 1). The hyperpigmented brown patches were mostly seen on abdominal and lumbosacral areas. Extraintestinal manifestations related to IBD were not detected.

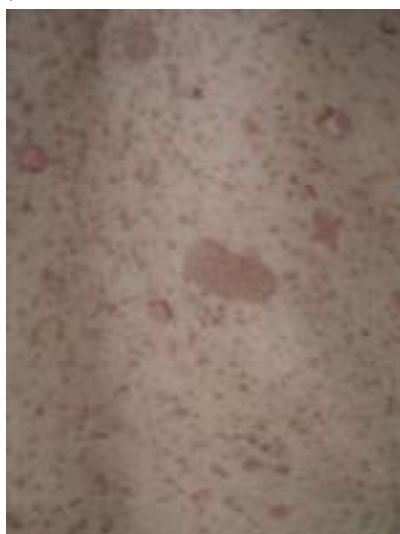

Figure 1. Skin lesions

After admission, the patient was ordered to take nothing by mouth and parenteral fluid administration was started for her. Laboratory data were as the followings: WBC 5600 with 20% lymphocytes, Hb 12.8 g/dl, MCV 79, Platelet count 456000, BUN 24 mg/dl, Cr 0.8 mg/dl, Na 138 meq/l, K 4 meq/l, Ca 9 mg/dl, P 3.9 mg/dl, Albumin 3.1 g/dl, AST 13 U/l, ALT 8 U/l, and ESR 24 mm/1st h. Stool exam showed many WBC and RBC without any evidence of parasites and stool culture was negative for infectious colitis (shigella, salmonella, yersinea, and campylobacter). A plain abdominal x-ray was taken and there was no abnormal finding. The patient's chest x-ray was also normal.

She received hydrocortisone 100 mg Q8h and ceftriaxone 1 gr BD intravenously, and subsequently lactase free and fiber free diet with sulfasalazine was started on the second day. She was closely monitored at emergency department. After negative stool culture result, ceftriaxone was discontinued. On the third day, symptoms were subsided and the patient was transmitted to the ward and received colon preparation. On the fifth day she underwent total colonoscopy and ileal intubation. In colonoscopy, avascularity, erythematous and edematous mucosa, and ulceration with pseudopolyps up to 30 cm from anal verge were seen (Figure 2). Terminal ileum was normal. Multiple biopsies were obtained from rectum and sigmoid mucosa. In microscopic examination the lamina propria was infiltrated with lymphocytes and plasma cells. The crypts showed goblet cell depletion, cryptitis, and crypt abscesses (Figure 3) and inflammatory pseudopolyp was seen in other sections (Figure 4).

One week after admission, she discharged from hospital while on prednisolone 50 mg and sulfasalazine 4 gr, daily. Corticosteroid was tapered and discontinued about 1.5 month later and during about 2 years follow up the patient was symptom free on sulfasalazine. Since the patient was cachectic, abdominopelvic Computer Tomography (CT) scan was done for her. Bilateral masses were identified

within psoas muscles, which were sharply margined and homogenous, with water attenuation. Also, a few subcutaneous neurofibromas were present on right flank (Figure 5). More Caudal CT scan showed bilateral presacral and nerve root foraminal Neurofibroma, mildly expanding the sacral foramina, as well as pelvic masses of neurofibromatosis displacing the rectum and uterus anteriorly. Incidentally, a large right ovarian cyst was also detected (Figure 6).

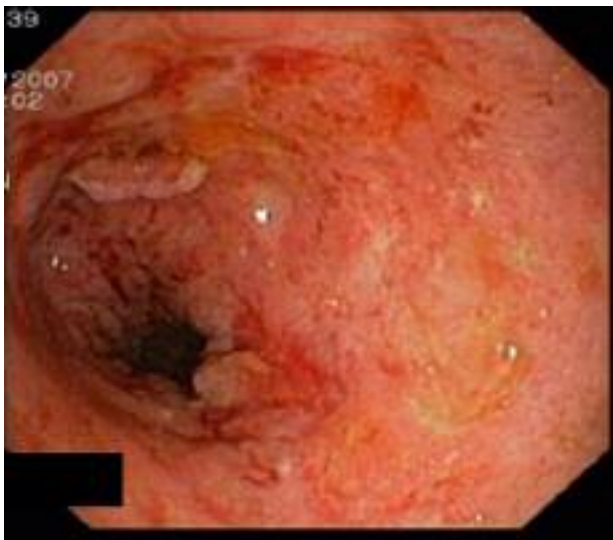

Figure 2. Colonoscopic view of rectum

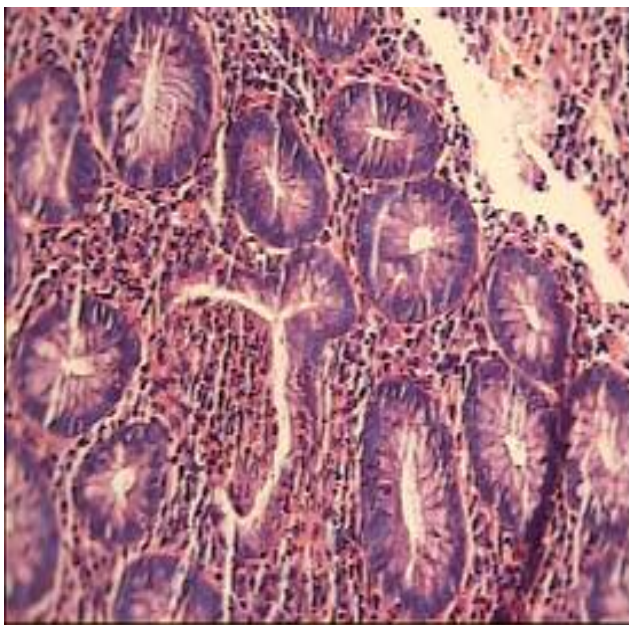


Figure 3. Pathology: cryptitis and crypt abscess

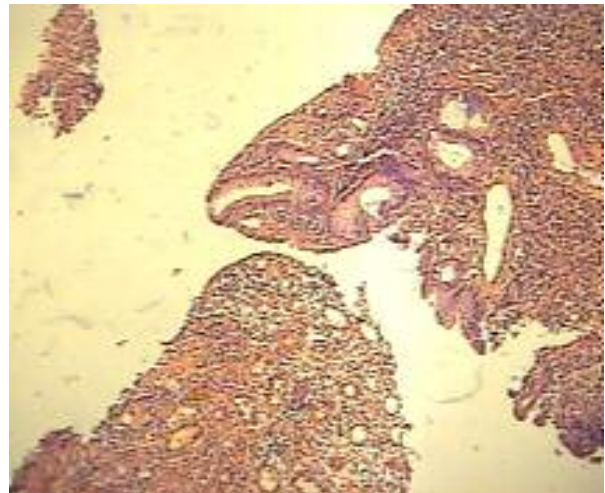


Figure 4. Pathology: pseudopolyp

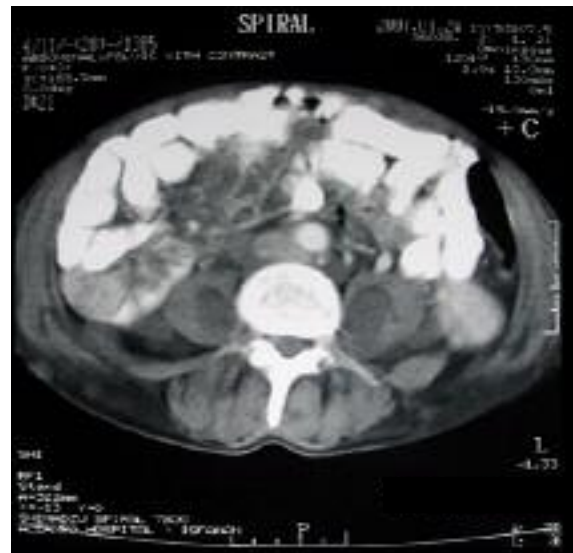

Figure 5. Bilateral psoas muscle neurofibroma

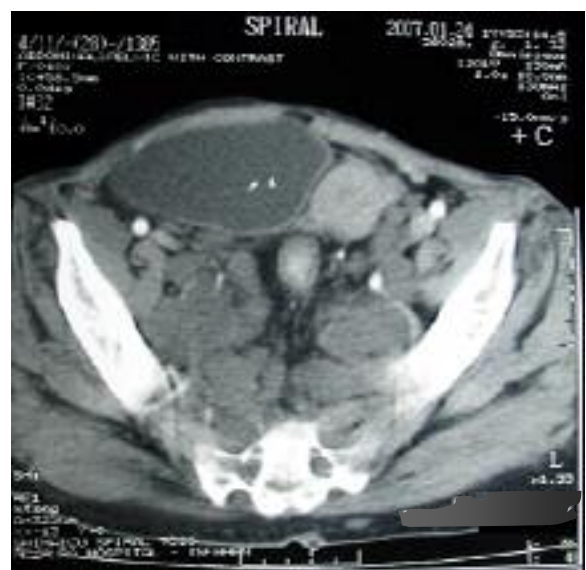

Figure 6. Neurofibromas and ovarian cyst

Discussion

Neurofibromatosis type 1 (von Recklinghausen's disease) is a relatively common autosomal-dominant neurocutaneous disorder that affects all races and both sexes equally. The diagnosis of NF1 is largely based on clinical criteria established by the National Institutes of Health Consensus Development Conference.⁹ In our case, NF1 was diagnosed according to typical skin lesions and positive family history that was mentioned about her daughter.

In review of the English literature, only one patient with an isolated neurofibroma in the large bowel who suffered from segmental colitis and presented with bloody diarrhea was reported.¹⁰ As it is described in that case, colonoscopy up to hepatic flexure revealed erythema and edema of the mucosa with hemorrhagic petechiae at the splenic flexure and proximal portion of the descending colon. It is also mentioned that the microscopic examination did not support a definite diagnosis of idiopathic inflammatory bowel disease and pathologic changes were classified as nonspecific colitis.¹¹

However, our patient had a typical endoscopic (avascularity, friability, and ulceration) as well as pathologic (cryptitis, crypt abscess, and goblet cell depletion) findings compatible with ulcerative colitis. The presence of pseudopolyps in colonoscopy, confirmed with pathology, was indicative of a prolonged ulcerative colitis.

Although the occurrence of neurofibromatosis and ulcerative colitis in our patient may be a very rare accidental finding, these two entities may be associated according to the involvement of mast cells in the pathophysiology of both of them. Mast cells are an important element in the pathogenesis of IBD, though the mechanisms are not well known.¹² Interactions between neuronal elements and mast cells play a significant role in the progress and maintenance of IBD. Substance P (SP) has been identified in nerve endings throughout the gastrointestinal tract, where the mast cells are localized. The neuropeptide SP is shown to prefer-

entially enhance mucosal mast cells mediator secretion in active IBD.^{13,14} Subjects with IBD have also heightened responses to stressors (via Brain Gut Axis activity) and greater associated epithelial damage. Stress causes activation and degranulation of mucosal mast cells in patients with IBD.¹⁵ Although neurofibromas consist mostly of Schwann cells and fibroblasts, they also contain other cell types, including perineural cells, mast cells, pericytes, endothelial cells, smooth muscle cells, and cells with intermediate features.¹⁶ Mast cells are important to tumor initiation, progression, and angiogenesis. Recent studies showed the contribution of the heterozygous mast cell to neurofibroma formation.^{16,17}

There is another rare finding in our patient. The patient has bilateral psoas muscle neurofibroma that is not common in NF1. The fact that retroperitoneal plexiform neurofibromatosis is usually bilateral and symmetric can facilitate recognition of malignant nerve sheath neoplasms in these patients. Asymmetry in size, however, indicates that larger lesion is likely to be malignant. Unlike most primary retroperitoneal neoplasms, the CT features of most Neurofibromas are so sufficiently characteristic that specific diagnosis usually can be made without invasive procedures.¹⁸

Conclusions

Although tumoral lesions are the most common cause of gastrointestinal bleeding in neurofibromatosis, ulcerative colitis is a rare cause of bloody diarrhea in these patients. The present report may be a very rare accidental finding. However, there may be an association between IBD and NF1 according to the role of mast cells in the pathophysiology of both diseases, which warrants further investigations.

Acknowledgements

We would like to thank the patient who provided a written consent for publication of her medical history within this case report. Also, we are thankful to Ali Gholamrezaei from Poursina Hakim Research Institute for helping with preparation of this report.

Conflict of Interests

Authors have no conflict of interests.

Authors' Contributions

HT has done the colonoscopy, and diagnosed, treated, and followed the patient and prepared the draft of the manuscript. MA took part in history taking, physical examination, and preparing pictures from the patient's lesions. PM and AF have done pathological and radiological studies and diagnosis, respectively.

All authors contribute to writing and editing the final manuscript.

References

1. Levy AD, Patel N, Abbott RM, Dow N, Miettinen M, Sobin LH. Gastrointestinal stromal tumors in patients with neurofibromatosis: imaging features with clinicopathologic correlation. *AJR Am J Roentgenol* 2004;183(6):1629-36.
2. Kim HR, Kim YJ. Neurofibromatosis of the colon and rectum combined with other manifestations of von Recklinghausen's disease: report of a case. *Dis Colon Rectum* 1998;41(9):1187-92.
3. Abramson LP, Orkin BA, Schwartz AM. Isolated colonic neurofibroma manifested by massive lower gastrointestinal bleeding and intussusception. *South Med J* 1997;90(9):952-4.
4. Bakker JR, Haber MM, Garcia FU. Gastrointestinal neurofibromatosis: an unusual cause of gastric outlet obstruction. *Am Surg* 2005;71(2):100-5.
5. Sathe PA, Kulkarni VM, Raut AA, Deolekar SS, Joshi AS. Ileal polyposis as manifestation of neurofibromatosis syndrome. *Indian J Gastroenterol* 2006;25(3):159-60.
6. Stone MM, Weinberg B, Beck AR, Grishman E, Gertner M. Colonic obstruction in a child with von Recklinghausen's neurofibromatosis. *J Pediatr Surg* 1986;21(8):741-3.
7. Sinha SK, Kochhar R, Rana S, Bapuraj R, Singh K. Intestinal pseudo-obstruction due to neurofibromatosis responding to cisapride. *Indian J Gastroenterol* 2000;19(2):83-4.
8. Bretagne JF, Le Pogamp P, Lancien G, Gastard J. Ulcerative hemorrhagic colitis, hyperparathyroidism and Recklinghausen's disease. *Gastroenterol Clin Biol* 1980;4(6-7):497-8.
9. Gutmann DH, Aylsworth A, Carey JC, Korf B, Marks J, Pyeritz RE, et al. The diagnostic evaluation and multidisciplinary management of neurofibromatosis 1 and neurofibromatosis 2. *JAMA* 1997;278(1):51-7.
10. Panteris V, Vassilakaki T, Vaitis N, Elemenoglou I, Mylonakou I, Karamanolis DG. Solitary colonic neurofibroma in a patient with transient segmental colitis: case report. *World J Gastroenterol* 2005;11(35):5573-6.
11. Farhadi A. Mucosal mast cells are pivotal elements in inflammatory bowel disease that connect the dots: stress, intestinal hyperpermeability and inflammation. *World J Gastroenterol* 2007;13(22):3027-30.
12. Raithel M, Schneider HT, Hahn EG. Effect of substance P on histamine secretion from gut mucosa in inflammatory bowel disease. *Scand J Gastroenterol* 1999;34(5):496-503.
13. Stoyanova II, Gulubova MV. Mast cells and inflammatory mediators in chronic ulcerative colitis. *Acta Histochem* 2002;104(2):185-92.
14. Farhadi A, Keshavarzian A, Van de Kar LD, Jakate S, Domm A, Zhang L, et al. Heightened responses to stressors in patients with inflammatory bowel disease. *Am J Gastroenterol* 2005;100(8):1796-804.
15. Gottfried ON, Viskochil DH, Fults DW, Couldwell WT. Molecular, genetic, and cellular pathogenesis of neurofibromas and surgical implications. *Neurosurgery* 2006;58(1):1-16.
16. Yang FC, Ingram DA, Chen S, Hingtgen CM, Ratner N, Monk KR, et al. Neurofibromin-deficient Schwann cells secrete a potent migratory stimulus for Nf1+/- mast cells. *J Clin Invest* 2003;112(12):1851-61.
17. Viskochil DH. It takes two to tango: mast cell and Schwann cell interactions in neurofibromas. *J Clin Invest* 2003;112(12):1791-3.
18. Bass JC, Korobkin M, Francis IR, Ellis JH, Cohan RH. Retroperitoneal plexiform neurofibromas: CT findings. *Am J Roentgenol* 1994;163(3):617-20.