



Novel coronavirus-related acute respiratory distress syndrome in a patient with twin pregnancy: A case report

Harsh Mehta^a, Sasa Ivanovic^a, Amanda Cronin^b, Lindsey VanBrunt^b, Nirav Mistry^{a,c}, Richard Miller^b, Paul Yodice^{a,c}, Fariborz Rezaei^{a,c,*}

^a Saint Barnabas Medical Center, Department of Medicine, Livingston, NJ 07039, USA

^b Saint Barnabas Medical Center, Department of Obstetrics and Gynecology, Livingston, NJ 07039, USA

^c Saint Barnabas Medical Center, Division of Critical Care, Department of Medicine, Livingston, NJ 07039, USA

ARTICLE INFO

Article history:

Received 11 May 2020

Received in revised form 12 May 2020

Accepted 14 May 2020

Keywords:

Novel coronavirus disease

COVID-19

Acute respiratory distress syndrome

Twin pregnancy

Mechanical ventilation

Vertical transmission

ABSTRACT

We present the case of a 39-year-old woman, G1P0, who had conceived twins via in-vitro fertilization, who presented at 27 weeks of gestation with nasal congestion and dry cough for 7 days. On presentation, her physical examination was benign, except for sinus tachycardia, and she was oxygenating adequately on room air. Laboratory studies were unremarkable, except a PCR test positive for SARS-CoV2, and a CT scan of her chest showed bilateral multi-focal ground-glass opacities. A fetal non-stress test was reassuring. She was treated with intravenous fluids, ceftriaxone, azithromycin, and hydroxychloroquine. During her hospital stay, she developed progressively worsening respiratory failure, initially requiring non-invasive ventilation, and subsequently progressed to acute respiratory distress syndrome requiring mechanical ventilation. She then suffered from sudden hypoxemia and hemodynamic collapse, on maximal ventilatory support, prompting an emergency cesarean section at bedside. This led to rapid stabilization of hemodynamic parameters, and of her overall respiratory status. Both the twins were born prematurely, and one of them tested positive for SARS-CoV2.

© 2020 Published by Elsevier B.V. This is an open access article under the CC BY-NC-ND license (<http://creativecommons.org/licenses/by-nc-nd/4.0/>).

1. Introduction

Since its first reported case in China, more than 4 million cases and around 270,000 deaths worldwide have been attributed to Coronavirus Disease 2019 (COVID-19) [1]. The causative agent for this pandemic is severe acute respiratory syndrome coronavirus-2 (SARS-CoV2), a new type of enveloped RNA coronavirus [1,2]. Coronaviruses are known pathogens and have previously been responsible for epidemics caused by severe acute respiratory syndrome coronavirus (SARS-CoV1) and Middle Eastern respiratory syndrome coronavirus (MERS-CoV) [2].

Pregnancy is a unique immunologic state, where the maternal immune system is modulated to allow tolerance to paternally derived fetal antigens, thereby leading to an increased susceptibility to infections, especially pneumonia [3]. In one study, up to 25% of pregnant women with pneumonia required critical care services, including mechanical ventilation [4]. Overall, pregnant women are more susceptible to respiratory pathogens, and might be at an increased risk for COVID-19 [5]. During the previous SARS and MERS outbreaks, pregnant

women were reported to have poorer outcomes than the general population [4]. We report a case of a high-risk pregnant woman who developed respiratory failure associated with COVID-19, and had a favorable outcome post-delivery. We also report possible vertical transmission of COVID-19 infection in this case.

2. Case Presentation

A 39-year-old African American pregnant woman (G1P0) presented to the emergency department with a 7-day history of nasal congestion and dry cough. She was at 27 weeks of ultrasound-confirmed in-utero gestation with diamniotic-dichorionic twins, achieved via in-vitro fertilization. Two days prior to presentation, she started experiencing chest discomfort and shortness of breath. She eventually developed fever, which prompted her visit to the emergency department. She had no known medical problems, and her current pregnancy had been uneventful. She denied recent travel. Her only medications included prenatal vitamins and aspirin.

On arrival at the emergency department, she had a temperature of 98.3 °F (36.8 °C), a heart rate of 121 beats/min, blood pressure of 135/105 mmHg, respiratory rate of 20 breaths/min, and an oxygen saturation of 96% on room air. On physical examination, her lungs were clear to auscultation bilaterally, while a cardiac exam revealed tachycardia with a regular rhythm and normal heart sounds. Abdominal exam was

* Corresponding author at: 94 Old Short Hills Road, Livingston, NJ 07039, USA.

E-mail addresses: harsh.mehta@rwjbh.org (H. Mehta), sasa.ivanovic@rwjbh.org (S. Ivanovic), amanda.peguillan@rwjbh.org (A. Cronin), lindsey.vanbrunt@rwjbh.org (L. VanBrunt), nirav.mistry@rwjbh.org (N. Mistry), rmiller@sbmfm.com (R. Miller), paul.yodice@rwjbh.org (P. Yodice), fariborz.rezaei@rwjbh.org (F. Rezaei).

consistent with 27 weeks of gestation. Bilateral lower extremities were symmetric without cyanosis or edema.

A fetal non-stress test (NST) showed moderate heart rate variability and no decelerations for both the twins. Laboratory tests were mostly unremarkable, as shown in Table 1. Tests for influenza and other respiratory pathogens were negative. A nasopharyngeal swab for COVID-19 RT-PCR was obtained. A CT angiogram of her chest was negative for pulmonary embolism (PE), but revealed multifocal patchy ground-glass opacities in both her lungs, consistent with multi-lobe pneumonia.

She was started on intravenous fluids, ceftriaxone and azithromycin. Her COVID-19 test came back as positive after 27 h. Hydroxychloroquine was added, and betamethasone was administered for fetal lung maturity. Over the next two days, her respiratory status worsened, leading to a requirement for supplemental oxygen.

On day 4, she became tachypneic and started requiring increasing amounts of oxygen, for which the FiO₂ was increased to 80%, delivered at 35 L/min via a high-flow nasal cannula. She was then transferred to the intensive care unit (ICU) and required endotracheal intubation and mechanical ventilation. Settings were adjusted to a tidal volume of 500 mL/breath, respiratory rate of 18 breaths/min, positive end-expiratory pressure (PEEP) of 10 cm H₂O and FiO₂ of 70%. A repeat chest X-ray showed worsening bilateral pulmonary infiltrates, raising concern for development of acute respiratory distress syndrome (ARDS). Over the next two days, she required maximal ventilator support, with a FiO₂ of 100%. Her blood pressure also dropped to 92/52 mmHg, for which was started on norepinephrine. Fetal heart tracings were recorded daily, which continued to be reassuring up to this point.

On day 7, her condition rapidly deteriorated, with oxygen saturation dropping to 80%; hence PEEP was increased to 14 cm H₂O, while maintaining an FiO₂ of 100%. Chest x-ray showed worsening bilateral alveolar infiltrates, consistent with progressing ARDS. During this time, her vasopressor requirements also increased significantly, and the norepinephrine was increased to 30 µg/min to achieve a mean arterial pressure (MAP) of 65 mmHg. Due to rapid maternal decompensation, we decided to deliver the fetuses. A classical C-section was performed at the patient's bedside, and two fetuses were delivered successfully. Baby A was female, weighed 925 g, and had APGAR scores of 1, 3 and 6 at 1, 5 and 10 min respectively. Baby B was male, weighed 1050 g, and had APGAR scores of 5, 6 and 6 at 1, 5 and 10 min respectively. The neonates were immediately transferred to the neonatal intensive care unit (NICU).

Immediately after uterine decompression, hemodynamic parameters improved significantly. Norepinephrine was titrated down to 6 µg/min and the patient gradually weaned off. FiO₂ was decreased to 40% within an hour, while PEEP was gradually decreased to 10 cm H₂O. Details of her vasopressor and ventilator requirements are

outlined in Fig. 1. On day 9, she was successfully extubated and eventually transferred out of the ICU. She was weaned off supplemental oxygen and was soon discharged home. The neonates were tested for COVID-19. Twin A tested positive 72 h after birth; however, she did not exhibit any infectious symptoms. Twin B tested negative at 72 h after birth. His course was complicated by development of alveolar hemorrhage, which was attributed to preterm delivery. He required invasive mechanical ventilation for the same.

3. Discussion

Our patient suffered from a progressively worsening respiratory failure, culminating in ARDS. High circulating volume, low albumin levels, increased capillary leak and development of a pro-inflammatory state have all been proposed as mechanisms predisposing pregnant women to ARDS [3]. Following the American Thoracic Society's guidelines for management of ARDS, our patient was mechanically ventilated while a low tidal volume was delivered along with a high PEEP to maintain an oxygen saturation of more than 92% [7].

Of note, on the seventh day of hospitalization, our patient's condition rapidly deteriorated, and she required increasing ventilatory and vasopressor support. This deterioration was attributed to rapidly worsening ARDS. However, it is also important to identify that the high PEEP, which was originally applied to combat ARDS, could have led to increased intrathoracic pressure, ultimately leading to decreased venous return and cardiac output [7]. Furthermore, in pregnancy, despite hypervolemia, the effect of the gravid uterus on inferior vena cava can compromise venous return, which, in combination with a high PEEP, can precipitate hypotension [8]. And hence, the fact that after delivery, her hemodynamic parameters rapidly improved can be attributed to the reduction in oxygen consumption and effective deliverance of preload, thereby leading to an improvement in cardiac output, and ultimately, in gas exchange. While prone positioning has been shown to reduce mortality in patients with severe ARDS by means of improved lung recruitment, data regarding its utility in pregnancy is sparse [9–11]. Due to this reason, we decided against pronating the patient at the time of her rapid deterioration.

In the data available in pregnant patients from the previous coronavirus outbreaks, no vertical transmission was reported [4]. In a recently published review of 37 pregnant mothers with COVID-19 and their 38 newborns, no vertical transmission was reported. Of these, all neonates with confirmed COVID-19 had been infected after birth, via droplet or contact transmission [6]. In our case, the patient was intubated at the time of delivery, making droplet transmission unlikely. The babies were delivered via C-section, eliminating the possibility of fetal contact with maternal feces, which has been reported as a mode of transmission. During delivery, appropriate sterilization techniques and precautions were utilized, and any maternal contact with the neonates was avoided. Both the neonates were transferred to the NICU immediately after birth. They were not breastfed, and appropriate aerosol and contact precautions were utilized during their handling in the NICU. Twin A tested positive and Twin B tested negative for COVID-19 at 72 h. Due to the reasons above, we believe that Twin A tested positive due to vertical transmission. We acknowledge that there are limitations to our theory. Firstly, the placenta and umbilical cord blood were not tested for COVID-19 and, secondly, vertical transmission would have affected both twins, but Twin B, in our case, tested negative.

In conclusion, our knowledge regarding the disease course of COVID-19 during pregnancy is limited to the data available from previous epidemics of SARS-CoV1 and MERS-CoV infections. COVID-19 has so far proven to be a highly contagious and lethal infection that can lead to rapidly worsening respiratory failure and death in the general population. Our case reflects that pregnant women are certainly as susceptible, if not more, and, hence, these patients should be closely followed by a multidisciplinary team of physicians. Prearranged plans for urgent delivery and neonatal resuscitation should be put in place, in anticipation of spontaneous labor or sudden maternal or fetal decline. While the

Table 1
Pertinent laboratory results during hospitalization.

	Reference Ranges	Day-0	Day-1	Day-6	Day-8	Day-10
COVID-19 RT PCR			Positive			
WBC (K/CMM)	4–10.5	5.6	4.1	11.3	9.2	9.9
Hemoglobin (g/dL)	12–15.7	12.8	12.2	12	10.4	8.9
Absolute lymphocyte count (K/CMM)	0.8–4.8	1.1	0.6	1.3	1.4	1.4
Platelet (K/CMM)	140–450	180	176	288	315	426
BUN (mg/dL)	10–26	4.4	3	3.8	7.9	8.3
Creatinine (mg/dL)	0.4–1.10	0.42	0.34	0.3	0.4	0.28
INR	0.9–1.1				1.1	
LDH (Unit/L)	60–200		272			
Fibrinogen (mg/dL)	244–550			>700		
Lactic Acid (mmol/L)	0.5–2.2				1.1	
CRP (mg/dL)	0–0.5		4.21			
D-dimer (Ddu ng/mL)	≤243			1018		
CK (Unit/L)	≤225				331	
Procalcitonin (ng/mL)				0.08		
Ferritin (ng/mL)	13.0–150.0			146.9		

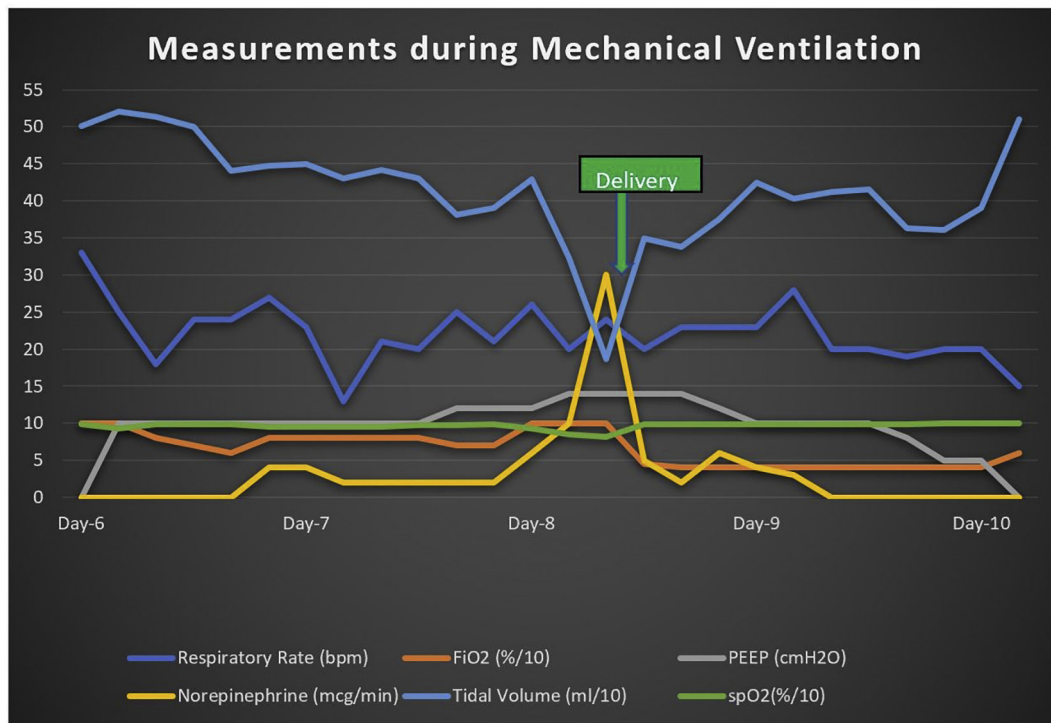


Fig. 1. Ventilator and Vasopressor requirements during the ICU stay. It demonstrates the rapid hemodynamic compromise, and subsequent stabilization post-delivery.

vertical transmission of infection has not been reported until now, our case prompts us to think that it could certainly be possible and further research is warranted on the subject.

Contributors

Harsh Mehta contributed to project conceptualization, and writing and editing of the manuscript.

Sasa Ivanovic contributed to editing of the manuscript.

Amanda Cronin contributed to editing of the manuscript.

Lindsay VanBrunt contributed to editing of the manuscript.

Nirav Mistry contributed to critical review of the manuscript.

Richard Miller contributed to critical review of the manuscript.

Paul Yodice contributed to critical review of the manuscript.

Fariborz Rezaei contributed to editing and critical review of the manuscript.

Conflict of Interest

The authors declare that they have no conflict of interest regarding the publication of this case report.

Funding

The authors declare that they did not receive any funding for their work in the production of this manuscript.

Patient Consent

Obtained.

Provenance and Peer Review

This case report was peer reviewed.

Acknowledgements

Ishani Shah- Department of Internal Medicine, Creighton University St. Joseph's Hospital and Medical Center, Phoenix, AZ (Email: ishani1991@gmail.com) for her help in reviewing and editing the manuscript.

References

- [1] Coronavirus disease 2019 (COVID-19), Situation Report – 112 (5/11/2020), 2020 https://www.who.int/docs/default-source/coronavirus/situation-reports/20200511-covid-19-sitrep-112.pdf?sfvrsn=813f2669_2.
- [2] N. Zhu, et al., A novel coronavirus from patients with pneumonia in China, 2019, *N. Engl. J. Med.* 382 (8) (2020) 727–733.
- [3] S.E. Lapinsky, Acute respiratory failure in pregnancy, *Obst. Med.* 8 (3) (2015) 126–132.
- [4] A.D. Schwartz, L.A. Graham, Potential maternal and infant outcomes from coronavirus 2019-nCoV (SARS-CoV-2) infecting pregnant women: lessons from SARS, MERS, and other human coronavirus infections, *Viruses* (2020) 12(2).
- [5] H. Liu, et al., Why are pregnant women susceptible to COVID-19? An immunological viewpoint, *J. Reprod. Immunol.* 139 (2020) 103122.
- [6] L. Panahi, M. Amiri, S. Pouy, Risks of novel coronavirus disease (COVID-19) in pregnancy; a narrative review, *Arch. Acad. Emerg. Med.* 8 (1) (2020), e34.
- [7] E. Fan, et al., An official American Thoracic Society/European Society of Intensive Care Medicine/Society of Critical Care Medicine clinical practice guideline: mechanical ventilation in adult patients with acute respiratory distress syndrome, *Am. J. Respir. Crit. Care Med.* 195 (9) (2017) 1253–1263.
- [8] P. Soma-Pillay, et al., Physiological changes in pregnancy, *Cardiovas. J. Africa* 27 (2) (2016) 89–94.
- [9] C. Guérin, et al., Prone positioning in severe acute respiratory distress syndrome, *N. Engl. J. Med.* 368 (23) (2013) 2159–2168.
- [10] C. Pan, et al., Lung recruitability in SARS-CoV-2 associated acute respiratory distress syndrome: a single-center, observational study, *Am. J. Resp. Critic. Care Med.* 0 (2020)(ja): p. null.
- [11] S. Samanta, et al., How safe is the prone position in acute respiratory distress syndrome at late pregnancy? *Am. J. Emerg. Med.* 32 (6) (2014)p. 687. e1–3.