

Power-assisted Liposuction and a Single Incision Pull-through Technique for Top Surgery: A Case Report

Brendon A. Bitoiu, BA*
Daniel E. McKee, MD, FRCSC†

Summary: Various treatment approaches exist for female-to-male subcutaneous mastectomy, also known as “top surgery.” The most commonly performed techniques for patients with decreased volume of breast tissue, no ptosis, and good skin elasticity continue to involve areolar or periareolar incision. Here, we report a case of a 17-year-old patient who underwent top surgery performed through power-assisted liposuction and a non-areolar single-incision “pull-through” technique. Operative management included initial liposuction for contouring of adipose tissue. Surgical subcision of excess breast tissue adherent to the subdermal plane was then performed and removed with a grasp-and-pull motion using the pull-through technique. We obtained a favorable result with low scar burden, preserved nipple sensation, and no nipple contracture. No complications were reported. This procedure is limited for patients with small breast size (A cup, <100 grams of glandular tissue per side), minimal to no ptosis, appropriate nipple size and position, soft fibroglandular tissue, and good skin elasticity. (*Plast Reconstr Surg Glob Open* 2021;9:e3341; doi: [10.1097/GOX.0000000000003341](https://doi.org/10.1097/GOX.0000000000003341); Published online 26 January 2021.)

Female-to-male (FTM) subcutaneous mastectomy (also known as “top surgery”) is an increasingly common procedure for transgender patients.¹ Its prevalence varies by country, with 0.17:100,000 reported in Sweden compared with 17.9:100,000 in Singapore.² Top surgery may be the first and only operation that patients go through in the gender-affirming transition.³

Popularized surgical techniques include: semicircular (keyhole), concentric circumareolar, extended concentric circumareolar, Wise pattern reduction, inferior pedicled, and double incision with nipple graft.³⁻⁷

There is ongoing debate about which technique provides optimal aesthetics with the lowest complication rates. All, however, are focused on the primary goal of removing breast parenchyma, obliteration of the inframammary

fold, appropriate sizing and position of the nipple–areolar complex, and minimizing scar burden.²

Liposuction, as a solo technique for glandular removal, has limited use in top surgery.² Reasons include ineffective glandular removal, residual skin excess, and contour difficulties.² We describe a novel technique using a combination of liposuction and a pull-through technique of remaining glandular tissue using a single minimal incision that is placed inferolateral on the chest.

Advantages of a single-incision pull-through technique include an inconspicuous scar on the lateral side wall of the chest while avoiding areolar distortion from scar contracture, smaller scar burden, and preserved nipple sensation.⁴

CASE REPORT

This case report involves a 17-year-old patient seen for an outpatient bilateral chest mastectomy for gender-affirming top surgery. The patient measured 160 cm in height, and weighed 110 pounds. Examination of the chest showed a breast cup size A, no ptosis, good skin elasticity, appropriate NAC size and position, and soft fibroglandular tissue (Fig. 1). Before operation, we discussed the patient’s wishes to have this done percutaneously through an inferolateral incision, possibly converting into a periareolar incision depending on intraoperative findings. The patient was marked in a standing position. Informed consent was obtained from the individual participant included in the study.

Disclosure: The authors have no financial interest to declare in relation to the content of this article.

From the *Faculty of Medicine, University of British Columbia, Vancouver, B.C., Canada; and †Department of Plastic Surgery, Division of Plastic Surgery, University of British Columbia, Vancouver, B.C., Canada.

Received for publication August 23, 2020; accepted November 11, 2020.

Copyright © 2021 The Authors. Published by Wolters Kluwer Health, Inc. on behalf of The American Society of Plastic Surgeons. This is an open-access article distributed under the terms of the [Creative Commons Attribution-Non Commercial-No Derivatives License 4.0 \(CCBY-NC-ND\)](https://creativecommons.org/licenses/by-nc-nd/4.0/), where it is permissible to download and share the work provided it is properly cited. The work cannot be changed in any way or used commercially without permission from the journal.

DOI: [10.1097/GOX.0000000000003341](https://doi.org/10.1097/GOX.0000000000003341)

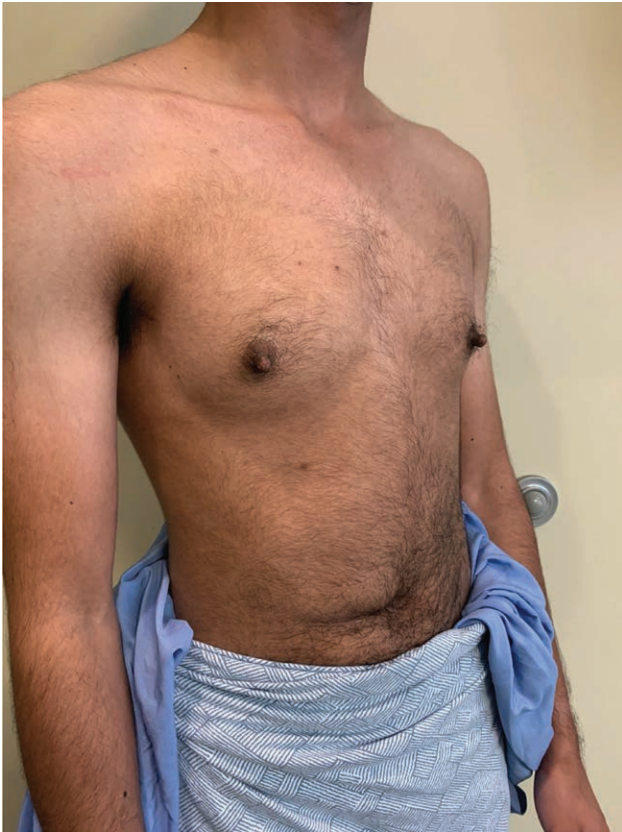

Fig. 1. Pre-operative examination of the chest.

The patient was placed in a supine position and general anesthesia was administered. Tranexamic acid was administered prophylactically. An estimated 250cm³ of Klein solution (1L of normal saline, 1000mg lidocaine, 1mg epinephrine, and 10 mEq of bicarbonate) was infiltrated into each breast. A 10-mm incision inferolaterally in the inframammary fold was used to access the glandular tissue. Power-assisted liposuction with a 4-mm cannula was used to remove 160cm³ of aspirate percutaneously in a subcutaneous

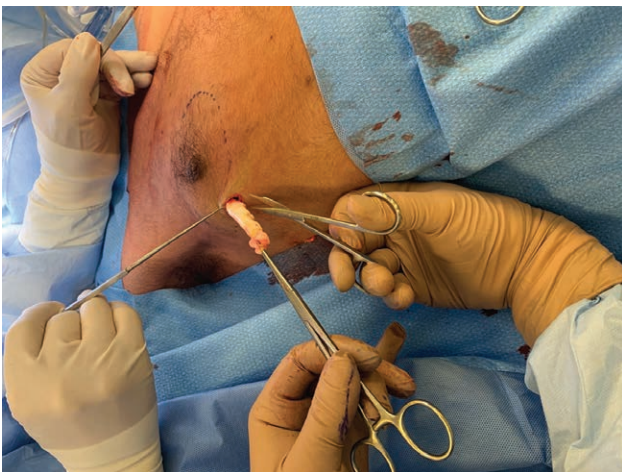


Fig. 2. Pull-through technique through a single inferolateral incision. Glandular tissue was excised using a "grasp-and-pull" motion.

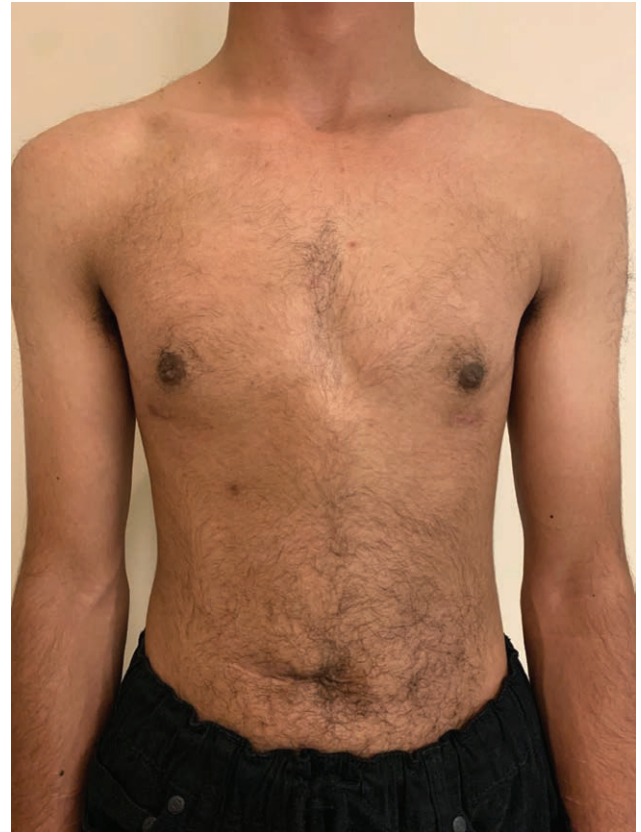

Fig. 3. 1 month post-operative follow-up: frontal view.

plane from both breasts. Liposuction was also used to contour and break up adipose tissue. Surgical subcision of excess breast tissue adherent to the subdermal plane was performed using a V-dissector cannula and no. 12 blade scalpel. The pull-through technique of remaining glandular tissue was then performed using a 19-cm straight Brand tendon tunnel forceps. Dissection was carefully performed by pinching the overlying skin with 1 hand while the other used a "grasp-and-pull" motion (Fig. 2). This was performed throughout until the contour of the chest felt smooth. The glandular tissue excised from each breast weighed 39g and 38g.

Nipple projection was reduced with direct excision and stitch approximation. The areola was not modified. Bleeding was minimal. The patient's incision was closed in layers, and Steri-Strips applied with Dermabond and Mastisol. A negative drainage system was not used. A chest binder was applied immediately post-operatively for 1 month. The patient was given cefalexin for 5 days post-operatively.

There were no complications such as infection, hematoma, seroma, or dehiscence that have been reported. In post-operative follow-up, the patient described taking a combination of Advil and Tylenol with no use of narcotics. The patient was seen at 1 month post-operative, with the chest binder removed (Figs. 3 and 4). Nipple sensation was preserved.

DISCUSSION

In 2008, Monstrey presented an algorithm for 5 female-to-male surgical techniques dependent on skin elasticity,

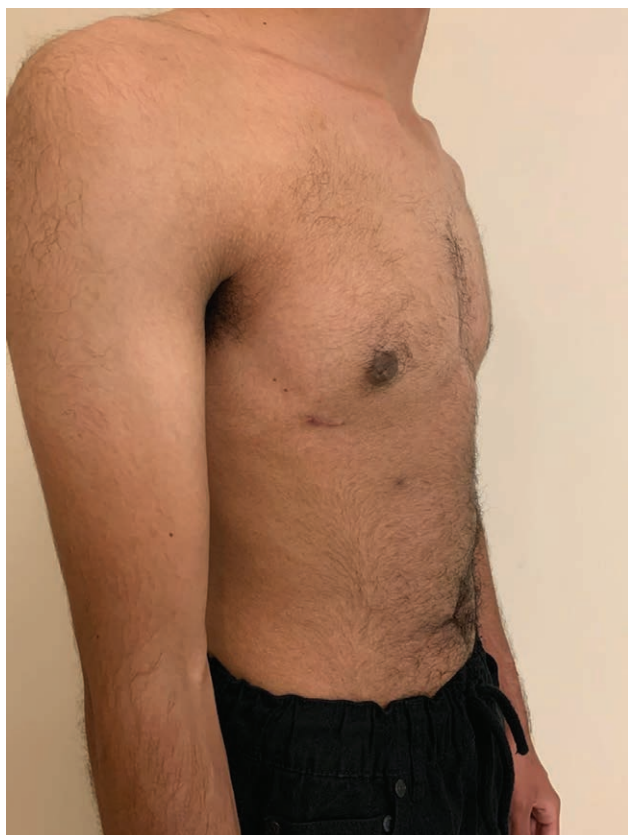

Fig. 4. 1 month post-operative follow-up: lateral view.

breast volume, degree of excess skin, and NAC size and position.⁵ This algorithm has been utilized over the years with successful outcomes. Since then, multiple alternative algorithms have been proposed with similar congruency amongst them.⁸

For patients with smaller breasts (size A), grade 0-1 Regnault ptosis, and good skin elasticity, current algorithms frequently recommend either a semicircular, transareolar, or concentric circumareolar approach.⁵⁻⁷ A combination of power-assisted liposuction and a “pull-through” technique was first described by Morselli in 1996 for the treatment of male gynecomastia.⁹ This technique allows for removal of adherent fibroglandular tissue in the subdermal plane through a minimally invasive technique. This technique has recently been modified and discussed for top surgery through a multiple-incision approach (as opposed to 1 incision that we describe).⁴

Previous literature has documented an increased risk of hematoma with minimally invasive techniques.¹⁰ Anecdotal evidence suggests that hematoma risk can be reduced through the use of tranexamic acid, careful monitoring of intra-operative bleeding, and post-operative chest binder. If a hematoma develops, management options include (1) immediate surgical intervention and

drainage to control active bleeding, or significant pressure to skin flaps; (2) delayed needle aspiration; and (3) conservative management with external pressure from a chest binder, until the hematoma reabsorbs.

Our group has had success with a novel single-incision pull-through technique for both gynecomastia and top surgery, corroborating and expanding on Morselli’s previous work. This procedure is appropriate for patients with small breast size, no ptosis, non-dense glandular tissue, good skin elasticity, and no modification to NAC diameter is required. A tool comparable to BREAST-Q to assess the patient experience and quality of life would be useful in comparing this technique with other small-incision techniques in the future.

Daniel E. McKee, MD, FRCSC

Department of Surgery

Division of Plastic Surgery

University of British Columbia

Vancouver, British Columbia

Canada

E-mail: daniel.mckee@alumni.ubc.ca

Website: www.vancouvertopsurgery.com

ACKNOWLEDGMENT

The authors thank Alana Mckee (Carleton University, Canada) for her research assistance.

REFERENCES

1. Tran BNN, Epstein S, Singhal D, et al. Gender affirmation surgery: A synopsis using American College of Surgeons National Surgery Quality Improvement Program and National Inpatient Sample databases. *Ann Plast Surg.* 2018;80(4 suppl 4):S229–S235.
2. Berry MG, Curtis R, Davies D. Female-to-male transgender chest reconstruction: A large consecutive, single-surgeon experience. *J Plast Reconstr Aesthet Surg.* 2012;65:711–719.
3. McEvenue G, Xu FZ, Cai R, et al. Female-to-male gender affirming top surgery: A single surgeon’s 15-year retrospective review and treatment algorithm. *Aesthet Surg J.* 2017;38:49–57.
4. Morselli PG, Summo V, Pinto V, et al. Chest wall masculinization in female-to-male transsexuals: Our treatment algorithm and life satisfaction questionnaire. *Ann Plast Surg.* 2019;83:629–635.
5. Monstrey S, Selvaggi G, Ceulemans P, et al. Chest-wall contouring surgery in female-to-male transsexuals: A new algorithm. *Plast Reconstr Surg.* 2008;121:849–859.
6. Hage JJ, Bloem JJ. Chest wall contouring for female-to-male transsexuals: Amsterdam experience. *Ann Plast Surg.* 1995;34:59–66.
7. Wolter A, Diedrichson J, Scholz T, et al. Sexual reassignment surgery in female-to-male transsexuals: An algorithm for subcutaneous mastectomy. *J Plast Reconstr Aesthet Surg.* 2015;68:184–191.
8. Kühn S, Keval S, Sader R, et al. Mastectomy in female-to-male transgender patients: A single-center 24-year retrospective analysis. *Arch Plast Surg.* 2019;46:433–440.
9. Morselli PG. “Pull-through”: A new technique for breast reduction in gynecomastia. *Plast Reconstr Surg.* 1996;97:450–454.
10. Cohen WA, Shah NR, Iwanicki M, et al. Female-to-male transgender chest contouring: A systematic review of outcomes and knowledge gaps. *Ann Plast Surg.* 2019;83:589–593.