

Fibrous dysplasia as a possible false-positive finding in ⁶⁸Ga-labeled prostate-specific membrane antigen positron emission tomography/computed tomography study in the follow-up of prostate cancer

ABSTRACT

Positron emission tomography/computed tomography (PET/CT) using ⁶⁸Ga-labeled prostate-specific membrane antigen (⁶⁸Ga-PSMA) has become an important tool in restaging patients with prostate cancer (PCa). Despite its high sensitivity and specificity, this method may produce false-positive findings, as indicated by previous studies. This case report aims to warn nuclear medicine physicians, oncologists, and urologists about the possibility of false-positive findings using this imaging modality, especially when the detected site is unusual for bone metastasis. A 68-year-old man with PCa underwent restaging tests after presenting with increased prostate-specific antigen. ⁶⁸Ga-PSMA PET/CT imaging revealed abnormal uptake in the left humeral head, which anatomically corresponded to the intramedullary and cortical sclerotic area. A biopsy was performed, and the pathology showed a lesion consisting of hard bone tissue with a small focal spot of fibrous dysplasia. Diagnostic issues related to ⁶⁸Ga-PSMA PET/CT imaging should be disseminated to help physicians make appropriate treatment choices for each patient.

Keywords: ⁶⁸Ga-labeled prostate-specific membrane antigen, bone metastasis, false-positive result, fibrous dysplasia, prostate cancer

INTRODUCTION

Prostate cancer (PCa) is the most common noncutaneous malignant tumor among men, with an estimated incidence of 1.4 million new diagnoses worldwide in 2013.^[1] It usually metastasizes to bone before other sites. Previous studies have indicated that the most common sites of bone metastases are lumbar and thoracic spine (74%), ribs (70%), pelvis (60%), femurs (44%), and shoulders (41%).^[2] In their meta-analysis, Perera *et al.* suggested that positron emission tomography/computed tomography (PET/CT) using ⁶⁸Ga-labeled prostate-specific membrane antigen (⁶⁸Ga-PSMA) provides superior sensitivity and specificity to detect metastasis compared to alternative techniques.^[3] However, despite its high sensitivity for malignancy, increased ⁶⁸Ga-PSMA uptake may also occur in normal structures and benign lesions.^[4] Fibrous dysplasia is

a benign bone lesion that may lead to false-positive results, as described by De Coster *et al.*^[5]

This case report aims to warn nuclear medicine physicians, oncologists, and urologists about the possibility of

**ANDRÉ MARCONDES BRAGA RIBEIRO,
EDUARDO NÓBREGA PEREIRA LIMA,
MAURÍCIO MURCE ROCHA¹**

Departments of Nuclear Medicine and ¹Urology,
A. C. Camargo Cancer Center, São Paulo, Brazil


Address for correspondence: Dr. André Marcondes Braga Ribeiro,
Department of Nuclear Medicine, A. C. Camargo Cancer Center,
Rua Professor Antônio Prudente, 211, Liberdade,
São Paulo, Brazil.
E-mail: andre_mbr@hotmail.com

Submission: 06-12-2018 **Accepted:** 21-12-2018 **Published:** 18-12-2019

This is an open access journal, and articles are distributed under the terms of the Creative Commons Attribution-NonCommercial-ShareAlike 4.0 License, which allows others to remix, tweak, and build upon the work non-commercially, as long as appropriate credit is given and the new creations are licensed under the identical terms.

For reprints contact: reprints@medknow.com

How to cite this article: Ribeiro AM, Lima EN, Rocha MM. Fibrous dysplasia as a possible false-positive finding in ⁶⁸Ga-labeled prostate-specific membrane antigen positron emission tomography/computed tomography study in the follow-up of prostate cancer. *World J Nucl Med* 2019;18:409-12.

Access this article online	
Website: www.wjnm.org	Quick Response Code 
DOI: 10.4103/wjnm.WJNM_111_18	

false-positive findings using this imaging modality, especially when the detected site is unusual for bone metastasis from PCa.

CASE REPORT

A 68-year-old man underwent radical prostatectomy for PCa treatment in another institution in 2013. After surgery, follow-up was irregular. Surgical pathology examination revealed the presence of acinar adenocarcinoma (Gleason score $4 + 3 = 7$) compromising the right lobe, 15% of the parenchyma, and circumferential margins. Seminal vesicles were unaffected. It was staged as pT2bN0. In November 2017, the patient had an appointment at the urology department of our institution to investigate increased levels of prostate-specific antigen (PSA). PSA values were 0.32 in June 2015 and rose to 1.26 in November 2017, characterizing a biochemical relapse. A restaging process was initiated with multiparametric magnetic resonance imaging (mpMRI) and ^{68}Ga -PSMA PET/CT. mpMRI showed a small hypervascular nodule with discrete hypersignal at T2, restriction to the diffusion of water molecules in the diffusion-weighted imaging sequence, and hypointensity in the apparent diffusion coefficient map on the right side of the prostate bed measuring $9\text{ mm} \times 6\text{ mm}$, suggesting local recurrence. The ^{68}Ga -PSMA study was performed in two steps in PET/CT Philips Gemini TF 64 ToF. In the first stage, performed after 60 min of the ^{68}Ga -PSMA injection, an image of the whole body. In the second stage, performed after 90 min of the ^{68}Ga -PSMA injection, a specific protocol for the acquisition of pelvic topography was performed to obtain images with higher resolution. Consistent with that finding, ^{68}Ga -PSMA PET/CT imaging revealed the formation of a nodule on the right side of the prostate bed (standardized uptake value [SUV] = 3.2) that was considered site of active prostatic neoplasm. The examination also showed abnormal ^{68}Ga -PSMA uptake (SUV = 4.2) in an unusual bone structure, corresponding to the intramedullary and cortical sclerotic area in the left humeral head [Figures 1-3]. A direct investigation by biopsy was suggested to evaluate a possible bone metastatic lesion in that area of the humerus. The patient was referred to the orthopedics department, and radiography and MRI of the left shoulder were performed. The radiograph showed a radiolucent lesion surrounded by a narrow sclerotic halo, with no cortical rupture, periosteal reaction, or involvement of soft tissues. It measured $20\text{ mm} \times 15\text{ mm}$ and was located inferiorly to the lesser tubercle of the left humerus [Figure 4]. The MRI revealed the presence of a bone lesion in the proximal metaphysis of the left humerus, inferior to the greater tubercle. Hyperintensity on T1 sequences and heterogeneous signal intensity after contrast

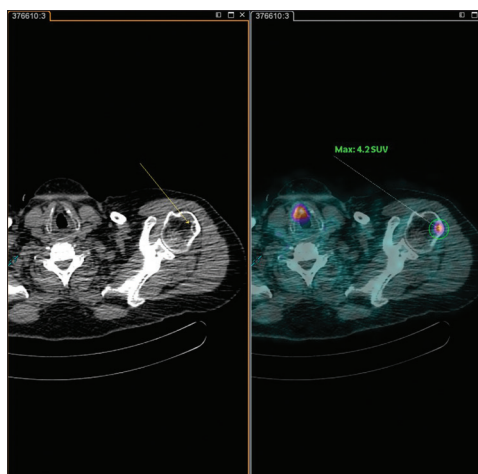


Figure 1: Axial low-dose computed tomography scan (on the left) and positron emission tomography/computed tomography fusion (on the right) showing ^{68}Ga -labeled prostate-specific membrane antigen uptake in the sclerotic area of the left humeral head (standardized uptake value = 4.2)

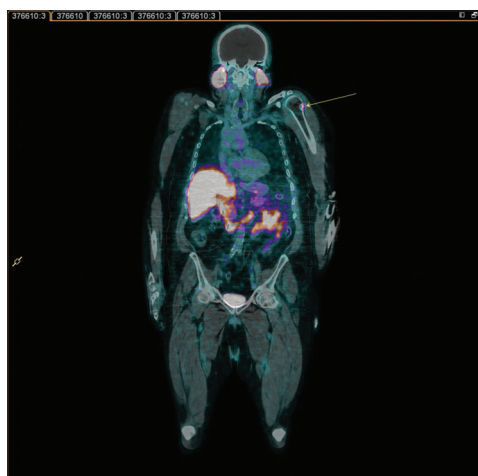

Figure 2: Coronal whole-body positron emission tomography/computed tomography fusion showing ^{68}Ga -labeled prostate-specific membrane antigen uptake in the left humeral head (arrow)

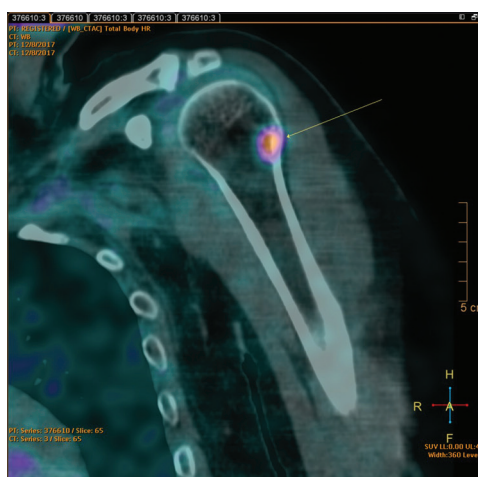


Figure 3: Coronal positron emission tomography/computed tomography fusion showing ^{68}Ga -labeled prostate-specific membrane antigen uptake in the sclerotic area of the left humeral head (arrow)

medium administration were observed, with hypointense margins on all sequences (sclerosis). The lesion measured 17 mm × 16 mm and had low-grade appearance [Figures 5-7]. A CT-guided biopsy was then performed [Figure 8], and the pathology test showed a lesion consisting of hard bone tissue with a small focal spot of fibrous dysplasia and no morphological evidence of malignancy.

DISCUSSION

A significant number of men undergoing curative treatment for PCa may be further diagnosed with recurrent or metastatic disease.^[6] PCa diagnosis and staging and other oncological pathologies depend largely on morphological (CT and MRI) and metabolic (^{99m}Tc-MDP bone scintigraphy) imaging methods. Classically, fibrous dysplasia lesions are intramedullary, expansile, and well defined. Although

endosteal scalloping may be present, a smooth cortical contour is always maintained. CT and MRI are useful for evaluating the soft-tissue components and the entire extent of a lesion. The MRI characteristics of fibrous dysplasia are variable, typically showing the signal intensity that is intermediate to low on T1-weighted images, intermediate to high on T2-weighted images, and heterogeneous enhancement after administration of gadolinium.^[7]

Recent studies have assessed the use of ⁶⁸Ga-PSMA PET/CT for the diagnosis of PCa metastasis,^[8] and according to the data presented at the 2018 American Society of Clinical Oncology annual meeting, imaging with ⁶⁸Ga-PSMA PET/CT is highly accurate in localizing recurrent PCa.^[9] PSMA is a type II membrane glycoprotein with intracellular, transmembrane, and extracellular segments. This glycoprotein is expressed on the cell surface, with significantly increased expression in PCa cells,^[10]

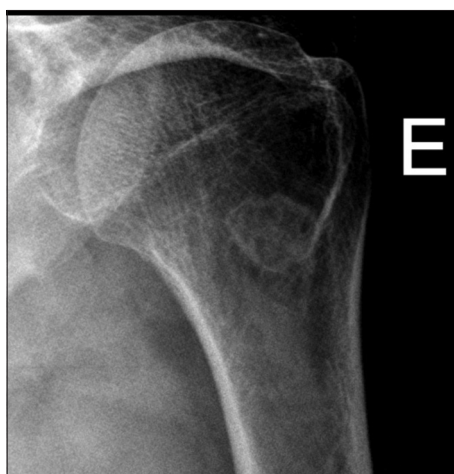


Figure 4: Anteroposterior radiograph showing a radiolucent lesion with a narrow sclerotic halo located inferiorly to the lesser tubercle of the left humerus

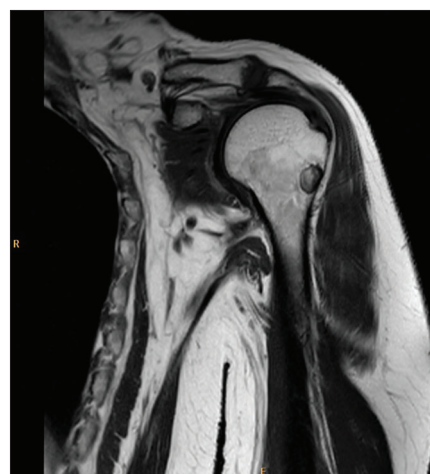


Figure 5: Coronal magnetic resonance imaging showing a bone lesion in the proximal metaphysis of the left humerus, with hyperintensity on T1 sequences (arrow)

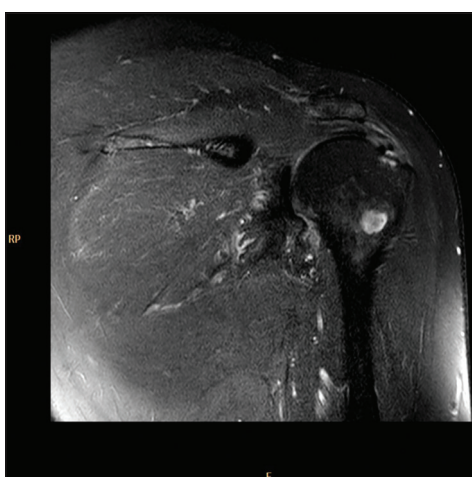


Figure 6: Coronal magnetic resonance imaging showing a bone lesion in the proximal metaphysis of the left humerus, with hyperintensity on T2 sequences (arrow)

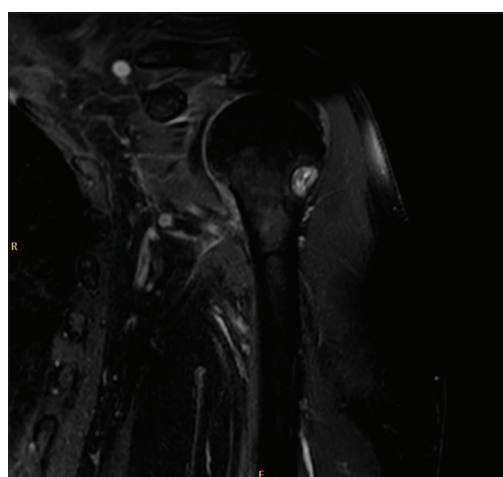


Figure 7: Coronal magnetic resonance imaging showing a bone lesion in the proximal metaphysis of the left humerus, with heterogeneous enhancement after contrast medium administration (arrow)

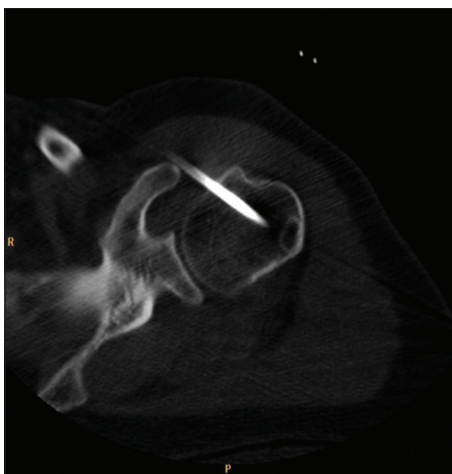


Figure 8: Axial computed tomography-guided biopsy of the sclerotic lesion in the proximal metaphysis of the left humerus. A large-core needle (8 G x 15 cm; Jamshidi) was used

and despite its name, PSMA is not specific to prostate tissue. False-positive radiotracer uptake in benign bone processes may relate to bone remodeling and increased vascularity like in sarcomatous transformation of fibrous dysplasia.^[4]

The present case demonstrates that although ⁶⁸Ga-PSMA PET/CT may accurately detect PCa bone metastases, it may also present false-positive results, especially when uncommon sites are involved. Thus, physicians should be aware of that during patient restaging to decide the best treatment option and avoid unnecessary procedures.

CONCLUSION

⁶⁸Ga-PSMA PET/CT imaging has become an important tool in restaging patients with PCa. It has been increasingly used in clinical practice, reinforcing the need to understand its potential benefits and limitations. Despite its high sensitivity and specificity, this method may produce false-positive findings, as indicated by previous reports. Therefore, diagnostic issues related to this imaging modality should be disseminated to help physicians make appropriate treatment choices for each patient.

Declaration of patient consent

The authors certify that they have obtained all appropriate patient consent forms. In the form the patient(s) has/have

given his/her/their consent for his/her/their images and other clinical information to be reported in the journal. The patients understand that their names and initials will not be published and due efforts will be made to conceal their identity, but anonymity cannot be guaranteed.

Financial support and sponsorship

Nil.

Conflicts of interest

There are no conflicts of interest.

REFERENCES

1. Dy GW, Gore JL, Forouzanfar MH, Naghavi M, Fitzmaurice C. Global burden of urologic cancers, 1990-2013. *Eur Urol* 2017;71:437-46.
2. Dodds PR, Caride VJ, Lytton B. The role of vertebral veins in the dissemination of prostatic carcinoma. *J Urol* 1981;126:753-5.
3. Perera M, Papa N, Christidis D, Wetherell D, Hofman MS, Murphy DG, *et al.* Sensitivity, specificity, and predictors of positive ⁶⁸Ga-prostate-specific membrane antigen positron emission tomography in advanced prostate cancer: A systematic review and meta-analysis. *Eur Urol* 2016;70:926-37.
4. Sheikhabaei S, Afshar-Oromieh A, Eiber M, Solnes LB, Javadi MS, Ross AE, *et al.* Pearls and pitfalls in clinical interpretation of prostate-specific membrane antigen (PSMA)-targeted PET imaging. *Eur J Nucl Med Mol Imaging* 2017;44:2117-36.
5. De Coster L, Sciot R, Everaerts W, Gheysens O, Verscuren R, Deroose CM, *et al.* Fibrous dysplasia mimicking bone metastasis on ⁶⁸Ga-PSMA PET/MRI. *Eur J Nucl Med Mol Imaging* 2017;44:1607-8.
6. Rowe SP, Macura KJ, Ciarallo A, Mena E, Blackford A, Nadal R, *et al.* Comparison of prostate-specific membrane antigen-based 18F-DCFBC PET/CT to conventional imaging modalities for detection of hormone-naïve and castration-resistant metastatic prostate cancer. *J Nucl Med* 2016;57:46-53.
7. Fitzpatrick KA, Taljanovic MS, Speer DP, Graham AR, Jacobson JA, Barnes GR, *et al.* Imaging findings of fibrous dysplasia with histopathologic and intraoperative correlation. *AJR Am J Roentgenol* 2004;182:1389-98.
8. Gorin MA, Rowe SP, Denmeade SR. Clinical applications of molecular imaging in the management of prostate cancer. *PET Clin* 2017;12:185-92.
9. Fendler W, Calais J, Gartmann J, Nickols NG, Reiter RE, Rettig M, *et al.* Accuracy of ⁶⁸Ga-PSMA11 PET/CT on recurrent prostate cancer: Preliminary results from a phase 2/3 prospective trial. *J Clin Oncol* 2018;36:5001.
10. Rai BP, Baum RP, Patel A, Hughes R, Alonzi R, Lane T, *et al.* The role PET with (⁶⁸) gallium (Ga)-labelled prostate-specific membrane antigen (PSMA) in the management of patient with organ confined and locally advanced prostate cancer prior to radical treatment and after radical prostatectomy. *Urology* 2016;95:11-5.