

# Functional Outcome of Pronation-External Rotation-Weber C Ankle Fractures with Supracollicular Medial Malleolar Fracture Treated with or without Syndesmotic Screws: A Retrospective Comparative Cohort Study

Yong Wu<sup>1,2</sup>, Qi-Fei He<sup>2</sup>, Liang-Peng Lai<sup>2</sup>, Xia Li<sup>3</sup>, Jun-Lin Zhou<sup>1</sup>

<sup>1</sup>Department of Orthopaedics, Chaoyang Hospital, Third Clinical Medical School of Capital Medical University, Beijing 100020, China

<sup>2</sup>Department of Trauma Orthopaedics, Jishuitan Hospital, Forth Clinical Medical School of Peking University, Beijing 100035, China

<sup>3</sup>Department of Epidemiology and Biostatistics, School of Public Health, Peking University Health Science Center, Beijing 100191, China

## Abstract

**Background:** In treatment of ankle fracture, intraoperative stress tests are used to assess the syndesmotic injury and instability. However, the optimized timing of the stress test should be applied whether in pre- or post-bony fixation during operation is seldom reported in previous studies. The different strategies on stress test timing would exhibit opposite results within a type of pronation-external rotation (PER) fractures with supracollicular medial malleolar (SMM) fractures. This study was designed to assess the 3-year functional outcomes of the special PER fractures with or without a syndesmotic transfixation based on the results of two different intraoperative stress test strategies.

**Methods:** This retrospective cohort study included 61 PER injury-Weber C ankle fractures combined with SMM fractures who were treated in Beijing Jishuitan Hospital between 2013 and 2014 and followed up for 3 years. Stress test was performed twice intraoperatively. A positive intraoperative stress test before bony fixation and a negative intraoperative stress test after bony fixation were found in these included patients. Twenty-nine patients (Group 1) were treated without a supplemental syndesmotic screw fixation, according to the negative intraoperative stress test after bony fixation, while 32 patients (Group 2) were treated with an additional syndesmotic screw fixation based on the positive intraoperative stress test before bony fixation. The American Orthopaedic Foot and Ankle Society (AOFAS) Ankle-Hindfoot Scale and Visual Analog Scale (VAS) for pain scores were the main measurements of outcome. The statistical index of demographic data, fracture morphologic data, time interval of follow-up, AOFAS and VAS were recorded and assessed by SPSS 21.0 software through Fisher exact tests and one-way analysis of variance. The associations between the main outcomes and influential factors were evaluated by linear regression models.

**Results:** We observed no difference in the distribution of age, sex, presence of associated posterior malleolus (PM), fracture dislocation, and fixation of associated PM between two treatment groups. With the numbers available, no statistically significant association could be detected with regard to the AOFAS (Group 1 vs. Group 2,  $96.72 \pm 6.20$  vs.  $94.63 \pm 8.26$ ,  $F = 1.24$ ,  $P = 0.27$ ) and VAS (Group 1 vs. Group 2,  $1.47 \pm 2.14$  vs.  $0.72 \pm 1.49$ ,  $F = 2.44$ ,  $P = 0.12$ ) in association with two strategies.

**Conclusions:** The present study indicates no difference to the use of the syndesmotic screw in terms of the functional outcome between syndesmosis transfixation and no-fixation patients among PER-Weber C ankle fracture patients with SMM fracture after 3-year follow-up. More attention should be paid to pre- and post-bony-fixation intraoperative stress tests and the morphology of medial malleoli fractures in ankle fractures.

**Key words:** Ankle Fracture; Ankle Injuries; Ankle Joint; Pronation-External Rotation Fracture; Stress Test

## INTRODUCTION

Ankle fractures are one of the most common injuries treated operatively by orthopedic surgeons.<sup>[1,2]</sup> Pronation-external rotation (PER) injuries or Weber C type fractures, especially PER-4 fractures, are unstable ankle fractures that are associated with the incidence of a complete rupture of the syndesmosis at the distal tibiofibular joint.<sup>[3-5]</sup> It is

**Address for correspondence:** Dr. Jun-Lin Zhou,  
Department of Orthopaedics, Chaoyang Hospital, Third Clinical  
Medical School of Capital Medical University, Beijing 100020, China  
E-Mail: drjunlinzhou@126.com

This is an open access journal, and articles are distributed under the terms of the Creative Commons Attribution-NonCommercial-ShareAlike 4.0 License, which allows others to remix, tweak, and build upon the work non-commercially, as long as appropriate credit is given and the new creations are licensed under the identical terms.

**For reprints contact:** reprints@medknow.com

© 2018 Chinese Medical Journal | Produced by Wolters Kluwer - Medknow

**Received:** 31-07-2018 **Edited by:** Peng Lyu  
**How to cite this article:** Wu Y, He QF, Lai LP, Li X, Zhou JL. Functional Outcome of Pronation-External Rotation-Weber C Ankle Fractures with Supracollicular Medial Malleolar Fracture Treated with or without Syndesmotic Screws: A Retrospective Comparative Cohort Study. Chin Med J 2018;131:2551-7.

### Access this article online

#### Quick Response Code:



**Website:**  
www.cmj.org

**DOI:**  
10.4103/0366-6999.244112

generally agreed that these injuries benefit from obtaining and maintaining an anatomically stable fixation, including the syndesmotom fixation.<sup>[6]</sup>

Using metal trans-syndesmosis screw was the most popular and mainstream approach to restore syndesmotom stability, although there is a lot of published information about malreduction of the syndesmotom screw and alternatives to syndesmotom screw fixation.<sup>[7-13]</sup> Intraoperative stress testing is recommended for diagnosing syndesmotom disruption or instability. There are two intraoperative strategies commonly used in clinical practice. One way is to perform stress test before bony fixation in order to confirm the syndesmotom injury and disruption,<sup>[14]</sup> while another way is to conduct stress test after bony fixation to assess syndesmotom instability.<sup>[15,16]</sup> However, there is a lack of evidence on the comparison between these two strategies despite the abundance of research concerning the treatment of ankle fractures and isolated syndesmotom injuries. In most situations, the operative procedures indicated by the test results of these two strategies would not conflict with each other, since syndesmotom instability tends to come along with syndesmotom disruption. However, with regard to some certain types of ankle fracture, such as the ankle fracture with both a complete syndesmotom injury and a supracollicular medial malleolar (SMM) fracture,<sup>[17]</sup> the result of these two intraoperative stress test strategies could lead to very opposite clinical decisions. As an SMM fracture likely comes with a complete deltoid ligament, the reduction and fixation of SMM fractures can restore the competence of the medial osteoligament.<sup>[18]</sup> However, the external rotation test is widely recognized as a clinical tool for the diagnosis of syndesmotom instability with deltoid ligament incompetence.<sup>[19]</sup> Therefore, the external rotation stress test after bony fixation could be negative when the lateral fibular and SMM fractures are reduced and fixed in PER-Weber C fractures. However, according to Lauge-Hansen classification,<sup>[3,4]</sup> PER-Weber C fractures always combine with syndesmotom disruption, thus presenting a positive result when testing before bony fixation.

As noted above, this study was designed to assess the 3-year functional outcomes of the special PER fractures with SMM fractures treated with or without a syndesmotom transfixation according to the results of two different intraoperative stress test strategies. We hypothesized that the negative postbony-fixation stress test might be a more reliable indication than the positive prebony-fixation stress test of the choice of syndesmotom fixation of PER fracture with SMM fracture and that PER ankle fractures with SMM treated with or without syndesmotom screw fixation could achieve a similar outcome.

## METHODS

### Ethical approval

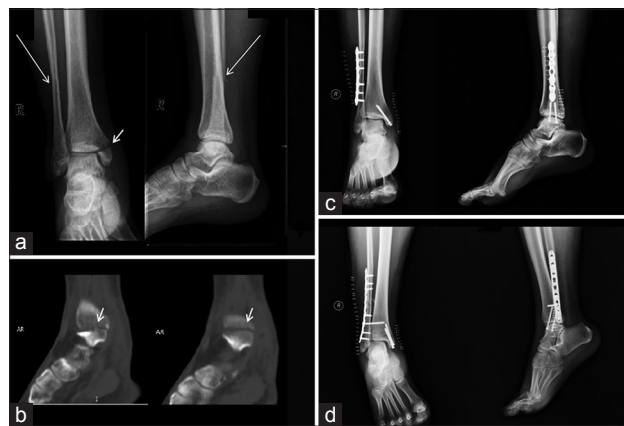The study was conducted in accordance with the *Declaration of Helsinki* and was approved by the Ethics Committee of

Beijing Jishuitan Hospital (No. 201611-07). Informed written consent was obtained from all patients or their guardians for the children before their enrollment in this study.

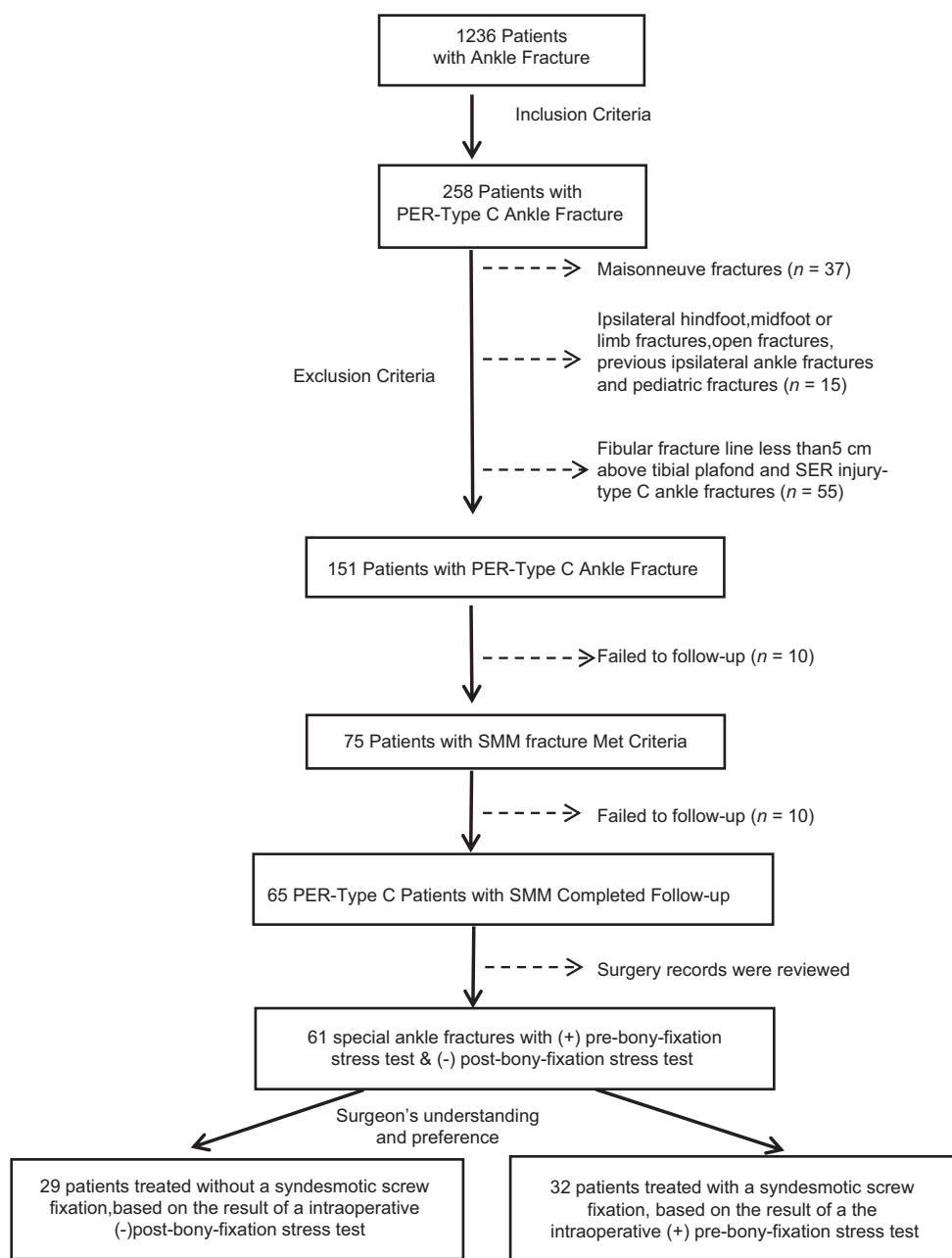
### Study population

We retrospectively reviewed a database of 1236 patients admitted to the hospital for ankle fractures from January 1, 2013, to December 31, 2014. All patients had standard three-view series injury radiographs (mortise, anteroposterior [AP], and lateral) and a preoperative computed tomography scan. The inclusion criterion included PER-Weber type C ankle fracture with a SMM fracture [Figure 1]. Moreover, only those with the oblique or spiral fibular fracture line more than 5 cm above the tibial plafond were included because the interosseous tibiofibular ligament was 49.4 mm (45.4–53.3 mm) proximal to the center of the plafond to the tibia.<sup>[20]</sup> The exclusion criteria included (i) Maisonneuve fractures;<sup>[21]</sup> (ii) fractures that were associated with ipsilateral hindfoot, midfoot, or limb fractures; (iii) open fractures; (iv) previous ipsilateral ankle injuries and deformities; (v) pediatric fractures (when <14 years of age).

To be included in our analysis, 71 patients met the selection criterion. Sixty-one patients among them completed the 3-year follow-up. The surgery records of each patient, especially the timing and order of stress test, were reviewed carefully, so as to validate their intraoperative stress test strategies, before or after bony fixation. These patients were recorded with a positive prebony-fixation stress test and a negative postbony-fixation stress test. The 61 patients were divided into two groups, namely with or without syndesmotom screw fixation [Figure 1]. Twenty-nine patients were treated without a supplemental syndesmotom screw fixation, according to the negative intraoperative stress test after bony fixation, while 32 patients were treated with an additional syndesmotom screw fixation based on the positive intraoperative stress test before bony fixation [Figure 2].



**Figure 1:** Inclusion criteria of the patients in the study. (a) Postoperative X-ray showed an SMM (arrowhead) and an oblique fibular fracture (arrows) that was higher than 5 cm above the tibial plafond. (b) Postoperative computed tomography showed a SMM fracture (arrowheads). Postoperative X-ray without (c) and with (d) syndesmotom screw fixation. SMM: Supracollicular medial malleolar.



**Figure 2:** Flowchart of the inclusion and exclusion criteria. PER: Pronation-external rotation; SER: Supination-external rotation; SMM: Supracollicular medial malleolar.

### Operative procedure

All patients underwent an anatomical fixation strategy performed by a senior member of the staff, which included open reduction internal fixation of lateral, medial, and posterior malleolus (PM) fractures. After lateral and medial bony fixation, the stability of the ankle was checked by intraoperative stress test, used as an external rotation or (and) a hook/cotton test, under fluoroscopy. In our routine, twice stress tests were performed, intraoperatively. The prebony-fixation stress test was performed just after the anesthesia was performed to confirm the concealed syndesmotic injury. Moreover, a postbony-fixation stress test was performed again when lateral and medial instability had been addressed before syndesmotic screw was inserted.

We defined disruption or instability of syndesmosis as the following: intraoperative AP radiograph that demonstrates a clear space of more than 6 mm between the medial wall of the fibula and the lateral wall of the posterior tibial malleolus, or distal tibiofibular overlapping of <5 mm measured 1 cm proximal of the tibial plafond, or a difference of more than 2 mm side-to-side in the tibiotalar or tibiofibular clear spaces on mortise radiographs.<sup>[22]</sup> As previously mentioned, in these PER injuries with SMM fractures, positive prebony-fixation stress test and negative postbony-fixation stress test were observed. However, the decision to use a syndesmotic screw was up to the judgment of surgeons and preference for which of the twice stress tests should be relied on. For syndesmotic screw stabilization, a regular 3.5-mm cortical

screw was inserted placed 2 cm proximal to the ankle affords across three cortices with the ankle in 20° of dorsiflexion after the syndesmosis was reduced and maintained with a clamp. After surgery, radiographs (mortise, AP, and lateral) were routinely performed, and the quality of fracture reduction and alignment were assessed by a senior surgeon in the following ward rounds. Baseline characteristics of the patients showed no significant difference in any parameter [Table 1].

All patients had similar postoperative treatment protocols. All patients were treated with a below-knee cast for 2 weeks after surgery. Gradual passive and initiative movements of the lower extremities were instructed from 2 weeks postoperatively. The syndesmotic screw was removed at a mean of 3 months after surgery before weight-bearing. The patients in the nonscrew fixation group commenced gradual weight-bearing earlier at 6 weeks postoperatively and advanced as tolerated.

### Patient follow-up

All patients had an average of 6-month routine radiographic follow-up after surgery. At 6-month follow-up, the mortise view, the AP, and lateral ankle joint radiographs were performed. Weber's three indexes were used to evaluate reduction of the ankle joint and syndesmosis in the mortise view: (1) trilateral intervals of the ankle joint should be equal and parallel, (2) the medial spike of the fibula should indicate the level of the tibial subchondral bone (no irregular Shenton's line), and (3) the contour of the lateral part of the articular surface of the talus continues as an unbroken curve to the recess in the distal fibula (Coin sign).<sup>[23,24]</sup> The American Orthopaedic Foot and Ankle Society (AOFAS) Ankle-Hindfoot Score and Visual Analog Scale (VAS) score were used for functional and pain evaluation at the final follow-up of a mean of 3 years.

### Statistical analysis

Statistical analyses were performed with SPSS 21.0 (SPSS Inc., Chicago, IL, USA). The distributions between the two groups were analyzed with respect to potential confounding factors, including age, gender, presence of PM fracture, fixation of malleolus fracture, fracture dislocation, and time interval of follow-up. Data were analyzed and reported using percentages for categorical variables and means (standard deviations [SD]) for continuous variables. Fisher's exact tests and one-way analysis of variance (ANOVA) were used to test between-group comparisons for categorical and continuous variables, respectively. The associations between the outcomes and influential factors were evaluated by linear regression models (continuous variables) or logistic regression models (categorical variables). Univariate models were applied because of the relatively balanced distributions of other potential prognostic factors between groups of interest. All *P* values were two-sided, and statistical significance was defined as *P* < 0.05.

### RESULTS

In total, 61 patients were included [Table 1]. There were 29 patients in Group 1 (no syndesmotic screw fixation) with a mean age of 35.9 ± 12.6 (range, 15–59) years and 32 patients in Group 2 (syndesmotic screw fixation) with a mean age of 37.3 ± 13.3 (range, 17–68) years. Group 1 consisted of 11 women and 18 men (mean follow-up: 37.8 ± 6.2 [range, 30–50] months), while Group 2 consisted of 15 women and 17 men (mean follow-up: 38.3 ± 6.5 [range, 30–53] months). There were 21 cases associated with PM fractures in Group 1, 10 of which were fixed, and 26 in Group 2, 13 of which were fixed. The difference of PM fragment (*P* = 0.412) and PM fixation (*P* = 0.621) was not statistically significant between the two groups. The dislocation of the tibiotalar joint also did not differ between the groups. There were

**Table 1: Baseline characteristics of the patients with PER injury-Weber C ankle fractures combined with SMM fractures**

Parameters	Without syndesmotic screw ( <i>n</i> = 29)	With syndesmotic screw ( <i>n</i> = 32)	Statistics	<i>P</i>
Age (years)	35.9 ± 12.6	37.3 ± 13.3	0.17*	0.68
Sex			1.41†	0.23
Female	11 (37.93)	15 (46.88)		
Male	18 (62.07)	17 (53.12)		
Mechanism			1.22†	0.27
Low energy	15 (51.72)	21 (65.62)		
High energy	14 (48.28)	11 (34.38)		
Fibular fracture height (mm)	74.56 (19.29)	79.17 (24.51)	0.65†	0.42
Posterior malleolus fracture	21 (72.41)	26 (81.25)	0.67†	0.41
Dislocation			2.17†	0.34
No dislocation	23 (79.31)	20 (62.50)		
Subluxation	2 (6.90)	5 (15.62)		
Complete dislocation	4 (13.79)	7 (21.88)		
Posterior malleolar fixation	10 (34.48)	13 (59.38)	0.24†	0.62
Follow-up time (months)	37.76 ± 6.16	38.34 ± 6.44	0.16*	0.69
Remove implant	18 (62.07)	20 (62.50)	<0.01†	0.97

Values are presented as mean ± SD and *n* (%). \**F* value; † $\chi^2$  value; SD: Standard deviation; ANOVA: Analysis of variance; PER: Pronation-external rotation; SMM: Supracollicular medial malleolar.

38 patients whose hardware was removed during follow-up (Group 1 vs. Group 2, 18 vs. 20,  $F < 0.01$ ;  $P = 0.97$ ). No significant difference was detected in follow-ups between two groups [Table 1].

None of the patients developed an infection postoperatively. There were no obvious malreductions of syndesmosis found using Weber's three indices in the mortise view, 6 months after surgery. Moreover, there were no patients undergoing reoperation as results of complications, such as syndesmoti diastasis or malreduction. The average AOFAS scores after 3 years in both groups were satisfactory (Group 1 vs. Group 2,  $96.72 \pm 6.20$  vs.  $94.63 \pm 8.26$ ,  $F = 1.24$ ;  $P = 0.27$ ), although the value was higher in Group 1. Compared to patients with syndesmoti screw, patients without syndesmoti screw had an increased likelihood and trend of better functional outcomes, with a 2.10-point higher and a 0.74-point lower score in AOFAS and VAS, respectively. In addition, lower risks of pain were found in patients without syndesmoti screws, while a slightly higher swelling risk was found. However, the differences were not statistically significant [Table 2].

## DISCUSSION

This study compared the functional outcomes of two different strategies for evaluating and addressing syndesmoti injury or instability. The results of this study indicated no significant difference in AOFAS and VAS scale 3 years after surgery in the PER fractures with SMM fractures with or without syndesmoti screw which presented the two different strategies of the intraoperative stress test. The outcomes concur with the earlier evidence regarding syndesmoti screw fixation. Kennedy *et al.*<sup>[25]</sup> also reported no difference in functional outcome between patients with or without a syndesmoti screw in low Weber C-type ankle fractures (<5 cm from the tibial plafond) with associated syndesmosis injury. In a randomized prospective controlled trial, Kortekangas *et al.*<sup>[26]</sup> and Pakarinen *et al.*<sup>[27]</sup> observed no difference in clinical outcome between syndesmoti fixation or not within patients with supination-external rotation type IV ankle fractures with confirmed syndesmoti injury, after 1-year and 4-year follow-up respectively. As such, syndesmoti fixation was not necessary for distal PER ankle fractures if rigid bimalleolar fracture fixation is achieved.

However, none of these previous studies distinguished the different types of medial malleolar fractures.<sup>[25-27]</sup> It is possible that other types of medial malleolar fractures except for SMM are combined with deltoid ligament injury.<sup>[17]</sup> A cadaveric study found that the application of an external rotation force resulted in consistent increase only in the medial clear space and that this increase was also seen in deltoid ligament sectioning, even when the syndesmosis was undamaged.<sup>[6]</sup> Previously, Boden *et al.*<sup>[28]</sup> in their classical cadaveric study found that the syndesmosis was stable after the fixation of a medial and lateral malleolar fracture. However, the medial malleolar fracture models in Boden's cadaveric study only simulated the supracollicular medial fractures. Therefore, more attention should be paid to the pattern of medial malleolar fractures, considering that medial malleolar fractures would affect the results of the external stress test and the choice of placing the syndesmoti screw. For example, simple fixation in treatment of medial malleolar fractures associated with deltoid ligament injury, such as the anterior colliculus fracture associated with a ruptured deep deltoid ligament, may not be adequate and may also need a syndesmoti fixation.

In the present study, all patients were found a positive stress test before bony fixation, in accordance with the findings of Song *et al.*<sup>[29]</sup> They found a 100% sensitivity (14/14) of external rotation test before bony fixation to detect concealed disruption of syndesmosis in PER-4 fracture. After bony fixation, all patients in the present study were found a negative stress test, which may be due to only patients with both a SMM fracture and a potential complete deltoid ligament being included in the study. This finding is in line with previous studies. Pakarinen *et al.*<sup>[15]</sup> found a low sensitivity and a high specificity of both external rotation test and hook test after bony fixation, with a higher specificity of hook test, using the standardized 7.5-Nm external rotation stress test as reference. Thus, the stress tests after bony fixation have a high possibility to present a negative result. To our knowledge, this is a rare study to report the distinction of stress test before and after bony fixation and follow up the functional outcome of the special PER fracture with a positive prebony-fixation stress test and a negative postbony-fixation stress test. Although the results of this study indicated that a negative postbony-fixation stress test may be a better indication of

**Table 2: Associations between the outcomes and syndesmoti screw in patients with PER injury-Weber C ankle fractures combined with SMM fractures**

Items	With syndesmoti screw (n = 32)	Without syndesmoti screw (n = 29)	F	P
Distribution				
AOFAS	94.63 ± 8.26	96.72 ± 6.20	1.24	0.27
VAS	1.47 ± 2.14	0.72 ± 1.49	2.44	0.12
Regression analysis*				
AOFAS	0	2.10 (-1.67, 5.87)*	–	0.27
VAS	0	-0.74 (-1.70, 0.21)*	–	0.12

Values are presented as mean ± SD. \*Values are represented as  $\beta$  (95% CI) and determined using linear regression. –: No data; SD: Standard deviation; CI: Confidence interval; AOFAS: American Orthopaedic Foot and Ankle Society; VAS: Visual Analog Scale; PER: Pronation-external rotation; SMM: Supracollicular medial malleolar.

syndesmotic fixation than a positive prebony-fixation stress test, more studies will be warranted to assess the sensitivity, specificity, and reliability of pre- and post-bony-fixation stress test in other types of ankle fracture. Moreover, a distinction should be made between syndesmotic disruption and real syndesmotic instability. Intraoperative arthroscopic anatomical examination<sup>[29]</sup> and stress test<sup>[14]</sup> before bony fixation are used to diagnose a syndesmotic disruption, while intraoperative stress test after bony fixation could be used to assess syndesmotic instability.<sup>[15]</sup> Different methods of stress test should be applied based on their characteristics and the surgical objective. For example, Pakarinen *et al.*<sup>[15]</sup> observed postbony-fixation stress tests may be limited as a predictor of syndesmotic instability ankle fractures because of a low sensitivity. However, postbony-fixation tests, especially hook test, exhibited high specificity and therefore might have an advantage of avoiding inserting unnecessary syndesmotic screw.

There are several limitations to the present study. First, this study is limited by a small sample size. A small number of patients increase the possibility of type II error in some functional scores. However, PER injury-Weber C ankle fractures are rare, especially for those with SMM fractures and fibular fractures higher than 5 cm above the tibial plafond. Furthermore, some potential confounding factors were excluded by strict criterion. The sample size in this study was one of the largest studies in comparison to previous similar studies.<sup>[25-27]</sup> The present study had an ample power (0.80) to detect a 2.40 difference of AOFAS score in participants without the syndesmotic screw compared to those with a syndesmotic screw. Even though the observed risk reduction was insignificant, it is too small to make a difference from the clinical perspective. Second, as a retrospective cohort study, some data were not recorded, such as malreduction and complications rates of syndesmotic screw, postoperative satisfaction, ankle joint activity, postoperative gait, and bone union rate and timing, which restricted us to further analyze the prognosis outcomes comprehensively. More perspective research is required to assess this problem. Third, because the timing of stress test and the usage of syndesmotic screw in our circumstances were decided by distinct surgeons, there was a possibility of surgeon bias. There were dozens of surgeons in our center who operated on the patients in our cohort, making it hard to control these possible confounding factors during operation. However, all postoperative radiographs were routinely performed and the quality of surgery assessed by a senior surgeon at the next postoperative round, which ensured the surgery quality in the study, controlling the surgeon bias to a certain extent.

Despite these limitations, this study distinguished itself from previous studies as it analyzed the PER fractures associated with both the SMM fracture and higher than 5-cm fibular fracture treated either with or without the use of a syndesmotic screw. Particularly, within these patients, the two different intraoperative stress test strategies, before or after bony fixation, would exhibit opposite results. Second,

this is a very rare study to compare the outcome of the two different diagnosis and treatment strategies for syndesmotic fixation using a follow-up information of SMM fracture patients.

In conclusion, the results of the present study indicate that there is no advantage to the use of the syndesmotic screw in terms of the functional outcome after stable fixation of the lateral and supracollicular medial malleoli in PER injury fractures. A negative postbony-fixation stress test might be a more reliable indication than a positive prebony-fixation stress test with regard to the procedure of syndesmotic fixation of PER fracture with SMM fracture. More attention should be paid to pre- and post-bony-fixation intraoperative stress tests and morphology of medial malleoli fractures in ankle fractures.

### Financial support and sponsorship

This study was supported by a grant from the Capital Characteristic Foundation of China (No. Z171100001017100).

### Conflicts of interest

There are no conflicts of interest.

### REFERENCES

1. Daly PJ, Fitzgerald RH Jr., Melton LJ, Ilstrup DM. Epidemiology of ankle fractures in Rochester, Minnesota. *Acta Orthop Scand* 1987;58:539-44. doi: 10.3109/17453678709146395.
2. Jensen SL, Andresen BK, Mencke S, Nielsen PT. Epidemiology of ankle fractures. A prospective population-based study of 212 cases in Aalborg, Denmark. *Acta Orthop Scand* 1998;69:48-50. doi: 10.3109/17453679809002356.
3. Lauge-Hansen N. Fractures of the ankle. II. Combined experimental-surgical and experimental-roentgenologic investigations. *Arch Surg* 1950;60:957-85. doi: 10.1001/archsurg.1950.01250010980011.
4. Lauge-Hansen N. Fractures of the ankle. IV. Clinical use of genetic roentgen diagnosis and genetic reduction. *AMA Arch Surg* 1952;64:488-500. doi: 10.1001/archsurg.1952.01260010504008.
5. Pettrone FA, Gail M, Pee D, Fitzpatrick T, Van Herpe LB. Quantitative criteria for prediction of the results after displaced fracture of the ankle. *J Bone Joint Surg Am* 1983;65:667-77. doi: 10.2106/00004623-198365050-00013.
6. Stoffel K, Wysocki D, Baddour E, Nicholls R, Yates P. Comparison of two intraoperative assessment methods for injuries to the ankle syndesmosis. A cadaveric study. *J Bone Joint Surg Am* 2009;91:2646-52. doi: 10.2106/JBJS.G.01537.
7. Franke J, von Recum J, Suda AJ, Grützner PA, Wendl K. Intraoperative three-dimensional imaging in the treatment of acute unstable syndesmotic injuries. *J Bone Joint Surg Am* 2012;94:1386-90. doi: 10.2106/JBJS.K.01122.
8. Mont MA, Sedlin ED, Weiner LS, Miller AR. Postoperative radiographs as predictors of clinical outcome in unstable ankle fractures. *J Orthop Trauma* 1992;6:352-7. doi: 10.1097/00005131-199209000-00014.
9. Sagi HC, Shah AR, Sanders RW. The functional consequence of syndesmotic joint malreduction at a minimum 2-year follow-up. *J Orthop Trauma* 2012;26:439-43. doi: 10.1097/BOT.0b013e31822a526a.
10. Weening B, Bhandari M. Predictors of functional outcome following transsyndesmotic screw fixation of ankle fractures. *J Orthop Trauma* 2005;19:102-8. doi: 10.1097/00005131-200502000-00006.
11. Gardner MJ, Brodsky A, Briggs SM, Nielson JH, Lorich DG. Fixation of posterior malleolar fractures provides greater syndesmotic stability. *Clin Orthop Relat Res* 2006;447:165-71. doi: 10.1177/107110070602701005.
12. Jones CR, Nunley JA 2<sup>nd</sup>. Deltoid ligament repair versus syndesmotic fixation in bimalleolar equivalent ankle fractures. *J Orthop Trauma* 2015;29:245-9. doi: 10.1097/BOT.0000000000000220.

13. Zhan Y, Yan X, Xia R, Cheng T, Luo C. Anterior-inferior tibiofibular ligament anatomical repair and augmentation versus trans-syndesmosis screw fixation for the syndesmotic instability in external-rotation type ankle fracture with posterior malleolus involvement: A prospective and comparative study. *Injury* 2016;47:1574-80. doi: 10.1016/j.injury.2016.04.014.
14. Song KS, Kim SG, Lim YJ, Jeon JH, Min KK. False negative rate of syndesmotic injury in pronation-external rotation stage IV ankle fractures. *Indian J Orthop* 2013;47:482-6. doi: 10.4103/0019-5413.118204.
15. Pakarinen H, Flinkkilä T, Ohtonen P, Hyvönen P, Lakovaara M, Leppilahti J, *et al.* Intraoperative assessment of the stability of the distal tibiofibular joint in supination-external rotation injuries of the ankle: Sensitivity, specificity, and reliability of two clinical tests. *J Bone Joint Surg Am* 2011;93:2057-61. doi: 10.2106/JBJS.J.01287.
16. van den Bekerom MP, Haverkamp D, Kerkhoffs GM, van Dijk CN. Syndesmotic stabilization in pronation external rotation ankle fractures. *Clin Orthop Relat Res* 2010;468:991-5. doi: 10.1007/s11999-009-0823-9.
17. Pankovich AM, Shivaram MS. Anatomical basis of variability in injuries of the medial malleolus and the deltoid ligament. I. Anatomical studies. *Acta Orthop Scand* 1979;50:217-23. doi: 10.3109/17453677908989759.
18. Tornetta P 3<sup>rd</sup>. Competence of the deltoid ligament in bimalleolar ankle fractures after medial malleolar fixation. *J Bone Joint Surg Am* 2000;82:843-8. doi: 10.2106/00004623-200006000-00011.
19. van den Bekerom MP, Mutsaerts EL, van Dijk CN. Evaluation of the integrity of the deltoid ligament in supination external rotation ankle fractures: A systematic review of the literature. *Arch Orthop Trauma Surg* 2009;129:227-35. doi: 10.1007/s00402-008-0768-6.
20. Williams BT, Ahrberg AB, Goldsmith MT, Campbell KJ, Shirley L, Wijdicks CA, *et al.* Ankle syndesmosis: A qualitative and quantitative anatomic analysis. *Am J Sports Med* 2015;43:88-97. doi: 10.1177/0363546514554911.
21. Pankovich AM. Maisonneuve fracture of the fibula. *J Bone Joint Surg Am* 1976;58:337-42. doi: 10.2106/00004623-197658030-00007.
22. Timothy OW, Kate EB. Ankle fractures. In: Charles MC, James DH, editors. *Rockwood and Green's Fractures in Adults*. 8<sup>th</sup> ed. Philadelphia: Lippincott Williams and Wilkins; 2015. p. 2567-69.
23. Futamura K, Baba T, Mogami A, Morohashi I, Kanda A, Obayashi O, *et al.* Malreduction of syndesmosis injury associated with malleolar ankle fracture can be avoided using Weber's three indexes in the mortise view. *Injury* 2017;48:954-9. doi: 10.1016/j.injury.2017.02.004.
24. Weber BG, Simpson LA. Corrective lengthening osteotomy of the fibula. *Clin Orthop Relat Res* 1985;199:61-7. doi: 10.1097/00003086-198510000-00009.
25. Kennedy JG, Soffe KE, Dalla Vedova P, Stephens MM, O'Brien T, Walsh MG, *et al.* Evaluation of the syndesmotic screw in low weber C ankle fractures. *J Orthop Trauma* 2000;14:359-66. doi: 10.1097/0005131-200006000-00010.
26. Kortekangas T, Savola O, Flinkkilä T, Lepojärvi S, Nortunen S, Ohtonen P, *et al.* A prospective randomised study comparing TightRope and syndesmotic screw fixation for accuracy and maintenance of syndesmotic reduction assessed with bilateral computed tomography. *Injury* 2015;46:1119-26. doi: 10.1177/1071100714540894.
27. Pakarinen HJ, Flinkkilä TE, Ohtonen PP, Hyvönen PH, Lakovaara MT, Leppilahti JI, *et al.* Syndesmotic fixation in supination-external rotation ankle fractures: A prospective randomized study. *Foot Ankle Int* 2011;32:1103-9. doi: 10.3113/FAI.2011.1103.
28. Boden SD, Labropoulos PA, McCowin P, Lestini WF, Hurwitz SR. Mechanical considerations for the syndesmosis screw. A cadaver study. *J Bone Joint Surg Am* 1989;71:1548-55. doi: 10.2106/00004623-198971100-00014.
29. Takao M, Ochi M, Naito K, Iwata A, Kawasaki K, Tobita M, *et al.* Arthroscopic diagnosis of tibiofibular syndesmosis disruption. *Arthroscopy* 2001;17:836-43. doi: 10.1016/s0749-8063(01)90007-6.

# 对于内踝丘上骨折的PER-Weber C型踝关节骨折是否行下胫腓螺钉固定的预后分析：一个回顾性队列研究

## 摘要

**背景：**在踝关节骨折的治疗中，术中应力试验常常被用来检测下胫腓的损伤和不稳定，然而对于是在骨折固定之前还是在骨折固定之后来进行应力试验，很少有相关临床研究的报道。对于合并有内踝丘上骨折（SMM）的旋前外旋型（PER）踝关节骨折，根据骨折固定前或者骨折固定后的应力试验结果可能做出相反的下胫腓螺钉固定的选择。本研究的目的是筛选在这种特殊类型的PER骨折，回顾性比较这两种不同的应力试验以及相应的下胫腓螺钉固定策略，对于3年预后的影响。

**方法：**本研究为一个回顾性队列研究，纳入并随访了61例2013/14年于北京积水潭医院手术的合并SMM的PER-Weber C型骨折患者，随访年限为3年。纳入标准包括内踝为丘上骨折，外踝骨折为高于胫骨穹窿上方5cm的斜行或者螺旋形骨折的腓骨骨折。对其术中骨折固定前后两次应力试验结果进行回顾，发现均表现为固定前为阳性，固定后为阴性。其中有29例（组1）按照骨折固定前的阳性结果给予了下胫腓螺钉固定，32例（组2）按照骨折固定后阴性的结果未给予下胫腓螺钉固定。随访按照这两种不同的诊疗策略治疗的61例患者术后3年的AOFAS足踝功能评分和VAS疼痛评分。

**结果：**这两组病人在年龄、性别、是否合并后踝骨折、合并骨折脱位以及是否对后踝进行固定等方面，分布均没有差异。在本研究的样本量下，也未在AOFAS评分（组1 vs. 组2,  $96.72 \pm 6.20$  vs.  $94.63 \pm 8.26$ ,  $F = 1.24$ ,  $P = 0.27$ ）和VAS评分（组1 vs. 组2,  $1.47 \pm 2.14$  vs.  $0.72 \pm 1.49$ ,  $F = 2.44$ ,  $P = 0.12$ ）方面观察到两种诊疗策略的差异。

**结论：**对于合并有SMM骨折的PER-Weber C型骨折患者，在内外踝坚强固定之后，胫腓螺钉固定并不能给患者带来额外获益，术中依照骨折固定后的阴性结果选择不置入螺钉可能更为合理。对于术中进行应力试验的时机以及踝关节内踝骨折的形态应给与更多的关注。