



Original Article

Use of malleoli as an indicator for flatfoot in patients with Down syndrome: development of a simple and non-invasive evaluation method through medial longitudinal arch

YOSHIHIDE KANAI, RPT, PhD^{1)*}, HIROTAKA MUTSUZAKI, MD, PhD²⁾,
MOMOKO WATANABE, RPTS³⁾, RYOKO TAKEUCHI, MD, PhD²⁾, YUKI MATAKI, MD²⁾,
YUSUKE ENDO, RPT, MS⁴⁾, ARITO YOZU, MD, PhD⁵⁾

¹⁾ School of Physical Therapy, Saitama Medical University: 981 Kawakado Moroyama-machi, Iruma-gun, Saitama 350-0496, Japan

²⁾ Department of Orthopaedic Surgery, Ibaraki Prefectural University of Health Sciences, Japan

³⁾ Department of Physical Therapy, Aiseikai Memorial Ibaraki Welfare Medical Center, Japan

⁴⁾ Department of Physical Therapy, Health Science University, Japan

⁵⁾ Department of Rehabilitation Medicine, Ibaraki Prefectural University of Health Sciences, Japan

Abstract. [Purpose] Flatfoot often presents in patients with Down syndrome, and it can be diagnosed using a simple radiograph. Consequently, due to radiograph limitations, alternative non-invasive testing must be determined. Conventionally, arch height ratio can be used for evaluation of the medial longitudinal arch, where the foot is evaluated by detecting the navicular bone on the foot surface. However, detection of the navicular tuberosity is difficult and even though the detection is relatively straightforward for patients without intellectual disability, measuring navicular bone is more difficult in patients with intellectual disability, such as those who have Down syndrome and are uncooperative with a tester. Therefore, we evaluated arch height ratio using the malleoli instead of the navicular bone to determine whether malleoli testing was appropriate for patients with Down syndrome that have an intellectual disability. [Participants and Methods] We conducted a retrospective study of 16 pairs of feet in 16 patients with Down syndrome, diagnosed with flatfoot. The height to the centre of the talo-navicular joint and that of the malleoli from the sole were measured on radiographs using weight-bearing conditions. [Results] The age range was 5.2 to 25.3 years. There was a correlation between the height of the navicular bone and that of the medial and lateral malleoli. [Conclusion] We conclude that the medial and lateral malleoli can substitute navicular bone as a landmark diagnosis test for flatfoot. Considering the close physical distance between the medial malleolus and navicular bone, and the association between the tibia and medial longitudinal arch, the medial malleolus may provide a better landmark in patients with Down syndrome with it being potentially less invasive for uncooperative patients.

Key words: Down syndrome, Flatfoot, Arch height ratio

(This article was submitted Dec. 9, 2019, and was accepted Feb. 6, 2020)

INTRODUCTION

Down syndrome (DS) is often characterized by orthopaedic diseases, including upper cervical spine instability, hip dislocation, and scoliosis^{1–3)}. A frequent orthopaedic complication of DS is flatfoot³⁾ and the prevalence of flatfoot is 60–88% in people with DS^{4, 5)}. Moreover, a significant relationship between flatfoot and general joint laxity has been shown⁶⁾; indeed,

*Corresponding author. Yoshihide Kanai (E-mail: kanai@saitama-med.ac.jp)

©2020 The Society of Physical Therapy Science. Published by IPEC Inc.



This is an open-access article distributed under the terms of the Creative Commons Attribution Non-Commercial No Derivatives (by-nc-nd) License. (CC-BY-NC-ND 4.0: <https://creativecommons.org/licenses/by-nc-nd/4.0/>)

many people with DS have been reported to have joint laxity^{7, 8}). Currently, flatfoot is diagnosed using a simple radiographic image. The angle between the base of the calcaneus and the sole is defined as the calcaneal pitch (CP) or the calcaneal inclination angle. In adults with flatfoot, the diagnosis is confirmed based on the decrease in CP and declination of the talus angle. However, because of the expense and radiation exposure, simple radiographic imaging is not always feasible. Therefore, a non-invasive and simple measurement method is needed.

Currently, the arch height ratio (AHR) of the foot is a simple and appropriate way to evaluate flatfoot⁹). The foot AHR measurement method calculates the ratio of the navicular bone height to the foot length⁹). This method does not require a radiograph, thus helping patients, who require this assessment, avoid radiation exposure. Additionally, unnecessary expenses are also attenuated. This measurement method was compared to the Yokokura method using simple radiographic images, and was shown to be valid as a measurement method¹⁰). Moreover, the navicular bone has been used as an index, and the relevance of using the AHR as an indicator for healthy volunteers was verified in previous studies^{9, 11}). Intra-rater reliability of the AHR was also confirmed in participants with DS¹²). However, it is difficult to detect the navicular tuberosity in participants with DS, which depends on the degree of proptosis and the height of the spur, from the foot surface. Additionally, detecting the navicular bone is difficult in patients with DS because they often cannot cooperate with standing silent long time. Even if detecting the navicular bone is able in patients without intellectual disability, evaluating the navicular is more difficult in patients with intellectual disability following a tester's instruction. Therefore, in the present study, we verified another method using the medial and lateral malleoli (MM and LM, respectively) instead of the navicular bone using the AHR method to evaluate the degree of flatfoot on a medial longitudinal arch (MLA).

Furthermore, the usefulness and ease of the method using the malleoli are not clear. Easy measurement of the evaluation parameters is required in the clinical setting. One of the important criteria for evaluating flat feet is the ease of palpation, and anatomically, the malleoli are easy to detect on visual inspection. Therefore, we verified whether the MM and LM correlated with the navicular bone on radiographs for use as indices to evaluate the degree of flatfoot. Moreover, as the AHR is the ratio between the height of the navicular bone and foot length, if there is a correlation between the height of the navicular bone from the sole and that of the MM and LM, we can use MM and LM as landmarks instead of the navicular bone for the AHR. Therefore, the purpose of the present study was to understand whether the malleoli were appropriate for use as landmarks. To the best of our knowledge, the use of the malleoli has not been reported in normal children or in those with DS, and this study was done as a preliminary study for understanding whether patients with DS were also able to be subjected to an evaluation and for developing a simple and non-invasive evaluation method.

PARTICIPANTS AND METHODS

This was a retrospective study. We selected participants with DS who had foot radiographs taken at our hospital between August 2008 and May 2018, and who were diagnosed with flatfoot. This study was approved by the Ethics Committee (approval no. e157) and was endorsed by the Research Ethics Committee at our hospital. Participants had the right to opt-out of the study at any time. The research manager could be contacted (via details available on a poster within the hospital) for participants to assert the right to leave the study.

The right foot was arbitrarily unified for measurement. We measured the foot only with the participant standing in weight-bearing conditions. Lateral views of the digital radiographs of the foot were analysed. The Lateral radiographs were taken standing on one leg with the targeted foot. If a participant lost balance, a staff member standing by supported them. Measurements on simple radiograph images were conducted based on the Yokokura method¹⁰). In this method, the lowest point of the calcaneus is defined as point O. The lowest point of the medial sesamoid bone is defined as Y point. The baseline is drawn between points O and Y. However, ossification of the sesamoids in feet commences at 8 and 9 years for girls and boys, respectively, and is completed by the age of 10 years for both genders in the Arab population¹³). In this study, some participants less than 10 years old did not show a clear sesamoid on the radiograph. Therefore, we defined the lowest point of the first metatarsal head as the modified Y point instead of the original Y point (Fig. 1). The line drawn between O and modified Y was set as the reference line. The centre of the talo-navicular joint between the talus and the navicular is defined as point C, and it represents the navicular bone height from the reference line (Fig. 1). The lowest apex of MM was set as point M, and that of LM was point L. The distances from the reference line of the points M and L were defined as height of MM and LM, respectively.

Pearson's correlation analysis was conducted to examine the relationship between measured parameters. Statistical analyses

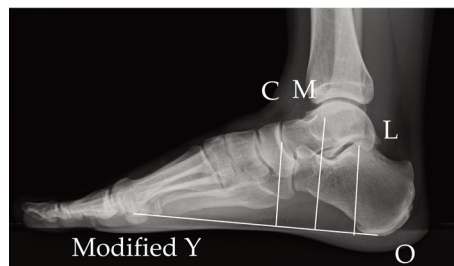


Fig. 1. Modified landmarks based on the Yokokura method¹⁰).

Modified method of Yokokura: a baseline is drawn between the lowest point of the medial sesamoid bone and that of the calcaneus at the original method. With the modified method, the baseline was drawn between the lowest point of the first metatarsal head and that of the calcaneus. C: the centre of the talo-navicular joint between the talus and the navicular. M: the lowest apex of medial malleolus. L: the lowest apex of lateral malleolus.

Table 1. Parameters measured on a radiograph in a population with Down syndrome

No	Age (years)	M: Height of MM (mm)	L: Height of LM (mm)	C: Height of TN (mm)
1	22.3	57.2	48.1	38.5
2	18.2	51.9	47.2	34.8
3	23.2	56.5	44.0	37.9
4	11.9	46.8	35.6	27.2
5	10.2	52.2	41.2	33.5
6	22.1	42.7	33.6	23.9
7	9.4	49.2	35.9	24.1
8	9.8	47.8	33.3	26.9
9	8.7	40.4	34.5	24.4
10	8.7	51.5	36.3	28.6
11	5.2	43.7	32.3	21.0
12	5.4	46.1	33.5	21.5
13	25.3	48.3	39.1	31.8
14	6.9	45.0	30.4	26.1
15	13.8	43.3	38.9	26.7
16	11.7	54.5	39.6	34.6
Mean	13.3	48.6	37.7	28.8
SD	6.5	4.9	5.1	5.4

SD: standard deviation; MM: medial malleolus; LM: lateral malleolus; TN: talo-navicular joint.

were performed using SPSS Statistics ver. 24 (IBM Corp., NY, USA). The level of statistical significance was set at $p=0.01$.

RESULTS

A total of 16 feet from 16 children with DS (mean age, 13.3 ± 6.5 years; range, 5.2 to 25.3 years) were included. Table 1 shows the age of the children with DS, the height of the MM and that of the LM, and the navicular bone height. Correlation analysis showed significant correlations between the height of point C and that of points M and L ($r=0.86$, $p<0.001$; $r=0.88$, $p<0.001$, respectively).

DISCUSSION

We found a strong positive correlation between the navicular bone height of patients with DS and the height of the MM and LM. In other words, as the height from the sole to the navicular bone increased, the height of MM and LM also increased. Therefore, it appears that it may be valid to evaluate the degree of MLA formation using MM and LM as bone indices instead of the navicular bone.

In the present study, a strong correlation between scaphoid height and heights of both the MM and the LM was observed. Therefore, it is conceivable to wonder which malleolus might be more suitable as a landmark instead of the navicular bone. The MM is located inside the foot as is the navicular bone, and it is close to the bone. By contrast, the LM is farther away from the navicular bone, and it is located outside the foot. Furthermore, it is important to distinguish the fibula from the tibia, as the fibula moves downward when the ankle is plantarflexed and upward when the ankle is dorsiflexed¹⁴. Thus, the height of LM possibly fluctuates, depending on the stance of the feet.

Moreover, we believe that the LM is not adequate for the scaphoid as an index in the clinical setting for two reasons: first, the previously mentioned distance of the LM from the navicular bone is farther, and second, it is considered that valgus knees frequently observed in DS decrease the height of MM and increase the height of LM^{15, 16}. Further, the mechanism of decrease in the MLA that causes flatfoot should also be taken into account: When the foot cannot support the load applied to the tibia, the talus slides down from the calcaneus and thereafter between the calcaneus and the scaphoid in a sagittal plane because both sides of the talus are surrounded by the bony ends of the tibia and fibula (the MM and LM)¹⁷. Simultaneously, the calcaneus moves backwards as the sliding talus pushes down the calcaneus, and the calcaneo-navicular ligament becomes tense. Therefore, the navicular bone is pulled down as the position of the calcaneus goes backward. Therefore, the MLA would lower in accordance with the dropping of the navicular bone. The tibia anatomically has a larger contact surface with the talus, and the load on the weight-bearing foot is mainly supported by the tibia¹⁸. Thus, it is believed that the tibia and the decrease in the MLA are closely related. Taken together, the physical proximity between the MM and navicular bone and the association between the tibia and the declination of the MLA indicate that MM would be a more suitable bony landmark to

be used in place of the navicular bone than LM.

The M point, indicating the tip of the MM was used for analysis of simple radiograph images in this study. However, it is difficult to palpate the tip of the MM from the foot surface and ease of palpation is an essential prerequisite of an evaluation index. Moreover, reliability, reproducibility, as indicated by a high inter- and intra-rater agreement, and objectivity are also required for clinical evaluation. Therefore, in contrast to the tip of the MM determined on a simple radiographic image as in this study, the maximum protruding part of the MM that is often used for measurement of the spino-malleolus distance is thought to be a relatively easy to palpate. Therefore, we believe that the reliability and objectivity of the maximum protruding part of the MM is used as an index instead.

This study had some limitations that must be acknowledged. First, this study was retrospective in design. Moreover, the knee alignment could not be confirmed in any of the cases. However, we believe that even if DS patients with valgus knee were included as participants in this study, the relative location of MM would be constant because the position of both the MM and the navicular bone change simultaneously. Conversely, we believe that the position of the LM relative to that of the navicular bone would be changed if the height of the LM increases with genu valgum. We intend to evaluate the alignment of the knee in a further study to clarify this point. However, we did not directly measure the height of the navicular bone and that of the MM and LM from the foot surface. Therefore, we conducted this study as a preliminary study as we mentioned in Introduction. In order to implement the use of MM instead of the navicular bone as a bony landmark in clinical practice, the actual evaluation with MM from the surface is needed to do, and further studies that the results of the measurement of MM are compared with a radiograph are needed.

Altogether, the malleoli could substitute for the navicular bone as landmarks. Considering the close physical distance between the MM and navicular bone and the association between the tibia and MLA, the MM may be a better landmark than LM in patients with DS. However, further studies are required to overcome the limitations of this study so that the MM can be used instead of navicular bone as a bony landmark to diagnose flatfoot in clinical practice.

Conflict of interest

None.

REFERENCES

- 1) Selikowitz M: Health problems and health checks in school-aged children with Down syndrome. *J Paediatr Child Health*, 1992, 28: 383–386. [[Medline](#)] [[CrossRef](#)]
- 2) Mik G, Gholve PA, Scher DM, et al.: Down syndrome: orthopedic issues. *Curr Opin Pediatr*, 2008, 20: 30–36. [[Medline](#)] [[CrossRef](#)]
- 3) Fanter NJ: Down syndrome and orthopaedic problems. *Hughston Health Alert*, 2012, 24: 1–2.
- 4) Concolino D, Pasquzzi A, Capalbo G, et al.: Early detection of podiatric anomalies in children with Down syndrome. *Acta Paediatr*, 2006, 95: 17–20. [[Medline](#)] [[CrossRef](#)]
- 5) Diamond LS, Lynne D, Sigman B: Orthopedic disorders in patients with Down's syndrome. *Orthop Clin North Am*, 1981, 12: 57–71. [[Medline](#)]
- 6) Merrick J, Ezra E, Josef B, et al.: Musculoskeletal problems in Down Syndrome European Paediatric Orthopaedic Society Survey: the Israeli sample. *J Pediatr Orthop B*, 2000, 9: 185–192. [[Medline](#)] [[CrossRef](#)]
- 7) Volman MJ, Visser JJ, Lensvelt-Mulders GJ: Functional status in 5 to 7-year-old children with Down syndrome in relation to motor ability and performance mental ability. *Disabil Rehabil*, 2007, 29: 25–31. [[Medline](#)] [[CrossRef](#)]
- 8) Eshuis R, Boonzaaijer M, van Wieringen H, et al.: Assessment of the relationship between joint laxity and migration of the hip in children with Down syndrome. *J Child Orthop*, 2012, 6: 373–377. [[Medline](#)] [[CrossRef](#)]
- 9) Miaki H, Kato I: Centre of foot pressure in a mediolateral direction and arch ratio as a reliable measure for flat-footedness. *Rigakuryoho Kagaku*, 2007, 22: 409–412. [[CrossRef](#)]
- 10) Yokokura S: A radiographic criterion of the medial and lateral longitudinal arch of the normal foot and classification of the flat foot. *Nippon Seikeigeka Gakkai Zasshi*, 1928, 3: 331–360.
- 11) Waseda A, Suda Y, Inokuchi S, et al.: Standard growth of the foot arch in childhood and adolescence—derived from the measurement results of 10,155 children. *Foot Ankle Surg*, 2014, 20: 208–214. [[Medline](#)] [[CrossRef](#)]
- 12) Kanai Y, Mutsuzaki H, Komuro T: Intra-rater reliability of arch height ratio measurement using the navicular tuberosity on the surface of the body in children with Down syndrome. *J Phys Ther Sci*, 2019, 31: 449–452. [[Medline](#)] [[CrossRef](#)]
- 13) Dharap AS, Al-Hashimi H, Kassab S, et al.: Incidence and ossification of sesamoid bones in the hands and feet: a radiographic study in an Arab population. *Clin Anat*, 2007, 20: 416–423. [[Medline](#)] [[CrossRef](#)]
- 14) Kapandji A: The ankle. In: *Physiology of the joints* 6th ed. London: Churchill Livingstone, 2010, pp 156–177.
- 15) Muscolino JE: Joints of the lower extremity. In: *Kinesiology: the skeletal system and muscle function*. St. Louis: Mosby/Elsevier, 2011, pp 255–325.
- 16) Jesse MW: Orthopedic conditions. In: *Physical therapy for children*, 5th ed. St. Louis: Elsevier, 2017, pp 294–338.
- 17) Cailliet R: Painful disorders of the adult foot. In: *Foot and ankle pain*, 2nd ed. Philadelphia: FA Davis Co, 1983, pp 105–124.
- 18) Neuman DA: Ankle and foot. In: *Kinesiology of the musculoskeletal system: foundations for rehabilitation*, 3rd ed. St. Louis: Elsevier, 2017, pp 595–652.