

Non-Hodgkin's Lymphoma of Multiple Skeletal Muscles Involvement Seen on FDG PET/CT Scans

Yue Dai, MD, Medapati Sowjanya, MD, Jia You, MD, and Kai Xu, PhD

Abstract: As normal healthy skeletal muscle does not contain lymphoid tissue, extra nodal lymphoma involving multiple muscles is rare, as well. This study reports a case of non-Hodgkin's lymphoma (NHL) of multiple skeletal muscles involvement and a review of differential diagnosis of it.

A 37-year-old female presented to our hospital after being diagnosed with NHL for 7 months. She had received six courses of cyclophosphamide hydroxydaunorubicin oncovin prednisolone etoposide (CHOPE) chemotherapy. Then she felt pain and noticed swelling on her left calf. The fluorodeoxyglucose (^{18}F FDG) positron emission tomography (PET)/computed tomography (CT) image showed abnormal focal FDG uptake in hypo-pharynx, which was the primary NHL and also in multiple groups of muscles in whole body. As the patient has history NHL, lymphoma of multiple muscle involvement was suspected.

Finally, an ultrasound-guided tissue biopsy was performed on the left calf and histological examination yielded lymphomatous cells infiltration in the left gastrocnemius.

Through this report, we emphasize that a multidisciplinary team approach with clinician, radiologist, and pathologist is essential for proper diagnosis, staging, and management of such rare lesions.

(*Medicine* 94(18):e833)

Abbreviations: CHOPE = cyclophosphamide hydroxydaunorubicin oncovin prednisolone etoposide, CT = computed tomography, FDG = fluorodeoxyglucose, MRI = magnetic resonance imaging, NHL = non-Hodgkins lymphoma, PET = positron emission tomography.

INTRODUCTION

Lymphomas constitute a broad range of lymphoproliferative disorders. They comprise 10% of all malignant tumors and are traditionally divided into Hodgkin and non-Hodgkin's types.¹ Because normal healthy skeletal muscle does not contain lymphoid tissue,² extra nodal lymphoma involving multiple muscles is rare, as well. This study reports a case of non-

Hodgkin's lymphoma (NHL) of multiple skeletal muscles involvement, and a review of differential diagnosis of it.

CASE REPORT

A 37-year-old female presented to our hospital after being diagnosed with NHL for 7 months. After she had received 6 courses of cyclophosphamide hydroxydaunorubicin oncovin prednisolone etoposide (CHOPE) chemotherapy, the woman found her left calf was painful and swollen. Then an ^{18}F -fluorodeoxyglucose (FDG) positron emission tomography (PET)–computed tomography (CT) was made for further evaluation of her lesion status and identified whether there is another related lesion. The whole body maximum intensity projection PET image (Figure 1A and B) showed increased FDG uptake in the primary lesion and multiple skeletal muscles. The fused PET–CT image showed increased FDG uptake in hypo-pharynx that was the primary NHL (Figure 1C) and multiple groups of muscles, including bilateral pectoralis major, deltoid, latissimus dorsi, trapezius, gluteus maximus, iliopsoas, sartorius, biceps femoris, semitendinosus, semimembranosus, especially the left soleus, and gastrocnemius (Figure 1D–F). These signs and the history of lymphoma indicated that the residual lesion and multiple muscles involvement were suspected. To diagnose the muscle lesions, an ultrasonography-guided tissue biopsy was performed on the left calf. Histological examination yielded lymphomatous cells infiltration in the left gastrocnemius (Figure 2).

DISCUSSION

Nowadays, FDG PET and PET/CT imaging have become mainstream clinical imaging tools for staging, therapy assessment, and follow-up evaluation of patients with lymphoma.³ Although CT and magnetic resonance imaging (MRI) provide high-resolution anatomic information, PET adds information on the metabolic activity of lesions.

In our case, we only find the muscles involved in left calf were swollen and hypo-dense relative to normal muscles on CT. However, the fused PET/CT image shows increased FDG uptake in multiple muscles of the whole body. PET/CT image is more valuable because metabolism of active lesions may not have morphological changes.

However, the PET imaging features are nonspecific. There is a broad spectrum of intramuscular disorders that can mimic NHL involving skeletal muscles such as primary soft tissue sarcoma, muscle sarcoidosis, intramuscular metastases, myositis, inflammatory pseudo-tumors, and skeletal muscle lymphoma (SML).^{4–10} In order to differentiate NHL involving skeletal muscle from other muscle lesions, we need CT and MRI as auxiliary tools. SML tends to involve multiple muscle and typically infiltrates the adjacent subcutaneous fat

Editor: Majid Assadi.

Received: March 3, 2015; revised: April 6, 2015; accepted: April 8, 2015. From the Department of Radiology, Affiliated Hospital of Xuzhou Medical College, Xuzhou 221006, China (YD, JY); and School of Medical Imaging, Xuzhou Medical College, Xuzhou 221004, China (YD, MS, JY, KX).

Correspondence: Kai Xu, PhD, School of Medical Imaging, Xuzhou Medical College, Jiangsu, China (e-mail: xkpaper@163.com).

The authors have no funding or conflicts of interest to disclose.

Copyright © 2015 Wolters Kluwer Health, Inc. All rights reserved.

This is an open access article distributed under the Creative Commons Attribution-NonCommercial-NoDerivatives License 4.0, where it is permissible to download, share and reproduce the work in any medium, provided it is properly cited. The work cannot be changed in any way or used commercially.

ISSN: 0025-7974

DOI: 10.1097/MD.0000000000000833

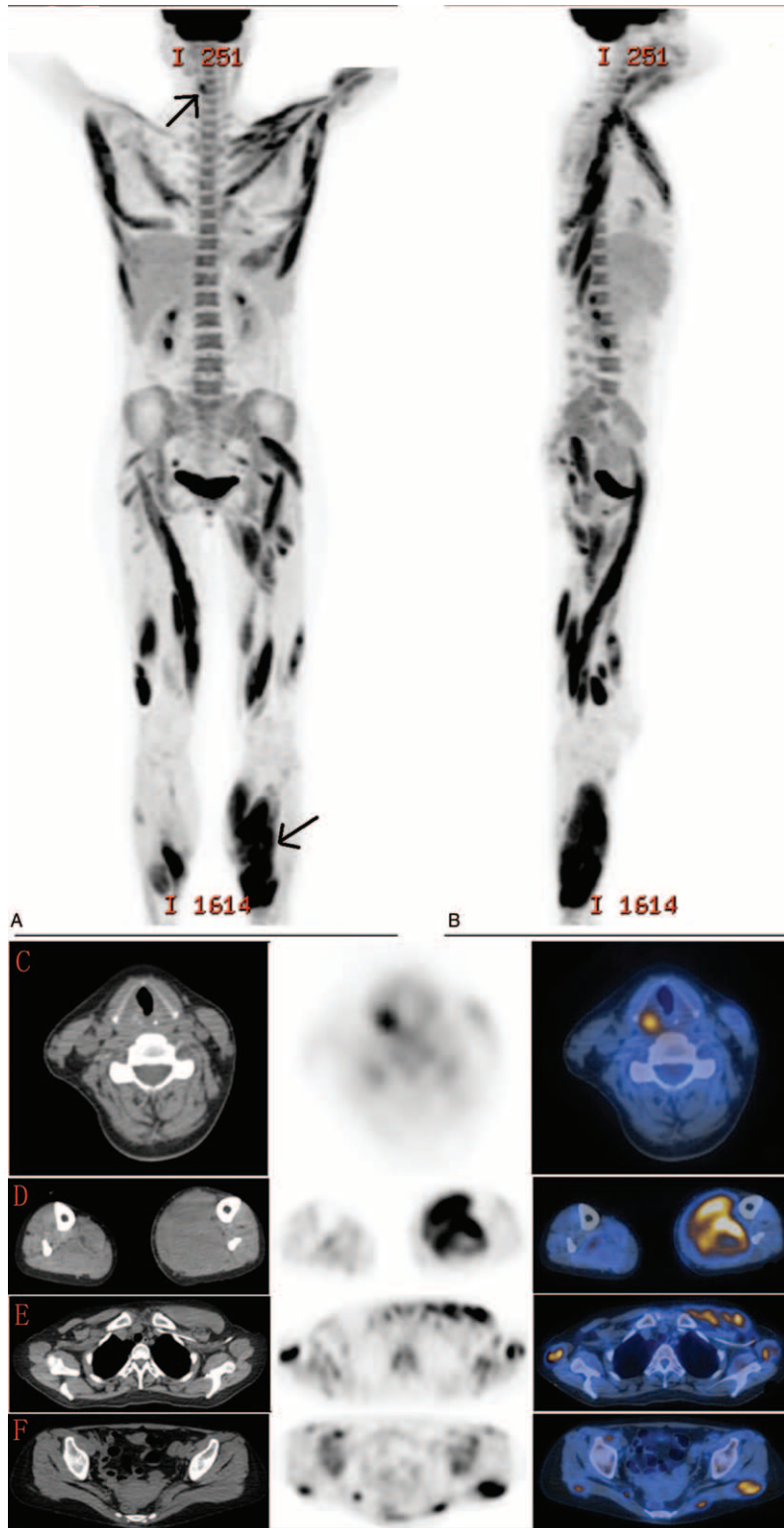


FIGURE 1. A 37-year-old female with a history of non-Hodgkin’s lymphoma felt pain and noticed swelling on her left calf was referred for an FDG PET/CT examination. The three-dimensional MIP image in coronal (A) and sagittal (B) plane demonstrated widespread FDG uptake lesions, including the primary lymphoma and multiple muscles, which are clearly visible (arrows). Selected trans axial slices of attenuation-corrected CT, PET, and fused PET/CT images showed abnormal focal FDG uptake at the level of hypo-pharynx (C), multiple groups of muscles (D–F), one of the site from where biopsy is taken (D).

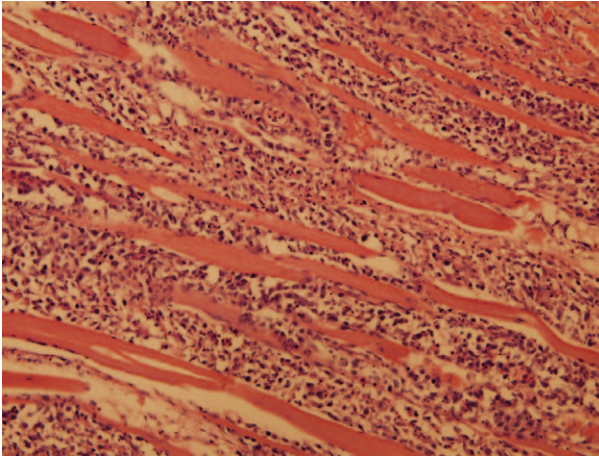


FIGURE 2. Ultrasound-guided tissue biopsy was performed on the left gastrocnemius to obtain a definitive histological diagnosis. Hematoxylin and eosin stain ($\times 400$) of the lesion revealed neoplastic lymphocytes surrounding and invading myofibrils, which was consistent with non-Hodgkin's lymphoma of skeletal muscles.

compartments.^{6,10,11} Muscle metastases manifest typically as intramuscular masses with homogenous or rim enhancement. Metastatic lesions with diffuse muscle enlargement have been also described in some literatures.^{12,13} Myositis has high or very high signal intensity on T2WI and T2WI fat-suppressed images.⁵ And bright stripes on T2WI in muscle sarcoidosis have been reported before.⁵ In contrast to other disorders, NHL involving skeletal muscle has been described as hypo-dense on CT, hyper-intense or iso-intense on the T1-weighted sequence and hyper-intense on the T2-weighted and fat suppression sequences.^{5,14,15}

To determine the primary lesion of lymphoma is the most important point because primary skeletal muscles lymphoma is unusual. As normal healthy skeletal muscle does not contain lymphoid tissue,² extra nodal lymphoma involving multiple muscles is rare, as well.

Our patient has been diagnosed as NHL, and her PET/CT image shows increased FDG uptake in multiple skeletal muscles. With her medical history, we diagnose it as metastasis or infiltration of lymphoma to skeletal muscles. The PET/CT imaging is an advantageous modality that assists in the diagnosis of this disease and could find more lesions. However, a biopsy is necessary for a final and conclusive diagnosis. A multidisciplinary team approach with clinician, radiologist, and

pathologist is essential for proper diagnosis, staging, and management of such rare lesions.¹⁵

REFERENCES

1. Cobleigh M, Kennedy J. Non-Hodgkin's lymphomas of the upper aerodigestive tract and salivary glands. *Otolaryngol Clin North Am.* 1986;19:685–710.
2. Bennett S, Slocombe R, Holloway S, et al. Lymphoma(s) showing epitheliotropism and diffuse skeletal muscle involvement presenting as a polymyopathy in a young dog. *Aust Vet J.* 2005;83:612–615.
3. Khandelwal AR, Takalkar AM, Lilien DL, et al. Skeletal muscle metastases on FDG PET/CT imaging. *Clin Nucl Med.* 2012;37:575–579.
4. Jhanwar YS, Straus DJ. The role of PET in lymphoma. *J Nucl Med.* 2006;47:1326–1334.
5. Beggs I. Primary muscle lymphoma. *Clin Radiol.* 1997;52:203–212.
6. Suresh S, Saifuddin A, O'Donnell P. Lymphoma presenting as a musculoskeletal soft tissue mass: MRI findings in 24 cases. *Eur Radiol.* 2008;18:628–634.
7. Surov A, Holzhausen HJ, Arnold D, et al. Intramuscular manifestation of non-Hodgkin lymphoma and myeloma: prevalence, clinical signs, and computed tomography features. *Acta Radiol.* 2010;51:47–51.
8. Lee VS, Martinez S, Coleman RE. Primary muscle lymphoma: clinical and imaging findings. *Radiology.* 1997;203:237–244.
9. Eustace S, Winalski CS, McGowen A, et al. Skeletal muscle lymphoma: observation at MR imaging. *Skelet Radiol.* 1996;25:425–430.
10. Surov A. Imaging findings of skeletal muscle lymphoma. *Clin Imaging.* 2014;38:594–598.
11. Metzler JP, Fleckenstein JL, Vuitch F, et al. Skeletal muscle lymphoma: MRI evaluation. *Magn Reson Imaging.* 1992;10:491–494.
12. Surov A, Hainz M, Holzhausen HJ, et al. Skeletal muscle metastases: primary tumors, prevalence, and radiological features. *Eur Radiol.* 2010;20:649–658.
13. Surov A, Fiedler E, Voigt W, et al. Magnetic resonance imaging of intramuscular metastases. *Skelet Radiol.* 2011;40:439–446.
14. Chong J, Som PM, Silvers AR, et al. Extranodal non-Hodgkin lymphoma involving the muscles of mastication. *Am J Neuroradiol.* 1998;19:1849–1851.
15. Muralee MC, Thakral A, Bhat SK. Primary extra nodal non-Hodgkin's lymphoma involving masseter and buccinators muscles. *Int J Oral Maxillofac Surg.* 2012;41:1393–1396.