

Comparison of Contrast Enhanced Low-Dose Dobutamine Stress Echocardiography with ^{99m}Tc-Sestamibi Single-Photon Emission Computed Tomography in Assessment of Myocardial Viability

Bhupendra Verma^{1*}, Amrita Singh²

¹Department of Cardiology, Ujala Hospital, Kashipur, UK, India; ²Department of Nephrology, Ujala Hospital, Kashipur, UK, India

Abstract

Citation: Verma B, Singh A. Comparison of Contrast Enhanced Low-Dose Dobutamine Stress Echocardiography with ^{99m}Tc-Sestamibi Single-Photon Emission Computed Tomography in Assessment of Myocardial Viability. Open Access Maced J Med Sci. 2019 Apr 30; 7(8):1287-1292. <https://doi.org/10.3889/oamjms.2019.254>

Keywords: Coronary artery disease; Myocardial perfusion scan; LV endocardial visualisation; Myocardial ischemia; LV dysfunction

***Correspondence:** Bhupendra Verma, Department of Cardiology, Ujala Hospital, Kashipur, UK, India. E-mail: bhupendra.269@gmail.com

Received: 11-Feb-2019; **Revised:** 30-Mar-2019; **Accepted:** 31-Mar-2019; **Online first:** 26-Apr-2019

Copyright: © 2019 Bhupendra Verma, Amrita Singh. This is an open-access article distributed under the terms of the Creative Commons Attribution-NonCommercial 4.0 International License (CC BY-NC 4.0)

Funding: This research did not receive any financial support

Competing Interests: The authors have declared that no competing interests exist

INTRODUCTION: Dobutamine stress echocardiography (DSE) and myocardial perfusion scan are the commonly used modalities to detect viable myocardium. DSE is comparatively cheaper and widely available but has a lower sensitivity.

AIM: We aimed to compare contrast-enhanced low-dose dobutamine echocardiography (LDDE) and gated ^{99m}Tc-sestamibi myocardial perfusion scan (MPS) for the degree of agreement in the detection of myocardial viability.

METHODS: We studied 850 left ventricular segments from 50 patients (42 men, mean age 55.5 years), with coronary artery disease and left ventricular systolic dysfunction (ejection fraction < 40%), using contrast-enhanced LDDE and ^{99m}Tc-Sestamibi gated SPECT. Segments were assessed for the presence of viability by both techniques and head to head comparisons were made.

RESULTS: Adequate visualisation increased from 80% in unenhanced segments to 96% in contrast-enhanced segments. Of the total 850 segments studied, 290 segments (34.1%) had abnormal contraction (dysfunctional). Among these, 138 were hypokinetic (16.2% of total), 144 were severely hypokinetic or akinetic (16.9% of total), and 8 segments were dyskinetic or aneurismal (0.9% of total). Among 151 segments considered viable by technetium, 137 (90.7%) showed contractile improvement with dobutamine; in contrast, only 8 of the 139 segments (5.7%) considered nonviable by technetium had a positive dobutamine response. The per cent of agreement between technetium uptake and a positive response to dobutamine was 78.6% with kappa = 0.63, suggestive of a substantial degree of agreement between the two modalities.

CONCLUSION: Use of contrast-enhanced LDDE significantly increased the adequate endocardial border visualisation. Furthermore, this study showed a strong degree of agreement between the modalities in the detection of viable segments. So, contrast-enhanced LDDE appears to be a safe and comparable alternative to MPS in myocardial viability assessment.

Introduction

Left ventricular dysfunction associated with coronary artery disease (CAD) is a common cause of morbidity and mortality. However, reports show that > 50% of such patients may have viable myocardium [1]. Revascularization improves left ventricular ejection fraction (LVEF), heart failure symptoms and prognosis predominantly in patients with viable myocardium [2], [3], [4], [5], [6], [7], [8]. Though some

recent studies provided contrary results, they had several significant limitations and confounding factors [9], [10].

Based on robust evidence on viability assessment, American Heart Association (AHA) has given class IIa recommendation for non-invasive imaging in patients with heart failure who have known CAD and no angina [11]. Guidelines from other societies also recommend detection of viability in the diagnostic workup of patients with CAD and severe

ventricular dysfunction [12], [13].

Most widely available and commonly used methods for this purpose are dobutamine stress echocardiography (DSE) and SPECT. Tc-99m sestamibi is the most widely used tracer in SPECT. The main limitations of SPECT include, higher cost compared to echocardiography, limited spatial resolution, poor availability, potential difficulty in interpreting results in patients with balanced myocardial ischemia (3-vessel disease), and risk of radiation. Higher cost and limited availability are the most important limitations in resource-poor countries like India. Results of DSE are immediately available, can be done bedside in sicker patients significantly supporting rapid patient management. An obvious advantage is the availability of ancillary information about chamber sizes and function, valves, pericardial effusion, aortic root disease. Additional parameters of viability can also be assessed like strain imaging, Doppler studies, and end-diastolic wall thickness (EDWT). However, in patients with chronic ischemic ventricular dysfunction, DSE has higher specificity (78% vs 65%) but a slightly lower sensitivity (81% vs 83%) compared to SPECT [14], [15], [16].

Recent advances in echocardiographic imaging have, however, significantly increased the sensitivity and interobserver agreement for the detection of coronary artery disease. These include harmonic imaging and LV opacification with contrast agents. Contrast-enhanced imaging, enable better visualisation of the endocardial border and a more reliable assessment of contractile function even in patients difficult to image with fundamental imaging. Therefore, contrast-enhanced imaging has been regularly used in DSE for myocardial detection ischemia in cases with ≥ 2 poorly visualised segments as recommended by various guidelines [17], [18], [19]. However, contrast enhancement has not been used in the setting of viability assessment by low dose dobutamine echocardiography (LDDE). Hence combining contrast with LDDE to increase sensitivity for viability assessment appears an attractive option. However, there is no head to head trial comparing the sensitivity of contrast-enhanced dobutamine stress echocardiography against myocardial perfusion SPECT. This study aimed to assess the degree of agreement between the two methods in detecting viability in dysfunctional myocardial segments.

Material and Methods

Study population

This was a single centre, double-blinded, a comparative study between DSE and Tc-SPECT. The study period was from May 2014 to December 2016, carried out in the department of cardiology, Jawaharlal

Institute of Postgraduate Medical Education and Research (JIPMER), Puducherry, India. Fifty consecutive patients with chronic coronary artery disease and impaired left ventricular systolic function (ejection fraction, EF < 40% at rest) without chest pain were included in the study. The study was conducted according to the Helsinki Declaration and the Good Clinical Practice Guidelines. Written informed consent was obtained from all patients. Ethical approval for the study protocol was obtained from the Ethics Committee of JIPMER.

Study design

The patients included in the study first underwent low dose dobutamine stress echocardiography (LDSE) with proper safety precautions in the cardiology department. As per protocol, the contrast agent was administered to patients both before and after stress, for better visualisation of wall motion abnormality. Dobutamine infusion was then continued to a high dose to attain peak stress. At peak stress, technetium was injected, and the patient was shifted for stress SPECT in the nuclear medicine department of the institute. Rest SPECT was done on a separate day. Two-day rest/stress protocol was used for SPECT study [20], [21], [22]. Both procedures were done in short interval maximum one week apart. 17-segment heart model, as recommended by ACC/AHA, was used for defect localisation and comparison between two modalities [23]. The cardiologist doing the LDSE was blinded to SPECT results and vice-versa.

Dobutamine stress echocardiography protocol [17], [18], [19]

Beta-blockers, CCBs and nitrates were stopped at least 2 days before DSE. The subjects were kept fasting for at least 4 hours. 2 ml of SonoVue ultrasound contrast (Sulphur Hexafluoride microbubbles, Bracco, Switzerland) was used for LV opacification at baseline and after dobutamine stress in all patients. The contrast was used with harmonic imaging and low MI settings (Mechanical Index, 0.15 to 0.3). Four views were acquired in all patients: apical four chamber and two chamber views, parasternal short axis and long axis (or long apical axis) views. The frame rate was kept > 25 frames per second. The initial infusion of dobutamine was 2.5 $\mu\text{g}/\text{kg}/\text{min}$ and gradually increased to 5, 7.5, 10, and 20 $\mu\text{g}/\text{kg}/\text{min}$, as required. Each dose was maintained for up to five minutes. An increase in heart rate by 10% was taken as end-point for completion of low dose dobutamine protocol. After completing the low dose protocol higher dosages of dobutamine (30 and 40 $\text{mcg}/\text{kg}/\text{min}$) was given to achieve peak stress so that stress SPECT could be done. All patients were continuously monitored for at least 30 min along with all emergency equipment.

All image acquisition and analysis were done by Philips IE33 system (Phillips Medical Systems, Andover, MA, USA), using 5 MHz probes. Off-line visual assessment of endocardial excursion and wall thickening was used for analysis. Function in each segment is graded at rest and with stress as normal, hypokinetic, akinetic/severely hypokinetic, dyskinetic, or aneurismal. Segments were considered dysfunctional when the wall motion score was 2 or more. Viability was considered to be present in a dysfunctional segment when there was an improvement in function by at least one grade, except improvement from dyskinesia to akinesia.

Myocardial perfusion scan protocol [20], [21], [22]

The stress SPECT was done on the same day of DSE, by using the ongoing dobutamine infusion to achieve peak stress. The radiotracer (Tc-99m) was injected intravenously at 1 minute into peak stress, and dobutamine infusion was continued for 2 minutes after the radiotracer injection. 30 min after injection of 99mTc-sestamibi, the patients were required to eat a fatty snack to accelerate hepatobiliary excretion of the radiotracer. For stress imaging, 555 MBq-1.11 GBq (15 – 30 mCi) was injected at peak stress. Gated SPECT was then performed from 30-60 minutes after injection. On a separate day rest, myocardial perfusion scan was done. For rest imaging, 555 MBq – 1.11 GBq (15-30 mCi) was injected at rest. 5 mg of sublingual nitrate was taken by patients 10 minutes before 9mTc-sestamibi injection. Gated SPECT was then performed within 45-60 min after injection.

The images were displayed as short axis, vertical and horizontal axes sections. Uptake was measured semiquantitatively based on the visual interpretation of colour scale. Segments were divided into 5 categories: 0 = normal perfusion, 1 = slightly reduced tracer uptake (> 75%), 2 = moderately reduced tracer uptake (50% to 75%), 3 = severely reduced tracer uptake (30% to 50%), and 4 = absent tracer uptake (< 30%). As a general rule, segments with rest score of 0 (normal perfusion) and 1 (slight reduction in counts) are considered viable. Segments with rest score of 2 (moderately decreased perfusion) are considered to represent a combination of viable and nonviable myocardium. In dysfunctional segments, perfusion was considered preserved when activity was 50% or more (score 0, 1 or 2).

Statistical analysis

Continuous variables are expressed as mean ± SD and categorical variables as the absolute values and percentages. A chi-squared test was used to compare the statistical parameters of this technique. The correlation between the two tests for the assessment of myocardial segment viability was expressed as per cent agreement and value of Kappa

(k). A p-value < 0.05 was considered statistically significant. Statistical analysis was performed using an SPSS software version 18.0.

Results

In total, 50 patients constituted the final study population. Mean age was 55.5 ± 10.7 years and 42 were males (84%). The mean LVEF by echocardiography, calculated by Simpson’s method, was 32 ± 4.6% (range = 21-40). The mean LVEF calculated by gated-SPECT was 29.5 ± 4.6% (range = 20-42). Twenty-seven patients had diabetes (54%), 21 were hypertensive (42%), 20 were a smoker (40%), and dyslipidaemia was seen in 19 patients (38%). Coronary artery disease was defined as > 50% diameter stenosis. Single vessel disease was seen in 13 patients (26%), double vessel disease in 18 patients (36%), triple vessel disease in 21 patients (42%), and left main disease was found in 9 patients (18%), (Table 1).

Table 1: Baseline characteristics of the study population

Variables	
Age 55.5 ± 10.7 years	(range = 25-76 years)
Male 42 (84)	
LVEF 32 ± 4.6%	(range = 21-40)
CV risk factors	
Diabetes	27 (54%)
Hypertension 21 (42)	
Smoker	20 (40)
Dyslipidemia	19 (38)
Past ACS 24 (48)	
Severity of CAD	
SVD	13 (26)
DVD	18 (36)
TVD	21 (42)
M disease 9 (18)	

Values shown represent numbers (percentages) and mean ± SD; LVEF, Left ventricular ejection fraction; CV, Cardiovascular; ACS, Acute coronary syndrome; CAD, Coronary artery disease; SVD, Single-vessel disease; DVD, Double-vessel disease; TVD, Triple-vessel disease; LM, Left-main.

Low-Dose Dobutamine Stress Echocardiography (LDDE)

A total of 850 segments from 50 patients were analysed, based on the 17 segment model of heart both LDDE and Tc-SPECT (Figure 1). Out of 850 segments, 170 segments were inadequately visualised at rest in unenhanced DSE.

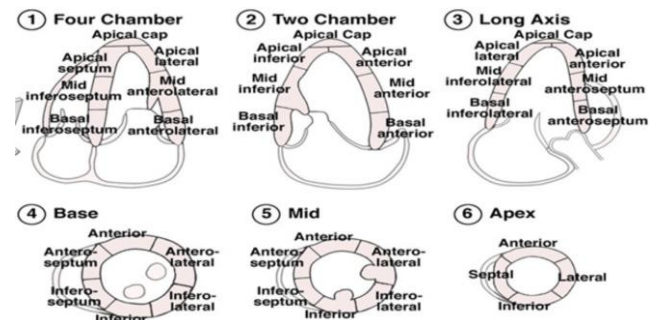


Figure 1: A 17-segment model of heart recommended by AHA

Adequate visualisation increased from 80% in unenhanced segments to 96%, in contrast, enhanced segments. Overall 4 patients (8%) had uninterpretable DSE in unenhanced images, with the use of contrast all studies became interpretable (Figure 2). Regional contractile function, as assessed by resting two-dimensional echocardiography, demonstrated normal contraction in 560 segments (65.8%) and abnormal contraction (dysfunctional) in 290 segments (34.1%). Of 290 dysfunctional segments, 138 were hypokinetic (16.2% of total), 144 were severely hypokinetic or akinetic (16.9% of total), and 8 segments were dyskinetic or aneurismal (0.9% of total) (Figure 2).

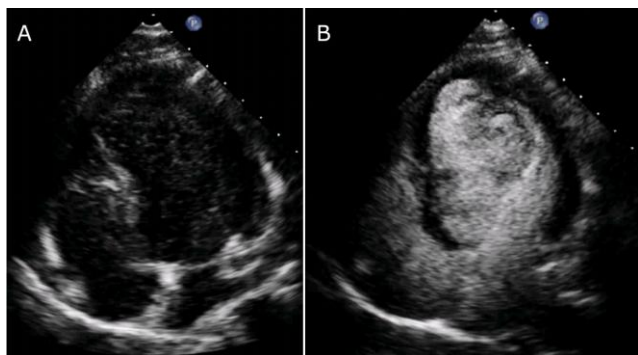


Figure 2: Representative still images showing significant improvement in visualisation of the endocardial border by use of contrast agent; A) without contrast; B) with SonoVue contrast

Dysfunctional segments were evaluated for the presence of contractile reserve, defined as an improvement of wall motion score by 1 grade or more. Of the 290 dysfunctional segments, 134 (46.2%) were viable and 156 (53.8%) nonviable by LDDE. Viability was found in 108/138 (78.2%) of hypokinetic and 26/144 (18%) severely hypokinetic/akinetic regions. All 8 dyskinetic/aneurismal segments were nonviable (Figure 3).

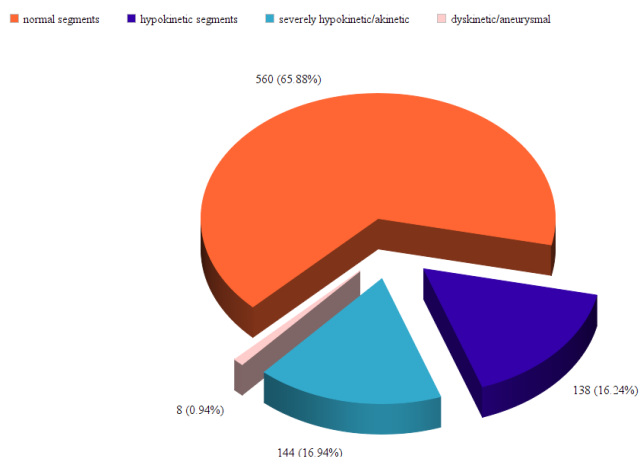


Figure 3: Distribution of regional contractile function assessed by echocardiography at rest

99mTc-Sestamibi gated SPECT

Significant LV dilatation was seen in 13 patients (26%) and transient ischemic dilatation found

in 5 patients (10%). Of the 290 dysfunctional segments, 151 (52%) were viable and 139 (48%) nonviable. Results of resting two-dimensional echocardiography and MPS showed that 119/138 (86%) of hypokinetic, 28/144 (19.4%) of severely hypokinetic and 4/8 (50%) of aneurismal regions were viable. Of the non-viable region, perfusion was grade 3 in 70% patients and grade 4 in 30% of patients. Of the 151 viable segments by rest MPS, 129 segments showed ischemia on stress (85.4%).

The relation between LDDE and SPECT

The number of segments with regional wall motion abnormalities (RWMA) that were considered viable by technetium was greater than the number of segments showing a contractile improvement in response to dobutamine (52% versus 46.2%). However, the difference was not significant ($p = 0.31$). A significant relation was observed between technetium uptake and response to dobutamine. Among 151 segments considered viable by technetium, 137 (90.7%) showed contractile improvement with dobutamine; in contrast, only 8 of the 139 segments (5.7%) considered nonviable by technetium had a positive dobutamine response.

On the contrary, we observed that 1.7% (5/290) of dysfunctional segments showed contractile reserve according to DSE, but did not show technetium uptake. The rate of agreement between technetium uptake and a positive response to dobutamine was 78.6%. The value of kappa for the degree of agreement between the two modalities was found to be 0.63. This corresponds to a substantial degree of agreement between the two tests.

Discussion

In patients with severe coronary artery disease and a low LVEF, the evaluation of viability in regions with chronic contractile dysfunction has been shown to predict improvement of function after revascularization [2], [3], [4], [5], [6], [7], [8], [24], [25]. The current study was done to compare the most widely available and commonly used modalities, i.e. dobutamine stress echocardiography and 99mTc-sestamibi imaging for the assessment of viable myocardium.

A head-to-head comparison of the individual segments in this study showed a 78.6% agreement between contrast-enhanced low-dose dobutamine stress echocardiography and ECG gated myocardial SPECT. Various direct comparisons of nuclear imaging and LDDE have reported a fair degree of agreement between the techniques. Panza et al. reported an agreement between 201Tl imaging and

low dose dobutamine echocardiography of 68% [26]. The disagreement in their study was also mainly related to segments with viability on nuclear imaging but without functional improvement on echocardiography. The largest head-to-head comparison was made by Bax et al., which included 114 patients who underwent resting perfusion imaging with 99mTc-tetrofosmin and low-dose dobutamine echocardiography. The agreement rate reported between the techniques was 72% [27].

Moreover, a recent study has reported with an agreement rate of 77% between LDDE and gated-SPECT with low dose dobutamine infusion [28]. However, Bax et al., compared LDDE with 99mTc-tetrofosmin and Panja et al., compared with thallium. In our settings (India), there is poor availability of thallium and 99mTc-tetrofosmin is not available, whereas, our study is more relevant in Indian setting because we have shown a substantial degree of agreement using 99m-technetium.

It has been seen that poor-quality images may occur in up to 30% of patients due to challenges imposed by excessive cardiac motion due to hyperventilation and tachycardia and in up to 10% due to patient-related factors like obesity and lung disease. Moreover, suboptimal studies result in increased interobserver variability and less reproducibility. Several recent studies have assessed whether better endocardial border visualisation by left ventricular opacification improves the accuracy of stress echocardiography for diagnosis of coronary artery disease. In the OPTIMIZE trial, which included 108 patients, the use of a contrast agent improved the percentage of segments adequately visualised at baseline (from $72 \pm 24\%$ to $95 \pm 8\%$) [29]. Similar results were found in this study. Out of 850 segments, 170 segments were inadequately visualised at rest in unenhanced DSE. With the use of contrast, adequate visualisation increased from 80% in unenhanced segments to 96% contrast-enhanced segments. Overall 4 patients (8%) had uninterpretable DSE in unenhanced images, with the use of contrast all studies became interpretable.

Discordance was observed between the two methods in both hypokinetic and akinetic segments. Put in other words, for the same dysfunctional segments gated SPECT showed viability more often than LDDE. Similar results were reported by Panza et al., and Bax et al. who found that detection of viability by nuclear scan was more frequent than DSE. This difference is considered to be due to the difference in mechanisms of viability detection by the two methods. A higher degree of myocyte functional integrity is required for contractile reserve than radiotracer uptake by the cells [30]. We observed that 1.7% (5/290) of dysfunctional segments showed contractile reserve according to DSE, but did not show technetium uptake. Similarly, Panza et al., reported 2% (6/311) of dysfunctional segments without perfusion, but they thought it to be due to the error

inherent in the comparison of the two techniques. However, this is more likely attributable to areas with non-transmural myocardial infarction, as described by Armstrong [31].

In this study, we reported the safety, and diagnostic accuracy of contrast-enhanced dobutamine stress echocardiography in a population of patients with known coronary artery disease. In agreement with the earlier reports, the technique was well tolerated by all patients, and in no case did the study have to be discontinued because of occurrence of serious side effects due to contrast (SonoVue) or dobutamine [32]. The echocardiographic approaches are attractive because there is no ionising radiation, is safe, widely available, low cost, shorter imaging time, portable, immediate availability of the results, additional parameters of viability (strain, Doppler, EDWT), availability of ancillary information about cardiac structures. None of the previous head to head trial used contrast-enhanced LDDE for comparison. This is extremely important for resource developing countries like India where echocardiography is more readily available and a significantly lower cost as compared to SPECT. This study demonstrated a good agreement between contrast-enhanced low dose dobutamine stress echocardiography and Tc-SPECT for the myocardial detection viability. Therefore, contrast-enhanced LDDE can be used for viability detection with a good level of confidence.

In conclusion, the use of contrast agent significantly increases the adequate endocardial border visualisation and increases interpretability of images. Our study demonstrated a substantial degree of agreement between contrast-enhanced low dose dobutamine stress echocardiography and Tc-99m SPECT for the detection of contractile reserve in infarcted areas. So, contrast-enhanced LDDE appears to be a safe and comparable alternative to MPS in myocardial viability assessment.

References

1. Bax JJ, Poldermans D, Elhendy A, Cornel JH, Boersma E, Rambaldi R et al. Improvement of left ventricular ejection fraction, heart failure symptoms and prognosis after revascularization in patients with chronic coronary artery disease and viable myocardium detected by dobutamine stress echocardiography. *J Am Coll Cardiol*. 1999; 34:163-9. [https://doi.org/10.1016/S0735-1097\(99\)00157-6](https://doi.org/10.1016/S0735-1097(99)00157-6)
2. Allman KC, Shaw LJ, Hachamovitch R, Udelson JE. Myocardial viability testing and impact of revascularization on prognosis in patients with coronary artery disease and left ventricular dysfunction: a meta-analysis. *J Am Coll Cardiol*. 2002; 39:1151-8. [https://doi.org/10.1016/S0735-1097\(02\)01726-6](https://doi.org/10.1016/S0735-1097(02)01726-6)
3. Underwood SR, Bax JJ, vom Dahl J, Henein MY, Knuuti J, van Rossum AC, et al. Imaging techniques for the assessment of myocardial hibernation. Report of a Study Group of the European Society of Cardiology. *Eur Heart J*. 2004; 25(10):815-36. <https://doi.org/10.1016/j.ehj.2004.03.012> PMID:15140530
4. Schinkel AF, Bax JJ, Poldermans D, Elhendy A, Ferrari R, Rahimtoola SH. Hibernating myocardium: diagnosis and patient

- outcomes. *Curr Probl Cardiol.* 2007; 32:375-410. <https://doi.org/10.1016/j.cpcardiol.2007.04.001> PMID:17560992
5. Senior R, Lahiri A, Kaul S. Effect of revascularization on left ventricular remodelling in patients with heart failure from severe chronic ischemic left ventricular dysfunction. *Am J Cardiol.* 2001; 88:624-9. [https://doi.org/10.1016/S0002-9149\(01\)01803-3](https://doi.org/10.1016/S0002-9149(01)01803-3)
6. Verma B, Singh A, Saxena AK, Kumar M. Deflated Balloon-Facilitated Direct Stenting in Primary Angioplasty (The DBDS Technique): A Pilot Study. *Cardiol Res.* 2018; 9(5):284-292. <https://doi.org/10.14740/cr770w> PMID:30344826 PMCid: PMC6188044
7. Verma B, Patel A, Katyal D, Singh VR, Singh AK, Singh A, Kumar M, Nagarkoti P. Real World Experience of a Biodegradable Polymer Sirolimus-Eluting Stent (Yukon Choice PC Elite) in Patients with Acute ST-Segment Elevation Myocardial Infarction Undergoing Primary Angioplasty: A Multicentric Observational Study (The Elite India Study). *Open Access Maced J Med Sci.* 2019 Apr 15; 7(7):1103-1109. <https://doi.org/10.3889/oamjms.2019.241>
8. Ling LF, Marwick TH, Flores DR, JaberWA, Brunken RC, Cerqueira MD, et al. Identification of therapeutic benefit from revascularization in patients with left ventricular systolic dysfunction: Inducible ischemia versus hibernating myocardium. *Circulation.* 2013; 6(3):363-72. <https://doi.org/10.1161/CIRCIMAGING.112.000138>
9. Bonow RO, Maurer G, Lee KL, Holly TA, Binkley PF, Desvigne-Nickens P, et al. Myocardial viability and survival in ischemic left ventricular dysfunction. *N Engl J Med.* 2011; 364(17):1617-25. <https://doi.org/10.1056/NEJMoa1100358> PMID:21463153 PMCid:PMC3290901
10. Beanlands RS, Nichol G, Huszti E, Humen D, Racine N, Freeman M, et al. F-18- fluorodeoxyglucose positron emission tomography imaging-assisted management of patients with severe left ventricular dysfunction and suspected coronary disease: a randomized, controlled trial (PARR-2). *J Am Coll Cardiol.* 2007; 50:2002-12. <https://doi.org/10.1016/j.jacc.2007.09.006> PMID:17996568
11. Yancy CW, Jessup M, Bozkurt B, Butler J, Casey DE, Drazner MH, Fonarow GC, Geraci SA, Horwich T, Januzzi JL, Johnson MR. 2013 ACCF/AHA guideline for the management of heart failure: a report of the American College of Cardiology Foundation/American Heart Association Task Force on Practice Guidelines. *Journal of the American College of Cardiology.* 2013; 62(16):e147-239. <https://doi.org/10.1161/CIR.0b013e31829e8807>
12. Neumann FJ, Sousa-Uva M, Ahlsson A, et al. 2018 ESC/EACTS guidelines on myocardial revascularization: The Task Force on Myocardial Revascularization of the European Society of Cardiology (ESC) and European Association for Cardio-Thoracic Surgery (EACTS). Developed with the special contribution of the European Association for Percutaneous Cardiovascular Interventions (EAPCI). *Eur Heart J.* 2018.
13. Patel MR, White RD, Abbara S et al. ACCF/ACR/ASE/ASNC/SCCT/SCMR appropriate utilization of cardiovascular imaging in heart failure: A joint report of the American College of Radiology Appropriateness Criteria Committee and the American College of Cardiology Foundation Appropriate Use Criteria Task Force. *J Am Coll Cardiol.* 2013; 61:2207-31. <https://doi.org/10.1016/j.jacc.2013.02.005> PMID:23500216
14. Schinkel AFL, Bax JJ, Geleijnse ML, et al. Noninvasive evaluation of ischaemic heart disease: myocardial perfusion imaging or stress echocardiography? *Eur Heart J.* 2003; 24:789-800. [https://doi.org/10.1016/S0195-668X\(02\)00634-6](https://doi.org/10.1016/S0195-668X(02)00634-6)
15. Bax JJ, Poldermans D, Elhendy A, Boersma E, Rahimtoola SH. Sensitivity, specificity, and predictive accuracies of various noninvasive techniques for detecting hibernating myocardium. *Curr Probl Cardiol.* 2001; 26:147. <https://doi.org/10.1067/mcd.2001.109973> PMID:11276916
16. Elfigh IA, Henein MY. Non-invasive imaging in detecting myocardial viability: Myocardial function versus perfusion. *IJC Heart & Vasculature.* 2014; 5:51-6. <https://doi.org/10.1016/j.ijcha.2014.10.008> PMID:28785612 PMCid:PMC5497170
17. Pellikka et al. American Society of Echocardiography Recommendations for Performance, Interpretation, and Application of Stress Echocardiography. *Journal of the American Society of Echocardiography.* 2007. <https://doi.org/10.1016/j.echo.2007.07.003>
18. H Becher, J Chambers, K Fox, et al. BSE procedure guidelines for the clinical application of stress echocardiography, recommendations for performance and report of the British Society of interpretation of stress echocardiography: An Echocardiography Policy Committee. *Heart.* 2004; 90:vi23-vi30. <https://doi.org/10.1136/hrt.2004.047985>
19. Sicari R, Nihoyannopoulos P, Evangelista A, Kasprzak J, Lancellotti P, Poldermans D, Voigt JU, Zamorano JL. Stress echocardiography expert consensus statement-executive summary: european association of echocardiography (a registered branch of the ESC). *European heart journal.* 2009; 30(3):278-89. <https://doi.org/10.1093/eurheartj/ehn492> PMID:19001473
20. Henzlova MJ, Cerqueira MD, Hansen CL, et al. ASNC Imaging Guidelines for Nuclear cardiology Procedures: Stress protocols and tracers. *J. Nucl. Cardiol.* 2009; 16:331. <https://doi.org/10.1007/s12350-009-9062-4>
21. Allman KC. Noninvasive assessment myocardial viability: Current status and future directions. *Journal of Nuclear Cardiology.* 2013; 20(4): 616-7. <https://doi.org/10.1007/s12350-013-9748-5>
22. Husain SS. Myocardial Perfusion Imaging Protocols: Is There an Ideal Protocol?. *J Nucl Med Technol.* 2007; 35(1):3-9.
23. Cerqueira MD, Weissman NJ, Dilsizian V, Jacobs AK, et al. Standardized myocardial segmentation and nomenclature for tomographic imaging of the heart. *Circulation.* 2002; 1054:539-542. <https://doi.org/10.1161/hc0402.102975>
24. Yoshinaga K, Morita K, Yamada S, et al. Low-dose dobutamine electrocardiograph-gated myocardial SPECT for identifying viable myocardium: comparison with dobutamine stress echocardiography and PET. *Journal of nuclear medicine: official publication. Society of Nuclear Medicine.* 2001; 42:838-844.
25. Javadi H, Porpiranfar MA, Semnani S et al. Scintigraphic parameters with emphasis on perfusion appraisal in rest 99mTc-sestamibi SPECT in the recovery of myocardial function after thrombolytic therapy in patients with ST elevation myocardial infarction (STEMI). *Perfusion.* 2011; 26: 394-399. <https://doi.org/10.1177/0267659111409970> PMID:21593086
26. Panza JA, Dilsizian V, Laurienzo JM, Curiel RV, Katsiyannis PT. Relation between thallium uptake and contractile response to dobutamine: implications regarding myocardial viability in patients with chronic coronary artery disease and left ventricular dysfunction. *Circulation.* 1995; 91:990-998. <https://doi.org/10.1161/01.CIR.91.4.990> PMID:7850986
27. Bax JJ, Poldermans D, Schinkel AFL, et al. Perfusion and contractile reserve in chronic dysfunctional myocardium: relation to functional outcome after surgical revascularization. *Circulation.* 2002; 106(suppl 1):114-118.
28. Mina Taghizadeh Asl et al. Comparison of stress dobutamine echocardiography and stress dobutamine gated myocardial SPECT for the detection of viable myocardium. *Nuclear Medicine Review.* 2014; 17(1):18-25. <https://doi.org/10.5603/NMR.2014.0005> PMID:24610648
29. Plana JC, Mikati IA, Dokainish H, Lakkis N, Abukhalil J, Davis R, et al. A randomized cross-over study for evaluation of the effect of image optimization with contrast on the diagnostic accuracy of dobutamine echocardiography in coronary artery disease: the OPTIMIZE trial. *J Am Coll Cardiol Img.* 2008; 1:145-52. <https://doi.org/10.1016/j.icmq.2007.10.014> PMID:19356420
30. Bax JJ, Poldermans D, Schinkel AFL, et al. Perfusion and contractile reserve in chronic dysfunctional myocardium: relation to functional outcome after surgical revascularization. *Circulation.* 2002; 106(suppl 1):114-118.
31. Armstrong WF. "Hibernating" myocardium: asleep or part dead? *J Am Coll Cardiol.* 1996; 28:530-535. [https://doi.org/10.1016/0735-1097\(96\)00138-6](https://doi.org/10.1016/0735-1097(96)00138-6)
32. Main ML, Goldman JH, Grayburn PA. Thinking outside the 'box'-the ultrasound contrast controversy. *J Am Coll Cardiol.* 2007; 18:2434-7. <https://doi.org/10.1016/j.jacc.2007.11.006> PMID:18154971