

Received: 2018.12.21

Accepted: 2019.02.26

Published: 2019.06.12

A Computed Tomography Study of the Association Between Increased Patellar Tilt Angle and Femoral Anteversion in 30 Patients with Recurrent Patellar Dislocation

Authors' Contribution:

Study Design A

Data Collection B

Statistical Analysis C

Data Interpretation D

Manuscript Preparation E

Literature Search F

Funds Collection G

AE **Huijun Kang**
BC **Conglei Dong**
BC **Gengshuang Tian**
ADG **Fei Wang**

Department of Joint Surgery, Third Hospital of Hebei Medical University, Shijiazhuang, Hebei, P.R. China

Corresponding Author: Fei Wang, e-mail: doctorwf@yeah.net
Source of support: Departmental sources

Background: Increased femoral anteversion (FA) has been demonstrated in patients with recurrent patellar dislocation (RPD). However, the effect of FA on the patellar tilt angle (PTA) in patients with RPD is unclear. The aim of this study was to compare the FA and PTA between patients with RPD and healthy controls and to investigate the relationship between FA and PTA.

Material/Methods: A total of 30 knees with RPD and 30 knees from healthy volunteers were evaluated with computed tomography (CT). The FA and PTA were measured and compared between the RPD and control groups. Correlations between the two parameters were assessed in the two groups.

Results: The FA was $27.7 \pm 6.8^\circ$ for the RPD group compared with $17.3 \pm 9.0^\circ$ for the control group ($P=0.000$), and the PTA was $29.0 \pm 7.1^\circ$ for the RPD group compared with $14.8 \pm 8.4^\circ$ for the control group ($P=0.000$). A positive correlation was found between these two parameters in the RPD group ($r=0.464$; $P=0.010$). Further analysis showed a significant correlation with a FA of $\geq 25^\circ$ in the RPD group ($r=0.709$; $P=0.001$), but no correlation was found with the control group.

Conclusions: A significantly higher FA and PTA were found in patients with RPD compared with controls. An increased PTA and a FA $\geq 25^\circ$ were significantly associated with RPD. A derotational femoral osteotomy may be indicated to correct patellar tilt in patients with RPD when femoral anteversion is $\geq 25^\circ$.

MeSH Keywords: **Bone Anteversion • Knee Dislocation • Osteotomy • Patellar Dislocation**

Full-text PDF: <https://www.medscimonit.com/abstract/index/idArt/914747>

 2636

 4

 3

 23



Background

Patellar tilt is a common pattern of patellar malalignment in patients with recurrent patellar dislocation (RPD). Generally, lateral retinaculum with excessive stress can lead to increased lateral patellar tilt, abnormal contact of the lateral surface of patella against the trochlea, and pathological patellar tracking [1]. If the patellar tilt is $>20^\circ$ and the patella cannot be everted to neutral on examination, a lateral retinacular release may be indicated to correct the lateral inclination [2]. However, a recent systematic review has shown a mean satisfaction rate of 80% after lateral retinacular release with a follow-up period of less than four years, which decreased to 63.5% when assessed for a longer period [3]. Many factors such as medial patellofemoral ligament injury, trochlear dysplasia, elevated tibial tubercle-trochlear groove (TT-TG) distance, and patella alta, contribute to patellar dislocation. Therefore, lateral retinacular release has been performed in combination with other procedures, such as medial patellofemoral ligament reconstruction, trochleoplasty, and tibial tubercle transfer to treat patellar dislocation [2].

Rotational malalignment has been underestimated so far in patients with patellar dislocation [4]. Many previous studies have observed an increase of femoral anteversion in patients with RPD compared to healthy controls [4–8]. However, few studies have focused on the effect of femoral anteversion on the patellar tilt, and results were controversial [9,10]. Yildirim et al. reported no significant differences in patellar tilt angle (PTA) between the operated leg (antegrade intramedullary nailing for femoral shaft fracture) and contralateral healthy legs, with a mean increase of femoral anteversion (FA) of 9.1° (range $1\text{--}25^\circ$) [9]. However, in a biomechanical study that included eight fresh-frozen cadaver knees, Kaiser et al. found that lateral patellar tilt significantly increased at 10° and 20° of increased internal femoral torsion with or without a native medial patellofemoral ligament [10].

It remains unclear whether there is a relationship between femoral anteversion and patellar tilt, and whether PTA could be considered to be a factor in the decision to perform derotational osteotomy in patients of RPD with patellar tilt. To the best of our knowledge, no previous study has investigated the potential relationship between these two parameters in patients with RPD.

Therefore, the aim of this study was to compare the FA and PTA between patients with RPD and healthy controls and to investigate the relationship between these two parameters. The hypothesis that drove this study was that patients with RPD might have higher values of FA and PTA than healthy controls and that an increased PTA could be associated with an increased FA in patients with RPD.

Material and Methods

Study groups

A total of 30 knees from 30 patients with recurrent patellar dislocation (RPD) (average age, 20.1 years) were included in this study. The inclusion criteria were a previous history of two or more episodes of patellar dislocation, a history of one or more physical sign, including dislocation of the patella, fracture of medial patellar facet or lateral femoral condyle, or injuries of the medial stabilizers on radiographs or magnetic resonance imaging (MRI). Exclusion criteria were a history of previous surgery, a history of general ligament laxity, a history of other injuries of the knee, direct-trauma dislocation, and habitual patellar dislocation.

The control group consisted of 30 knees from 30 patients with meniscal injury, with an average age of 22.6 years. The computed tomography (CT) scans of the contralateral healthy limb were included as the controls. The exclusion criteria were any lower limb disorders that may affect alignment.

This study was approved by Hebei Medical University Institutional Review Board (IRB) (Approval No. 2018-H06-01) and informed consent was obtained from all participants. The demographic data showed no significant difference between the RPD group and the control group and are presented in Table 1.

Computed tomography (CT) scans

The computed tomography (CT) imaging of the knee was performed using a standard imaging technique using a Philips CT Secura (Philips Medical Systems, The Netherlands). Each subject was placed in the supine position, and the knee was in full or near full extension. A specially made thick and hollow rectangular foam support was used to stabilize the ankle and maintain the plantar surface of the foot in a vertical position. The levels of the femoral neck, patella, and femoral condyles were determined, and 5 mm sections were taken at these points while in the supine position.

CT images were stored using the picture archiving and communication system (PACS) Digital Imaging and Communications in Medicine (DICOM). Measurements on the CT sections were performed using RadiAnt-DICOM software (Medixant Ltd., Poznań, Poland), using a mouse cursor with automated distance or angle calculation. Two orthopedic surgeons reviewed all images. To determine the interobserver and intraobserver reliability of the measurement, intraclass correlation coefficients (ICCs) were calculated by randomly selecting 20 patients (10 from the RPD group and 10 from control group). Two of the authors independently measured the degree of FA. Also, one independent observer performed all the above measurements twice, two

Table 1. Patient characteristics show that no statistical difference was found between the recurrent patellar dislocation (RPD) group and the control group.

Parameter	RPD group	Control group	Statistics value	P value
Sex, male/female, n	3/27	5/25	$\chi^2=0.577$	0.448
Side, left/right, n	12/18	17/13	$\chi^2=1.669$	0.196
Age at time of surgery, y	20.1±5.6	22.6±7.3	Z=-1.393	0.164
Height, cm	165.4±6.5	167.1±4.8	t=-1.158	0.252
Weight, kg	65.6±13.5	67.4±10.5	Z=-0.915	0.360

No statistical difference was noted between the two groups.

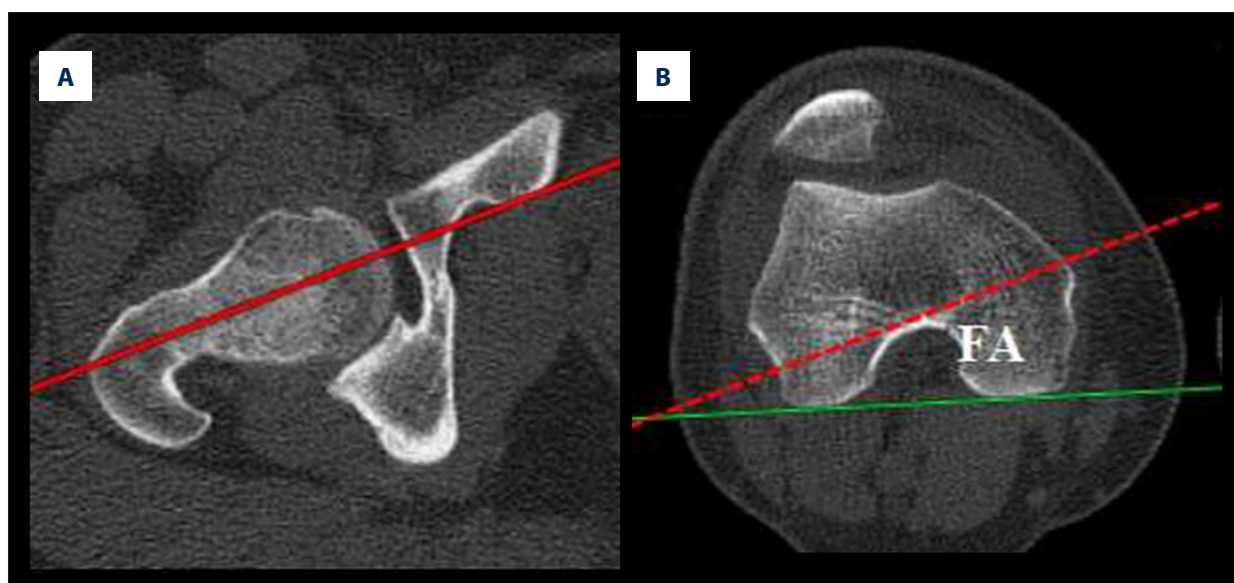


Figure 1. (A, B) The measurement of the femoral anteversion (FA), defined as the angle formed between the axis of the middle femoral neck and the axis of the posterior distal femur.

weeks apart. The interobserver and intra-observer ICCs were 0.905 (95% CI, 0.777–0.961) and 0.972 (95% CI, 0.929–0.989) for the measurements, respectively.

Assessment of femoral anteversion (FA) and the patellar tilt angle (PTA)

Femoral anteversion (FA) was defined as the angle formed between the middle femoral neck axis and the posterior distal femoral axis (Figure 1) [4,6–8]. Briefly, the points of the center of the femoral head and the mid-femoral neck were identified in the transverse plane. The line connecting the center of the femoral head and the mid-femoral neck was the middle femoral neck axis. The posterior distal femoral axis was defined by a line running through the most posterior points of the medial and lateral femoral condyles. Positive degrees indicated femoral antetorsion and negative values indicated femoral retortorsion [4,6–8].

The patellar tilt angle (PTA) was measured as the angle subtended between the widest patellar axis and posterior distal femur axis (Figure 2) [7,11]. The slice with the widest patella was selected, and the line drawn across the patella from its medial to lateral border was the widest patellar axis. The posterior distal femur axis was defined by a line running through the most posterior points of the medial and lateral femoral condyles. Positive degrees indicate lateral patellar tilt and negative values indicated medial tilt [7,11].

Statistical analysis

Before the study began, the sample size was estimated using the femoral anteversion as the primary variable. From previous studies [4–8], the standard deviation (SD) was assumed as 12° in the RPD group and as 10° in the normal group, with an estimated difference of 10° between the groups. A power calculation was performed with a confidence level of 95% ($\alpha=0.05$)

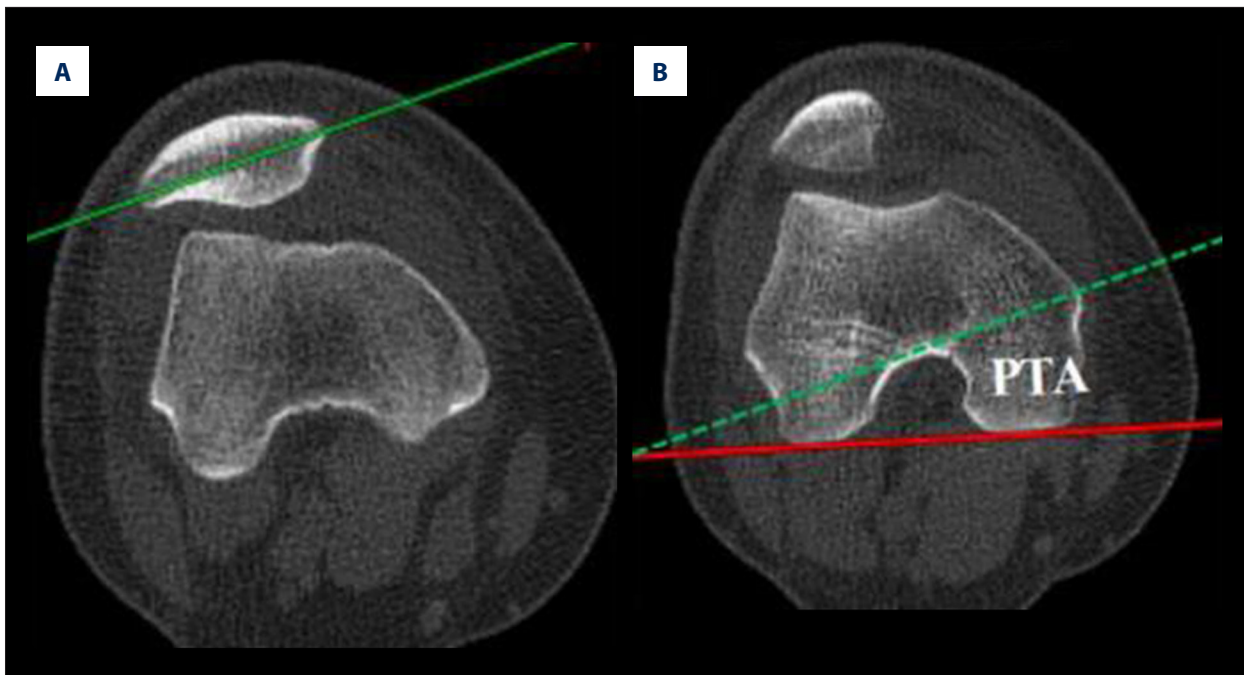


Figure 2. (A, B) The measurement of the patellar tilt angle (PTA), defined as the angle subtended between the widest patellar axis and the axis of the posterior distal femur.

Table 2. Computed tomography (CT) imaging measurements show that femoral anteversion (FA) and patellar tilt angle (PTA) were significantly greater in the recurrent patellar dislocation (RPD) group than the control group.

Parameter	RPD group	Control group	Statistics value	P value
All the cases	30	30	–	–
Femoral anteversion, deg	27.7±6.8	17.3±9.0	t=5.064	.000
Patellar tilt angle, deg	29.0±7.1	14.8±8.4	t=7.046	.000
Cases with FA ≥25°	17	8	–	–
Femoral anteversion, deg	32.5±4.6	28.2±5.3	Z=-2.798	.005
Patellar tilt angle, deg	30.1±8.4	19.6±8.1	t=2.953	.007
Cases with FA <25°	13	22	–	–
Femoral anteversion, deg	21.3±2.2	13.3±6.3	Z=-3.705	.000
Patellar tilt angle, deg	27.4±5.0	13.0±8.0	t=5.853	.000

The femoral anteversion and patellar tilt angle were significantly higher in the RPD group than that in the control group. FA – femoral anteversion.

and a power (1-b) of 90%, which yielded an estimated sample size of 26 patients per group.

The mean and standard deviation (SD) were calculated for all of the parameters and compared between the RPD and control groups by unpaired t-tests. The associations between these two parameters were calculated using Pearson's correlation coefficient. Statistical analysis was performed using SPSS version 23.0 software (SPSS Inc, Chicago, Illinois). The level of significance was $P < 0.05$.

Results

The femoral anteversion (FA) and patellar tilt angle (PTA) were significantly different between the recurrent patellar dislocation (RPD) group and the control group. The FA was $27.7 \pm 6.8^\circ$ for the RPD group compared with $17.3 \pm 9.0^\circ$ for the control group ($P = 0.000$). The PTA was $29.0 \pm 7.1^\circ$ for the RPD group compared with $14.8 \pm 8.4^\circ$ for the control group (Table 2) ($P = 0.000$).

Table 3. Correlation analysis of the results of the femoral anteversion (FA) and patellar tilt angle (PTA) in the recurrent patellar dislocation (RPD) group and the control group.

Parameter	RPD group		Control group	
	Coefficient	P value	Coefficient	P value
All cases	0.464	0.010	0.267	0.154
Cases with FA $\geq 25^\circ$	0.709	0.001	-0.379	0.354
Cases with FA $< 25^\circ$	-0.061	0.843	0.112	0.621

A positive correlation was found between the femoral anteversion (FA) and patellar tilt angle (PTA) in the recurrent patellar dislocation (RPD) group, and a significant correlation was found when the femoral anteversion was $\geq 25^\circ$ in the RPD group.

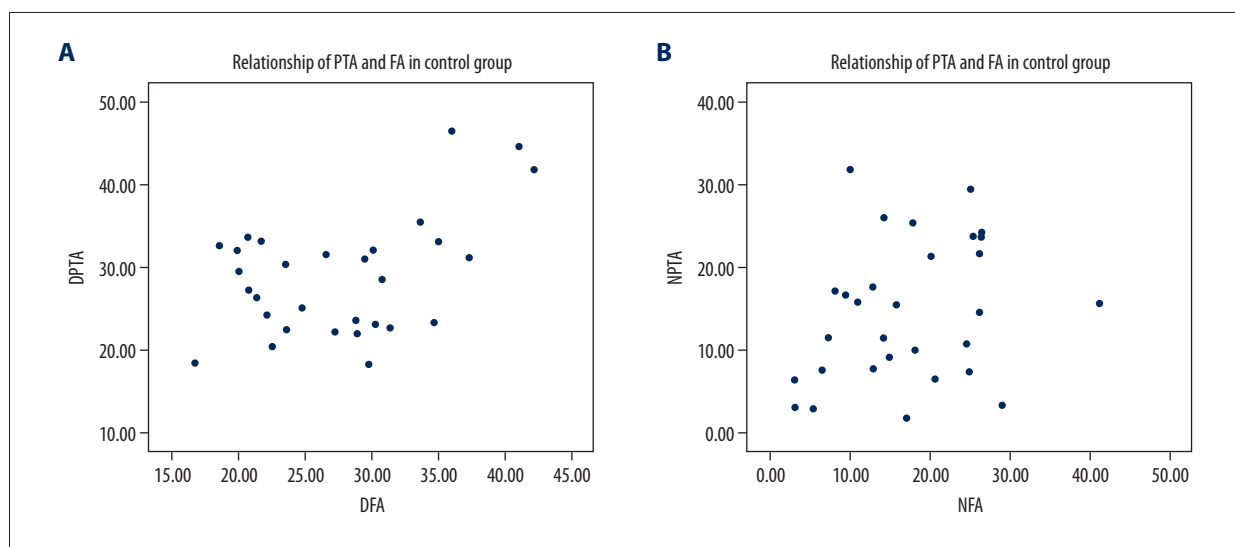


Figure 3. Scatter plot shows the relationship between patellar tilt angle (PTA) and the femoral anteversion (FA). Patient data shown are from the recurrent patellar dislocation (RPD) group (A) and the control group (B).

In a further analysis with the FA cutoff value of 25° , which was the recommended degree for surgery of derotational femoral osteotomy reported in the literature [12,13], 17 cases and 8 cases had a FA of $\geq 25^\circ$ in the RPD group and control group, respectively. Whether the FA was of $\geq 25^\circ$ or $< 25^\circ$, significantly higher values were found in FA and PTA in the RPD group compared with the control group (Table 2).

Regarding the possible relationship between FA and PTA, a positive correlation was found between these two parameters in the RPD group ($r=0.464$; $P=0.010$), but no correlation was noted in the control group. In the further analysis with the FA cutoff value of 25° , there was a significant correlation between these two parameters when the FA was $\geq 25^\circ$ in the RPD group ($r=0.709$; $P=0.001$), but no correlation was found in the control group. When the FA was $< 25^\circ$, no linear correlations were found between these two parameters (Table 3, Figure 3).

Discussion

The most important finding of the present study was that a significantly higher femoral anteversion (FA) and patellar tilt angle (PTA) was found in patients with recurrent patellar dislocation (RPD) compared with normal controls. There was a significant correlation between the PTA and FA when the FA was $\geq 25^\circ$ in patients with RPD. Therefore, a derotational femoral osteotomy might be indicated to correct patellar tilt when femoral anteversion is $\geq 25^\circ$.

A significantly higher FA was found in patients with RPD compared with controls in the present study. In the literature, there have been several previously reported studies on the relationship between patellar dislocation and measurements of FA, which are shown in Table 4 [4–8,14]. The present study also showed a significant increase in PTA in patients with RPD compared with controls. Therefore, the degree of patellar tilt should also be considered in patients with RPD. Prakash et al. reported a PTA of $29.1 \pm 8.1^\circ$ in 48 patients with patellar dislocation and

Table 4. Results of the literature review of the measurement of femoral anteversion (FA).

The study	Modality	RPD group	Control group
Diederrichs [4]	MRI	20.3°±10.4°	13.0°±8.4°
Dejour [5]	CT	15.6°±9.0°	10.8°±8.7°
Erkocak [6]	CT	14.7°±4.3°	11.6°±3.5°
Prakash [7]	CT	19.2°±10.4°	12.0°±8.4°
Takagi [8]	3D-CT	30.9°±9.6°	17.0°±8.4°
Takai [14]	CT	30.1°±13.9°	21.7°±11.6°
Present study	CT	27.7°±6.8°	17.3°±9.0°

5.8±3.8° in 87 healthy controls [7]. Using three-dimensional computed tomography (CT) models, Yamada et al. measured 60 knees with RPD and reported the PTA of 22.7±8.8° compared with 6.8±6.6° in the healthy volunteers [11]. In the present study, the PTA was 29.0±7.1° for the RPD group compared with 14.8±8.4° for the control group. These results were similar to those reported in previous studies.

In healthy individuals, the patellar position and orientation were simultaneously controlled by the bony congruence and the balance of soft tissue around the patella [15]. Due to the normal medial stabilizer, the patella will remain stable within the trochlea. In the present study, no significant correlations between the FA and PTA were found in the control group. In a previous study, Reikerås found no association between increased femoral anteversion and abnormal patellofemoral characteristics in patients without specific symptoms of anterior knee pain or patellar instability [16].

In the RPD group, the PTA was significantly increased when compared with controls. When the FA was <25°, no linear association was found between the two parameters of the PTA and FA. In the investigation of 20 patients with internal rotational deformity of distal femur (increase in femoral anteversion) after the surgical treatment for femoral fracture, Yildirim et al. also reported no significant differences in the PTA between the operated leg and contralateral normal leg when the mean increase in FA was 9.1° (range, 1–25°) [9]. However, with the same femoral internal torsion, in a biomechanical study that tested eight fresh-frozen cadaver knees, Kaiser et al. observed that lateral patellar tilt increased significantly after the transection of the medial patellofemoral ligament compared with native medial patellofemoral ligament [10]. Therefore, the medial soft tissue may have more influence on the patellar tilt in patients of RPD with a relatively low FA. In the patients with RPD, medial soft tissue, especially when the medial patellofemoral ligament is torn [17], the medial soft tissue repair or reconstruction may be the primary choice of treatment.

In the present study, in the RPD group, a significant correlation between the PTA and FA was found when the FA was ≥25°. In the clinical setting, these two parameters could be easily measured on the transverse CT images, with the same reference line used of the posterior femoral condyles, and similar direction of lateral inclination. Previous biomechanical findings support that an increased internal torsion produces a laterally directed force vector acting on the patella, which may facilitate patellar tilt and even patellar dislocation [12,18]. In a biomechanical study, specimens with a transected medial patellofemoral ligament, which represents patients with RPD with insufficient medial restraint showed similar facilitating effect with that of 10° of increased internal torsion [10]. Beyond this degree, this facilitating effect on patellar tilt increased with an increase of internal torsion, as showed the linear relationship between these two parameters when the FA was ≥25° in the RPD group [19]. Generally, an absolute femoral anteversion of 15–25° represents 5–10° of relative increased internal torsion above the normal value [19]. Biomechanical results showed that medial patellofemoral ligament reconstruction as an isolated therapy only appears to be reasonable for 10° increased internal torsion [19]. With greater internal torsion, a lateralizing force vector remains, and an additional femoral derotational osteotomy is recommended. In clinical practice, some authors also proposed the absolute values of 15–25° of internal femoral torsion to perform the derotational osteotomy in patients with RPD [12,13].

A survey of the international patellofemoral experts showed that lateral retinacular release was performed in <2% of their surgical cases [20]. In a prospective study, Pagenstert et al. found that retinacular lengthening showed less medial instability, quadriceps atrophy, and a better clinical outcome at two years compared with the lateral retinacular release [21]. Retinacular lengthening can preserve muscular attachments, and allows muscle strengthening and dynamic stabilization, but simple division of the lateral patellar structures may result in muscular retraction and lack of dynamic stabilization [21]. With concomitant medial patellofemoral ligament reconstruction, Liu et al. reported that lateral retinaculum plasty yielded better clinical results than lateral retinacular release in the management of RPD [22]. Retinacular lengthening or plasty could be a successful alternative instead of lateral retinacular release to treat patients with RPD.

The implications for knee surgery are that the assessment of patellar tilt in patients with RPD is important in clinical practice because the choice of surgical treatment should be dependent on femoral anteversion values. A detailed clinical algorithm has been created according to the various risk factors to manage RPD [2]. Generally, patellar tilt should be addressed when the PTA is >20° and the patella cannot be everted to neutral on examination. By analysis of the relationship of PTA

and FA in patients with RPD, a more patient-specific treatment strategy should be developed. The medial soft tissue may have more influence on the patellar tilt in patients with a relatively low FA. A significant correlation was demonstrated in the present study between the PTA and FA when the FA was $\geq 25^\circ$ in patients with RPD. Therefore, medial patellofemoral ligament reconstruction is a primary surgical option to correct patellar tilt when the FA is $< 25^\circ$, and when the FA is $\geq 25^\circ$, an additional derotational femoral osteotomy may be indicated with medial patellofemoral ligament reconstruction.

The present study had several limitations. First, a dynamic study on patellar tilt was not performed, which may be important for future studies, as motion may alter anatomic relationships. However, dislocations in patients with RPD mostly occur towards the end of extension, which is quite different from recurrent patellar dislocation which the dislocation occurs mainly during flexion [23]. Patellar motion, which is commonly evaluated with patellar tilt and lateral shift, was only measured with patellar tilt. A previously reported *in vivo* study showed that

patellar shift and tilt were moderately or strongly correlated in 95% of patients with RPD and that it was not necessary to use both parameters to evaluate patellar alignment [11]. Finally, the possible effects of other factors such as severity of soft tissue damage were not evaluated in this study.

Conclusions

Significantly increased femoral anteversion (FA) and patellar tilt angle (PTA) were found in patients with recurrent patellar dislocation (RPD) compared with controls. A significant correlation was found between an increased PTA and an increased FA of $\geq 25^\circ$ in patients with RPD. A derotational femoral osteotomy may be indicated to correct patellar tilt in patients with RPD when the FA is $\geq 25^\circ$.

Conflict of interest

None.

References:

- Christoforakis J, Bull AM, Strachan R et al: Effects of lateral retinacular release on the lateral stability of the patella. *Knee Surg Sports Traumatol Arthrosc*, 2006; 14(3): 273–77
- Weber AE, Nathani A, Dines JS et al: An algorithmic approach to the management of recurrent lateral patellar dislocation. *J Bone Joint Surg Am*, 2016; 98(5): 417–27
- Lattermann C, Toth J, Bach BR Jr.: The role of lateral retinacular release in the treatment of patellar instability. *Sports Med Arthrosc*, 2007; 15(2): 57–60
- Diederichs G, Kohlz T, Kornaropoulos E et al: Magnetic resonance imaging analysis of rotational alignment in patients with patellar dislocations. *Am J Sports Med*, 2013; 41: 51–57
- Dejour H, Walch G, Nove-Josserand L, Guier C: Factors of patellar instability: An anatomic radiographic study. *Knee Surg Sports Traumatol Arthrosc*, 1994; 2: 19–26
- Erkokoc OF, Altan E, Altintas M et al: Lower extremity rotational deformities and patellofemoral alignment parameters in patients with anterior knee pain. *Knee Surg Sports Traumatol Arthrosc*, 2016; 24: 3011–20
- Prakash J, Seon JK, Woo SH et al: Comparison of radiological parameters between normal and patellar dislocation groups in the Korean population: A rotational profile CT-based study. *Knee Surg Relat Res*, 2016; 28: 302–11
- Takagi S, Sato T, Watanabe S et al: Alignment in the transverse plane, but not sagittal or coronal plane, affects the risk of recurrent patella dislocation. *Knee Surg Sports Traumatol Arthrosc*, 2018; 26(10): 2891–98
- Yildirim AO, Aksahin E, Sakman B et al: The effect of rotational deformity on patellofemoral parameters following the treatment of femoral shaft fracture. *Arch Orthop Trauma Surg*, 2013; 133(5): 641–48
- Kaiser P, Schmoelz W, Schoettle P et al: Increased internal femoral torsion can be regarded as a risk factor for patellar instability – a biomechanical study. *Clin Biomech*, 2017; 47: 103–9
- Yamada Y, Toritsuka Y, Nakamura N et al: Correlation of 3D shift and 3D tilt of the patella in patients with recurrent dislocation of the patella and healthy volunteers: An *in vivo* analysis based on 3-dimensional computer models. *Am J Sports Med*, 2017; 45(13): 3111–18
- Teitge RA: Osteotomy in the treatment of patellofemoral instability. In: *Techniques in Knee Surgery*, 2006; 5: 2–18
- Hinterwimmer S, Rosenstiel N, Lenich A et al: Femoral osteotomy for patellofemoral instability. *Unfallchirurg*, 2012; 115: 410–16
- Takai S, Sakakida K, Yamashita F et al: Rotational alignment of the lower limb in osteoarthritis of the knee. *Int Orthop*, 1985; 9: 209–15
- Frings J, Krause M, Akoto R, Frosch KH: Clinical results after combined distal femoral osteotomy in patients with patellar maltracking and recurrent dislocations. *J Knee Surg*, 2018 [Epub ahead of print]
- Reikerås O: Patellofemoral characteristics in patients with increased femoral anteversion. *Skeletal Radiol*, 1992; 21(5): 311–13
- Sallay PI, Poggi J, Speer KP, Garrett WE: Acute dislocation of the patella: A correlative pathoanatomic study. *Am J Sports Med*, 1996; 24: 52–60
- Post WR, Teitge R, Amis A: Patellofemoral malalignment: Looking beyond the view box. *Clin Sports Med*, 2002; 21: 521–46
- Kaiser P, Schmoelz W, Schöttle PB et al: Isolated medial patellofemoral ligament reconstruction for patella instability is insufficient for higher degrees of internal femoral torsion. *Knee Surg Sports Traumatol Arthrosc*, 2018. [Epub ahead of print]
- Fithian DC, Paxton EW, Post WR, Panni AS: Lateral retinacular release: A survey of the International Patellofemoral Study Group. *Arthroscopy*, 2004; 20(5): 463–68
- Pagenstert G, Wolf N, Bachmann M et al: Open lateral patellar retinacular lengthening versus open retinacular release in lateral patellar hypercompression syndrome: A prospective double-blinded comparative study on complications and outcome. *Arthroscopy*, 2012; 28(6): 788–97
- Liu C, Duan G, Niu Y et al: Lateral retinaculum plasty instead of lateral retinacular release with concomitant medial patellofemoral ligament reconstruction can achieve better results for patellar dislocation. *Knee Surg Sports Traumatol Arthrosc*, 2018; 26(10): 2899–905
- Batra S: Recurrent dislocation is different from habitual dislocation of the patella. *Int Orthop*, 2014; 38(10): 2223