



Case Report

The Oxinium Arthrogram: A Sign of Oxidized Zirconium Implant Failure

Benjamin M. Frye, MD^{*}, Kelsey R. Laughery, PA-C, Adam E. Klein, MD

Department of Orthopaedics, West Virginia University, Morgantown, WV, USA

ARTICLE INFO

Article history:

Received 7 January 2021
 Received in revised form
 2 February 2021
 Accepted 6 February 2021
 Available online xxx

Keywords:

Oxinium
 Oxidized zirconium
 Metallosis
 Arthrogram
 Total knee arthroplasty
 Total hip arthroplasty

ABSTRACT

Oxinium implants are composed of a zirconium alloy with a hard ceramic surface formed by oxidization of the outer layer. This material has been shown to be an effective bearing surface for total joint arthroplasty and an alternative material for use in patients with metal hypersensitivity. Reports exist of metallosis due to unintended wear of Oxinium components from multiple mechanisms including polyethylene liner dissociation and joint instability. This metallosis creates a distinct appearance on radiographic imaging similar to that of an arthrogram. We report 2 cases of metallosis and describe the characteristic radiographic appearance of failed oxidized zirconium implants.

© 2021 The Authors. Published by Elsevier Inc. on behalf of The American Association of Hip and Knee Surgeons. This is an open access article under the CC BY-NC-ND license (<http://creativecommons.org/licenses/by-nc-nd/4.0/>).

Introduction

Oxidized zirconium implants (Oxinium; Smith and Nephew, Memphis, TN) were developed to potentially improve the longevity of total hip (THA) and total knee (TKA) arthroplasty implants by reducing polyethylene wear [1,2]. Another potential benefit has been their use in patients with reported metal allergy [3–5]. These implants have shown midterm survivorship comparable with that of more traditional implants [6–8]. Oxidized zirconium is scientifically described as a metallic alloy of zirconium with a ceramic surface that is a transformation of the metal substrate [9–11]. This transformation is a result of oxygen diffusion into the zirconium when heated, thus forming a zirconium oxide (zirconia) ceramic layer. This material has a hardness greater than that of cobalt-chromium, and the underlying alloy is less brittle than ceramic. The zirconia layer is often incorrectly described as a “coating.”

Adverse local tissue reactions (ALTRs) and metallosis have been observed with metal-on-metal total hip replacements, corrosion at modular junctions, and polyethylene wear-through [12–16]. Metal debris within the prosthetic joint from these mechanisms is not

always readily visible on plain radiographs, but rather may have a subtle cloudy appearance with longstanding wear [15].

We present one case each of a failed THA and TKA in which there was unintended articulation of an oxidized zirconium femoral component against a titanium acetabular and tibial component. This wear resulted in massive synovial deposits of oxidized zirconium whose appearance on plain radiographs was similar to that of an arthrogram. These patients were referred to our facility because of the catastrophic failure and alarming radiographic finding previously unseen by the referring surgeons. The purpose of this report is to help surgeons recognize failure of oxidized zirconium implants should they encounter this rare presentation. Both patients gave consent to include their history and images.

Case histories

Case 1

A 71-year-old female presented to our clinic with a painful right TKA performed 5 years previously at an outside facility. She did well initially and had obtained relief from her arthritic knee pain. She subsequently developed a new pain over the previous year that progressed significantly over several months. In addition to pain, she complained of a progressive bowing deformity of the knee, as well as instability and increased swelling. She was evaluated by her

^{*} Corresponding author. PO Box 9196, Morgantown, WV 26506-9196, USA. Tel.: +1 304 285 7444.

E-mail address: bfrye@hsc.wvu.edu

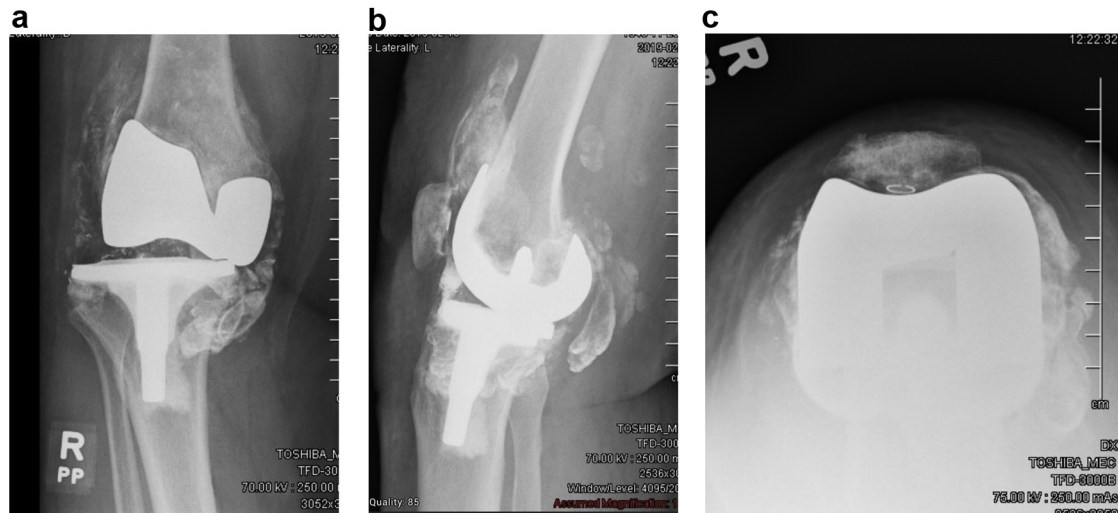


Figure 1. Anteroposterior (a), lateral (b), and sunrise (c) radiographs of a failed oxidized zirconium TKA with resultant Oxinium “arthrogram.”

initial surgeon and was sent to us immediately because of concern for catastrophic failure and an unexplained appearance on her radiographs.

Physical examination revealed a healed surgical incision without erythema or drainage and a large joint effusion. Her resting knee alignment was in about 10 degrees of varus which increased to almost 20 degrees when standing; she demonstrated a varus thrust with ambulation. The resting varus was mostly correctable but resulted in significant palpable and audible crepitus. Knee motion was limited because of pain, but she was able to fully extend and flex to approximately 100 degrees.

Radiographs demonstrated a cemented TKA with complete wear-through of the tibial polyethylene on the medial side of the knee with grooving of the medial femoral condyle and medial subluxation of the femur on the tibia (Fig. 1). The resultant wear had deposited debris in the synovial lining of the joint which

appeared radiographically similar to that of an arthrogram. These synovial deposits were radiographically visible throughout the knee joint, into the suprapatella pouch and the posterior recess of the knee. The femoral component appeared to be well-sized and well-aligned, with no signs of loosening. The tibial component appeared well-sized without signs of loosening; however, it appeared to be in excessive varus. Inflammatory markers revealed an erythrocyte sedimentation rate of 8 mm/h (0–15 mm/h) and C-reactive protein of 10.7 mg/L (0–10 mg/L). Operative records confirmed the use of an Oxinium Legion femoral component (Smith and Nephew, Memphis, TN).

Prosthetic joint infection was deemed unlikely, and her indications for revision surgery were catastrophic wear-through of the polyethylene likely from varus malposition of the tibial component resulting in overall varus malalignment of the entire leg. This malalignment led to increased forces and shear through

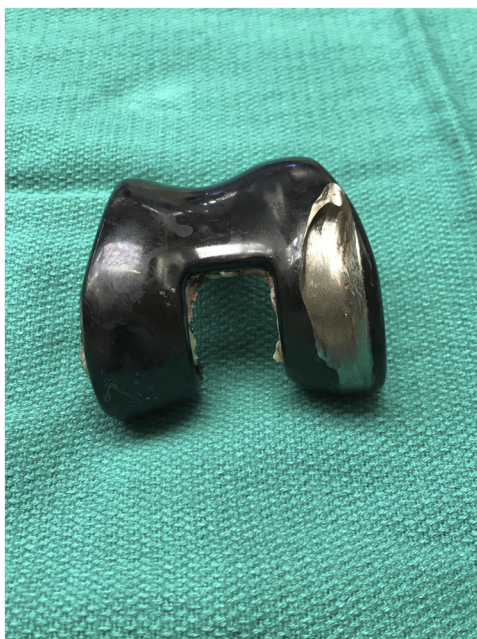

Figure 2. Retrieved femoral component with visible wear, grooving, and exposed underlying zirconium substrate.

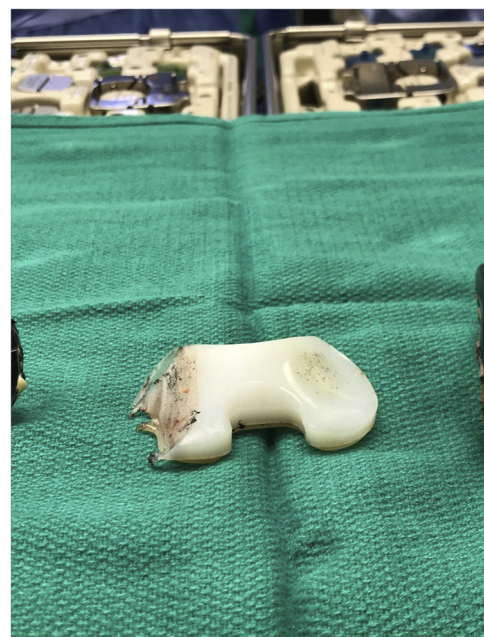


Figure 3. Retrieved polyethylene with evidence of complete wear-through medially.

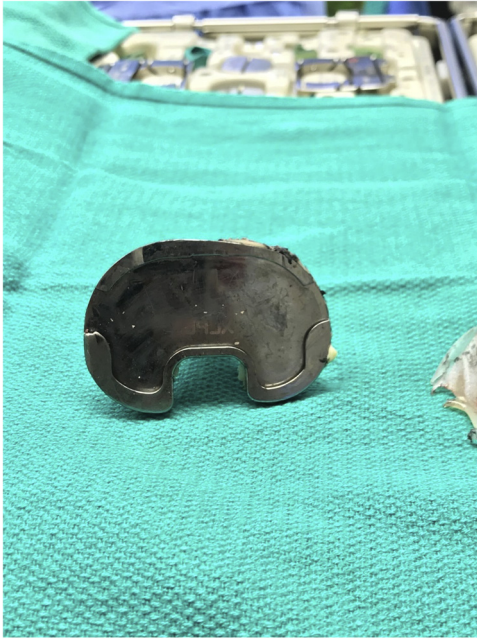

Figure 4. Retrieved tibial component with black staining from oxidized zirconium debris.

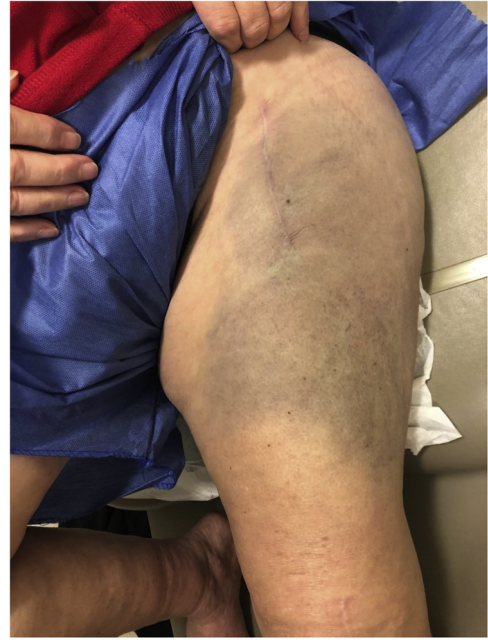

Figure 6. Clinical photograph showing dark skin discoloration in a patient with a failed oxidized zirconium THA with polyethylene liner dissociation.

the medial side of the polyethylene. The resultant arthrogram findings on the radiograph were due to wear and grooving of the oxidized zirconium femoral component against the titanium tibial baseplate.

At the time of revision surgery, the synovial lining of the knee was completely stained black which corresponded to the areas visible on the arthrogram. The femoral component had a large groove worn into the medial condyle which was deep enough to expose a silver metallic appearance, different than the typical black color of Oxinium (Fig. 2). The tibial polyethylene was completely worn-through medially (Fig. 3). The tibial baseplate had minimal thinning of the peripheral locking mechanism but was also stained black so much so that an imprint of “XLPE” from the backside of the polyethylene was visible (Fig. 4). A complete synovectomy was

performed along with revision of both the femoral and tibial components to a constrained condylar knee replacement (Fig. 5). The patient’s recovery was uneventful, and she obtained significant improvement in alignment, stability, pain relief, and function nearly 2 years from revision.

Case 2

A 71-year-old female presented to our clinic with a painful THA performed 8 months previously at an outside facility. She also complained of mechanical popping, grinding, and sensations of hip instability. This instability had contributed to some falls. She was evaluated by her initial surgeon and was sent to us immediately

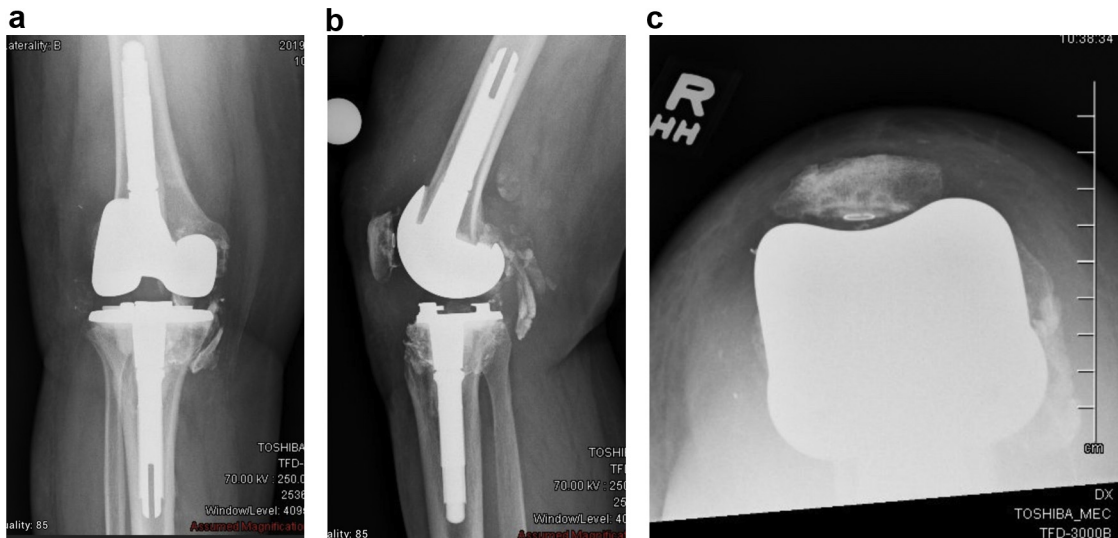


Figure 5. Postoperative anteroposterior (a), lateral (b), and sunrise (c) radiographs after synovectomy and revision to a stemmed, constrained condylar TKA.

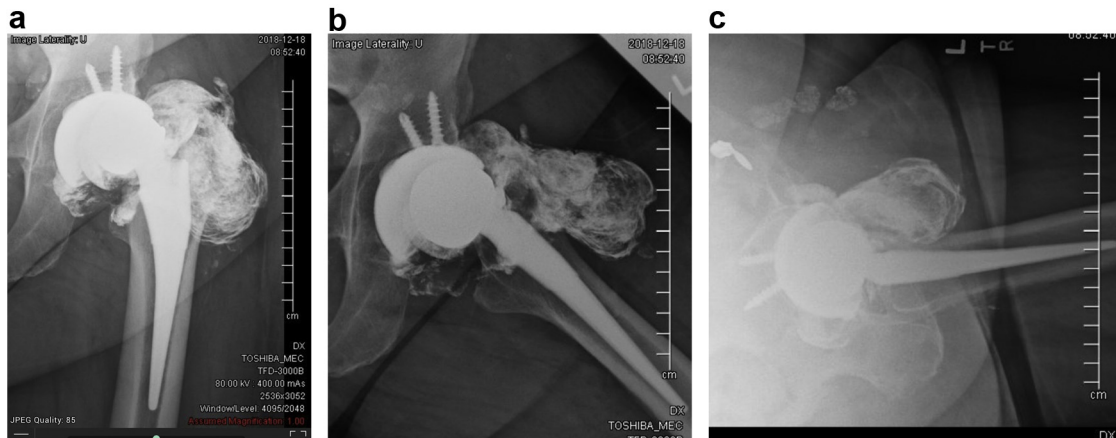


Figure 7. Antero posterior (a), frog lateral (b), and cross-table lateral (c) radiographs of a failed oxidized zirconium THA with polyethylene liner dissociation and resultant Oxinium “arthrogram.”

due to concern for catastrophic failure and an unexplained appearance on her radiographs.

Physical examination showed a well-healed incision from a direct anterior approach surgery without redness or drainage. However, there appeared to be dark discoloration of the entire lateral thigh (Fig. 6). The patient was able to ambulate with a walker and perform a single leg stance on the operative leg. Range of motion of the hip, however, was limited because of pain and significant grinding and popping.

Radiographs demonstrated an R3 acetabular component and Anthology stem (Smith and Nephew, Memphis, TN). Eccentric positioning and deformation of the femoral head within the acetabulum and an associated Oxinium “arthrogram” was visible on multiple views (Fig. 7). The “arthrogram” outlined a dissociated polyethylene liner with direct contact of the deformed femoral head against the superior rim of the acetabular component. The femoral stem and acetabular component appeared to be well-aligned and well-fixed, but the femoral component appeared

undersized. A computed tomography scan redemonstrated the radiographic findings with a large “Oxinium arthrogram” of the surrounding prosthetic joint tissues (Fig. 8). Inflammatory markers revealed an erythrocyte sedimentation rate of 11 mm/h (0–15 mm/h) and a C-reactive protein of 2.4 mg/L (0–10 mg/L). Operative records confirmed the use of an Oxinium femoral head.

Prosthetic joint infection was deemed unlikely, and the indications for revision were catastrophic failure due to a dissociated polyethylene liner with wear and deformation of the oxidized zirconium femoral head. The resultant “arthrogram” findings on the radiograph were attributed to debris from wear and grooving of the oxidized zirconium femoral head against the titanium acetabular component.

At the time of revision surgery via posterior approach, the prosthetic joint tissues beneath the fascia were found to be completely stained black (Fig. 9). The gluteus medius was found to be thin, but in continuity. A large amount of wear and grooving was found on the Oxinium femoral head deep enough to expose a silver

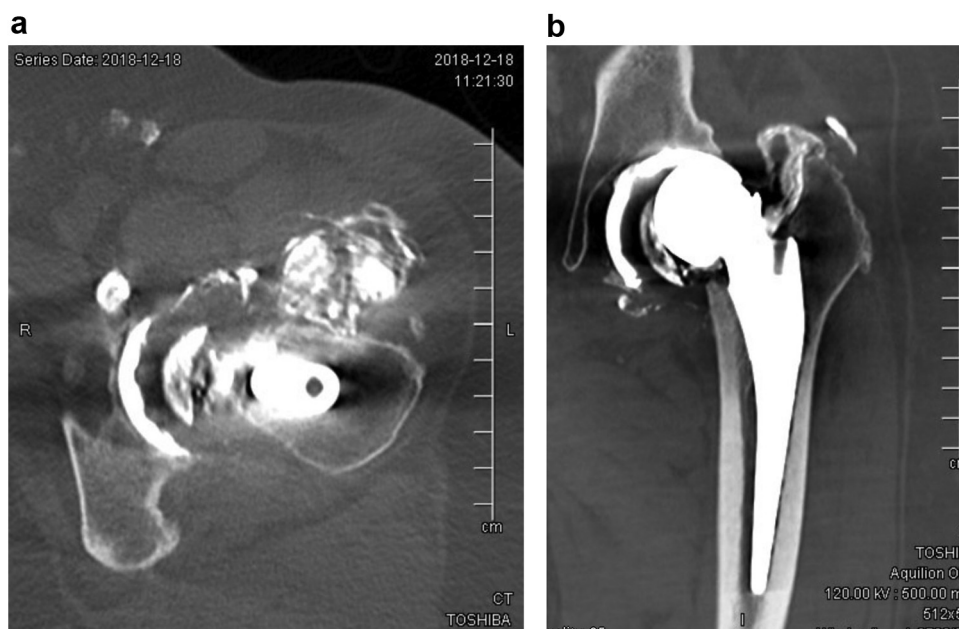


Figure 8. Axial (a) and coronal (b) computed tomography images of a failed oxidized zirconium THA with polyethylene liner dissociation and resultant Oxinium “arthrogram.”

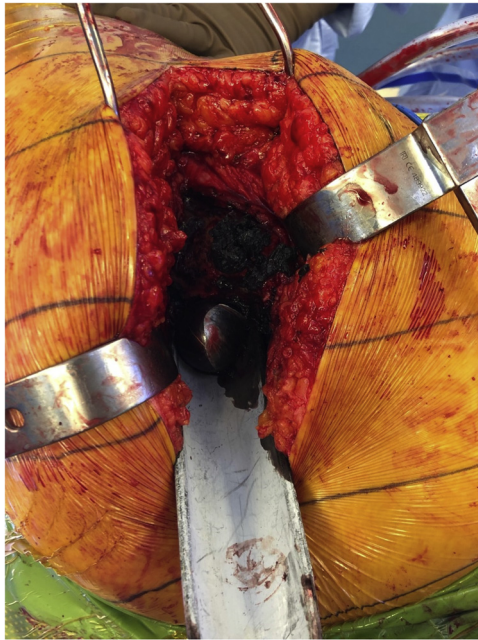


Figure 9. Intraoperative photograph showing metallosis and dark stained tissues from a failed oxidized zirconium THA with polyethylene liner dissociation.

metallic appearance, unlike the black surface of Oxinium (Fig. 10). The polyethylene liner was confirmed to have been dissociated as predicted. Both components were well-fixed to host bone. The retrieved acetabular component showed a small amount of wear on the rim down to the antirotation scallops (Fig. 11). The patient underwent a complete revision of all components (Fig. 12). The patient is 2 years from revision with much improved pain, stability, and function but still complains of some residual pain and weakness. Her lateral thigh discoloration has persisted.

Discussion

These case reports are presented to highlight the radiographic appearance of worn oxidized zirconium. The resultant appearance, similar to that of an arthrogram, can be quite alarming and confusing when first encountered. This “arthrogram” is associated with direct wear of the oxidized zirconium component against a




Figure 10. Retrieved femoral head with visible wear, grooving, and exposed underlying zirconium substrate.

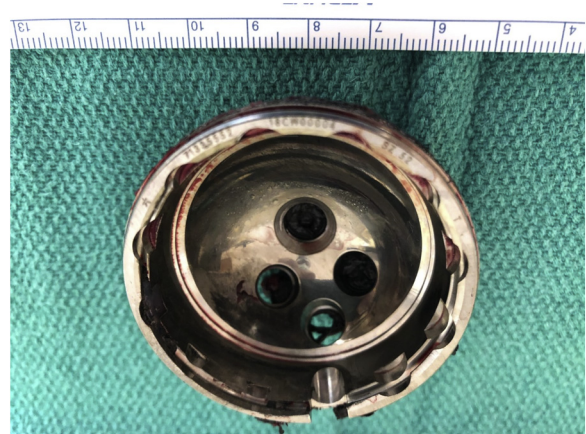


Figure 11. Retrieved acetabular component with visible wear on the rim down to the antirotation scallops.

titanium component. Oxidized zirconium, once scratched free of its hard oxidized layer, is a softer material than titanium which is responsible for the visible debris. For this outcome to occur, there must be wear-through or dissociation of the polyethylene from its host component which would imply that any signs of an Oxinium arthrogram on radiographs indicates a failed implant necessitating revision surgery. These cases are rare but have been documented in the literature (Table 1).

Greco and Berend published a case of a dissociated polyethylene from a medial unicompartmental knee arthroplasty that resulted in rapid wear of the oxidized zirconium femoral component and demonstrated a large Oxinium arthrogram [17]. A recent article by Purcell et al. [18] described extra-articular extravasation of oxidized zirconium particles after a failed TKA. This article differs in that there was only small articular sided wear on the femoral condyles and no failure of the polyethylene. The preoperative films in Purcell’s case show radiolucencies around the femoral component, and they describe loosening at the time of surgery which may illustrate the potential for Oxinium wear debris related to mechanical loosening. Kore et al. [19] showed a similar process to our TKA case in a patient with recurrent TKA instability in which the femoral component was repeatedly scratched free of its black oxidized layer. Similar to our case was the finding of black stained synovial tissue, but, unlike ours, their case did not manifest an arthrogram appearance on radiographs.

Multiple case reports have been published documenting dissociated polyethylene liners resulting in erosion of an Oxinium femoral head with an associated Oxinium arthrogram and severe soft tissue metallosis [20–22]. Complete wear and deformation of an Oxinium femoral head is not necessarily required for premature failure of a THA. Moussa et al. [23] reported an increased surface roughness of scratched oxidized zirconium femoral heads retrieved after THA dislocations. Carli et al. [24] showed increased polyethylene wear from oxidized zirconium heads that were roughened upon dislocation and subsequent reduction maneuvers.

We do not have histologic analysis of the resected tissue in either of our cases, which limits our ability to know if this process is similar to metallosis or ALTR seen with cobalt-chromium alloy debris. Patients with failed metal-on-metal THA, associated ALTR, and tissue loss have been shown to have high complication rates, such as dislocation, after revision surgery [25]. The THA patient in this series had grossly intact abductors at the time of surgery but is still experiencing pain and weakness. The TKA patient does not report weakness at this time, but both patients have residual Oxinium-stained peri-prosthetic tissues that could not be safely

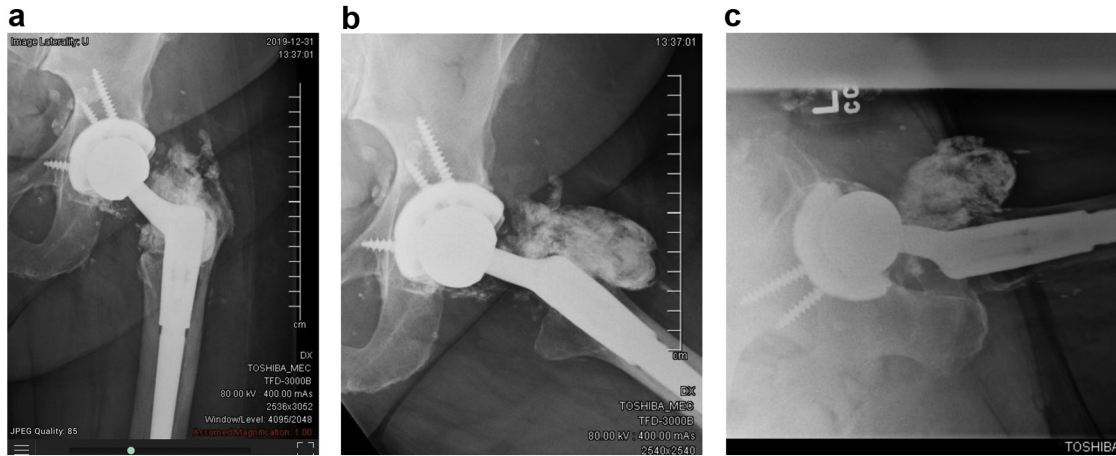


Figure 12. Postoperative anteroposterior (a), frog lateral (b), and cross-table lateral (c) radiographs after synovectomy and revision to a new acetabular component and modular tapered stem.

resected. The sequelae of unresected oxidized zirconium debris remain unknown at this time. The rare occurrence of these cases makes future study difficult.

This article is not meant to critique oxidized zirconium's properties with regard to being a quality bearing surface for arthroplasty. It is, however, somewhat concerning to see the extreme amount of wear and deep grooving of the Oxinium components in both cases. The titanium tibial and acetabular components in these cases showed small amounts of wear, which was minimal compared with the amount of wear on the Oxinium components. This finding suggests that oxidized zirconium, once scratched free of its hard oxidized layer, is a softer material than titanium and can lead to the observed accelerated wear in our cases [26]. The uncovering of a silver metallic appearance in the deep grooves certainly helps fuel surgeon suspicion that Oxinium is a coating.

Summary

Oxinium components have shown good midterm survivorship, and the oxidized layer has been shown to be extremely wear resistant, but exposure of the underlying layers can lead to rapid wear, deformation, and metallosis. These cases serve to help surgeons identify this rare complication and help stress the importance of good surgical technique. Appropriate TKA alignment and ligament balancing and proper acetabular component placement and polyethylene seating could likely have avoided this complication in these cases. Routine THA and TKA follow-up is likely appropriate for patients with well-placed and functioning oxidized zirconium implants. Patients with malaligned, unstable, or painful implants should be seen more frequently for early identification of implant failure to avoid severe metallosis and soft tissue damage. Metallosis from the failure of non-Oxinium components has been well described in the literature, but this dramatic radiographic finding has not. Severe metallosis and soft tissue damage can lead to long-term pain, weakness, and instability, even after revision.

Further long-term study is required to promote the routine use of oxidized zirconium implants.

Conflict of interests

B. M. Frye is in the speakers' bureau or gave paid presentations for Zimmer Biomet and is a paid consultant for Zimmer Biomet and NovoSource.

References

- [1] Ezzet KA, Hermida JC, Colwell Jr CW, D'Lima DD. Oxidized zirconium femoral components reduce polyethylene wear in a knee wear simulator. *Clin Orthop Relat Res* 2004;428:120.
- [2] Ezzet KA, Hermida JC, Steklov N, D'Lima DD. Wear of polyethylene against oxidized zirconium femoral components effect of aggressive kinematic conditions and malalignment in total knee arthroplasty. *J Arthroplasty* 2012;27(1):116.
- [3] Akil S, Newman JM, Shah NV, Ahmed N, Deshmukh AJ, Maheshwari AV. Metal hypersensitivity in total hip and knee arthroplasty: current concepts. *J Clin Orthop Trauma* 2018;9(1):3.
- [4] Ajwani SH, Charalambous CP. Availability of total knee arthroplasty implants for metal hypersensitivity patients. *Knee Surg Relat Res* 2016;28(4):312.
- [5] Innocenti M, Carulli C, Matassi F, Carossino AM, Brandi ML, Civinini R. Total knee arthroplasty in patients with hypersensitivity to metals. *Int Orthop* 2014;38(2):329.
- [6] Roe J, Vioreanu M, Salmon L, Waller A, Pinczewski L. Ten-year comparison of oxidized zirconium and cobalt-chromium femoral components in total knee arthroplasty. *Orthop J Sports Med* 2016;4(7 suppl5).
- [7] Karidakis GK, Karachalios T. Oxidized zirconium head on crosslinked polyethylene liner in total hip arthroplasty: a 7- to 12-year in vivo comparative wear study. *Clin Orthop Relat Res* 2015;473(12):3836.
- [8] Zaoui A, Hage SE, Langlois J, Scemama C, Courpied JP, Hamadouche M. Do oxidized zirconium femoral heads reduce polyethylene wear in cemented THAs? A blinded randomized clinical trial. *Clin Orthop Relat Res* 2015;473(12):3822.
- [9] Good V, Ries M, Barrack RL, Widding K, Hunter G, Heuer D. Reduced wear with oxidized zirconium femoral heads. *J Bone Joint Surg Am* 2003;85-A(Suppl 4):105.
- [10] Patel AM, Spector M. Tribological evaluation of oxidized zirconium using an articular cartilage counterface: a novel material for potential use in hemiarthroplasty. *Biomaterials* 1997;18(5):441.

Table 1
Published studies of failed cases with an associated "Oxinium Arthrogram."

Study	Joint replacement	Failure mechanism	Oxinium arthrogram
Greco and Berend [17]	Unicompartmental knee arthroplasty	Polyethylene dissociation	Yes
Zou et al. [20]	Total hip arthroplasty	Polyethylene dissociation	Yes
Gkoulipoulou et al. [21]	Total hip arthroplasty	Polyethylene wear-through and mechanical loosening	Yes
Tribe et al. [22]	Total hip arthroplasty	Polyethylene dissociation	Yes

- [11] Hunter G, Dickinson J, Herb B, Graham R. Creation of oxidized zirconium orthopaedic implants. *J ASTM Int* 2005;2(7):12775.
- [12] Chalmers BP, Perry KI, Taunton MJ, Mabry TM, Abdel MP. Diagnosis of adverse local tissue reactions following metal-on-metal hip arthroplasty. *Curr Rev Musculoskelet Med* 2016;9(1):67.
- [13] Berry DJ, Abdel MP, Callaghan JJ. What are the current clinical issues in wear and tribocorrosion? *Clin Orthop Relat Res* 2014:3659.
- [14] Cooper HJ, Della Valle CJ, Berger RA, et al. Corrosion at the head-neck taper as a cause for adverse local tissue reactions after total hip arthroplasty. *J Bone Joint Surg Am* 2012;94(18):1655.
- [15] Paydar A, Chew FS, Manner PA. Severe periprosthetic metallosis and polyethylene liner failure complicating total hip replacement: the cloud sign. *Radiol Case Rep* 2015;2(4):115.
- [16] Sharareh B, Phan DL, Goreal W, Schwarzkopf R. Metallosis presenting as knee pain 26 years after primary total knee arthroplasty. *J Orthop Case Rep* 2015;5(2):62.
- [17] Greco N, Berend K. Polyethylene liner dislocation of fixed-bearing medial Oxinium unicompartmental arthroplasty with severe metallosis. *Knee* 2018;25(2):341.
- [18] Purcell A, Buckner S, Brindley G, Grimes J. A Unique case of extra-articular extravasation of metal into the Lower leg resulting from oxidized zirconium wear particles from total knee arthroplasty. *Arthroplast Today* 2020;6(4):988.
- [19] Kore L, Bates T, Mills G, Lybeck D. Oxidized zirconium total knee arthroplasty implant failure in a patient with knee instability. *Arthroplast Today* 2020;6(3):552.
- [20] Zou AH, Novikov D, Feng JE, Anoushiravani AA, Schwarzkopf R, Vigdorchik JM. Liner dissociation leading to catastrophic failure of an Oxinium femoral head. *Arthroplast Today* 2018;5(1):21.
- [21] Gkoulipoulou E, Agathangelidis F, Vampertzis T, Ntovas T. Severe metallosis following oxidized zirconium wear in total hip arthroplasty. *BMJ Case Rep* 2016;2016.
- [22] Tribe H, Malek S, Stammers J, Ranawat V, Skinner JA. Advanced wear of an Oxinium™ femoral head implant following polyethylene liner dislocation. *Ann R Coll Surg Engl* 2013;95(8):e133.
- [23] Moussa ME, Esposito CI, Elpers ME, Wright TM, Padgett DE. Hip dislocation increases roughness of oxidized zirconium femoral heads in total hip arthroplasty: an analysis of 59 retrievals. *J Arthroplasty* 2015;30(4):713.
- [24] Carli A, Koch CN, Esposito CI, Wright TM, Padgett DE. Polyethylene wear increases in liners articulating with scratched oxidized zirconium femoral heads. *Clin Orthop Relat Res* 2018;476(2):182.
- [25] Munro JT, Masri BA, Duncan CP, Garbus DS. High complication rate after revision of large-head metal-on-metal total hip arthroplasty. *Clin Orthop Relat Res* 2014;472(2):523.
- [26] Kop AM, Whitewood C, Johnston DJL. Damage of Oxinium femoral heads subsequent to hip arthroplasty dislocation. *J Arthroplasty* 2007;22(5):775.