

Acute interstitial nephritis and drug-induced systemic lupus erythematosus due to chlorthalidone and amiodarone: A case report

SAGE Open Medical Case Reports
Volume 8: 1–4
© The Author(s) 2020
Article reuse guidelines:
sagepub.com/journals-permissions
DOI: 10.1177/2050313X20910029
journals.sagepub.com/home/sco



Umut Selamet¹, Ramy M Hanna^{1,2} , Anthony Sisk³,
Lama Abdelnour¹, Lena Ghobry⁴ and Ira Kurtz^{1,5}

Abstract

Drug-induced lupus erythematosus has features distinct from primary systemic lupus erythematosus. It can occur with a wide variety of agents that result in the generation of anti-histone or other types of antibodies. Systemic manifestations of drug-induced systemic lupus erythematosus may include renal dysfunction due to circulating immune complexes or due to other immune reactions to the culprit medication(s). Acute interstitial nephritis occurs due to DNA–drug or protein–drug complexes that trigger an allergic immune response. We report a patient who developed acute kidney injury, rash, and drug-induced systemic lupus diagnosed by serologies after starting chlorthalidone and amiodarone. A renal biopsy showed acute interstitial nephritis and not lupus-induced glomerulonephritis. It is important to note that systemic lupus erythematosus and acute interstitial nephritis can occur together, and this report highlights the role of the kidney biopsy in ascertaining the pathological diagnosis and outlining therapy in drug-induced lupus erythematosus.

Keywords

Drug-induced lupus erythematosus, systemic lupus erythematosus, amiodarone, chlorthalidone, acute interstitial nephritis, proteinuria, glomerular disease

Date received: 15 May 2019; accepted: 30 January 2020

Introduction

Drug-induced lupus erythematosus (DILE) is marked by the development of immunological and dermatological manifestations after the initiation of one or more medications.¹ While hydralazine and anti-histone antibodies are the best-known examples, other drugs have been known to cause a lupus-like reaction.^{1,2} Anti-histone antibodies are classically associated with DILE, but can also be seen in systemic lupus erythematosus (SLE).³ DILE usually involves skin and joint manifestations. Renal manifestations due to the presence of drug–protein immune complexes circulating in the blood are possible.⁴ While medications can cause acute interstitial nephritis (AIN) as an adverse reaction, it is not the expected renal lesion in DILE. Ascertaining the causality of the renal injury can be challenging using mere serology and urinary sediment.

Some common agents that more commonly cause DILE are hydralazine, procainamide, and quinidine, and they do so by inducing anti-nuclear antibodies (ANAs) as well as anti-histone antibodies.¹ A more extensive list of agents, including diuretics and drugs with sulfa moieties, is associated

with positive ANAs but generally do not cause SLE.² Amiodarone has been reported to cause a lupus-like syndrome and, in other cases, has demonstrated features typical of DILE.^{5,6}

We report a case of a 69-year-old woman who was started on amiodarone for atrial fibrillation and chlorthalidone for hypertension. The patient developed acute kidney injury

¹Division of Nephrology, Department of Medicine, David Geffen School of Medicine at UCLA, Los Angeles, CA, USA

²Division of Nephrology, Department of Medicine, UCI Medical Center, Orange, CA, USA

³Renal Pathology Division, Department of Pathology and Laboratory Medicine, David Geffen School of Medicine at UCLA, Los Angeles, CA, USA

⁴Graduate School of Public Health, University of Pittsburgh, Pittsburgh, PA, USA

⁵Brain Research Institute, University of California, Los Angeles, CA, USA

Corresponding Author:

Ramy M Hanna, Division of Nephrology, Department of Medicine, David Geffen School of Medicine at UCLA, Room 7-155, Factor Bldg. 700 Tiverton Ave., Los Angeles, CA 90095, USA.

Emails: rhannamd81@yahoo.com; ramyh1@uci.edu



(AKI) and a simultaneous drug rash. Workup revealed positive ANAs and anti-histone antibodies. The patient had improvement in renal function with the withdrawal of both chlorthalidone and amiodarone and remission of the drug-related exanthem.

Case report

A 69-year-old Caucasian woman with a past medical history of type 2 diabetes mellitus, resistant hypertension, diastolic congestive heart failure with preserved ejection fraction. She had pulmonary nodules incidentally noted on chest radiography, and workup of these ruled out malignancy, granulomatous disease, tuberculosis, and fungal infection as possible etiologies. The patient was diagnosed with sick sinus syndrome, and underwent pacemaker placement 5 years prior to her presentation to our center. She was diagnosed with recurrent atrial fibrillation with rapid ventricular response 3 months prior to presenting to nephrology. She was started on amiodarone therapy for atrial fibrillation as well as chlorthalidone for hypertension.

She presented to nephrology clinic with AKI, and her serum creatinine was 3.88 mg/dL, which was elevated from her baseline level of 1.2–1.7 mg/dL. Her medication history included apixaban, atorvastatin, cholecalciferol, clonidine, fexofenadine, glargine insulin, labetalol, latanoprost eye drops, and nifedipine. She was also on topical triamcinolone for a new skin rash that developed 3 months after the initiation of chlorthalidone and amiodarone.

Three months after starting the aforementioned medications, the patient reported the development of a rash on her chest, arms, and legs. The patient had a prior rash with hydrochlorothiazide, and she reacted similarly to chlorthalidone. Her creatinine rose to a peak of 3.88 mg/dL 11 weeks after the initiation of amiodarone and chlorthalidone. She had moderate proteinuria of 0.4–0.6 g protein/g creatinine at baseline, and the level of proteinuria did not change from baseline after initiation of chlorthalidone and amiodarone.

Liver function tests were checked on presentation to nephrology: alanine transaminase (ALT) 22 units/L, aspartate transaminase (AST) levels 25 units/L, total bilirubin levels (Tbilli) 0.4 mg/dL, and alkaline phosphatase (ALP) at 67 units/L. Thyroid function tests were also checked and showed a mild elevation in thyroid-stimulating hormone (TSH) to 8.1 mIU (microinternational unit)/L, with free T3 at 283 pg/dL and free T4 at 1.6 ng/dL. Free T3 and free T4 were within normal limits, and this pattern suggests subclinical hypothyroidism. Blood pressures had improved from 159/66 mmHg at the time of drug initiation to 120–140/80 mmHg 3 months after amiodarone and chlorthalidone initiation.

A serological workup was sent given the rise in serum creatinine and demonstrated a 1:160 homogeneous ANA (reference range <1:40 titer). Anti-double-stranded DNA antibody

(anti dsDNA) was measured at 874 IU (international unit)/mL (reference range <1:200 IU/L). Anti-histone antibody was confirmed to be positive at 2 units (reference range = 0–0.9 units). An anti-smooth muscle antibody was also positive at 1:160 titer (reference range titer 0). The rest of the workup was negative, including anti-ribonucleic protein (RNP), anti-smith, anti-Sjogren's serologies (SSA and SB), rheumatoid factor, scleroderma antibodies, Jo1 antibody, anti-citrullinated protein antibody (anti-CCP), thyroid peroxidase, and anti-neutrophil cytoplasmic antibodies (ANCA). Cardiolipin IgG was noted to be positive at borderline level, 16 GPL (reference range <15 GPL).

The patient's known proteinuria and albuminuria attributed to diabetic nephropathy remained less than 1 g of protein/g of creatinine (0.6–0.8 g/g). Besides proteinuria, urinary sediment showed a slight increase in hematuria (1→9 red blood cells) and pyuria (4→13 white blood cells) over the time period of 11 weeks between drug initiation and the patient's presentation to nephrology clinic. Urinary eosinophils were negative, and there was no evidence of peripheral eosinophilia. Given worsening AKI and persistent skin rash, a skin biopsy and a kidney biopsy were ordered.

The skin biopsy showed interface/lichenoid dermatitis and a lymphocyte-predominant infiltrate with eosinophils. There were no infectious organisms, and the colloidal iron and alcian special blue stains showed only minimal mucin accumulation. The interpretation was a lichenoid, lichen planus-like or lupus-like drug-related eruption and DILE being in the histologic differential diagnosis.

The patient had a kidney biopsy 13 weeks after drug initiation and 1 week after presentation to nephrology clinic with AKI. The biopsy yielded two cores of renal parenchyma with at least 17 glomeruli; six of which were obsolescent. The remaining glomeruli were enlarged with normal cellularity. Glomeruli had smooth single contoured basement membranes. One glomerulus showed a segment of sclerosis. The tubulointerstitium had patchy scarring involving about 20% of the cortex with interstitial fibrosis and tubular atrophy. There was a mild infiltrate of mononuclear cells in the areas of scar formation. There was focal mild interstitial inflammation in areas of early scar formation with some edema and associated tubulitis. Eosinophils were seen in these areas as well as scattered throughout the interstitium.

Immunofluorescence staining was reported as negative. The specimen for electron microscopy showed one glomerulus with segmental sclerosis but no deposits. Podocytes had mild to moderate patchy foot processes effacement involving about 50% of the surface areas. Basement membranes were mildly thickened and segmentally wrinkled. Overall, the renal biopsy disclosed acute interstitial nephritis with eosinophils, suggestive of a hypersensitivity reaction, secondary focal and segmental glomerulosclerosis (FSGS), thickened glomerular basement membrane suggestive of early diabetic

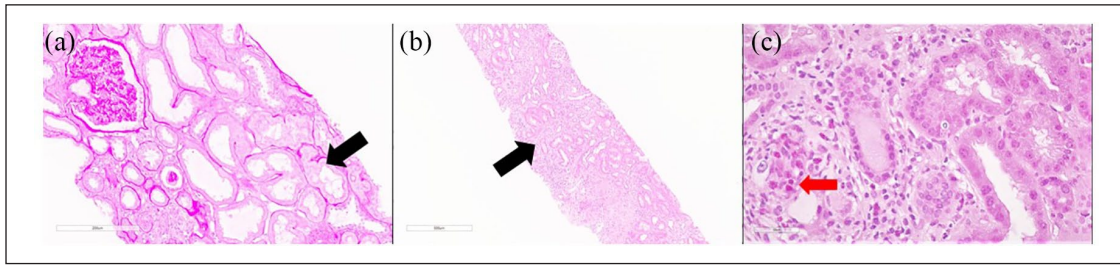


Figure 1. Renal biopsy findings showing acute interstitial nephritis: (a) Proximal tubules are irregularly attenuated with loss of brush border staining. Periodic acid-Schiff stain, 100 \times magnification. Black arrow: acute tubular necrosis; (b) low-power magnification slide showing lymphocyte-predominant interstitial infiltrate. Hematoxylin and eosin stain, 10 \times . Black arrow: group of lymphocytes; and (c) tubules are spaced apart by interstitial inflammation with clusters of eosinophils and edema. Hematoxylin and eosin, 400 \times magnification. Red arrow: group of eosinophils.

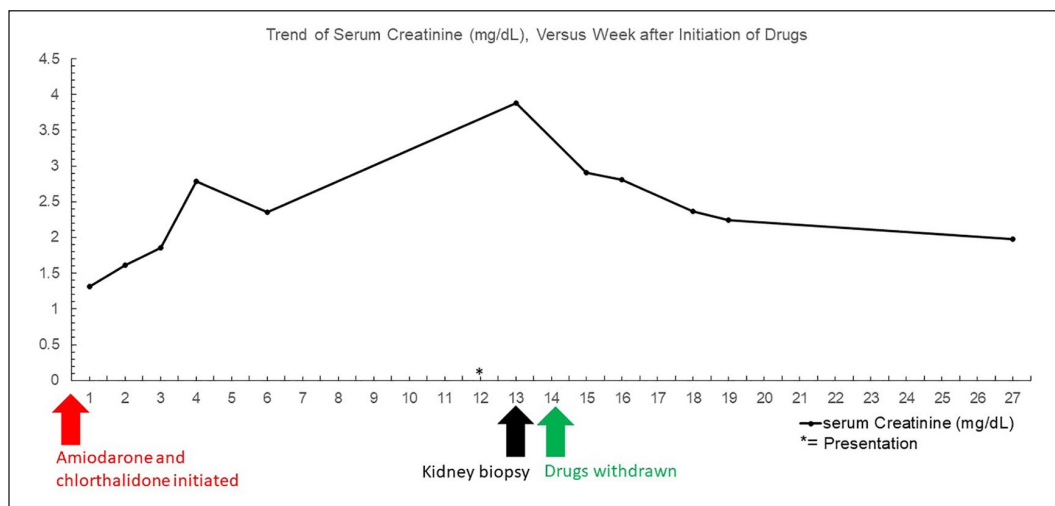


Figure 2. Trend of serum creatinine (mg/dL), versus week after initiation of drugs. Red arrow: start of amiodarone and chlorthalidone, black arrow: kidney biopsy, green arrow: cessation of amiodarone and chlorthalidone.

nephropathy, and acute tubular necrosis (ATN) with mild interstitial fibrosis. See Figure 1 for renal biopsy findings.

The patient was advised to stop amiodarone and chlorthalidone, the two new drugs introduced proximal to the event of AKI. Her serum creatinine dropped from a peak of 3.88–2.91 mg/dL, and it continued to trend down until it returned to 2.24 mg/dL 6 weeks after the renal biopsy. The estimated glomerular filtration rate (eGFR) had overall improved from 13 to 25 mL/min (from stage V to stage IIIb-IV by Kidney Disease Improving Global Outcomes (KDIGO) chronic kidney disease (CKD) staging). The proteinuria remained <1 g/g as before (0.8 g protein/g creatinine), similar to baseline levels of proteinuria thought to be due to coexisting diabetic nephropathy. There were no changes noted in the urinary sediment findings of mild pyuria and hematuria. The drug rash also resolved after cessation of amiodarone and chlorthalidone. There was no renal replacement therapy used during the AKI episode, even though plans were made for the use of corticosteroids. The resolution of renal injury with

the cessation of nephrotoxic drugs made the use of corticosteroids unnecessary. The patient's renal function returned closer to baseline at 1.98 mg/dL 26 weeks after drug initiation.

Please see Figure 2 for the trend of serum creatinine and timing of introduction of chlorthalidone and amiodarone, the renal biopsy, and the discontinuation of the suspect culprit agents.

Discussion

We present a case showing AKI due to a drug-related reaction along with serological findings suggestive of DILE. The patient had uncontrolled diabetes, hypertension, diastolic congestive heart failure (CHF), and atrial fibrillation, so the initial suspicion for worsening kidney functions was attributed to diabetic nephropathy and cardiorenal syndrome before nephrology evaluation. The presence of a skin rash following the introduction of two new drugs prompted a

more thorough workup for AKI, including serology and a kidney biopsy. It is also important to note that neither of the culprit drugs were agents commonly associated with DILE. It is a reminder that DILE can occur secondary to the use of amiodarone and sulfa moiety containing diuretics.

The results of serology could not completely exclude SLE, but the clinical course and rapid improvement in rash and renal parameters with withholding both offending agents supported the diagnosis of DILE well. The appearance of anti-histone antibodies supports the diagnosis of DILE over SLE as well but is not definitive. Renal biopsy results did not reveal immune complex disease expected with both DILE and SLE. The finding of AIN provided a cogent clinical clue that the patient was suffering from a drug-induced process. Epidemiologically, de novo SLE in an older patient is less likely, and the observed remission by withholding medications alone without immunosuppressive therapy is also more typical of DILE than SLE. The patient's renal function and proteinuria patterns need to be monitored, though, and re-biopsy is indicated in SLE or DILE patients who appear to have a flare up.⁷

This case suggests the importance of remaining vigilant for unusual causes of AKI and glomerular disease in diabetic patients. The risk of misattribution of kidney injury due to reversible etiologies in diabetic patients to worsening diabetic nephropathy is high. In this case, the clinical suspicion combined with a thorough serologic workup suggested a need for a kidney biopsy. This biopsy yielded a reversible cause and significantly improved the patient's renal function. It is a further reminder of the possibility of DILE in patients taking agents that are not typically associated with lupus. As such, we recommend a thorough workup for any dermatologic-renal presentation, and we must also consider the need for a kidney biopsy.^{8,9} It is important to mention that some cases of DILE can present without overt renal dysfunction but with interstitial findings on kidney biopsy.¹⁰ A growing list of over 1000 agents have been compiled that have been reported to cause DILE, and it is important for practitioners to remain up to date on all agents where this idiopathic reaction may be observed.¹¹

Conclusion

- We report a rare case of a syndrome typical of drug-induced lupus without the usual triggers.
- The renal biopsy was important as it pointed to AIN as the primary nephrological pathology, rather than lupus nephritis.
- AIN is an unexpected finding in DILE but pointed to a drug-induced process rather than classical SLE.
- A large number of agents have been reported to cause DILE.

Declaration of conflicting interests

The author(s) declared no potential conflicts of interest with respect to the research, authorship, and/or publication of this article.

Ethics approval

Our institution does not require ethical approval for reporting individual cases or case series.

Funding

The author(s) disclosed receipt of the following financial support for the research, authorship, and/or publication of this article: I.K. is supported in part by funds from the National Institutes of Health (NIH) (R01-DK077162), the Allan Smidt Charitable Fund, the Factor Family Foundation, and the Ralph Block Family Foundation.

Informed consent

Written informed consent was obtained from the patient documented in the medical record to publish patient information and biopsy images, but no identifiable images. No identifiable patient information is used in this case report.

ORCID iD

Ramy M Hanna  <https://orcid.org/0000-0003-1807-8909>

References

1. Vedeove CD, Simon JC, Girolomoni G, et al. Drug-induced lupus erythematosus with emphasis on skin manifestations and the role of anti-TNF α agents. *J Dtsch Dermatol Ges* 2012; 10(12): 889–897.
2. Wilson JD. Anti nuclear antibodies and cardiovascular drugs. *Drugs* 1980; 19: 292–305.
3. Epstein A and Barland P. The diagnostic value of antihistone antibodies in drug-induced lupus erythematosus. *Arthritis Rheum* 1985; 28(2): 158–162.
4. Sheikh TK, Charron RC and Katz A. Renal manifestations of drug-induced systemic lupus erythematosus. *Am J Clin Pathol* 1981; 75(5): 755–762.
5. Yachoui R and Saad W. Amiodarone-induced lupus-like syndrome. *Am J Ther* 2015; 22(1): e20–e21.
6. Susano R, Caminal L, Ramos D, et al. Amiodarone-induced lupus. *Ann Rheum Dis* 1999; 58: 655–656.
7. Anders H. Re-biopsy in lupus nephritis. *Ann Transl Med* 2018; 6(Suppl. 1): S41.
8. Katz U and Zandman-Goddard G. Drug-induced lupus: an update. *Autoimmun Rev* 2010; 10(1): 46–50.
9. Hogan JJ, Markowitz GS and Radhakrishnan J. Drug-induced glomerular disease: immune-mediated injury. *Clin J Am Soc Nephrol* 2015; 10(7): 1300–1310.
10. McLaughlin K, Gholoum B, Guiraudon C, et al. Drug-induced lupus: an update. *Am J Kidney Dis* 1998; 32(4): 698–702.
11. Arnaud L, Mertz P, Gavand PE, et al. Drug-induced systemic lupus: revisiting the ever-changing spectrum of the disease using the WHO pharmacovigilance database. *Ann Rheum Dis* 2019; 78(4): 504–508.