

Case Report

Multiple Myeloma and Epidural Spinal Cord Compression : Case Presentation and a Spine Surgeon's Perspective

Kee-Yong Ha, M.D., Ph.D., Young-Hoon Kim, M.D., Ph.D., Hyun-Woo Kim, M.D.

Department of Orthopaedic Surgery, Seoul St. Mary's Hospital, College of Medicine, The Catholic University of Korea, Seoul, Korea

Multiple myeloma, a multicentric hematological malignancy, is the most common primary tumor of the spine. As epidural myeloma causing spinal cord compression is a rare condition, its therapeutic approach and clinical results have been reported to be diverse, and no clear guidelines for therapeutic decision have been established. Three patients presented with progressive paraplegia and sensory disturbance. Image and serological studies revealed multiple myeloma and spinal cord compression caused by epidural myeloma. Emergency radiotherapy and steroid therapy were performed in all three cases. However, their clinical courses and results were distinctly different. Following review of our cases and the related literature, we suggest a systematic therapeutic approach for these patients to achieve better clinical results.

Key Words : Multiple myeloma · Spine · Spinal cord compression.

INTRODUCTION

Multiple myeloma (MM) is one of the most common hematological malignancies involving the spine. Pathological fracture of the vertebral body and neurological deterioration can occur as a form of skeleton related event in patients with MM. Under these conditions, surgical intervention or conservative treatment including radiotherapy have been tried for local control. However, there are still debates on which therapeutic approach is optimal^{7,10,13,17}. In particular, spinal cord compression by epidural myeloma with or without pathological fractures is a grave complication and, in this condition, timely optimal treatment is essential. However, there are also debates on optimal treatment. Here, we present three patients suffering from spinal cord compression caused by an epidural myeloma with different clinical courses and results. By reviewing the related literatures, we discuss the surgical roles for these patients with MM and spinal involvement.

CASE REPORT

Brief descriptions of the presented patients are summarized

in (Table 1).

Patient 1

A 62-year-old woman with no significant medical background, presented with upper back pain for one month and progressive lower extremity numbness and weakness. She was unable to walk unaided in the last several days and had developed urinary incontinence. A neurological examination revealed bilateral lower extremity weakness with grade IV strength, decreased deep and superficial sensation, a tingling sensation below the umbilicus and increased knee jerk. Initial laboratory tests revealed a hemoglobin of 14.0 g/dL, white cells of 8200/mm³, erythrocyte sedimentation rate of 120 mm/h, and elevated serum total protein of 10.1 g/dL (normal range, 6.6-8.3 g/dL), but she did not have renal or hepatic insufficiency. Additional laboratory tests including a bone marrow biopsy revealed κ chain immunoglobulin G (IgG) multiple myeloma. On magnetic resonance imaging (MRI) of the entire spine that was taken to evaluate the neurological condition, an epidural mass was found to compress the spinal cord posteriorly, extending from the C7 to T2 vertebra. The epidural mass was hypointense to the spinal

• Received : January 14, 2013 • Revised : May 28, 2013 • Accepted : August 1, 2013

• Address for reprints : Young-Hoon Kim, M.D., Ph.D.

Department of Orthopaedic Surgery, Seoul St. Mary's Hospital, The Catholic University of Korea, 222 Banpo-daero, Seocho-gu, Seoul 137-701, Korea
Tel : +82-2-2258-2837, Fax : +82-2-535-9834, E-mail : boscoa@empal.com

• This is an Open Access article distributed under the terms of the Creative Commons Attribution Non-Commercial License (<http://creativecommons.org/licenses/by-nc/3.0>) which permits unrestricted non-commercial use, distribution, and reproduction in any medium, provided the original work is properly cited.

Table 1. Summary of the patients

Patient No.	Sex/Age	Primary diagnosis	Involved level	Initial Frankel grade	Last FU Frankel grade	Treatments
1	F/62	MM, IgG, Kappa	C7-T2	B	B	High dose steroid+RT
2	F/39	MM, IgG, Lambda	C7-T2	D	B	High dose steroid+RT, surgery
3	F/62	MM, IgG, Kappa	T3-5	D	E	High dose steroid+RT

IgG : immunoglobulin G

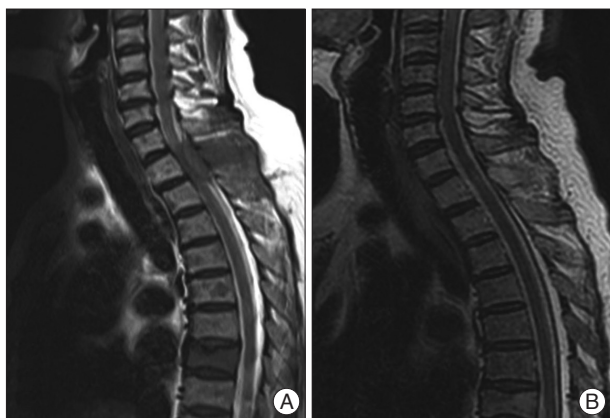

Fig. 1. Case 1. A : Sagittal T2-weighted magnetic resonance image (MRI) of the spine showing posterior epidural mass extending from the C7 to T1 vertebra. Multiple marrow signal changes are noted at the vertebral body. B : Follow-up MRI obtained 1 month after radiotherapy shows a complete epidural tumor response.

cord on T1-weighted images and hyperintense on T2-weighted images, with moderate contrast enhancement. No pathological fracture of the adjacent vertebra was found. High-dose steroid therapy (dexamethasone, 40 mg/day) and emergent radiotherapy were performed under the diagnosis of MM and spinal cord compression. Before this medical treatment, her neurological status was Frankel B. MRI, checked after 3000 cGy fractioned radiotherapy for the C7-T2 lesion, revealed complete resolution of the epidural mass (Fig. 1). However, during 6 months of follow-up, the patient did not experience any neurological improvement (final neurological status, Frankel B).

Patient 2

A 39-year-old woman presented with both shoulder and upper back pain for 1 month. A bone marrow biopsy was performed due to findings of an A/G ratio reversal, anemia, hypercalcemia and azotemia on laboratory tests revealed multiple myeloma. The findings of multiple punched out lesion in the skull and multiple osteolytic lesions over the spine on the radiological examination were matched with MM (IgG, λ chain). Computed tomography (CT) scans for the upper back pain revealed an epidural mass compressing the spinal cord. The initial neurological examination revealed normal motor and sensory functions of Frankel E grade. High-dose steroid therapy and fractioned radiotherapy (C7- T2, 3000 cGy) were conducted for the spinal cord compression lesion. After the ninth fraction of radiotherapy, she suddenly developed both lower extremity

weakness, sensory disturbance below the T4 level and urinary incontinence (Frankel B). A follow-up MRI revealed sustained compression of the spinal cord by an epidural mass without any additional pathological fractures. An emergent decompressive laminectomy was performed. No pathological fractures of the posterior element of the involved spine were observed intraoperatively. A friable bluish gray colored soft tissue mass was found at the epidural space compressing the spinal cord with mild adhesion to the underlying dura. Coincident microscopic findings of multiple myeloma with <10% necrosis rates were observed from the excised mass (Fig. 2). At the 6 month follow-up after surgery, her neurological status remained unchanged (Frankel B).

Patient 3

A 62-year-old woman was presented with upper back pain and progressive weakness for one month. On her history, she had undergone posterior spine surgery for a multiple compression fracture 6 months ago. She denied hearing about multiple myeloma at that surgery. Laboratory and radiological tests revealed multiple myeloma (IgG, κ chain). MRI showed multiple pathological fracture involving T4, 7, and 9 and an epidural mass was compressing the spinal cord at the T4 level. On neurological examination, her lower extremity motor power was over grade IV and she was able to walk unaided (Frankel D), even though she complained of lower extremity weakness. High-dose steroid and fractioned radiotherapy were performed. A radiological examination conducted 3 months post-radiotherapy revealed complete resolution of the cord compression and disappearance of the epidural mass (Fig. 3). No further pathological fracture were found. At the 18 month follow-up, her neurological status had improved with mild discomfort over the upper back region.

DISCUSSION

MM is a hematological multicentric disorder. It comprises 1% of malignant tumors and 10-15% of hematopoietic neoplasms¹⁶. However, as MM is a bone-marrow based neoplastic proliferation of plasma cells that secrete a monoclonal immunoglobulin, skeleton related events are not uncommon. Among these skeleton events, the spine is one of the most commonly involved sites and pathological fractures of the spinal column are the most common spinal involvement of MM. Another form of spinal involvement of MM is spinal cord compression. Spinal cord compression is reported to develop in 11-24% of patients with

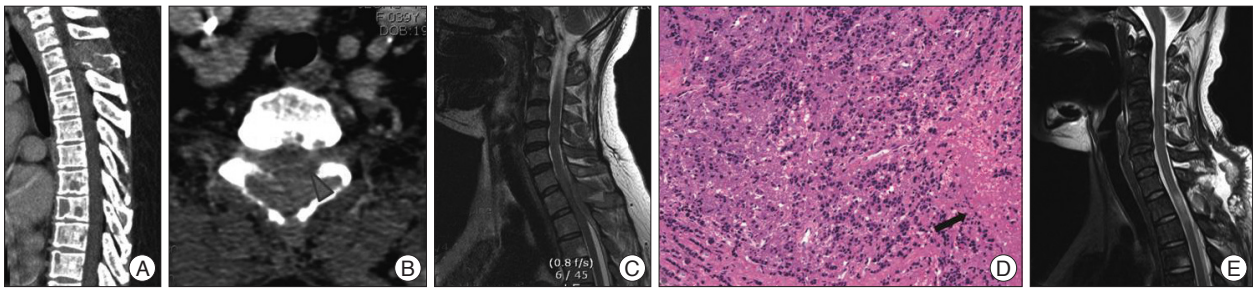


Fig. 2. Case 2. A and B : Sagittal and axial image of computed tomography (CT) scans showing multiple osteolytic lesions without pathological fracture of the vertebral column and an epidural mass compressing the spinal cord posteriorly (arrow head). C : A follow-up MRI taken after the ninth fractionated radiotherapy shows spinal cord compression caused by an epidural mass. D : Histological findings are consistent microscopic findings and multiple myeloma with a small portion of necrosis (arrow, H-E stain, $\times 100$). E : A follow-up MRI obtained 1 month after the laminectomy shows no evidence of recurrence, but a signal change is noted in the spinal cord indicating myelopathy.

MM¹⁷). Most cord-compression lesions occur due to a pathological fracture of the involved vertebral body or extension of a vertebral body myeloma lesion. However, an epidural myeloma could elicit spinal cord compression as a rare form of extraosseous myeloma. Although the exact incidence of spinal cord compression by epidural myeloma has not been reported, extraosseous involvement of MM is an uncommon condition and is found in <5% of patients with MM⁹). The sites of predilection for an extraosseous myeloma are the submucosal tissue of the upper respiratory tract, the gastrointestinal tract, pleura and the central nervous system³). Among them, spinal cord compression from an epidural myeloma without combined pathological fractures of the vertebral body is a rare condition and has mainly been reported as a case presentations in the literature^{1,8,10}). Radiographs in patients with an epidural myeloma are usually normal and in some cases, multiple compression fractures and osteopenic appearance of the vertebral body could suggest MM. MRI is the best diagnostic modality for detecting spinal cord compression, epidural masses and marrow involvement of MM. All of our patients were previously diagnosed by a hematological specialist and referred to our department for an evaluation of the spine lesions. Although the third case showed an accompanying pathological fracture of T4, the spinal cord compression developed not by the pathological fracture but by the posteriorly located epidural mass. This epidural lesion should be distinguished from several other neoplastic or inflammatory

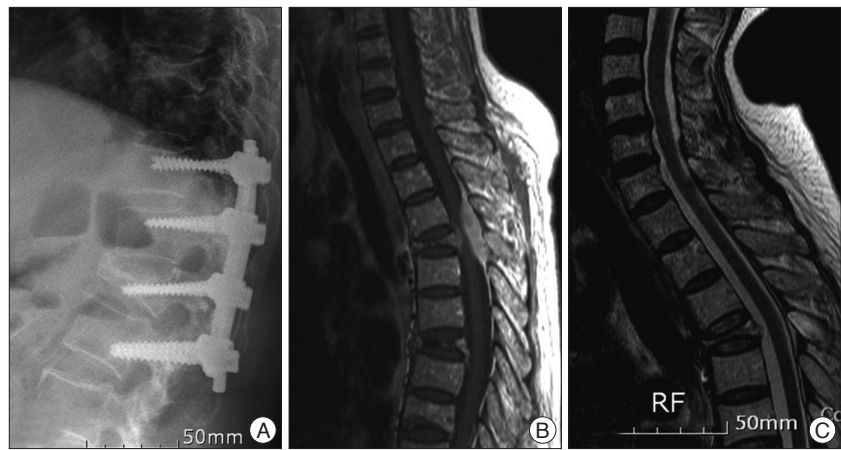

Fig. 3. Case 3. A : Before the diagnosis of multiple myeloma, the patient underwent posterior spine fusion for a multilevel compression fracture. B : Sagittal T-1 enhanced image shows the posterior epidural mass extending from T3 to T5 with a compression fracture at the T4 and T7 vertebra. C : A follow-up MRI obtained 1 month after radiotherapy shows a complete epidural mass response without progression of pathological compression fractures.

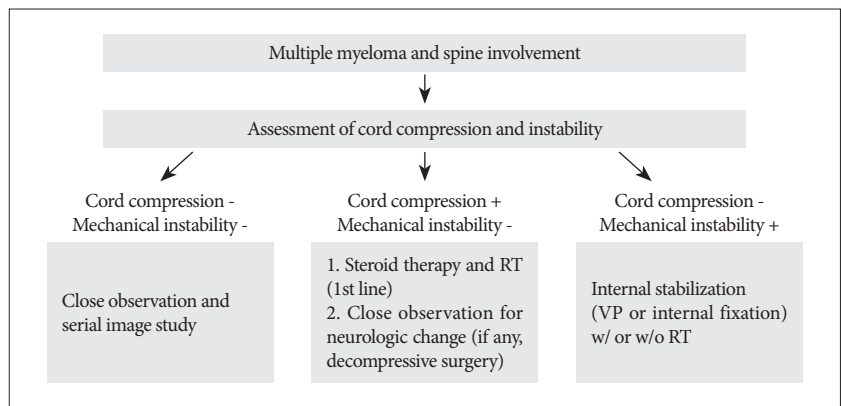


Fig. 4. Evaluation of patients with multiple myeloma and spinal involvement. VP : vertebroplasty, RT : radiotherapy.

conditions, such as tuberculous infection particularly in endemic areas, metastatic lesion, lymphoma and meningioma. Although other clinical data including laboratory results could be useful to differentiate, a histopathological diagnosis might be required to confirm the diagnosis. Extraosseous epidural myeloma is be-

lied to originate from lymphoid tissue in the epidural or paraspinal lymph node¹⁰. However, a signal change in the adjacent spinous process was observed in all of our cases. A directly extension or connection to this posterior marrow lesion could not be ruled out.

In general, extraosseous myeloma involvement at diagnosis or during the course of disease is considered a poor prognosis³. Failure of neurological recovery has been observed in most reported cases with various treatment modalities as our cases showed^{2,9,11}. Because of the limited size of most reports and the differences in the treatment provided, no clear guidelines have been established for spinal cord compression caused by a myeloma. Some authors recommend radiotherapy combined with high-dose steroid therapy as the first choice of treatment because MM is highly sensitive to radiotherapy^{6,12}. In one report, radiotherapy alone was tried for 63 patients with MM. The authors reported that 76% of the patients experienced an improvement in motor function, 2% deteriorated and local control was achieved in 98% in 1 year¹⁴. In contrast, surgical decompression was attempted in several reports and early surgical decompression followed by radiotherapy or chemotherapy was recommended^{4,8,10,15}. However, most authors agreed that timely intervention is critical for spinal cord compression by a myeloma. As our cases and other reported cases have shown, neurological recovery beyond the critical point is extremely rare regardless of the radiotherapy or surgery attempted. Although further research to define the optimal treatment for this condition is mandatory, close observation of the neurological status and patient and medical staff awareness of neurological deterioration are also important to prevent neurological deficits and obtain favorable results. Moreover, the involved level by the epidural myeloma is one of the important factors to be considered. If the involved level is the cervical or thoracic level, likely these presented cases, more attentions should be paid to monitor the neurologic status. Surgical intervention prior to non-surgical treatment should be considered in the cases presented with any deterioration of the neurologic status.

Although we could not reach a firm conclusion with these cases of the limited numbers, we present an algorithm to help the clinical decision-making process and define the role for surgery in the spinal involvement of myeloma from the perspective of spine surgeon (Fig. 4). The mechanical status of the spine and neurological status are two important factors to be assessed. As most surgeons recognize, these local factors are one of the many components used to determine management of the patient with spinal lesions caused by a myeloma.

The spine is the main predilection of MM. It is our obligation as spine surgeons to provide patients with the most reliable and optimal treatment and to alleviate pain and maintain their quality of life.

CONCLUSION

Optimal therapeutic strategy for epidural myeloma and spinal cord compression as one of devastating complications of multiple myeloma is still under debate. By review of cases with different clinical courses and related literatures, the authors tried to suggest therapeutic strategy for optimal clinical results. Close evaluation for mechanical stability and neurologic status, and multidiscipline approach are important factors leading successful results for this systemic disease.

References

1. Avadhani A, Shetty AP, Rajasekaran S : Isolated extraosseous epidural myeloma presenting with thoracic compressive myelopathy. *Spine J* 10 : e7-e10, 2010
2. Benson WJ, Scarffe JH, Todd ID, Palmer M, Crowther D : Spinal-cord compression in myeloma. *Br Med J* 1 : 1541-1544, 1979
3. Damaj G, Mohty M, Vey N, Dincan E, Bouabdallah R, Faucher C, et al. : Features of extramedullary and extraosseous multiple myeloma : a report of 19 patients from a single center. *Eur J Haematol* 73 : 402-406, 2004
4. Dürr HR, Wegener B, Krödel A, Müller PE, Jansson V, Refior HJ : Multiple myeloma : surgery of the spine : retrospective analysis of 27 patients. *Spine (Phila Pa 1976)* 27 : 320-324; discussion 325-326, 2002
5. Innes J, Newall J : Myelomatosis. *Lancet* 1 : 239-245, 1961
6. Jin R, Rock J, Jin JY, Janakiraman N, Kim JH, Movsas B, et al. : Single fraction spine radiosurgery for myeloma epidural spinal cord compression. *J Exp Ther Oncol* 8 : 35-41, 2009
7. Lim BS, Chang UK, Youn SM : Clinical outcomes after percutaneous vertebroplasty for pathologic compression fractures in osteolytic metastatic spinal disease. *J Korean Neurosurg Soc* 45 : 369-374, 2009
8. Loubopoulos A, Ioannidis P, Balogiannis I, Stavrinou P, Koletsa T, Karacostas D : Cervical epidural plasmacytoma presenting as ascending paraparesis. *Spine J* 11 : e1-e4, 2011
9. Matsui H, Fujie H, Tsuji H : Extraosseous epidural tumor of immunoglobulin D myeloma. *J Spinal Disord* 5 : 366-369, 1992
10. Okacha N, Chrif E, Brahim E, Ali A, Abderrahman E, Gazzaz M, et al. : Extraosseous epidural multiple myeloma presenting with thoracic spine compression. *Joint Bone Spine* 75 : 70-72, 2008
11. Palmbach M, Hoffmann W, Grodd W, Postler E, Voigt K : Extraosseous, epidural tumour spread of multiple myeloma. *Eur J Radiol* 22 : 146-148, 1996
12. Prestwich RJ, Ackroyd S, Gilson D : Is surgery required in the management of spinal cord compression in myeloma patients? *Clin Oncol (R Coll Radiol)* 23 : 161, 2011
13. Rades D, Huttenlocher S, Dunst J, Bajrovic A, Karstens JH, Rudat V, et al. : Matched pair analysis comparing surgery followed by radiotherapy and radiotherapy alone for metastatic spinal cord compression. *J Clin Oncol* 28 : 3597-3604, 2010
14. Rades D, Veninga T, Stalpers LJ, Basic H, Rudat V, Karstens JH, et al. : Outcome after radiotherapy alone for metastatic spinal cord compression in patients with oligometastases. *J Clin Oncol* 25 : 50-56, 2007
15. Renier JC, Brégeon C, Boasson M, Audran M, Emile J, Guy G, et al. : [Spinal cord compression in multiple myeloma. Study of 10 cases]. *Rev Rhum Mal Osteoartic* 51 : 193-196, 1984
16. Wadleigh M, Tefferi A : Classification and diagnosis of myeloproliferative neoplasms according to the 2008 World Health Organization criteria. *Int J Hematol* 91 : 174-179, 2010
17. Wallington M, Mendis S, Premawardhana U, Sanders P, Shahsavari-Haghighi K : Local control and survival in spinal cord compression from lymphoma and myeloma. *Radiother Oncol* 42 : 43-47, 1997