

Decellularized Matrix and Supplemental Fat Grafting Leads to Regeneration following Traumatic Fingertip Amputation

Wesley N. Sivak, MD, PhD*
Edward J. Ruane, MD*
Steven J. Hausman, PhD†
J. Peter Rubin, MD*‡§
Alexander M. Spiess, MD*

Summary: Decellularized scaffold materials are capable of regenerating missing tissues when utilized under appropriate conditions. Fat grafting also has reported advantages in revitalizing damaged tissue beds. This report details a case of traumatic fingertip amputation treated with a combination of decellularized materials in conjunction with fat grafting, resulting in a supple and functional reconstruction of the affected digit. After traumatic fingertip amputation, a patient was initially treated with decellularized porcine urinary bladder matrix powder. As a second stage, the healed tip scar tissue was reexcised, and a second application of powder was applied. As a third stage, the tip scar tissue was reexcised and a decellularized bilayer was sewn into the soft tissues of the debrided tip, resulting in an improved soft tissue envelope. As a final stage, the restored fingertip soft tissue envelope was fat grafted for additional bulk. Patient underwent treatment every other day with decellularized porcine urinary bladder matrix (powder and bilayer) and was able to reasonably regenerate the traumatic fingertip soft tissue envelope. This resulted in an envelope that was further enhanced with fat grafting. The resulting digit was sensate with maintained length, and possessed a more normal appearance than would be achieved by healing by secondary intention, or local flap or graft coverage. Decellularized materials can be utilized in conjunction with fat grafting to treat traumatic fingertip amputations in select patients. This combination approach is able to achieve a sensate fingertip and regain length lost in the affected digit. Additionally, we describe a novel technique that can be employed to maximize the amount of soft tissue regenerated by the decellularized products. (*Plast Reconstr Surg Glob Open* 2016;4:e1094; doi: 10.1097/GOX.0000000000001094; Published online 12 October 2016.)

Decellularized scaffold materials provide a template for tissue ingrowth and have been shown to aid in healing of complex wounds caused by a variety of conditions.¹⁻³ These materials have also been reported to be capable of regenerating missing tissues when used under appropriate conditions. Fat grafting has also been reported

to be advantageous in revitalizing damaged tissue beds due in part to the presence of adipose-derived stem cells within the graft.⁴ A combination approach incorporating both of these strategies has yet to be reported in the literature.

Fingertip amputations are one of the most common injuries seen by hand surgeons.⁵ Traditional approaches to treating these injuries rely upon sacrificing length in the affected digit to achieve adequate soft tissue coverage over exposed structures. Herein, we report a case of traumatic fingertip amputation treated with a decellularized porcine urinary bladder matrix in both its powder and bilayer form (MicroMatrix and MatriStem from ACell, Inc., Columbia, Md.) utilized in conjunction with fat grafting, resulting in successful reconstruction of a sensate fingertip soft tissue envelope.

From the *Department of Plastic Surgery, University of Pittsburgh, Pittsburgh, Pa.; †Hausman Technology Presentations, Baltimore, Md.; ‡Department of Bioengineering, University of Pittsburgh, Pittsburgh, Pa.; and §McGowan Institute for Regenerative Medicine, University of Pittsburgh, Pittsburgh, Pa.

Received for publication August 7, 2016; accepted August 31, 2016.

Copyright © 2016 The Authors. Published by Wolters Kluwer Health, Inc. on behalf of The American Society of Plastic Surgeons. All rights reserved. This is an open-access article distributed under the terms of the Creative Commons Attribution-Non Commercial-No Derivatives License 4.0 (CCBY-NC-ND), where it is permissible to download and share the work provided it is properly cited. The work cannot be changed in any way or used commercially without permission from the journal.

DOI: 10.1097/GOX.0000000000001094

Disclosure: The views expressed in this manuscript are those of the authors and do not necessarily reflect the official policy or position of the University of Pittsburgh or the University of Pittsburgh Medical Center. The authors have no financial interest to declare in relation to the content of this article. The Article Processing Charge was paid for by the authors.

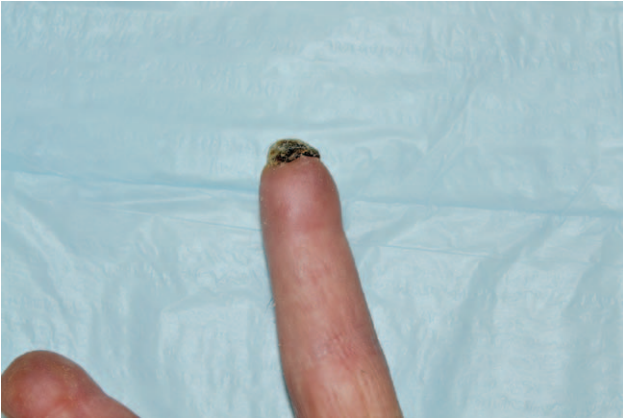


Fig. 1. Appearance of the injured left long finger approximately 3 months after injury, soon after initiation of MatriStem powder therapy.

CASE REPORT

A 69-year-old male scientific researcher presented to clinic 2 weeks after a snow-blower accident with injuries to his dominant left hand (Fig. 1). The long finger was amputated transversely through the middle portion of the distal phalanx, retaining the eponychial fold and a proximal 2-mm segment of his nail bed with attached nail plate. The index finger sustained segmental loss of the distal phalanx. At the time of injury he was treated with dressing changes to the long finger and had primary closure of the soft tissues of his index finger. He was offered bilateral V-Y

advancement flaps for closure of his long finger defect, but was motivated to seek treatment with a decellularized scaffold material. He was otherwise in good health, had never smoked, and had a good support system at home. He was perceived to be an excellent candidate for treatment with decellularized scaffold given his motivation and background in scientific research.

After informed consent, he underwent debridement of the long finger down to healthy bleeding tissues under local anesthetic blockade and had MicroMatrix powder applied to the wound per manufacturer guidelines. He was instructed on dressing changes and provided additional materials for ongoing wound care. On follow-up at 4 months the wound was closed. However, he had developed tip hypersensitivity and lacked sufficient overall length and suppleness of the soft tissue envelope. He was re-debrided to create an acute wound, and continued with MicroMatrix powder application and dressing changes. During the third visit, he was again re-debrided and the soft tissue envelope was stented open with a MatriStem bilayer sheet folded up into a plug, and sewn into the surrounding soft tissues with chromic gut suture. Over the course of treatment progressive lengthening of the digit and overlying nail was observed (Fig. 2). Digital length was measured from the distal interphalangeal joint (DIPJ) to fingertip utilizing standard photographs taken at each clinic visit; measurements were performed with ImageJ (National Institutes of Health, Bethesda, Md.).

At 12 months out from his original injury date, our patient underwent fat grafting to the tip of his long finger (Fig. 3). Abdominal fat was harvested utilizing tumescent

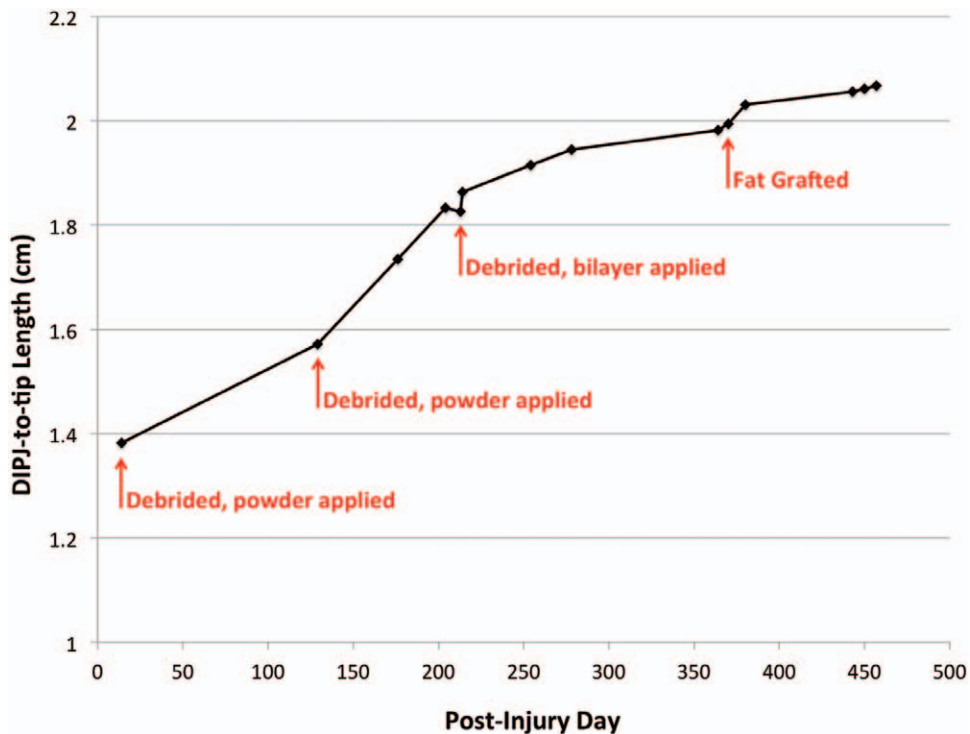


Fig. 2. DIPJ-to-tip distance over time as measured from standardized photographs taken at each clinic visit. Overall, 6.8 mm was gained in digital length over the course of the treatment.

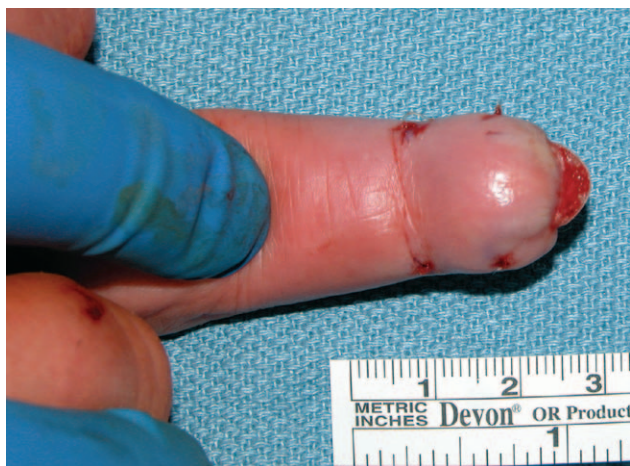

Fig. 3. Intraoperative appearance of the digit at the time of fat grafting. Fat grafts were deposited via 4 stab incisions into the volar pulp.

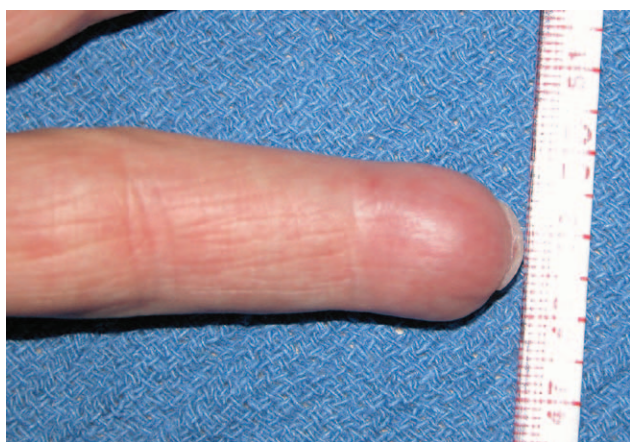

Fig. 4. Appearance of the digit 3 months after fat grafting procedure; the patient had 6-mm 2-point discrimination measured in the digit at this time.

liposuction with handheld cannulas. Fat was prepared according to the Coleman method.⁶ Processed fat was injected via multiple percutaneous stab incisions into the volar pulp of the left long finger; in total 1.5 ml of fat was injected. Our patient tolerated the procedure well and now has increased bulk of the tip, reduced hypersensitivity, and 6-mm 2-point discrimination measured in the digit at his last follow-up visit, 3 months after his fat grafting procedure (Fig. 4). There has been no appreciable resorption of fat in the fingertip and no deformity at his abdominal donor site. At this point the patient has been undergoing treatment with an ultrasonic bone stimulator for a non-union of his index finger distal phalanx and bone grafting was being considered should this modality fail.

SUMMARY

Fingertip injuries are a common problem requiring precise care for optimal results. The special sensory receptor sites in the glabrous skin of the fingertip are uniquely adapted for digital proprioception and should be preserved whenever possible. Devitalized tissues often require amputation to achieve a stable wound bed to allow for adequate healing. This leads to digit shortening and overall negatively impacts residual hand function in the affected limb. In this report we have presented an alternative strategy for reconstruction of an amputated fingertip, with good sensation and an objectively demonstrated gain in length of the injured digit over time. Since initial presentation to our clinic 2 weeks out from his traumatic snow-blower injury, our patient gained 6.8 mm in length from DIPJ to tip. In addition, hypersensitivity that had developed during the healing process has diminished, with normal 2-point discrimination in the digit. The additional bulk provided to the volar surface of the digit has improved its appearance and given him adequate tissues for fine-motor activities.

This strategy is time consuming and labor intensive, and not appropriate for all patients, especially for those who need a timely return to an active lifestyle. However, decellularized materials can be utilized in conjunction with fat grafting to reconstruct soft tissue in traumatic fingertip amputations. This multimodal approach has demonstrated an ability to regain length to achieve a sensate and minimally hypersensitive fingertip.

Alexander M. Spiess, MD

Department of Plastic Surgery

University of Pittsburgh

3550 Terrace Street – Scaife Hall, Suite 6B

Pittsburgh, PA 15261

E-mail: spiessam@upmc.edu

REFERENCES

1. Attinger CE, Janis JE, Steinberg J, et al. Clinical approach to wounds: debridement and wound bed preparation including the use of dressings and wound-healing adjuvants. *Plast Reconstr Surg.* 2006;117:72S–109S.
2. Eweida AM, Marei MK. Naturally occurring extracellular matrix scaffolds for dermal regeneration: do they really need cells? *Biomed Res Int.* 2015;2015:839694.
3. Valerio IL, Campbell P, Sabino J, et al. The use of urinary bladder matrix in the treatment of trauma and combat casualty wound care. *Regen Med.* 2015;10:611–622.
4. Rigotti G, Marchi A, Galiè M, et al. Clinical treatment of radiotherapy tissue damage by lipoaspirate transplant: a healing process mediated by adipose-derived adult stem cells. *Plast Reconstr Surg.* 2007;119:1409–1422; discussion 1423.
5. Hart RG, Kleinert HE. Fingertip and nail bed injuries. *Emerg Med Clin North Am.* 1993;11:755–765.
6. Coleman SR. Structural fat grafting: more than a permanent filler. *Plast Reconstr Surg.* 2006;118(3 Suppl):108S–120S.