

Thymectomy through lateralized partial sternotomy

Prashant N. Mohite, Sandip Singh Rana, Prasanth Sadasivan, Swapnil Deshpande

Department of Cardiothoracic and Vascular Surgery, Postgraduation Institute of Medical Research and Education, Chandigarh, India

Address for correspondence: Mr. Prashant N. Mohite, Department of Cardiothoracic and Vascular Surgery, 294, Sector 15/A, Chandigarh – 140 015, India. E-mail: drprashantis@rediffmail.com

ABSTRACT

A young woman with nonthymomic myasthenia gravis with failure of medical treatment was offered thymectomy through partial sternotomy. Shifting of vertical arm of “L” incision laterally avoids fracture of opposite sternal flange and provides better sternal stability postoperatively.

Key words: Myasthenia gravis, partial sternotomy, thymectomy

INTRODUCTION

Myasthenia gravis is an autoimmune disease in which antibodies block the acetylcholine receptors at the neuromuscular junction causing spectrum of symptoms from ptosis to progressive weakness and fatigue of the voluntary musculature. Blalock *et al.* in 1939 demonstrated thymectomy as a treatment option of myasthenia gravis.^[1]

CASE REPORT

A 23-year-old female presented with complaints of progressive weakness in upper limbs and drooping of both eyelids since 6 months. She was diagnosed of myasthenia gravis and was started on medical treatment for the same without much benefit. CT scan showed normal-sized thymus without any evidence of tumor or thymoma. Decision was made in favor of thymectomy.

Technique

A vertical midline skin incision is made starting 2–3 cm

below the suprasternal notch up to the level of the fourth intercostal space: subcutaneous tissue, muscles cut with electrocautery, and upper part of sternum exposed. L-shaped partial sternotomy is planned for the thymectomy. A vertical line extending from suprasternal notch up to fourth intercostals space, half to 1 cm lateral to the midline on right side is drawn on presternal fascia with electrocautery. Sternum is divided vertically along this line with an electric powered saw. A small bridge of bone between this vertical division and the fourth intercostal space on right side is then divided with the sternal saw [Figure 1]. Finochietto sternal retractor is used to move apart the divided sternal flange and expose the anterior surface of the thymus [Figure 2]. Dissection is started with the inferior horn of the right or left lobe and progressed

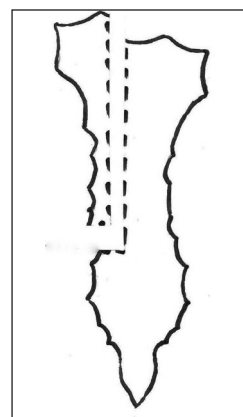


Figure 1: Unilateral partial sternotomy

Access this article online

Quick Response Code:



Website:

www.jcdronline.com

DOI:

10.4103/0975-3583.85268

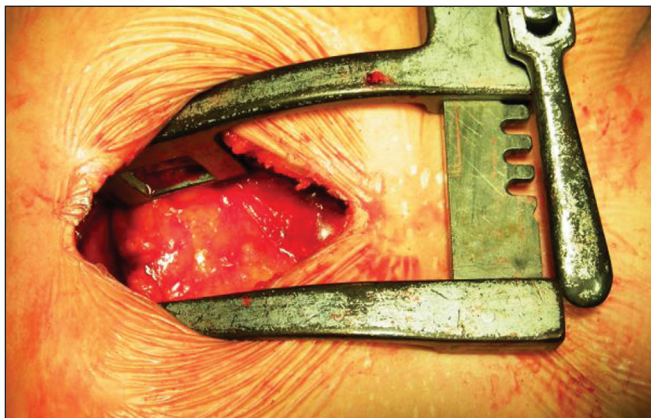


Figure 2: Exposure of thymus through the partial sternotomy

to the superior horn. Thyrothymic ligament divided and ligated followed by thymic branch of the internal mammary artery. The opposite lobe is dissected similarly and finally thymic vein draining into innominate vein is taken care of. Pleurae are swept away and most fatty tissue is wiped out bilaterally. Single retrosternal drain is sufficient unless inadvertent puncture of pleura, in which case, the intercostal drain is necessary. Sternum is closed with two Stainless Steel wires in the figure of “8” style.

DISCUSSION

Common indications for thymectomy in myasthenia gravis are failure of medical treatment, young patients with short duration of symptoms and significant disability from their medical treatment.^[2] Variety of approaches are available for thymectomy, namely median sternotomy^[3,4] partial sternotomy,^[5] transcervical incision,^[6] and video-assisted thoracoscopy.^[7] Conventional median sternotomy provides better exposure and produce better late results because of the removal of ectopic foci of thymic tissue,^[8] but it is associated with greater morbidity and mortality. Partial sternotomy allows visualization of thymus, its vascular attachment, and parathymic fatty tissue through smaller incision. It is associated with a significantly smoother postoperative course and less pulmonary complications.^[8] Recently, thoracoscopic thymectomy has gained popularity because of less postoperative morbidity, minimal discomfort, and shorter hospital stay and cost the procedure offers.^[7] But, it is technically more difficult and requires specialized equipment and training.

Variety of partial sternotomy procedures are described in the literature. Inverted T-shaped incision through fourth intercostal space has been used widely and gives good exposure of the thymus^[5] but associated with the

sternal instability as sternum gets divided into three parts. Vertical split sternotomy involves vertical splitting of the upper-half of the sternum and spreading apart the sternal flanges.^[9] This causes fracture of one or both sides of the sternal flanges at mid-sternum that may cause intra as well as postoperative blood loss from the sternal fracture site and chance of sternal instability. In the L-shaped partial sternotomy, since the vertical part of the sternotomy is in the midline, there are chances of fracture of opposite sternal flange at midsternum during retraction.

In this article, authors propose lateralization of vertical arm of L-shaped median sternotomy by 1/2 to 1 cm. This facilitates retraction and at the same time avoids the fracture of the opposite flange of the sternum during retraction. While closing the sternotomy, the wire can be passed through the intact opposite sternal flange and wrapped around the slimmer separated sternal flange. This offers better sternal stability especially in patients with osteoporotic sternum of patients on long-term steroid therapy. This modification of partial sternotomy is useful for all the procedures that can be performed through partial sternotomy.

REFERENCES

1. Blalock A, Manson MF, Morgan HJ, Riven SS. Myasthenia gravis and tumors of the thymic region: Report of a case in which the tumor was removed. *Ann Surg* 1939;110:544-59.
2. Gronseth GS, Barohn RJ. Practice parameter: Thymectomy for autoimmune myasthenia gravis (an evidence-based review): Report of the Quality Standards Subcommittee of the American Academy of Neurology. *Neurology* 2000;55:7-15.
3. Hatton PD, Diehl JT, Daly BD, Rheinlander HF, Johnson H, Schrader JB, *et al.* Transsternal radical thymectomy for myasthenia gravis: A 15-year review. *Ann Thorac Surg* 1989;47:838-40.
4. Kattach H, Anastasiadis K, Cleuziou J, Buckley C, Shine B, Pillai R, *et al.* Transsternal thymectomy for myasthenia gravis: Surgical outcome. *Ann Thorac Surg* 2006;81:305-8.
5. Grandjean JG, Lucchi M, Mariani MA. Reversed-T upper mini-sternotomy for extended thymectomy in myasthenic patients. *Ann Thorac Surg* 2000;70:1423-5.
6. Kirschner PA, Osseman KE, Kark AE. Studies in myasthenia gravis. Transcervical total thymectomy. *JAMA* 1969; 209:906-10.
7. Toker A, Eroglu O, Ziyade S, Tanju S, Senturk M, Dilege S, *et al.* Comparison of early postoperative results of thymectomy: Partial sternotomy vs. videothoracoscopy. *Thorac Cardiovasc Surg* 2005;53:110-3.
8. Miller JJ, Mansour KA, Hatcher CR Jr. Median sternotomy T incision for thymectomy in myasthenia gravis. *Ann Thorac Surg* 1982;34:473-4.
9. Pêgo-Fernandes PM, de Campos JR, Jatene FB, Marchiori P, Suso FV, de Oliveira SA. Thymectomy by partial sternotomy for the treatment of myasthenia gravis. *Ann Thorac Surg* 2002;74:204-8.

How to cite this article: Mohite PN, Rana SS, Sadasivan P, Deshpande S. Thymectomy through lateralized partial sternotomy. *J Cardiovasc Dis Res* 2011;2:190-1.

Source of Support: Nil, **Conflict of Interest:** None declared.