

Available online at [www.sciencedirect.com](http://www.sciencedirect.com)

ScienceDirect

journal homepage: [www.elsevier.com/locate/radcr](http://www.elsevier.com/locate/radcr)

## Case Report

# Primary lymphoma of the breast: A case series

Anubha Wadhwa, MD\*, Kathleen Senebouttarath, MD

Department of Radiology, Froedtert Hospital, Medical College of Wisconsin, 9200 West Wisconsin Avenue, Milwaukee, WI 53226, United States

### ARTICLE INFO

#### Article history:

Received 2 February 2018

Accepted 4 April 2018

#### Keywords:

Primary breast lymphoma

Secondary breast lymphoma

### ABSTRACT

Primary breast lymphoma has been defined as localized involvement of one or both breasts with or without ipsilateral axillary nodal involvement, usually as a rare manifestation of extranodal non-Hodgkin's lymphoma. We describe three cases of this uncommon disease seen at our institution. Two of these cases presented as palpable breast lumps and one was screening detected. None of the patients had a prior history of lymphoma; only one reported B symptoms night sweats and weight loss. Diagnosis was established on ultrasound-guided core biopsy and no evidence of metastatic disease was identified. Even though the imaging features are not specific to this diagnosis, the radiologists should be aware of the clinical and imaging presentation of this rare malignancy to recommend appropriate management and establish radiologic–pathologic concordance.

© 2018 The Authors. Published by Elsevier Inc. on behalf of University of Washington.

This is an open access article under the CC BY-NC-ND license.

(<http://creativecommons.org/licenses/by-nc-nd/4.0/>)

## 1. Introduction

Primary breast lymphoma (PBL) is a rare presentation of non-Hodgkin's lymphoma (NHL), with mostly case reports and small case series reported in the literature. It usually presents as a clinically palpable mass and is rarely screening detected. Although the imaging characteristics are not specific, they may sometimes mimic benign masses. Diagnosis can usually be established with a percutaneous needle biopsy. Unlike primary breast carcinoma, surgery is not the key treatment for PBL. Treatment is mainly confined to combination of chemotherapy and radiation therapy. We present three cases of PBL from our institution with discussion about their imaging features and management.

### 1.1. Case 1

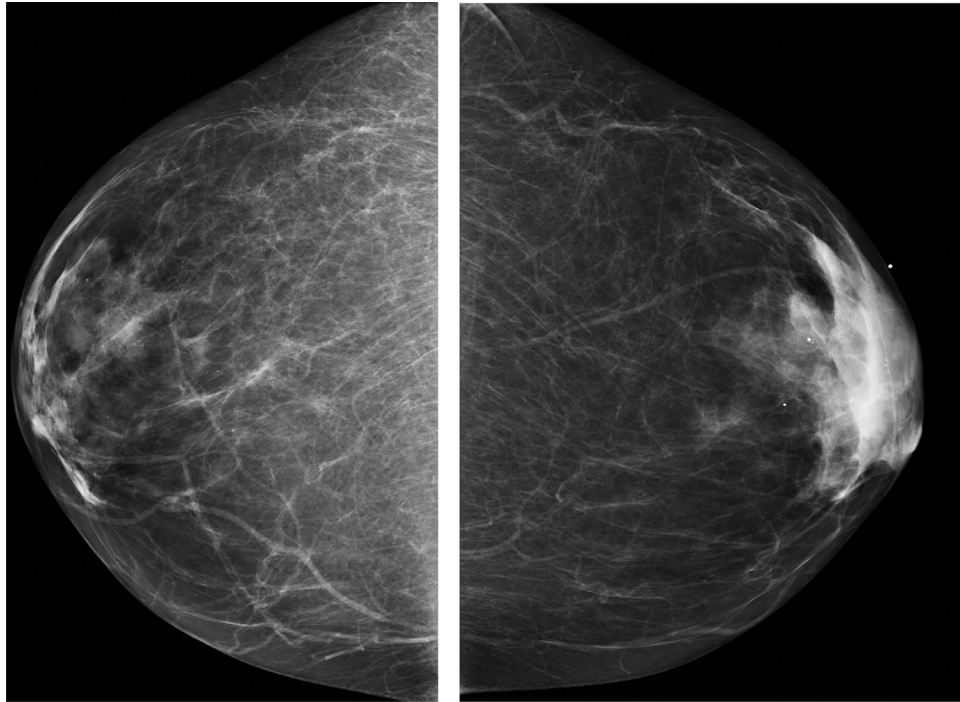
A 63-year-old female with past medical history of ovarian cancer in 1986 and history of low-grade B-cell NHL involving the right breast 4 years ago treated with excision and radiation therapy. Patient presented with a rapidly growing palpable left breast mass and also reported recent night sweats and weight loss. Mammogram was performed and demonstrated increased asymmetric density within the left subareolar region (Fig. 1). Targeted ultrasound (US) was performed demonstrating a 5 × 4 × 3 cm solid oval mass with mixed echogenicity in the left breast at 2 o'clock corresponding to the palpable finding (Fig. 2A). Increased vascularity was identified (Fig. 2B). No abnormal or enlarged left axillary nodes were seen on US. US-guided left breast biopsy was performed and demonstrated large B-cell lymphoma. Positron emission tomography (PET)–computed tomography (CT) done few weeks later showed that the mass had increased to 7 cm size and showed intense increased metabolic activity, with maximum

\* Corresponding author.

E-mail addresses: [awadhwa@mcw.edu](mailto:awadhwa@mcw.edu) (A. Wadhwa), [kathysenebouttarath@gmail.com](mailto:kathysenebouttarath@gmail.com) (K. Senebouttarath).

<https://doi.org/10.1016/j.radcr.2018.04.009>

1930-0433/© 2018 The Authors. Published by Elsevier Inc. on behalf of University of Washington. This is an open access article under the CC BY-NC-ND license. (<http://creativecommons.org/licenses/by-nc-nd/4.0/>)



**Fig. 1 – (Case 1) Mammogram with bilateral craniocaudal views. Palpable area in the left lateral breast marked with a radiopaque marker. There is underlying dense asymmetry seen in the palpable area in the left breast. Also bilateral subareolar round calcifications are present, which were unchanged from prior mammograms.**

standardized uptake value (SUV) of 38 (Fig. 3). Mild activity was seen in left subpectoral and axillary nodes. No other evidence of metastatic disease was seen on PET-CT and other staging workup.

Patient subsequently underwent chemotherapy (R-CHOP  $\times 2$ ). Additionally, consolidative radiation therapy to the left breast to 50 Gy in 25 fractions as well as the regional lymphatics to 46 Gy in 23 fractions was given. Follow-up PET-CT after treatment showed complete resolution of left breast and axillary mass and uptake (Fig. 4). The patient has since been in remission about 4 years postcompletion of her treatment.

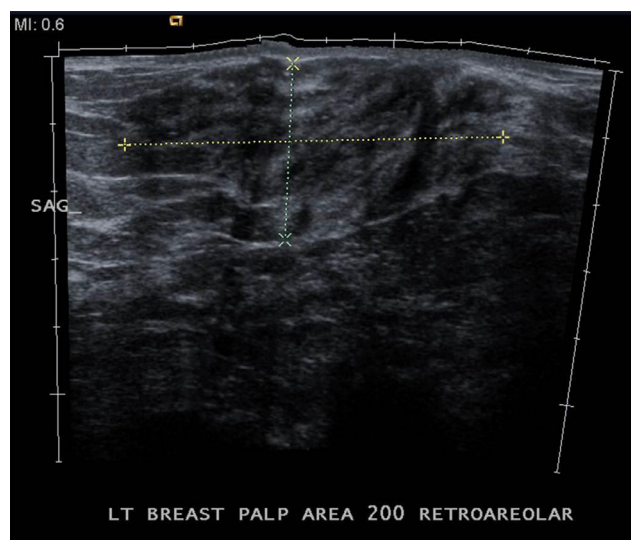
### 1.2. Case 2

A 56-year-old female with past medical history of diabetes mellitus, hypertension, and hypercholesterolemia presented with a palpable right-sided breast mass and fatigue. No history of fever, night sweats, or chills. Mammogram was performed and identified a 3.0 cm mass in the right breast at 10 o'clock, corresponding to the palpable finding (Fig. 5). Targeted US confirmed a 4.3  $\times$  2.0  $\times$  0.9 cm solid hypoechoic mass (Fig. 6). Patient underwent an US-guided needle biopsy, which revealed diffuse large B-cell lymphoma (DLBCL). PET-CT demonstrated a 1.7 cm right breast mass with mild uptake and maximum SUV of 2.0, without uptake in the axillary nodes or elsewhere to suggest metastatic disease (Fig. 7). Bone marrow biopsy was negative.

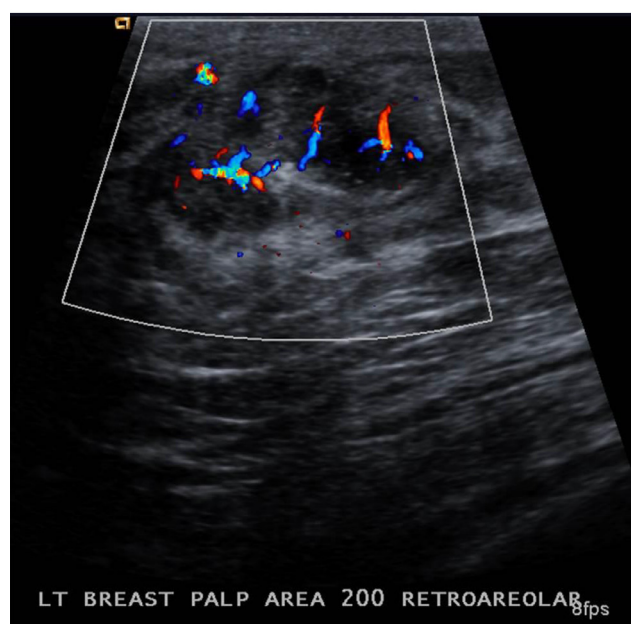
Patient underwent chemotherapy (R-CHOP  $\times$  six cycles) and consolidative radiation therapy to the right breast to a total dose of 48 Gy delivered in 24 fractions and 46 Gy in 23 fractions to the regional lymph nodes. Follow-up PET showed no evidence of malignancy. The patient is now 5 years out from treatment completion, without any clinical or mammographic evidence of disease recurrence.

### 1.3. Case 3

A 79-year-old female was found to have increasing focal asymmetries in the upper outer right breast on her screening mammogram (Fig. 8). Patient had a benign biopsy in this area 3 years ago which showed "Benign intramammary node." No corresponding sonographic abnormality was seen and breast magnetic resonance (MR) was recommended. The breast magnetic resonance was interpreted as normal with no corresponding abnormal enhancement in the upper outer right breast (Fig. 9). The right breast findings were followed for another year, when a diagnostic mammogram revealed further increase in the size and number of these focal asymmetries (Fig. 10). Repeat US evaluation demonstrated multiple small hypoechoic superficial masses in the upper outer right breast (Fig. 11). US-guided biopsy showed "Extranodal marginal zone lymphoma." PET-CT showed no evidence of lymphadenopathy or lymphoma in the right axilla or elsewhere in the body.



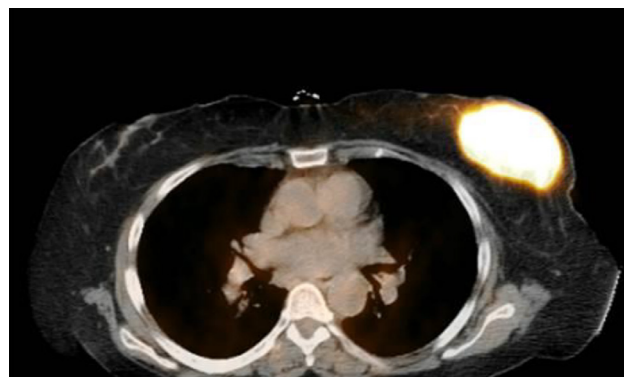(a)



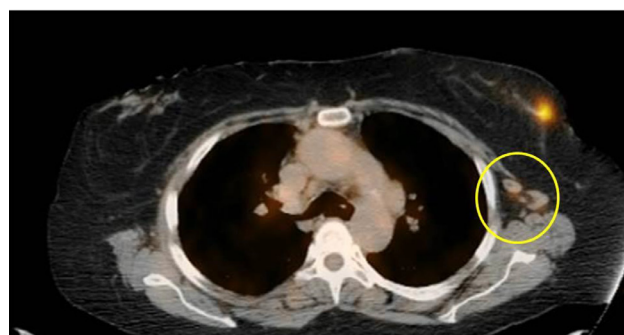(b)

**Fig. 2 – (Case 1) (A) Ultrasound evaluation of the palpable finding in the left breast demonstrates an oval solid mass with heterogeneous echotexture measuring 5.6 cm greatest dimension. (B) Doppler shows internal hypervascularity in the mass.**

The patient had no clinical symptoms pertinent to lymphoma and complete blood count was normal. Treatment with single agent "Rituximab" was recommended; however, patient elected only observation given low volume of her disease. In the 16 months of follow-up after her diagnosis, her disease has been stable in the right breast with no evidence of other organ involvement or lymphadenopathy.

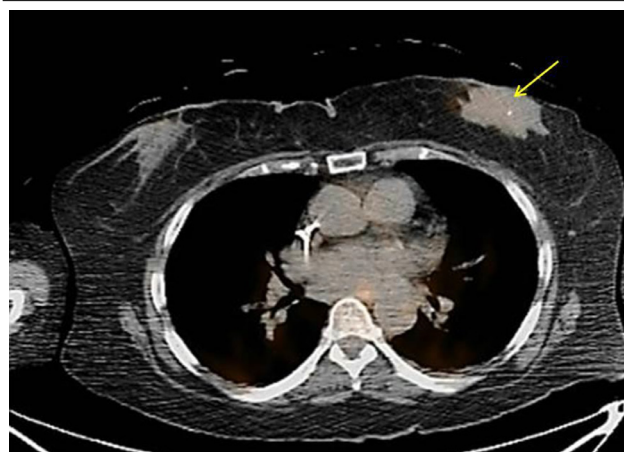


(a)



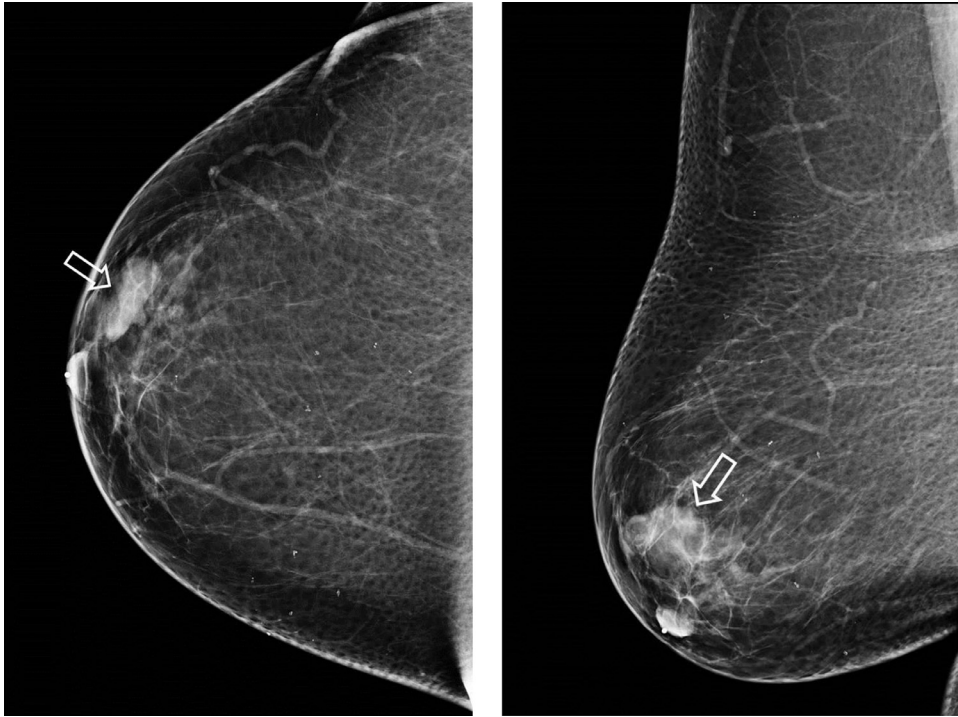
(b)

**Fig. 3 – (Case 1) (A) Positron emission tomography (PET)–computed tomography (CT) (PET–CT) shows avid uptake in the left breast mass with standardized uptake value (SUV) of 38.3. (B) Mild uptake seen in the left axillary nodes (yellow circle) with maximum SUV of 3.8. No evidence of metastatic disease was seen elsewhere on the PET. (For interpretation of the references to color in this figure legend, the reader is referred to the web version of this article.)**

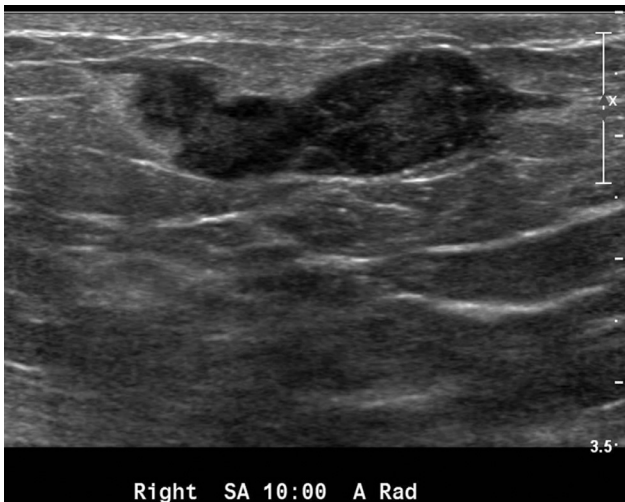

**Fig. 4 – (Case 1) Follow-up positron emission tomography–computed tomography after two cycles of R-CHOP chemotherapy shows decrease in size of the left breast mass and metabolic activity, with maximum standardized uptake value of 2.8 (yellow arrow). (For interpretation of the references to color in this figure legend, the reader is referred to the web version of this article.)**

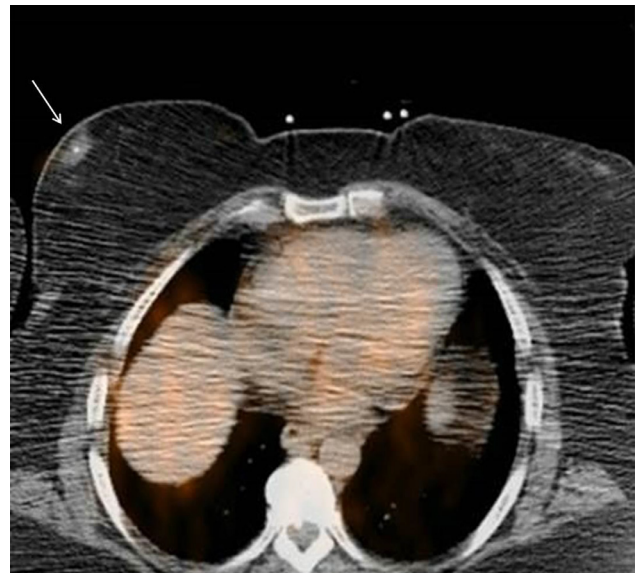



**Fig. 5 – (Case 2) Right breast diagnostic mammogram (craniocaudal and mediolateral oblique views) done to evaluate a palpable lump in the right breast. There is a 3 cm focal asymmetry in the upper outer right breast in the area of the palpable finding (white arrowhead), which was new from patient's last mammogram done 2 years ago.**



**Fig. 6 – (Case 2) Ultrasound (US) reveals a 4.3 cm solid hypoechoic mass with irregular margins corresponding to the palpable mass. US-guided biopsy of the mass showed diffuse large B-cell lymphoma.**

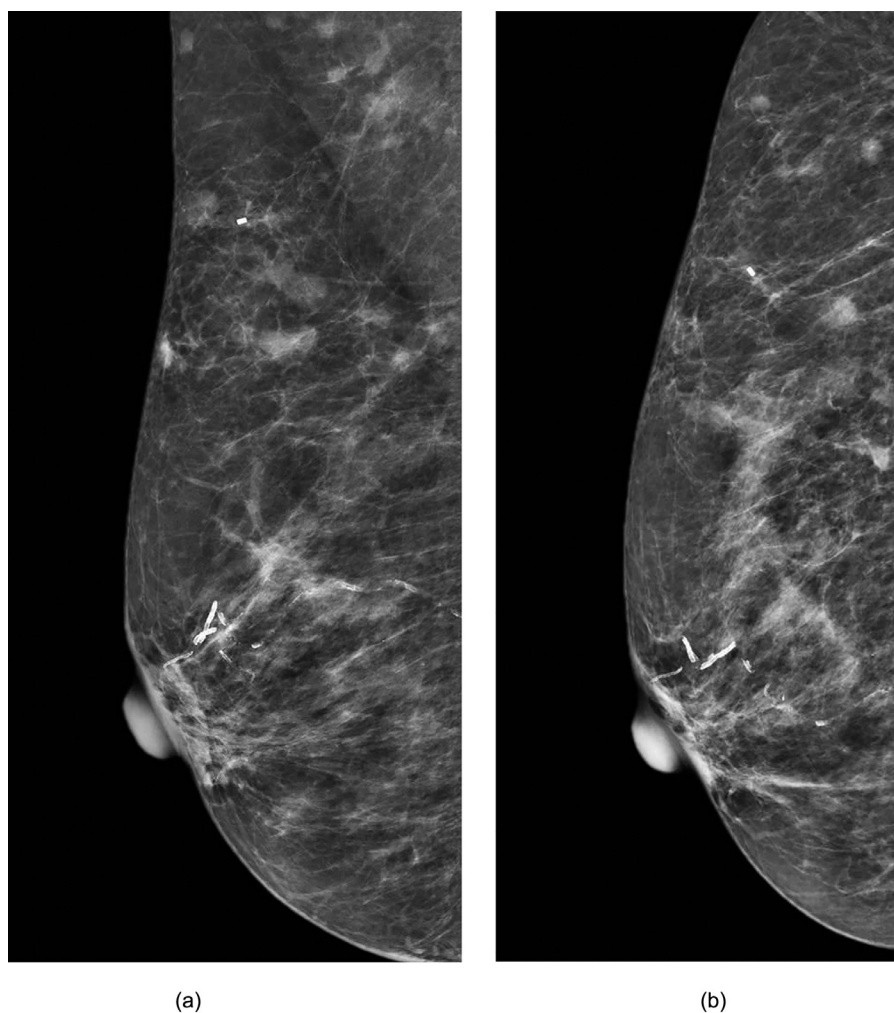


**Fig. 7 – (Case 2) Right breast lymphoma is not positron emission tomography avid and has a maximum standardized uptake value of 2.0 (white arrow).**

## 2. Discussion

Although lymphomas are one of the most common hematologic malignancies, breast involvement with lymphoma is very rare. This occurs mostly in the secondary form as part of

extra nodal tumor involvement in disseminated disease. PBL is even rarer, accounting for 0.04–0.5% of all breast malignancies [1,2] and 0.85–2.2% of extranodal lymphomas [3–5]. The criteria for the diagnosis of PBLs were defined by Wiseman



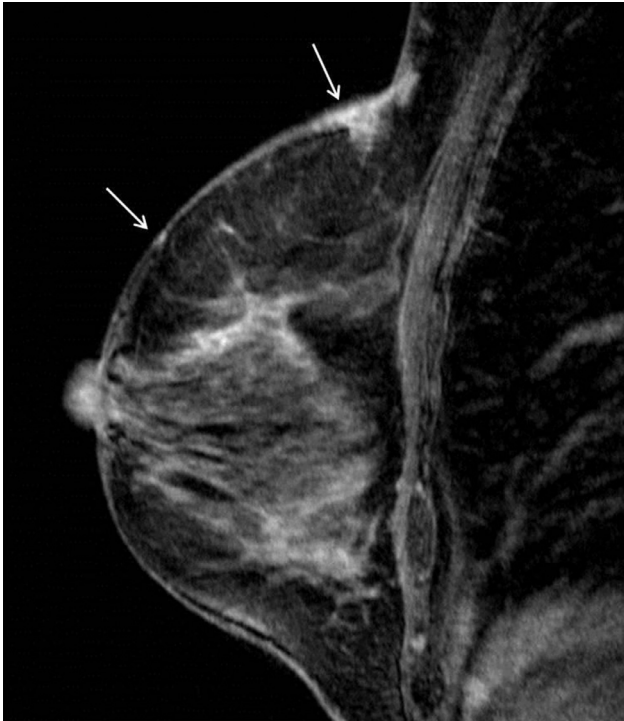
**Fig. 8. – (Case 3) (A) and (B) Right breast diagnostic mammogram (mediolateral oblique and exaggerated craniocaudal views) demonstrates multiple increasing focal asymmetries in the upper outer right breast.**

and Liao in 1972 and include: (a) both mammary tissue and lymphomatous infiltrate present in close association in an adequate pathologic specimen; (b) no evidence of widespread lymphoma by standard staging techniques or preceding extra mammary lymphoma, except for ipsilateral axillary node involvement, if diagnosed simultaneously with the breast lymphoma [6]. Non-Hodgkin's DLBCL is the most common histology for PBL, followed by follicular and mucosal-associated lymphoid tissue lymphomas [7,8]. Breast involvement with Hodgkin's disease or T-cell tumor is rare.

The clinical presentation of breast lymphoma is usually a single or sometimes multiple painless palpable lumps, which may be bilateral. Nipple or skin retraction, or nipple discharge is rarely seen. The usual B symptoms seen with lymphomas like fever, weight loss, and night sweats are very rare with PBL. It may sometimes present as diffuse breast enlargement and edema and may mimic an inflammatory process. It almost always occurs in females, with the fifth and sixth decades being the most common presenting age. Many studies have reported right breast predominance [7,8].

The imaging findings of breast lymphoma are nonspecific and may resemble any other breast malignancy or sometimes may have a more benign appearance. The most common mammographic abnormality is a solitary noncalcified breast mass with circumscribed or indistinct margins [9–11]. Calcifications, architectural distortion, nipple retraction, or spiculations are usually not seen in association with this malignancy. Global asymmetry may also be a mammographic presentation of PBL, seen in one-third of the patients in the study by Sabate et al., and usually associated with high-grade lymphomas [1]. In one of the largest series by Liberman et al. of 32 cases of NHL in 29 women (66% classified as PBL), the most common mammographic finding was a solitary noncalcified mass (69%). Multiple masses were seen in 9% cases, diffuse increased opacity with skin thickening in 9%, and no mammographic abnormality was seen in 13% cases [12]. Multiple masses are more common with secondary breast lymphoma (SBL), compared to primary.

On US a hypoechoic solid oval or round mass with circumscribed or indistinct margins is the most common appearance. Hyperechogenicity, mixed echo pattern, or pseudocystic

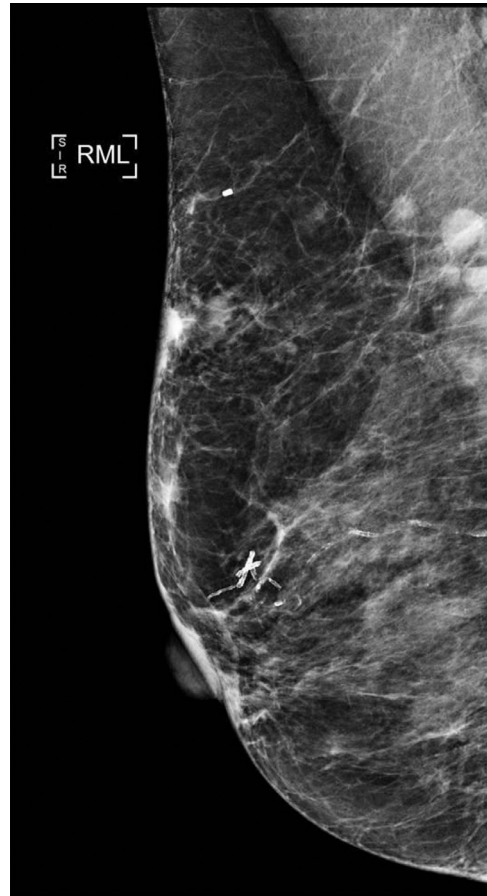


**Fig. 9 – (Case 3) Post contrast T1-weighted magnetic resonance (MR) image shows skin and adjacent subcutaneous enhancement in the superior right breast (white arrows). The MR was however interpreted as normal.**

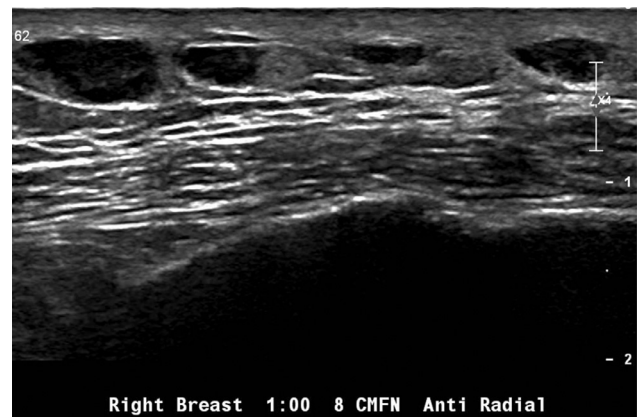appearance has also been described in the literature. Posterior acoustic enhancement is present in 52–75% of the masses and hypervascularity is seen in 55–64% [9–12]. Surov et al. found no significant differences in the mammographic or US imaging characteristics between PBL and SBL masses. PBL masses were usually larger at presentation and SBL masses were greater in number in their study [11].

There are no large case reviews on the magnetic resonance imaging of breast lymphoma. The few cases reported in the literature described most masses as being T1 isointense and T2 hyperintense with marked inhomogeneous contrast enhancement, with type 2 kinetics being the most common [13,14]. PET-CT is a valuable tool in the staging and follow-up of lymphoma patients. It may show involvement of axillary nodes or other extranodal disease in breast lymphoma. In the series by Yang et al., 92% of breast lymphomas demonstrated avid homogeneous fluorodeoxyglucose uptake at PET-CT with a mean maximum SUV of 10.6. Some other case reports have described ring-like uptake or diffuse avid PET uptake in the affected breast [15,16]. PET is also very useful in evaluating response to treatment.

There are no current established guidelines for the treatment of PBL. Treatment may involve combination of surgery, chemotherapy, and radiation therapy. Radical mastectomy has been described in the older literature as part of the treatment but subsequent studies showed it offers no benefit, and may actually delay the start of chemotherapy. Chemoimmunotherapy with consolidation radiation therapy is now considered the mainstay in the treatment of PBL. CHOP or CHOP-like



**Fig. 10 – (Case 3) Follow-up mammogram after 1 year shows interval increase in the focal asymmetries in the superior right breast.**



**Fig. 11 – (Case 3) Ultrasound (US) evaluation of the upper outer right breast reveals multiple hypoechoic and some cystic superficial masses corresponding to the focal asymmetries on the mammogram. US-guided biopsy of two of these masses showed "Marginal zone lymphoma."**



anthracycline-based chemotherapy combined with rituximab is now considered the standard treatment for most DLBCL breast lymphomas [17,18]. This may be followed with radiation to the ipsilateral breast and regional nodes. In the study by Avilés et al. the 10 year overall survival in patients treated with either radiation or chemotherapy alone was 50% vs 76% in those who received combination of radiation and chemotherapy. PBL is an aggressive tumor with high relapse rates, mainly involving extranodal sites. Studies have shown high central nervous system relapse rates in up to 20% patients resulting in poor overall survival rates, and recommend adding central nervous system prophylaxis to systemic treatment in PBL [19–21].

PBL is a distinct and rare clinicopathologic entity. It does not have distinctive imaging findings, but should be considered in the differential diagnosis of a mass lacking spiculations, architectural distortion, or microcalcifications. The primary treatment does not involve surgery but a combination of chemotherapy and radiation.

#### REFERENCES

- [1] Sabate JM, Gomez A, Torruaba S, Camins A, Roson N, De Las Heras P, et al. Lymphoma of the breast: clinical and radiological features with pathologic correlation in 28 patients. *Breast J* 2002;8:294–304.
- [2] Giardini R, Piccolo C, Rilke F. Primary non-Hodgkin's lymphomas of the female breast. *Cancer* 1992;69:725–35.
- [3] Ribrag V, Bibeau F, El Weshi A, Frayfer J, Fadel C, Cebotaru C, et al. Primary breast lymphoma: a report of 20 cases. *Br J Haematol* 2001;115:253–6.
- [4] Hugh JC, Jackson FI, Hanson J, Poppema S. Primary breast lymphoma. An immunohistologic study of 20 new cases. *Cancer* 1990;66:2602–11.
- [5] Avilés A, Delgado S, Nambo MJ, Neri N, Murillo E, Cleto S. Primary breast lymphoma: results of a controlled clinical trial. *Oncology* 2005;69:256–60.
- [6] Wiseman C, Liao KT. Primary lymphoma of the breast. *Cancer* 1972;29:1705–12.
- [7] Domchek SM, Hecht JL, Fleming MD, Pinkus GS, Canellos GP. Lymphomas of the breast. *Cancer* 2002;94:6–13.
- [8] Schouten JT, Weese JL, Carbone PP. Lymphoma of the breast. *Ann Surg* 1981;194:749–53.
- [9] Yang WT, Lane DL, Le-Petross HT, Abruzzo LV, Macapinlac HA. Breast lymphoma: imaging findings of 32 tumors in 27 patients. *Radiology* 2007;245:692–702.
- [10] Lyou CY, Yang SK, Choe DH, Lee BH, Kim KH. Mammographic and sonographic findings of primary breast lymphoma. *Clin Imaging* 2007;31:234–8.
- [11] Surov A, Holzhausen HJ, Wienke A, Schmidt J, Thomssen C, Arnold D, Ruschke K, Spielmann RP. Primary and secondary breast lymphoma: prevalence, clinical signs and radiological features. *Br J Radiol* 2012;85:e195–205.
- [12] Liberman L, Giess CS, Dershaw DD, et al. Non-Hodgkin lymphoma of the breast: imaging characteristics and correlation with histopathologic findings. *Radiology* 1994;192:157–60.
- [13] Shim E, Song SE, Seo BK, Kim Y-S, Son GS. Lymphoma affecting the breast: a pictorial review of multimodal imaging findings. *J Breast Cancer* 2013;16(3):254–65.
- [14] Darnell A, Gallardo X, Sentis M, Castañer E, Fernandez E, Villajos M. Primary lymphoma of the breast: MR imaging features. A case report. *Magn Reson Imaging* 1999;17(3):479–82.
- [15] Kumar R, Xiu Y, Dhurairaj T, Yu JQ, Alavi A, Zhuang H. F-18 FDG positron emission tomography in non-Hodgkin lymphoma of the breast. *Clin Nucl Med* 2005;30:246–8.
- [16] Bakheet SM, Bakheet R, Ezzat A, Tulbah A, Durakovic A, Hussain S. F-18 FDG positron emission tomography in primary breast non-Hodgkin's lymphoma. *Clin Nucl Med* 2001;26:299–301.
- [17] Avilés A, Delgado S, Nambo MJ, Neri N, Murillo E, Cleto S. Primary breast lymphoma: results of a controlled clinical trial. *Oncology* 2005;69(3):256–60.
- [18] Coiffier B, Lepage E, Briere J, Herbrecht R, Tilly H, Bouabdallah R, Morel P, Van Den Neste E, Salles G, Gaulard P, et al. CHOP chemotherapy plus rituximab compared with CHOP alone in elderly patients with diffuse large-B-cell lymphoma. *N Engl J Med* 2002;346(4):235–42.
- [19] Wong WW, Schild SE, Halyard MY, Schomberg PJ. Primary non-Hodgkin lymphoma of the breast: the Mayo Clinic experience. *J Surg Oncol* 2002;80(1):19–25.
- [20] Shao YB, Sun XF, He YN, Liu CJ, Liu H. Clinicopathological features of thirty patients with primary breast lymphoma and review of the literature. *Med Oncol* 2015;32:5.
- [21] Yhim H-Y, et al. Clinical outcomes and prognostic factors in patients with breast diffuse large B cell lymphoma; Consortium for Improving Survival of Lymphoma (CISL) study. *BMC Cancer* 2010;10:321.