

# Evaluation of myeloid cells (tumor-associated tissue eosinophils and mast cells) infiltration in different grades of oral squamous cell carcinoma

Priyanka Debta,  
Fakir Mohan Debta<sup>1</sup>,  
Minal Chaudhary<sup>2</sup>,  
Smita Bussari<sup>3</sup>

Department of Oral and Maxillofacial Pathology, Institute of Dental Science, SOA University, Bhubaneswar,  
<sup>1</sup>Department of Oral Medicine and Radiology, S.C.B. Dental College and Hospital, Cuttack, Odisha, <sup>2</sup>Department of Oral and Maxillofacial Pathology, SPDC, Sawangi, Wardha, <sup>3</sup>Department of Oral and Maxillofacial Pathology, Aditya Dental College, Beed, Maharashtra, India

## Address for correspondence:

Dr. Priyanka Debta,  
Department of Oral and Maxillofacial Pathology, Institute of Dental Science, SOA University, Bhubaneswar, Odisha, India.  
E-mail: drpriyanka\_1234@rediffmail.com

## INTRODUCTION

Oral squamous cell carcinoma (OSCC) is one of the leading causes of death in India. Sixty percent of oral cancers are well advanced by the time they are detected, and despite innovation being made in surgery, radiation, and chemotherapy, the long-term survival rate remains to be <50%.<sup>[1]</sup> OSCC is malignant neoplasm arising from mucosal epithelium of oral cavity. It consists of heterogeneous cell population with different biologic characters.<sup>[2]</sup> The tumor microenvironment is a dynamic network that includes the cancer cells, stromal tissue (immune cells, fibroblast, myofibroblast, cytokines, and vascular tissue), as well as the extracellular matrix (ECM) that surrounds it all.<sup>[3]</sup> The immune system can respond to cancer cells in two ways: By reacting against tumor-specific antigens (molecule that is unique to cancer cells) or against tumor-associated antigens (molecules that are expressed differently by cancer cells and normal cells).<sup>[4]</sup> Cells of immune system

## ABSTRACT

**Background:** The multifunctional involvement and infiltration of myeloid cells (tumor-associated tissue eosinophils [TATE] and mast cells) can provide a unique opportunity to define relevant effectors functions that may represent novel, therapeutic options for modulation of tumor onset/growth. **Aim:** Our study aimed to evaluate infiltration of myeloid cells (TATE and Mast cells) infiltration in different grades (WHO grading) of oral squamous cell carcinoma (OSCC). **Materials and Methods:** Total 30 cases of OSCC were selected for this study. Hematoxylin and eosin stain and toluidine blue special stain, to evaluate TATE and the mast cells infiltration, were used. Three-year follow-up of OSCC cases was done. **Result:** Among 30 cases, 63.33% cases of OSCC showed TATE-positive and 36.66% cases showed TATE-negative. Regarding mast cells infiltration, 66.66% OSCC cases showed mast cells positive and 33.33% cases did not show significant mast cells infiltration. We found significant association of TATE and mast cells infiltration in OSCC cases. These myeloid cells infiltration significantly associated with age of patients but did not show any significant association with gender, site, and habit of cases. When we compared these cells infiltration with clinical stages and different histological grades of tumor, we found their infiltration is decreasing, from Stages 1 to Stage 3 of tumor and from well to poorly differentiated carcinoma. We have also found the less infiltration of these myeloid in recurrence cases of OSCC. **Conclusion:** As the infiltration of TATE and mast cells are correlated, along with evaluation of TATE, we should also evaluate the presence of mast cells infiltration in OSCC. The assessment of myeloid cells could become, in the future, useful for therapeutic approaches in this subset of the patient.

**Key words:** Mast cells, oral squamous cell carcinoma, tumor-associated tissue eosinophils, toluidine blue

comprised lymphoid series and myeloid progenitor series cells.<sup>[5]</sup> Myeloid cells are derived from hematopoietic stem cells and the types that are seen in human tumors include macrophages, hemangiocytes, and dendritic cells, as well as neutrophils, eosinophils, mast cells, and myeloid-derived suppressor cells.<sup>[6]</sup>

Tissue eosinophils are derived in hemopoiesis from CD34<sup>+</sup> myeloid progenitors found in the bone marrow. The factors that influence the proliferation and the differentiation of the eosinophil lineage are cytokine growth factors including interleukin-3 (IL-3), granulocyte-macrophage colony-stimulating factor and IL-5, which are important in promoting eosinophil differentiation. It is now well recognized that IL-5 is the key cytokine in terminal

This is an open access article distributed under the terms of the Creative Commons Attribution-NonCommercial-ShareAlike 3.0 License, which allows others to remix, tweak, and build upon the work non-commercially, as long as the author is credited and the new creations are licensed under the identical terms.

**For reprints contact:** reprints@medknow.com

**How to cite this article:** Debta P, Debta FM, Chaudhary M, Bussari S. Evaluation of myeloid cells (tumor-associated tissue eosinophils and mast cells) infiltration in different grades of oral squamous cell carcinoma. Indian J Med Paediatr Oncol 2016;37:158-67.

## Access this article online

### Quick Response Code:



**Website:**  
www.ijmpo.org

**DOI:**  
10.4103/0971-5851.190349

differentiation of eosinophil from committed precursors.<sup>[7,8]</sup> Eosinophils are granule containing cells that are 8  $\mu\text{m}$  in diameter, and their nuclei are usually bilobed although three or more lobes are often observed. The eosinophils are characterized by its bright red granules with the dye such as eosin under light microscope, while under electron microscope, this granule shows electron-dense crystalloid core surrounded by less electron dense granule matrix.<sup>[7,9]</sup> Other cell of interest in myeloid group is mast cell. It is round or elongated in shape and can be appreciated as large cells with diameter varying from 5 to 25  $\mu\text{m}$ . The nucleus is ovoid and nonsegmented, and in the cytoplasm, there are the usual cell organelles, such as the Golgi apparatus, mitochondria, and some endoplasmic reticulum. However, the dominant cytoplasmic element is granules.<sup>[10,11]</sup> Mast cells are derived from multipotential stem cells in bone marrow.<sup>[12,13]</sup> Mast cells originate from the bone marrow as immature cells and migrate to peripheral tissues where they mature *in situ*. Mast cells are now recognized as an early and persistent infiltrating cell type in many tumors, often entering before significant tumor growth. Mast cells accumulate at the boundary between healthy tissues and malignancies and are often found in close association with blood vessels within the tumor microenvironment.<sup>[14]</sup>

Eosinophil produce nerve growth factor (NGF),<sup>[15]</sup> a cytokine not only involved in survival and functional maintenance of sympathetic neurons but also in immune regulation. NGF acts in an autocrine fashion by activating release of eosinophil peroxidase (EPO). NGF also promotes mast cell survival and activation.<sup>[15,16]</sup> Thus, eosinophils have the capacity to regulate mast cell function. Moreover, eosinophils are also thought to become active following the action of mast cells, as this cells secrete histamine and eosinophils chemoattractant factor (ECF) which attract eosinophils in tissue.<sup>[17]</sup> Mast cells are larger than eosinophils, and these are multifunctional cells which play a central role in acquired and innate immunity as well as in allergic inflammation. Mast cells are local resident of connective tissue.<sup>[10]</sup> The most striking morphological feature of mast cells is the larger number of strongly metachromatic granules present in the cytoplasm.<sup>[17]</sup> It was not until the early 1980s that study of tissue eosinophilia in head and neck cancer gained attention. In the majority of the reports, tumor-associated tissue eosinophilia correlated with favorable outcomes. Nevertheless, unfavorable association has also been reported. Tumor-associated tissue eosinophils represent a local inflammatory reaction leading to tumor cell damage. Furthermore, detection of tumor necrosis factor-alpha (TNF- $\alpha$ ) suggested that tumor-associated tissue eosinophils may play a role in the host defense mechanism. However, the actual role of tumor-associated eosinophil on tumor stroma remained a controversial topic.<sup>[18]</sup> Mast cell mediators are known

to affect endothelial cells by inducing vasodilation. They also help in recruitment of inflammatory cells. It has been postulated that mast cells play a role in promoting angiogenesis in some malignant tumors. However, in some studies, high mast cell density has been found to correlate with favorable prognosis whereas other studies show a negative correlation. Thus, a controversy still exists.<sup>[18]</sup> Till now, there are only few literature<sup>[18-20]</sup> in which both myeloid cells (Tumor-associated tissue eosinophils [TATE] and mast cells) has been observed in the OSCC. Hence, in search of new predictive factors for OSCC, our study aimed to evaluate the significance of tissue eosinophil and mast cell infiltration in different grades (WHO grading) of OSCC.

## MATERIALS AND METHODS

The study was carried out after obtaining approval from the Institutional Ethical Committee, DMIMS, Sawangi (M). It was retrospective study.

### Inclusion criteria

1. Histopathologically diagnosed cases
2. Surgically operated OSCC cases
3. Intraoral primary tumor cases of OSCC.

### Exclusion criteria

1. Immunocompromised cases such as the patients suffering from autoimmune diseases and HIV patients
2. Tumors with extensive ulceration and/or necrosis. The sample size of 30 histopathologically diagnosed cases of OSCC with 10 well, 10 moderate, and 10 poorly differentiated squamous cell carcinoma (PDSCC) was included in this study. Toluidine blue was used for mast cells staining and hematoxylin and eosin (H and E) stain was used for tumor-associated tissue eosinophil staining. Three-year follow-up of OSCC cases was done.

### Common steps for staining methods

The study was performed on paraffin embedded tissue which was fixed in 10% neutral buffered formalin and routinely processed. Paraffin wax blocks were cut using LEICA soft tissue microtome, and the sections of 5 micron were used for staining. All sections were dewaxed thoroughly in xylene and hydrated through descending grades (100%, 90%, 80%, and 70%) of alcohol to water. For TATE staining, routine H and E stain was used, after staining eosinophil granules appeared as reddish to pink and nuclei take blue color. Special stain toluidine blue was used for mast cells staining. For this, 0.5% toluidine blue (0.5 g toluidine blue in 100 ml distilled water) solution was prepared and sections were stained in this solution for 30 s. After staining mast cells, granules appeared as red in color and rest tissue were appeared as varying shades

of blue color. Common steps after staining-sections were washed in tap water then dehydrated through ascending grades (70%, 80%, 90%, and 100%) of alcohol, cleared and mounted in Distyrene plasticizer xylene.<sup>[17,21]</sup> Slides were examined under light microscope [Figures 1 and 2]. High-density areas of infiltration of these myeloid cells were selected randomly in section and cells were counted in high power fields (HPFs). Scoring criteria: <10 = 0, 10–30 = 1, 30–50 = 2, >50 = 3. For evaluation of the inter/intraexaminer consistency, slides were observed by two more examiners for counting of these cells.

## RESULTS

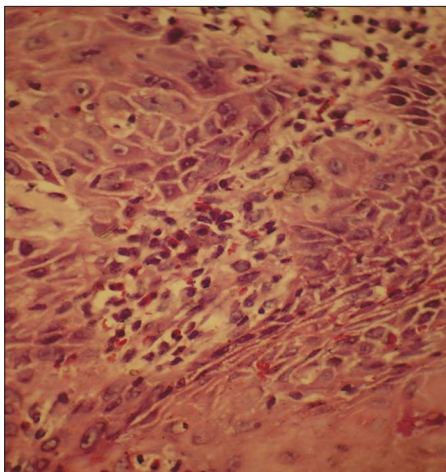
The data were collected from all cases and organized in a systemic manner. All data were formulated in table and graph derived from statistical analysis, for interpretation of results.

Among 30 cases, 63.33% cases of OSCC showed TATE-positive and 36.66% cases showed TATE-negative [Table 1]. Regarding mast cells infiltration, 66.66% OSCC cases showed mast cells positive and 33.33% cases did not show significant mast cells infiltration [Table 2]. Among our 30 cases of OSCC; 50% cases were T2N0M0, 30% T1N0M0, 13.3% T3N1M0, 3.3% T3N0M0, 3.3% T2N1M0 [Graph 1]. These myeloid cells infiltration significantly associated with age of patients but did not show any significant association with gender, site, and habit of cases [Tables 3 and 4]. We compared these cells infiltration with clinical stages of tumor, we found that their infiltration is decreasing, from Stages 1 to Stage 3 of tumor. TATE infiltration showed significant difference ( $P < 0.05$ ) in clinical stage of tumor whereas mast cells infiltration did not show any significant difference [Tables 5, 6 and Graphs 2, 3]. When we compared infiltration of TATE and mast cells in different histological grades of tumor, from well to poorly differentiated carcinoma, we found that their mean

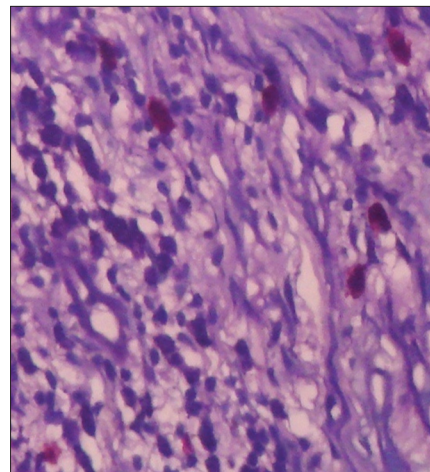
score of infiltration is decreasing from well to PDSCC [Tables 7, 8 and Graphs 4, 5]. Three-year follow-up was done to see any recurrence cases. We also found the less infiltration of these myeloid cells in recurrence cases of OSCC [Table 9 and Graph 6]. We found significant association of TATE and mast cells infiltration in OSCC cases [Graph 7].

## DISCUSSION

The immunosurveillance hypothesis posits that the immune system recognizes malignant cells as foreign agents and eliminates them. There is the potential of immune system to control cancer and the various ways that immunotherapy can boost the potential of immune system for the benefit of the patient.<sup>[22]</sup> Lorena *et al.* did study to compare the number of eosinophils identified routinely with H and E stain and by immunohistochemistry in OSCCs with TATE and found that there was no statistically significant difference ( $P > 0.05$ ) in the number of eosinophils/mm<sup>2</sup> identified by H and E stain or immunostaining technique in OSCCs with TATE.<sup>[23]</sup> So in this study, routine H and E stain was used to evaluate the infiltration of TATE in different histological grade of OSCC. Mast cells are not readily identified in H and E stains because their metachromatic granules are refractile and do not take up the stain. This metachromasia is due to the high concentrations of the sulfated mucopolysaccharide heparin.<sup>[17]</sup> Hence, special stain toluidine blue was used for mast cells staining. Although mononuclear cells, and to a lesser extent neutrophils, are also found in oral cancers, eosinophils when present, from the predominant inflammatory cell population.<sup>[24-26]</sup> Among 30 cases, 63.33% cases of OSCC showed TATE-positive and 36.66% cases showed TATE-negative [Table 1]. Regarding mast cells infiltration, 66.66% OSCC cases showed mast cells positive and 33.33% cases did not show significant mast cells infiltration [Table 2]. There are

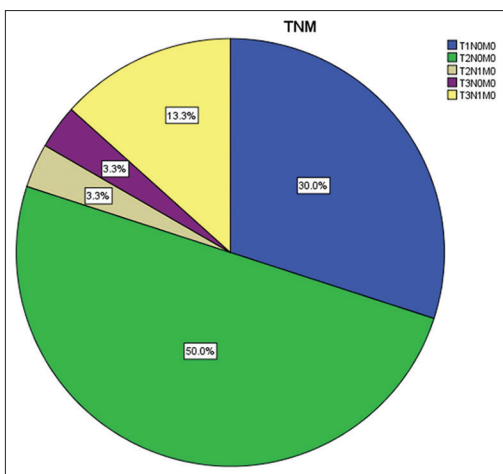


**Figure 1:** Section shows presence of tumor-associated tissue eosinophils in tumor stroma (H and E)

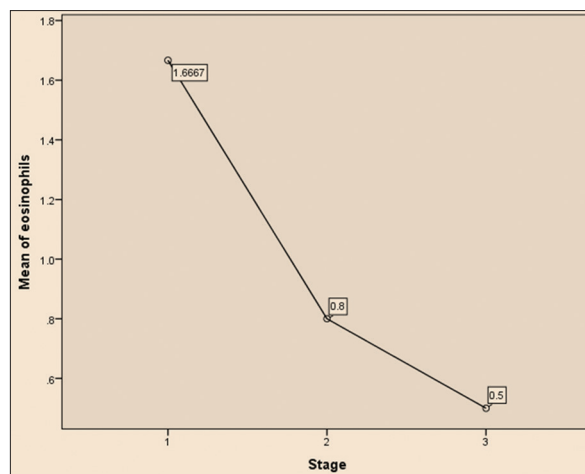


**Figure 2:** Toluidine blue stained section shows presence of mast cells (with red metachromatic granules)

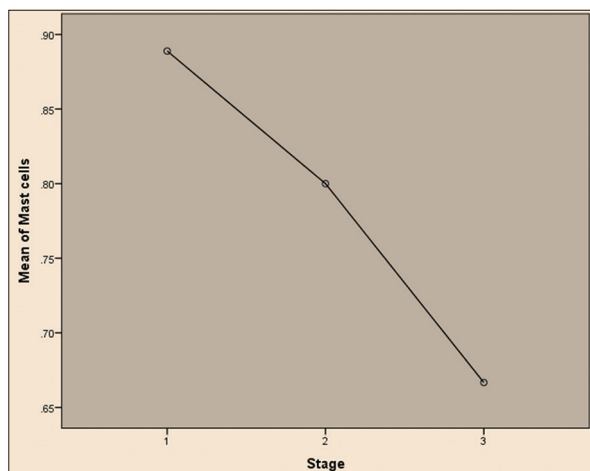




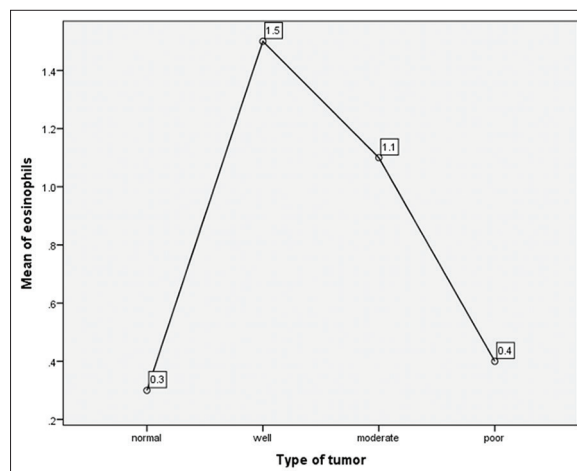
**Graph 1:** Percentage of oral squamous cell carcinoma cases as per tumor node metastasis classification



**Graph 2:** Comparison of eosinophils infiltration with stages of oral squamous cell carcinoma tumor (ANOVA test)



**Graph 3:** Comparison of mast cells infiltration with stages of oral squamous cell carcinoma tumor (ANOVA test)



**Graph 4:** Eosinophils infiltration in normal and in oral squamous cell carcinoma cases (ANOVA test)

**Table 1: Infiltration of eosinophils in positive and negative cases of oral squamous cell carcinoma (mean and P value)**

Eosinophils expression	Group statistics				t	P
	n	Mean	SD	SEM		
Eosinophils						
Negative	11	0.00	0.000	0.000	8.955	0.0001
Positive	19	1.58	0.769	0.176		

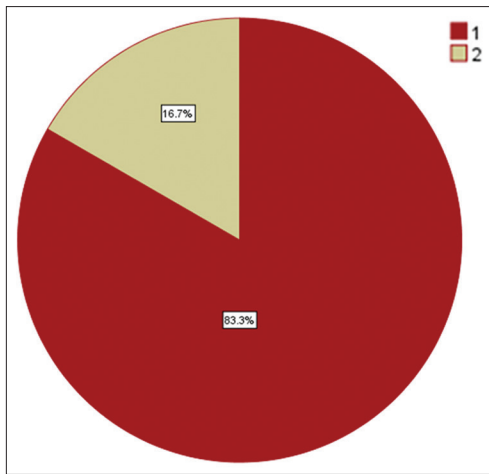
SD – Standard deviation; SEM – Standard error of mean

**Table 2: Infiltration of mast cells in positive and negative cases of oral squamous cell carcinoma (mean and P value)**

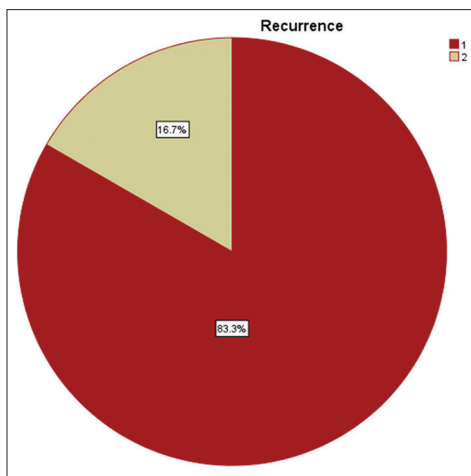
Mast cells expression	Group statistics				t	P
	n	Mean	SD	SEM		
Mast cells						
Negative	10	0.00	0.000	0.000	15.983	0.0001
Positive	20	1.10	0.308	0.069		

SD – Standard deviation; SEM – Standard error of mean

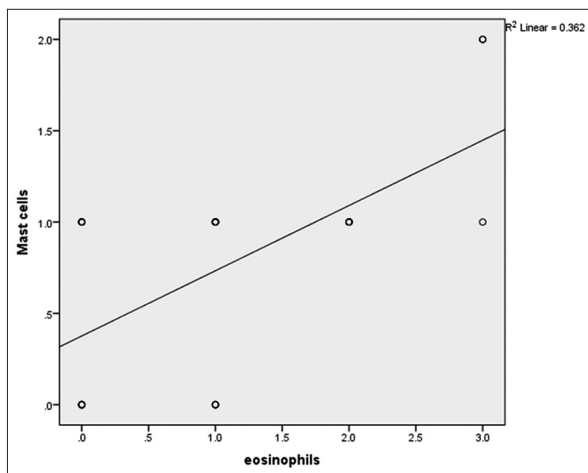
numerous methods for evaluation of tissue eosinophil and mast cell and many investigators use different grading systems. Loe and Fletcher considered more than 10 eosinophils per HPF to be moderate TATE and more than 100 eosinophils per HPF to be massive TATE. Goldsmith *et al.* assessed the prominence of eosinophils within the inflammatory infiltrate on a scale of 0–4+, according to the following criteria: 0 equals no eosinophil; 1 + equals 5–10 eosinophils per HPF; 2 + equal 10–20 eosinophils per HPF; and 3 + equals more than 30 eosinophils per HPF. Sassler *et al.* assigned the criteria as low, medium, or high-grade classification (1–5, 5–10, or >10 eosinophils per HPF, respectively). Deron *et al.* declared a tumor to be TATE-positive if more than 2 eosinophils per HPF were found.<sup>[27]</sup> Horiuchi *et al.* selected the area with the highest number of tissue eosinophil/mast cells around the tumor and counted them in 10 HPF, chosen at random.<sup>[28]</sup> Alkabuli stated that if boundaries of the classical method were modified then we can achieve good correlation between



**Graph 5:** Recurrence and no recurrence cases of OSCC



**Graph 6:** Eosinophils and mast cells expression in recurrence and no recurrence cases of oral squamous cell carcinoma



**Graph 7:** Correlation of eosinophils & mast cells infiltration in OSCC. Correlation coefficient value  $r = 0.602$  and  $P$  value = 0.000

classical method (in 10 HPF) and density method (with use of grid) and suggested modification in classical method as low (>10), moderate (50–120), and heavy (120 above)

**Table 3: Comparison of clinical parameters with eosinophils infiltration**

Parameters	Number	Negative	Positive	$\lambda^2$	$P$
Age					
≤50	11	1	10	5.687	0.017 ( $P < 0.05$ )
>50	19	10	9		
Gender	20	7	13		
Male				0.072	0.789 ( $P > 0.05$ )
Female	10	4	6		
Site					
BM	13	6	7	5.322	0.150 ( $P > 0.05$ )
BM and alveolar bone	10	5	5		
Tongue	4	0	4		
Floor of the mouth	3	0	3		
Habit					
Smoking	10	1	9	5.490	0.064 ( $P > 0.05$ )
Chewing	12	5	7		
Both	8	5	3		

BM – Buccal mucosa

grades for eosinophils in per 10 HPF.<sup>[25]</sup> We found that in normal group, tissue eosinophils count ranged from 0 to 8 eosinophils per 10 HPF. Hence, we consider the tumors to be TATE-positive if count was  $\geq 10$  eosinophils per 10 HPF. A count of  $< 10$  eosinophils per 10 HPF was considered as a TATE-negative (0). Scoring criteria:  $< 10 = 0$ ,  $10-30 = 1$ ,  $30-50 = 2$ ,  $> 50 = 3$ . For evaluation, high-density area was chosen at random. For mast cell evaluation, we have followed the same method as used for eosinophil counting. According to Igarashi *et al.*, tissue eosinophilia has been found in 22–89% of all malignant tumors.<sup>[29]</sup> It has been observed that TATE and mast cells infiltration is significantly increased in OSCC patients in comparison to normal group of patients and the infiltration of these myeloid cells (TATE and Mast cells) is decreasing from well to poorly differentiated OSCCs and it was found that mean  $\pm$  standard deviation value of TATE and mast cells/10 HPF is increased in WDSCC in comparison to moderately differentiated squamous cell carcinoma and PDSCC. The increase in number of eosinophil was also reflected with an increase of mast cell secretes ECF and histamine which attract tissue eosinophils.<sup>[17]</sup> We also found the less infiltration of these myeloid cells in recurrence cases of OSCC during their 3-year follow-up. Recurrence and regional lymph node metastases are two major hurdles in the management of the OSCC. Thus, a comprehensive investigation of the factors and molecular events which contribute to recurrence and invasion of OSCC are necessary for the development of novel strategies for prognostication and treatment. Regarding the antitumoral role of TATE in OSCC was also evaluated in several studies<sup>[19,30-34]</sup> done by several authors like Debta

**Table 4: Comparison of clinical parameters with mast cells infiltration**

Parameters	Number	Negative	Positive	$\lambda^2$	P
Age					
≤50	11	0	11	8.684	0.003 (P<0.05)
>50	19	10	9		
Gender					
Male	20	8	12	1.200	0.273 (P>0.05)
Female	10	2	8		
Site					
BM	13	6	7	3.012	0.390 (P>0.05)
BM and alveolar bone	10	3	7		
Tongue	4	0	4		
Floor of the mouth	3	1	2		
Habit					
Smoking	10	1	9	3.825	0.148 (P>0.05)
Chewing	12	5	7		
Both	8	4	4		

BM – Buccal mucosa

**Table 5: Comparison of eosinophils infiltration with stages of oral squamous cell carcinoma tumor (ANOVA test)**

Stages	n	Mean	SD	P
1	9	1.67	1.000	0.036 (P<0.05)
2	15	0.80	0.676	
3	6	0.50	1.225	
Total	30	1.00	0.983	

SD – Standard deviation

**Table 6: Comparison of mast cells infiltration with stages of oral squamous cell carcinoma tumor (ANOVA test)**

Stages	n	Mean	SD	P
1	9	0.89	0.601	0.759 (P>0.05)
2	15	0.80	0.414	
3	6	0.67	0.816	
Total	30	0.80	0.551	

SD – Standard deviation

*et al.*<sup>[19]</sup> Lowe D.<sup>[30]</sup> Gold Smith MM *et al.*<sup>[31]</sup> Gold Smith MM *et al.*<sup>[32]</sup> Gao J *et al.*<sup>[33]</sup> and Dorta RG *et al.*<sup>[34]</sup> All these studies in OSCC provided evidence for increased number of tissue eosinophil association with antitumoral role and good prognosis. Tumor-associated eosinophil has also been studied in various other malignancies of the body such as malignancies of colon, cervix, larynx, esophagus, and nasopharynx<sup>[35-39]</sup> suggested that tumor-associated tissue eosinophils are associated with favorable prognosis and this is indicative of good immune response of the body. However, it remains unknown whether it is the eosinophils

**Table 7: Eosinophils infiltration in normal and in oral squamous cell carcinoma cases (ANOVA test)**

	n	Mean	SD	P
Normal	10	0.30	0.483	0.006 (P<0.05)
Well	10	1.50	1.080	
Moderate	10	1.10	0.994	
Poor	10	0.40	0.516	
Total	40	0.83	0.931	

SD – Standard deviation

**Table 8: Mast cells infiltration in normal and in oral squamous cell carcinoma cases (ANOVA test)**

	n	Mean	SD	P
Normal	10	0.10	0.316	0.006 (P<0.05)
Well	10	0.90	0.568	
Moderate	10	0.80	0.632	
Poor	10	0.70	0.483	
Total	40	0.63	0.586	

SD – Standard deviation

**Table 9: Eosinophils and mast cells expression in recurrence and no recurrence cases of oral squamous cell carcinoma**

Cell	Recurrence	n	Mean	P
Eosinophils	1 (no recurrence)	25 (83.3)	1.16	0.044 (P<0.05)
	2 (recurrence)	5 (16.5)	0.20	
Mast cells	1 (no recurrence)	25 (83.3)	0.92	0.005 (P<0.05)
	2 (recurrence)	5 (16.5)	0.20	

themselves that lead to the improved prognosis or simply that tissue eosinophilia is a coincidental epiphenomenon initiated by a more fundamental biologic process. There is some experimental evidence for the former since it has been shown that the growth of implanted murine tumors is inhibited if the proposed implanted site has eosinophilia.<sup>[37]</sup> Direct damage to mammalian tumor cells by the eosinophil-mediated peroxidase system has also been demonstrated. TNF- $\alpha$ , secreted by eosinophils, also play an important role in OSCC as it causes death of tumor cells.<sup>[34]</sup>

The studies done by Tanooka *et al.*, Sand *et al.*, Samoszuk *et al.*, Ch'ng *et al.*, Alkhabuli, Sinnamon *et al.* and Ueda *et al.* have provided evidence for the association of increase number of mast cells with favorable prognosis and suggest that mast cells play a defensive and antitumoral role.<sup>[18,40-45]</sup> Mast cells are versatile in function and capable of regulating inflammation, host defense and innate immunity by elaboration of several chemokines and cytokines. Mast cell accumulation in tumor is probably part of a response to tumor-derived chemoattractant.<sup>[46,47]</sup> Antitumoral role of mast cells is explained by various mediators that are

detrimental to the tumor including cytokines IL-1, IL-4, and IL-6 which induce apoptosis of tumor cells and chondroitin sulfate inhibit metastasis. Mast cells also produce TNF- $\alpha$ , is directly cytotoxic to tumor cells.<sup>[43,48]</sup> In experimental mice, it has been seen that mast cell deficient mice had an increased tumor incidence after treatment with a carcinogenic agent.<sup>[40]</sup> Thus all this evidence suggest that tumor-associated tissue mast cell play a role in antitumoral activity and thus show association with a favorable prognosis.

Tumors are complex tissues whose fate depends on the levels of pro-versus antitumorogenic signals that are provided by the tumor cells, by the local tumor microenvironment (including by resident and recruited immune cells), and by the host systemically. All of these processes can potentially be negatively or positively regulated by individual products released by inflammatory cells. It is correct to point out that mast cells population and tumors can exhibit heterogeneity of phenotype, defining mechanistically how mast cells interfere with or promote the survival and progression of particular types of tumors is likely to continue to represent a challenge.<sup>[49]</sup> We believe that the understanding of the precise role of mast cells in tumor microenvironment and its interaction with other inflammatory cells infiltration will be of critical importance for the development of new targeted therapies in human cancer.

The mast cells are an important source of several proangiogenic and angiogenic factors such as histamine, heparin, chymase, basic fibroblast growth factor (FGF), vascular endothelial growth factor (VEGF), transforming growth factor-beta (TGF- $\beta$ ).<sup>[50]</sup> Several proteases released by mast cells (MMP-9 and the serine proteases chymase and tryptase) are proangiogenic; they can degrade components of the ECM and contribute to tumor invasiveness.<sup>[51,52]</sup> Once secreted, mast cell mediators can do the following: (a) Initiate tissue and immunological responses; (b) attract inflammatory cells; and (c) mediate tissue remodeling and repair.<sup>[53-56]</sup> Differences in response lie in the ability of mast cells to secrete pro-inflammatory (mainly TNF- $\alpha$ ) or anti-inflammatory (IL-10 and TGF- $\beta$ ) cytokines. For example, mast cells can secrete TNF- $\alpha$  and increase antigen presentation by dendritic cells, promoting pro-inflammatory T cell responses and monocyte/macrophage activation. However, under specific conditions, mast cells can secrete IL-10 and thus block T cell proliferation.<sup>[53,57]</sup> Moreover, mast cells can modulate adaptive immunity and angiogenesis<sup>[57,58]</sup> through the release of cytoplasmic granules and cytokines (mainly IL-1, TNF- $\alpha$ , and IL-6) and growth factors (VEGF, TGF- $\beta$ , FGF, angiopoietin-1). Therefore, mast cells can modulate the intensity of organ injury depending on the pathophysiological context.<sup>[59]</sup> Ch'ng *et al.* stated in

their experiment as like other inflammatory cells, mast cells are attracted to tumors by various factors including hypoxia, cellular damage, tissue ischemia and tumor-derived chemoattractants including stem cell factor, IL-3, and IL-4. They, in turn, produce various cytokines such as TNF- $\alpha$ , IL-1, IL-4, and IL-6 which can induce apoptosis of tumor cells, suggestive of an antitumoral role of mast cells. They concluded that mast cells have a direct inhibitory effect on the proliferation of mucosal squamous cell carcinoma.<sup>[43]</sup> Iamaroon *et al.* conducted a study on 26 OSCC patients to determine the correlation between the number of mast cells and microvessels densities. The densities of mast cells and microvessels increased in tumorigenesis which suggests that mast cells and microvessels may be used as indicator for tumor progression.<sup>[60]</sup> The cell-mediated cytotoxic effects of the mast cells have been reported, with mast cell: Tumor ratios which were >20:1. Conversely, the cytotoxic effects of the mast cells were nullified and the tumor progression was found to be enhanced when the mast cell-tumor ratios were increased from 10:1 to 1:100. Hence, the effect of mast cells against the cancer cells might depend on the concentration of the mast cells might depend on the concentration of the mast cell products in the microenvironment. Based on these findings, Tomita *et al.* hypothesized that reversing this process, i.e., enhancing the cytotoxic functions of the mast cells and suppressing their angiogenic functions, could lead to a new anticancer treatment strategy.<sup>[61]</sup>

A recent study done by Davoine *et al.* and published in 2013 suggest that eosinophils may contribute to the inflammatory response observed in OSCC and limit tumor progression by subsequent anti-tumor activity through the action of cationic proteins. They observed that inhibition of OSCC growth correlated with detectable cytotoxic granule enzyme EPO activity in culture medium.<sup>[62]</sup> Regardless, basic proteins from eosinophil granules are extremely cytotoxic, thus, small concentration of free exocytosed granules may be sufficient to exert a potent inflammatory/cytotoxic response against tumor cells.<sup>[63]</sup> In addition to these potential cytotoxic effector activities, eosinophils are also capable of exerting an immunoregulatory role in relation to the tumor environment. Eosinophils secrete a wide range of cytokines chemokines and growth factors and these may further contribute to the biological and immunological role of the eosinophil in OSCC.<sup>[64]</sup> Various causes for tumor-associated eosinophilia have been postulated: Tumor-inducing eosinophilia; tumor antigenicity-stimulated T lymphocytes that attract eosinophils by means of chemotactic factors; tumor antigens combining with antibodies to form immune complexes resulting in eosinophilia; and tumor secretagogues having eosinophil chemotactic ability or eosinophilopoietic activity. Confirmatory evidence has



been sporadic, and it is likely that several causes are responsible.<sup>[65,66]</sup> Regardless of the cause of accumulation or the mechanism by which eosinophils traffic to tumors, a salient question remains: What are the consequences of this eosinophil infiltration? Specially, are eosinophils destructive, cytotoxic effector cells limiting tumor growth as part of a host surveillance mechanism, or do the infiltrating eosinophils facilitate tumor growth by remodeling and immunoregulation of the tumor microenvironment? Eosinophils can be related to cytokines of Th1 and Th2 response via synthesis and release of interferon- $\gamma$  and IL-4, IL-5, and IL-10. In head and neck squamous cell carcinoma, it has been shown that the Th1 response is mainly associated with a better prognosis than those with the Th2 response.<sup>[67,68]</sup> Early stage of OSCC was found to express mainly INF- $\gamma$  and IL-2 genes (Th1 responses) whereas the advanced stage tumors have IL-4 and IL-10 expression (Th2 response).<sup>[69]</sup> Lorena *et al.* found intimate association of eosinophils with strong lymphoplasmacytic cell infiltration in OSCC.<sup>[23]</sup> Cormier *et al.* suggest that the recruitment and accumulation of eosinophils to tumors are part of a site-specific, early host-recognition response.<sup>[70]</sup> With better characterization of infiltrating immune cells, the precise role of inflammation in cancer has begun to be elucidated, leading to a resolution of the initial contradiction that inflammation is protective in certain tumors yet detrimental in others. The malignant state is unleashed by defect in communication pathways, which recruit host cells to become active participants. Inflammatory cells and their interaction with different cytokines have significant impact on carcinoma. Advances in diagnosis and treatment have slowly accumulated but a sound understanding of underlying cell biology is likely to enable future, much-needed progress. Although TATE and mast cells are commonly encountered in human cancer, their functional role in the tumor microenvironment remains an ambiguity, can represent another promising approach in cancer immunotherapy. Immunotherapy using IL-2 has been shown to have moderate success against some tumors and is often associated with “unexpected” but significant eosinophilia, which resulted in assumptions suggesting that eosinophils possess anti-tumor activity, at least *in vitro*.<sup>[71]</sup> IL-2 is recognized as a potent regulator of eosinophil activation, *in vitro*.<sup>[72,73]</sup> IL-2 induced release of EPO in culture media is associated with inhibition of oral cancer cell proliferation.<sup>[62]</sup> Myeloid cells represent novel targets for therapeutic strategies. The mobilization and recruitment of myeloid cells by the tumor defines myeloid cells as a potential delivery system to target the tumor microenvironment. Targeting cytokines and cytotoxic proteins to tumors by means of gene-modified myeloid cells thus represents a promising strategy to treat cancer.<sup>[74]</sup> Thus, we can suggest that the infiltration of

TATE and mast cells (myeloid cells) could become, in the future, useful for therapeutic approaches in OSCC cases.

## CONCLUSION

Now, it is time to integrate the quantification of these myeloid cells (TATE and mast cells) infiltration for routine microscopic evaluation of OSCC. Thus, careful studies on the nature of efficient immune reactions, the place where they are initiated, the cell and molecules involved, and their impact at different stages of the disease should provide new tool and goal for targeted therapies. Most pathologists do not routinely count eosinophils in malignant tumors although this determination in H and E sections can be easily performed. Furthermore, one should be attentive more if higher eosinophil counts are evident in OSCC. The eosinophil and mast cells counts could become, in the future, useful for therapeutic approaches in this subset of patients. Hence, it is recommended that quantitative assessment of eosinophils and mast cells should become part of the routine diagnosis.

## Financial support and sponsorship

Nil.

## Conflicts of interest

There are no conflicts of interest.

## REFERENCES

1. Boring CC, Squires TS, Tong T, Montgomery S. Cancer statistics, 1994. *CA Cancer J Clin* 1994;44:7-26.
2. Chang SS. American Joint Committee on Cancer. 6<sup>th</sup> ed. New York: Springer; 2002.
3. Witz IP, Levy-Nissenbaum O. The tumor microenvironment in the post-PAGET era. *Cancer Lett* 2006;242:1-10.
4. Graziano DF, Finn OJ. Tumor antigens and tumor antigen discovery. *Cancer Treat Res* 2005;123:89-111.
5. Stewart S, Edward EM. Immunology, Immunopathology and Immunity. 6<sup>th</sup> ed. Washington D.C.: ASM; 2001. p. 53-8.
6. Gabrilovich D. Mechanisms and functional significance of tumour-induced dendritic-cell defects. *Nat Rev Immunol* 2004;4:941-52.
7. Lee GR, Foerster J, Lukens J, Paraskevas F, Greer JP, Rodgers GM. *Wintrobe's Clinical Haematology*. 10<sup>th</sup> ed., Vol. 2. London: Williams & Wilkins; 1999. p. 351-8, 362-72.
8. Miller F, de Harven E, Palade GE. The structure of eosinophil leukocyte granules in rodents and in man. *J Cell Biol* 1966;31:349-62.
9. Lowe D, Jorizzo J, Hutt MS. Tumour-associated eosinophilia: A review. *J Clin Pathol* 1981;34:1343-8.
10. Ankle RM, Kale DA, Nayak R. Mast cells are increased in leukoplakia, oral submucous fibrosis, oral lichen planus and oral squamous cell carcinoma. *J Oral Maxillofac Pathol* 2007;11:18-22.
11. Richard BO, William DJ, Timothy GB. *Andrew's Diseases of the Skin: Clinical Dermatology*. 9<sup>th</sup> ed. Philadelphia: WB Saunders; 2000. p. 11-2.
12. Galli SJ. Mast cells and basophils. *Curr Opin Hematol* 2000;7:32-9.
13. Kitamura Y, Kasugai T, Arizono N, Matsuda H. Development of mast cells and basophils: Processes and regulation mechanisms. *Am J Med Sci* 1993;306:185-91.
14. Crivellato E, Nico B, Ribatti D. Mast cells and tumour



- angiogenesis: New insight from experimental carcinogenesis. *Cancer Lett* 2008;269:1-6.
15. Solomon A, Aloe L, Pe'er J, Frucht-Pery J, Bonini S, Bonini S, *et al.* Nerve growth factor is preformed in and activates human peripheral blood eosinophils. *J Allergy Clin Immunol* 1998;102:454-60.
  16. Bullock ED, Johnson EM Jr. Nerve growth factor induces the expression of certain cytokine genes and bcl-2 in mast cells. Potential role in survival promotion. *J Biol Chem* 1996;271:27500-8.
  17. Culling CF, Allison RT, Barr WT. *Cellular Pathology Technique*. 4<sup>th</sup> ed. London, Butterworth – Heinemann Ltd.; 1985. p. 460-1.
  18. Alkhabuli JO. Significance of neo-angiogenesis and immuno-surveillance cells in squamous cell carcinoma of the tongue. *Libyan J Med* 2007;2:30-9.
  19. Debta P, Debta FM, Chaudhary M, Wadhwan V. Evaluation of prognostic significance of immunological cells (tissue eosinophil and mast cell) infiltration in oral squamous cell carcinoma. *J Cancer Sci Ther* 2011;3:201-4.
  20. Debta P, Debta FM, Chaudhary M, Dani A. Evaluation of infiltration of immunological cell (tumour associated tissue eosinophils and mast cells) in oral squamous cell carcinoma by using special stains. *Br J Med Res* 2012;2:75-85.
  21. Bancraft JD, Gamble M. *Theory and Practice of Histological Techniques*. 4<sup>th</sup> ed. Germany, Elsevier: Churchill Livingstone; 2002. p. 346-7.
  22. Finn OJ. Molecular origins of cancer. *Cancer immunology. N Engl J Med* 2008;358:2704-15.
  23. Lorena SC, Dorta RG, Landman G, Nonogaki S, Oliveira DT. Morphometric analysis of the tumor associated tissue eosinophilia in the oral squamous cell carcinoma using different staining techniques. *Histol Histopathol* 2003;18:709-13.
  24. Falconieri G, Luna MA, Pizzolitto S, DeMaglio G, Angione V, Rocco M. Eosinophil-rich squamous carcinoma of the oral cavity: A study of 13 cases and delineation of a possible new microscopic entity. *Ann Diagn Pathol* 2008;12:322-7.
  25. Alkhabuli JO, High AS. Significance of eosinophil counting in tumor associated tissue eosinophilia (TATE). *Oral Oncol* 2006;42:849-50.
  26. Alrawi SJ, Tan D, Stoler DL, Dayton M, Anderson GR, Mojica P, *et al.* Tissue eosinophilic infiltration: A useful marker for assessing stromal invasion, survival and locoregional recurrence in head and neck squamous neoplasia. *Cancer J* 2005;11:217-25.
  27. Ercan I, Cakir B, Basak T, Ozdemir T, Sayin I, Turgut S. Prognostic significance of stromal eosinophilic infiltration in cancer of the larynx. *Otolaryngol Head Neck Surg* 2005;132:869-73.
  28. Horiuchi K, Mishima K, Ohsawa M, Sugimura M, Aozasa K. Prognostic factors for well-differentiated squamous cell carcinoma in the oral cavity with emphasis on immunohistochemical evaluation. *J Surg Oncol* 1993;53:92-6.
  29. Igarashi T, Urade M, Sugi M. Oral squamous cell carcinoma with eosinophilic infiltration. *Jpn J Oral Surg* 1985;31:1564-8.
  30. Lowe D, Fletcher CD. Eosinophilia in squamous cell carcinoma of the oral cavity, external genitalia and anus – Clinical correlations. *Histopathology* 1984;8:627-32.
  31. Goldsmith MM, Cresson DH, Askin FB. The prognostic significance of stromal eosinophilia in head and neck cancer. *Otolaryngol Head Neck Surg* 1987;96:319-24.
  32. Goldsmith MM, Belchis DA, Cresson DH, Merritt WD 3<sup>rd</sup>, Askin FB. The importance of the eosinophil in head and neck cancer. *Otolaryngol Head Neck Surg* 1992;106:27-33.
  33. Gao J, He Y, Wu L. The clinical analysis of eosinophil infiltration in human squamous cell carcinoma of buccal mucosa. *Hua Xi Kou Qiang Yi Xue Za Zhi* 1997;15:228-9, 232.
  34. Dorta RG, Landman G, Kowalski LP, Lauris JR, Latorre MR, Oliveira DT. Tumour-associated tissue eosinophilia as a prognostic factor in oral squamous cell carcinomas. *Histopathology* 2002;41:152-7.
  35. Pretlow TP, Keith EF, Cryar AK, Bartolucci AA, Pitts AM, Pretlow TG 2<sup>nd</sup>, *et al.* Eosinophil infiltration of human colonic carcinomas as a prognostic indicator. *Cancer Res* 1983;43:2997-3000.
  36. Lowe DG. Carcinoma of the cervix with massive eosinophilia. *Br J Obstet Gynaecol* 1988;95:393-401.
  37. Thompson AC, Bradley PJ, Griffin NR. Tumor-associated tissue eosinophilia and long-term prognosis for carcinoma of the larynx. *Am J Surg* 1994;168:469-71.
  38. Ohashi Y, Ishibashi S, Suzuki T, Shineha R, Moriya T, Satomi S, *et al.* Significance of tumor associated tissue eosinophilia and other inflammatory cell infiltrate in early esophageal squamous cell carcinoma. *Anticancer Res* 2000;20:3025-30.
  39. Fujii M, Yamashita T, Ishiguro R, Tashiro M, Kameyama K. Significance of epidermal growth factor receptor and tumor associated tissue eosinophilia in the prognosis of patients with nasopharyngeal carcinoma. *Auris Nasus Larynx* 2002;29:175-81.
  40. Tanooka H, Kitamura Y, Sado T, Tanaka K, Nagase M, Kondo S. Evidence for involvement of mast cells in tumor suppression in mice. *J Natl Cancer Inst* 1982;69:1305-9.
  41. Sand L, Hilliges M, Larsson PA, Wallstrom M, Hirsch JM. Effects of long-term administration of cancer-promoting substances on oral subepithelial mast cells in the rat. *Anticancer Res* 2002;22:2623-7.
  42. Samoszuk M, Kanakubo E, Chan JK. Degranulating mast cells in fibrotic regions of human tumors and evidence that mast cell heparin interferes with the growth of tumor cells through a mechanism involving fibroblasts. *BMC Cancer* 2005;5:121.
  43. Ch'ng S, Sullivan M, Yuan L, Davis P, Tan ST. Mast cells dysregulate apoptotic and cell cycle genes in mucosal squamous cell carcinoma. *Cancer Cell Int* 2006;6:28.
  44. Sinnamon MJ, Carter KJ, Sims LP, Lafleur B, Fingleton B, Matrisian LM. A protective role of mast cells in intestinal tumorigenesis. *Carcinogenesis* 2008;29:880-6.
  45. Ueda T, Aozasa K, Tsujimoto M, Yoshikawa H, Kato T, Ono K, *et al.* Prognostic significance of mast cells in soft tissue sarcoma. *Cancer* 1988;62:2416-9.
  46. Sharada P, Girish HC, Umadevi HS, Priya NS. Mast cells in health and disease: A review. *J Indian Acad Oral Med Radiol* 2006;18:202-5.
  47. Tony B, Stephen B, Neil C, Christopher G. *Rook's Textbook of Dermatology*. 7<sup>th</sup> ed. Malden, Man: Blackwell Publication; 2004. p.3.73-3.76
  48. Theoharides TC, Conti P. Mast cells: The Jekyll and Hyde of tumor growth. *Trends Immunol* 2004;25:235-41.
  49. Marichal T, Tsai M, Galli SJ. Mast cells: Potential positive and negative roles in tumor biology. *Cancer Immunol Res* 2013;1:269-79.
  50. Michailidou EZ, Markopoulos AK, Antoniadis DZ. Mast cells and angiogenesis in oral malignant and premalignant lesions. *Open Dent J* 2008;2:126-32.
  51. Baram D, Vaday GG, Salamon P, Drucker I, Hershkoviz R, Mekori YA. Human mast cells release metalloproteinase-9 on contact with activated T cells: Juxtacrine regulation by TNF-alpha. *J Immunol* 2001;167:4008-16.
  52. Huang C, Sali A, Stevens RL. Regulation and function of mast cell proteases in inflammation. *J Clin Immunol* 1998;18:169-83.
  53. Marshall JS. Mast-cell responses to pathogens. *Nat Rev Immunol* 2004;4:787-99.
  54. Galli SJ, Nakae S, Tsai M. Mast cells in the development of adaptive immune responses. *Nat Immunol* 2005;6:135-42.
  55. Gurish MF, Austen KF. The diverse roles of mast cells. *J Exp Med* 2001;194:F1-5.
  56. Maurer M, Theoharides T, Granstein RD, Bischoff SC, Bienenstock J, Henz B, *et al.* What is the physiological function of mast cells? *Exp Dermatol* 2003;12:886-910.

57. Galli SJ, Grimaldeston M, Tsai M. Immunomodulatory mast cells: Negative, as well as positive, regulators of immunity. *Nat Rev Immunol* 2008;8:478-86.
58. Rodewald HR, Feyerabend TB. Widespread immunological functions of mast cells: Fact or fiction? *Immunity* 2012;37:13-24.
59. Knol EF, Olszewski M. Basophils and mast cells: Underdog in immune regulation? *Immunol Lett* 2011;138:28-31.
60. Iamaroon A, Pongsiriwet S, Jittidecharaks S, Pattanaporn K, Prapayasatok S, Wanachantararak S. Increase of mast cells and tumor angiogenesis in oral squamous cell carcinoma. *J Oral Pathol Med* 2003;32:195-9.
61. Tomita M, Matsuzaki Y, Onitsuka T. Effect of mast cells on tumor angiogenesis in lung cancer. *Ann Thorac Surg* 2000;69:1686-90.
62. Davoine F, Sim A, Tang C, Fisher S, Ethier C, Puttagunta L, *et al.* Eosinophils in human oral squamous carcinoma; role of prostaglandin D2. *J Inflamm (Lond)* 2013;10:4.
63. Kubo H, Loegering DA, Adolphson CR, Gleich GJ. Cytotoxic properties of eosinophil granule major basic protein for tumor cells. *Int Arch Allergy Immunol* 1999;118:426-8.
64. Hogan SP, Rosenberg HF, Moqbel R, Phipps S, Foster PS, Lacy P, *et al.* Eosinophils: Biological properties and role in health and disease. *Clin Exp Allergy* 2008;38:709-50.
65. Pincus SH, Schooley WR, DiNapoli AM, Broder S. Metabolic heterogeneity of eosinophils from normal and hypereosinophilic patients. *Blood* 1981;58:1175-81.
66. Manthorpe R, Egeberg J, Hesselvik M, Videbaek A. Unique eosinophil granules in a case of T-cell lymphoma. *Scand J Haematol* 1977;19:129-44.
67. van Herpen CM, van der Laak JA, de Vries IJ, van Krieken JH, de Wilde PC, Balvers MG, *et al.* Intratumoral recombinant human interleukin-12 administration in head and neck squamous cell carcinoma patients modifies locoregional lymph node architecture and induces natural killer cell infiltration in the primary tumor. *Clin Cancer Res* 2005;11:1899-909.
68. Dasgupta S, Bhattacharya-Chatterjee M, O'Malley BW Jr., Chatterjee SK. Recombinant vaccinia virus expressing interleukin-2 invokes anti-tumor cellular immunity in an orthotopic murine model of head and neck squamous cell carcinoma. *Mol Ther* 2006;13:183-93.
69. Agarwal A, Rani M, Saha GK, Valarmathi TM, Bahadur S, Mohanti BK, *et al.* Disregulated expression of the Th2 cytokine gene in patients with intraoral squamous cell carcinoma. *Immunol Invest* 2003;32:17-30.
70. Cormier SA, Taranova AG, Bedient C, Nguyen T, Protheroe C, Pero R, *et al.* Pivotal advance: Eosinophil infiltration of solid tumors is an early and persistent inflammatory host response. *J Leukoc Biol* 2006;79:1131-9.
71. Rivoltini L, Viggiano V, Spinazzè S, Santoro A, Colombo MP, Takatsu K, *et al.* *In vitro* anti-tumor activity of eosinophils from cancer patients treated with subcutaneous administration of interleukin 2. Role of interleukin 5. *Int J Cancer* 1993;54:8-15.
72. Bossé M, Audette M, Ferland C, Pelletier G, Chu HW, Dakhama A, *et al.* Gene expression of interleukin-2 in purified human peripheral blood eosinophils. *Immunology* 1996;87:149-54.
73. Levi-Schaffer F, Barkans J, Newman TM, Ying S, Wakelin M, Hohenstein R, *et al.* Identification of interleukin-2 in human peripheral blood eosinophils. *Immunology* 1996;87:155-61.
74. Ferrara N, Kerbel RS. Angiogenesis as a therapeutic target. *Nature* 2005;438:967-74.