

Original Article

The Effectiveness of Micro-osteoperforations during Canine Retraction: A Three-dimensional Randomized Clinical Trial

Basema Alqadasi¹, Khalid Aldhorae², Esam Halboub³, Nasrin Mahgoub⁴, Akram Alnasri¹, Ali Assiry⁵, Hou Y. Xia¹

¹Department of Orthodontics, Hospital of Stomatology, Xi'an Jiaotong University, Xi'an, Shaanxi, China, ²Department of Orthodontics, College of Dentistry, Thamar University, Thamar, Yemen, ³Department of Maxillofacial Surgery and Diagnostic Science, College of Dentistry, Jazan University, Jazan, Kingdom of Saudi Arabia, ⁴Department of Dentistry, First affiliated Hospital, Xi'an Jiaotong University, Xi'an, Shaanxi, China, ⁵Department of Preventive Dental Sciences, Najran University, Najran, Kingdom of Saudi Arabia

Received : 26-05-19.
Accepted : 19-07-19.
Published : 04-10-19.

ABSTRACT

Aim: A major challenge in orthodontics is decreasing treatment time without compromising treatment outcome. The purpose of this split-mouth trial was to evaluate micro-osteoperforations (MOPs) in accelerating orthodontic tooth movement. **Materials and Methods:** Eight patients of both genders were selected, age ranging between 15 and 40 years, with Class II Division 1 malocclusion. The participants in this trial with MOPs were randomly allocated to either the right or the left side, distal to the maxillary canine. First maxillary premolars were extracted as part of the treatment plan on both sides and then canine retraction was applied. Miniscrews were used to support anchorage. MOP side received (three small perforations) placed on the buccal bone, distal to the maxillary canine, on randomly selected side using an automated mini-implant driver and the other side was the control side. Blinding was used at the data collection and analysis stages. The primary outcome was the rate of canine retraction measured with a three-dimensional (3D) digital model from the baseline to the first 2 weeks superimposed at the rugae area from the baseline to the first, second, and third months. The following secondary outcomes were examined: anchorage loss, canine tipping, canine rotation, root resorption, plaque index, and gingival index. Pain level, pain interference with the patients' daily life, patients' satisfaction with the procedure and degree of ease, willingness to repeat the procedure, and recommendation to others were also evaluated. **Results:** No statistically significant difference was observed in the rates of tooth movement between the MOP and the control sides at all-time points (first month: $P = 0.77$; mean difference, 0.2 mm; 95% CI, -0.13, 0.18 mm; second month: $P = 0.50$; mean difference, -0.08 mm; 95% CI, -0.33, 0.16 mm; third month: $P = 0.76$; mean difference, -0.05 mm; 95% CI, -0.40, 0.29 mm). There were also no differences in anchorage loss, rotation, tipping, root resorption, plaque index, periodontal index, and pain perception between the MOP and control sides at any time point ($P > 0.05$). MOPs had no effect on the patients' daily life except for a feeling of swelling on the first day ($P = 0.05$). Level of satisfaction and degree of easiness of the procedure were high. **Conclusion:** According to our clinical trial, MOPs cannot help in speeding up a canine retraction.

KEYWORDS: Accelerating tooth movement, cements/enamel junction, marginal bone crest, micro-osteoperforation

Address for correspondence: Hou Y. Xia,

Department of Orthodontics, Hospital of Stomatology,
Xi'an Jiaotong University, Xi'an, Shaanxi, China.
E-mail: 369Hyx@163.com

This is an open access journal, and articles are distributed under the terms of the Creative Commons Attribution-NonCommercial-ShareAlike 4.0 License, which allows others to remix, tweak, and build upon the work non-commercially, as long as appropriate credit is given and the new creations are licensed under the identical terms.

For reprints contact: reprints@medknow.com

How to cite this article: Alqadasi B, Aldhorae K, Halboub E, Mahgoub N, Alnasri A, Assiry A, *et al.* The effectiveness of micro-osteoperforations during canine retraction: A three-dimensional randomized clinical trial. *J Int Soc Prevent Communit Dent* 2019;9:637-45.

Access this article online

Quick Response Code:



Website: www.jispcd.org

DOI: 10.4103/jispcd.JISPCD_233_19

INTRODUCTION AND LITERATURE REVIEW

Longer treatment periods on orthodontic treatment are associated with root resorption and periodontal disease are common problems, which we need to decrease, so a shorter treatment period is important, especially for older patients, who typically require a longer treatment span because their metabolic rate is much slower than younger patients.

The new era in orthodontics aims to accelerate tooth movement without using any harmful surgical procedures,^[1-3] according to the familiar standard theory of activation of the inflammatory process and osteoclasts.^[4] Acceleration method is needed to decrease the side effects of treatment such as root resorption, caries, periodontal inflammation, and patient follow-up times.^[5,6]

Tooth movement usually arises from the arranged activity of alveolar bone remodeling system (osteoclasts and osteoblasts). The applied orthodontic force on the tooth causes tension in the surrounding Periodontal ligaments and the alveolar bone, this results in bone resorption and formation of area of tension and pressure on tooth surfaces. The speed of tooth movement in orthodontic treatment is mainly affected by the remodeling process.^[4,7]

In general, three common methods^[8] are used before speeding up the tooth movement, the first method is smearing physical stimulating substance to initiate bone anabolic and catabolic process, for example, low-level laser therapy,^[9,10] vibration,^[11] and AcceleDent System.^[12,13] These procedures are not the paths that are stimulated throughout the usual orthodontic tooth movement. Rather, these stimulant-activated processes activated cells that are responsible for resorption (osteoclasts) or bone formation (osteoblasts).^[7,14] The second method is using chemicals or medication,^[15] for example, an injection of prostaglandins, vitamin D3, and osteocalcin locally in the place of the required movement. The third approach encourages natural bone remodeling in ways that are activated with surgical, minimal surgical methods, and stimulants during orthodontic treatments (such as cortectomies,^[7,16] piezocision,^[3,7,17-19] and micro-osteoperforations [MOPs]^[2,7,20-22]). Because of the need for the development of the previous approach mentioned and for more trials of these methods, we present our study, to evaluate MOPs as one of the simplest and safest methods to accelerate orthodontic treatment and to improve patients' acceptance for the treatment duration, especially adults. In 2016, systematic review^[23] showed that minimally invasive method can accelerate tooth movement with high difference from the first month of application.

All research results of previous trials showed that orderly simple distress from applying MOPs will accelerate the tooth movements^[14] except one study,^[24] which showed that MOPs did not add any increase in tooth movement during canine retraction. Almost all studies showed that there is root tipping without any mention of loss of anchorage in the presence of temporary anchorage device (TAD) and no root resorption.

We hypothesize that harnessing and amplifying the body's natural inflammatory response to orthodontic movement using MOPs in alveolar bone would produce a minimally invasive, safe, and easily performed protocol to accelerate tooth movement.

In our study, we wanted to inspect the effectiveness of MOPs in the acceleration of tooth movement during canine retraction as a minimally invasive method by measuring the anteroposterior displacement of canine in both sides by using three-dimensional (3D) digital models in the planed time frame as primary outcome and to measure the root resorption and pain intensity during canine retraction as secondary outcome.

MATERIALS AND METHODS

This study was a split-mouth randomized clinical trial with a 1:1 allocation. The research was accepted by the stomatology department of Xi'an Jiaotong University Hospital in Xi'an City, Shaanxi Province, China. Ethical approval was obtained from the ethics committee with approval number, NXjkqII [2017] No.006. The research sample involved eight patients of ages ranging between 15 and 40 years. The main inclusion criteria of the study were patients with Class II Division 1 malocclusion who required the extraction of both maxillary first premolars with full erupted canine. Table 1 summarizes the rest of the inclusion and exclusion criteria of the study. Patients who agreed to participate in the experiments were asked to fill out and sign the agreement and the ethics form after clarifying the purpose of the intervention and the associated risks and benefits.

All participant were referred to the periodontics department for checking the periodontal and oral hygiene condition before starting the orthodontic treatment. The orthodontic treatment was carried out by the same orthodontic resident (BA) using fixed orthodontic appliance (McLaughlin, Bennt and Trevisi prescription and self-ligating bracket) with maximum anchorage support using miniscrews, also direct anchorage was used by applying the force directly from minisrew to canine to prevent mesial movement of posterior teeth during canine retraction. Indirect anchorage was applied by ligating upper second

Table 1: Inclusion and exclusion criteria

Clinical diagnosis	Class II
Age / gender	15–40 years old, both men and women
Oral examination	Good oral hygiene; adequate attached gingiva thickness (1–2mm); no periodontal disease
Bracket type	Both self-ligating brackets and non-self-ligating brackets, self-ligating is better
The treatment plan	The first maxillary bilateral premolars need to be extracted (the experiment is only limited to the upper jaw, so whether the mandibular first premolar is removed from the teeth and does not affect the inclusion of the patient); And implant anchorage is needed in the posterior area
Anamnesis	No history of previous orthodontic treatment; No systemic disease (which effects bone cycle) No history of periodontal disease treatment
X-ray examination	No radiographic bone loss on-smoking

premolars to miniscrew to prevent mesial movements of posterior teeth.

The treatment strategy was as follows: the extraction of the maxillary first premolar, which was carried out at the beginning of the treatment and then canine retraction was performed after finishing the alignment and leveling stage.

RANDOMIZATION

The intervention was randomly allocated to either right or left side with 1:1 allocation ratio.

To increase the unpredictability of the random allocation sequence, the sequences with either right or left were concealed in opaque envelope and shuffled. Each participant was asked to pick one sealed envelope to assign to the intervention either on the right or left side. The patient's model was divided into two groups (MOPs side and control side), then the trial group gets MOPs on the right or left side, the aim of the non-determined side was to avoid unequal occlusal forces. Power arms were used to advance the retraction on the maxillary canine brackets. After the extractions and complete alignment stage, impressions and cone beam computed tomography (CBCT) were taken. The canine retraction was attained with calibrated 150-g nickel-titanium closing coil springs attached from the TAD to supporting power arms on the bracket of the canine.

INTERVENTIONS

The trial group obtained three perforations; the flapless method was performed on the left or right side in the middle of the extraction space using automated mini-implant instrumentation, each perforation was around 1.5–2mm width and 5–7mm depth [Figure 1A and B]. No antibiotic prescription was given; the nonexperimental side of the same arch was considered as the control group.

PRIMARY OUTCOME

The experimental procedure has five stages: before the experiment, after two weeks, after one month, two months, and three months of canine retraction. At

every stage, impressions and photographs were taken to monitor the rate of tooth movement.

Model assessment: The patient's name, date, and the number of visits were labeled and stored. Forty cast models were scanned in a three shape scanner. All cast measurements were made by Geomagic program (engineer software form 3D system). After reference points were determined (1 midline point, 2 and 3 on the molar cusp, 4 and 5 tip of the buccal cusp of a second premolar, 6 and 7 tip of the buccal cusp of canine), lines were drawn to measure the difference of tooth movement [Figure 2]. The distance between line 5 and 6 (which represented the difference in distance of tooth movement between the control and experimental group) was calculated.^[18,25]

SECONDARY OUTCOMES

Cone beam computed tomography assessment

Before CBCT scanning, the patient was placed in a seated position with head upright position so that the intersection lines were straight horizontal and vertical through the center of the region of interest. All CBCT images were taken with the following parameters: 47 mA, 120 kVp, 250 mm voxel resolution, and 16-cm field of view.

Root resorption

The measurements of root resorption before and after the procedure were carried out by determining a point on the crown tip and another point on the apex tip of the root to determine the total canine length [Figure 3A].^[26,27] The height of the bone was specified by measuring the distance between cemento-enamel junction and marginal bone crest from the buccal and lingual sides by drawing two lines between them^[28] [Figure 3B]. All measurements were calculated by one examiner, the reliability coefficient was used to evaluate the measurement twice weekly, showing excellent agreement.

Pain intensity

The participating patients were asked to evaluate their level of discomfort and pain on the day of the procedure as well as on 2, 7, and 28 days after the procedure.

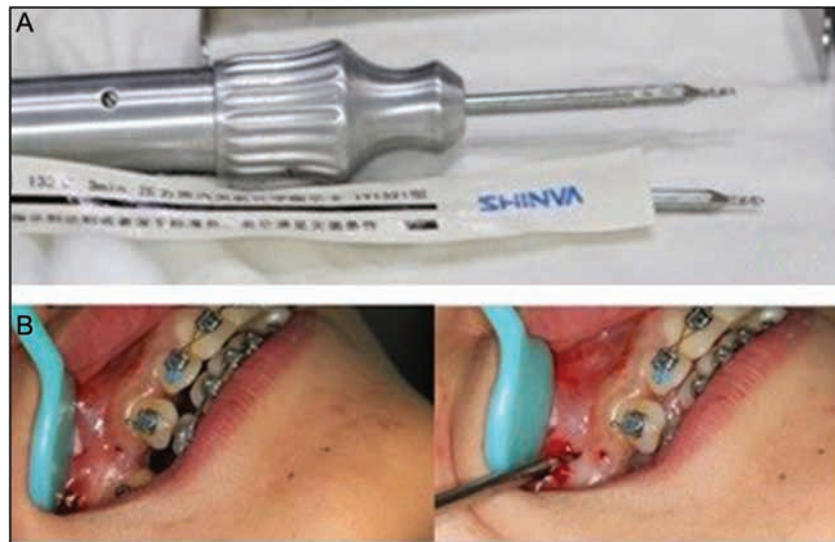

Figure 1: (A) MOP instruments hand-assisted mini-implant. (B) Micro-osteoperforations procedure

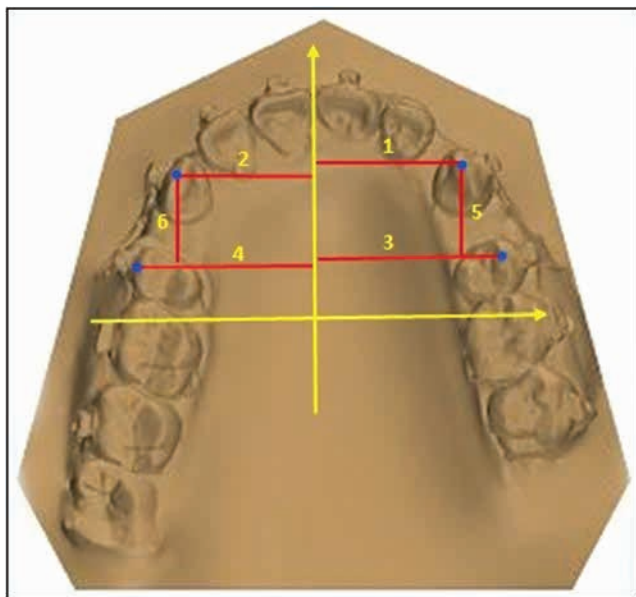


Figure 2: Line 5 and 6 represent the distances between canine and second premolar in controls and experimental sides

A numeric rating scale short form of questionnaire (https://www.physiopeedia.com/Shortform_McGill_Pain_Questionnaire) was applied. The patients were instructed to select a digit on a scale (from 0 to 10) to describe their pain with 0 for “no pain” and 10 for “severe pain.”

STATISTICAL ANALYSIS

Data were handled and analyzed using the Statistical Package for the Social Sciences (SPSS) software, version 21 (IBM, Armonk, New York). Owing to the small sample size, all statistical analyses were performed using nonparametric tests. Wilcoxon signed-rank test was used to compare different measurement on both sides. To compare an individual measurement in different

time points, repeated measures analysis of variance (ANOVA) was applied. A P value of < 0.05 was considered statistically significant. Reliability coefficient was used to evaluate the reliability of primary outcomes measurements by one examiner. All participants were randomly selected, six of 3D superimposed digital models and canine displacement were measured twice within two-week intervals, the reliability coefficient was found to be 0.9, which showed excellent superimposing and measurement agreement.

RESULTS

MODEL CAST ANALYSIS

All statistical tests in different time points revealed no significant differences between MOPs and control sides except for the test after three months where the displacement movement of the canine was higher in MOPs compared to the control side ($P = 0.002$) [Table 2]. The repeated measures ANOVA for the difference in distance between any two-time points revealed significant differences for MOPs ($P = 0.007$) and control sides ($P = 0.002$). Table 3 presents the differences between time points that were statistically significant.

CONE BEAM COMPUTED TOMOGRAPHY ANALYSIS FOR ROOT RESORPTION

Table 4 presents the measured canine lengths at baseline and after 3 months of the study. Neither MOPs (measurement difference = 0.03mm) nor control (measurement difference = 0.05mm) showed a significant difference between the two measurements [Figure 4]. Comparing these differences between both groups did not reveal a statistically significant difference ($P = 0.886$) [Figure 5].

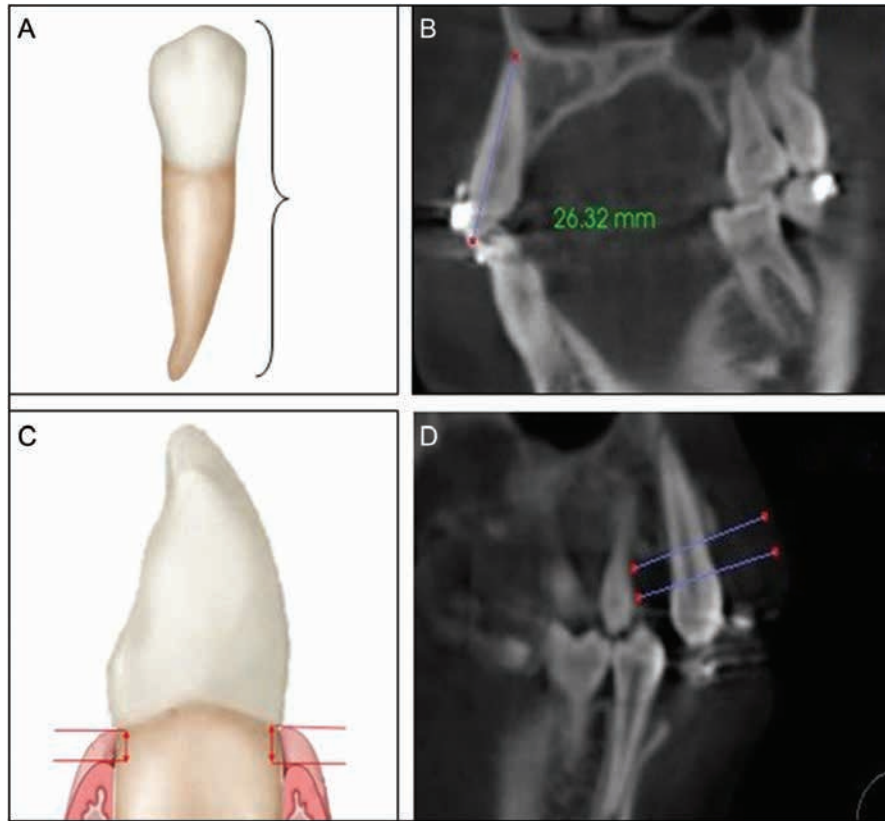


Figure 3: (A and B) Total tooth length: the distance between root apex and tip of the crown. (C and D) Cementoenamel Junction to Marginal Alveolar Bone Crest Distance

CONE BEAM COMPUTED TOMOGRAPHY ANALYSIS FOR BONE HEIGHT

The results did not show any differences between both sides (MOPs and control) with regard to the bone height whether buccally or palatally. Neither the MOP side (measurement difference = 0.11 and 0.23 mm, for buccal and palatal, respectively) nor the control side (measurement difference = 0.1 and 0.05 mm, for buccal and palatal, respectively) showed a significant difference between the two measurements. Comparing these differences between both groups did not reveal a statistically significant difference ($P = 1.00$ and 0.393 , respectively) [Figure 6].

PAIN ASSESSMENT

After 48 h of MOP application and starting canine retraction, no signs of trauma were detected in the relevant sides or in the control group. The distribution of the pain categories between the two groups was exactly the same; the patients reported moderate pain in MOP and control groups (35.5% each) [Table 5].

DISCUSSION

Our study evaluated a new method of speeding up the time required for orthodontic treatment and of decreasing the associated pain.

In orthodontics, a common scenario is when two interventions are applied in the same patient in a split-mouth approach. In this case, we have paired observations, and the required sample size is smaller because of the reduced variability. The split-mouth technique design resembles the crossover design, more often encountered in trials in medicine, without the period effects.^[29]

In our working example, we are interested in evaluating space closure differences in Class II Division 1 maxillary premolar extraction patients by using nickel-titanium on one side and a nickel-titanium with MOPs by miniscrew on the contralateral side. This is a paired observation case, with the participant serving as the control, as both intervention and comparison treatments are applied in each patient. This design is more efficient because the sites that receive the interventions are similar, thus reducing variance and sample size requirements.

The result of our study shows that the mean values of the canine displacements were nonsignificant. Our results were in disagreement with the findings from previous clinical and laboratory trial,^[14] which showed that application of MOPs could increase the rate of canine retraction during orthodontic treatment by more than one to two times and was better than the conventional orthodontic treatment method. However, our result was

Table 2: Mean, standard deviations (SD) of the distance between canine and second premolar in different time points for micro-osteoperforations and control groups

Side group	MOPs		Control		P-value
	Mean	SD	Mean	SD	
Before Exp.	10.83	1.25	10.96	0.76	0.808
After 2 w	10.32	1.18	10.85	1.06	0.545
After 1 m	9.72	1.26	9.79	0.67	0.818
After 2 m	9.10	0.89	9.09	1.08	0.945
After 3 m	8.70	1.21	9.28	1.23	0.002*

*P<0.005

Table 3: Multiple comparisons using post hoc test of micro-osteoperforations in different time points

Dependent Variable: MOPs				
(I) MOPs	(J) MOPs	Mean Difference (I-J)	Std. Error	Sig.
After 1 m	After 2 m	.6225	.58230	.292
	After 2 w	-.5987-	.58230	.311
	After 3 m	1.0225	.58230	.088
	Before Exp.	-1.1100-	.58230	.065
After 2 m	After 1 m	-.6225-	.58230	.292
	After 2 w	-1.2212-*	.58230	.043
	After 3 m	.4000	.58230	.497
	Before Exp.	-1.7325-*	.58230	.005
After 2 w	After 1 m	.5987	.58230	.311
	After 2 m	1.2212*	.58230	.043
	After 3 m	1.6212*	.58230	.009
	Before Exp.	-.5113-	.58230	.386
After 3 m	After 1 m	-1.0225-	.58230	.088
	After 2 m	-.4000-	.58230	.497
	After 2 w	-1.6212-*	.58230	.009
	Before Exp.	-2.1325-*	.58230	.001
Before Exp.	After 1 m	1.1100	.58230	.065
	After 2 m	1.7325*	.58230	.005
	After 2 w	.5113	.58230	.386
	After 3 m	2.1325*	.58230	.001

*P<0.005

in agreement with a study published in 2018 that failed to show any significant difference for using MOPs during canine retraction over the conventional method.^[24]

It is well known that the timing of treatment and the age of patients have a significant role in orthodontic treatment. To minimize the influence of age on the rate of tooth movement and to get almost similar outcome during the study, we chose adults between 15 and 40 years. In this age range, the development is almost or completely finished.^[30] Gender of the patients is also another difficult factor that affects the treatment results due to the hormone implications, which is different among males and females. Similar to most of the studies, our study could not decrease this problem due to the limitation in patients' numbers.^[31,32] Occlusion factor was excluded from this

Table 4: Multiple comparisons using post hoc test of control group in different time points

Dependent Variable: control side				
(I) CONTROL	(J) CONTROL	Mean Difference (I-J)	Std. Error	Sig.
After 1 m	After 2 m	.6225	.58230	.292
	After 2 w	-.5987-	.58230	.311
	After 3 m	1.0225	.58230	.088
	Before Exp.	-1.1100-	.58230	.065
After 2 m	After 1 m	-.6225-	.58230	.292
	After 2 w	-1.2212-*	.58230	.043
	After 3 m	.4000	.58230	.497
	Before Exp.	-1.7325-*	.58230	.005
After 2 w	After 1 m	.5987	.58230	.311
	After 2 m	1.2212*	.58230	.043
	After 3 m	1.6212*	.58230	.009
	Before Exp.	-.5113-	.58230	.386
After 3 m	After 1 m	-1.0225-	.58230	.088
	After 2 m	-.4000-	.58230	.497
	After 2 w	-1.6212-*	.58230	.009
	Before Exp.	-2.1325-*	.58230	.001
Before Exp.	After 1 m	1.1100	.58230	.065
	After 2 m	1.7325*	.58230	.005
	After 2 w	.5113	.58230	.386
	After 3 m	2.1325*	.58230	.001

*P<0.005

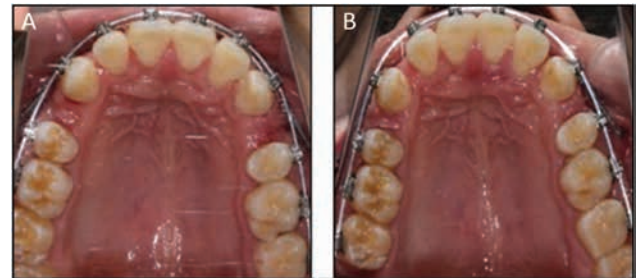


Figure 4: (A) Position of canine before experiment, (B) Position of canine after one month

study for its effects on the speeding tooth movement.^[33] Any defect related to the bite or unequal occlusion was excluded. Many studies tested the occlusion interfering with canine destabilization in Class II Division 1 case. Because the canine is free from arch bite association, canine retraction is another possible reason that might affect the rate of the orthodontic movement.

All diseases related to the periodontal ligament or patients with bad oral health were excluded to remove any probability of inflammation from any cause other than the MOPS.^[29,34] So to make all these variables less and to reduce their effect in the treatment procedures, certain criteria have been selected [Table 1].

Many studies reported the effects of extraction timing on tooth movement. Some of them recommended

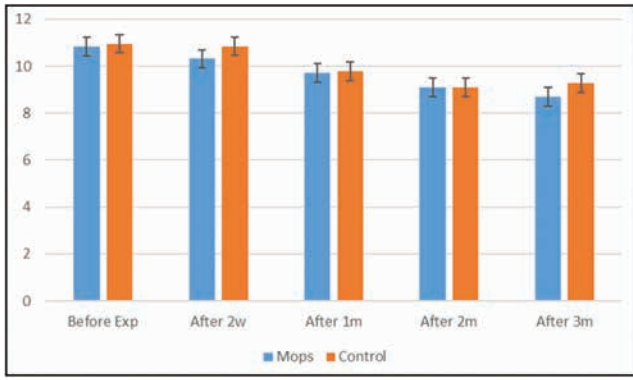


Figure 5: Illustrating the differences in distance for pre- and post-canine retraction in MOPs and control groups in different durations

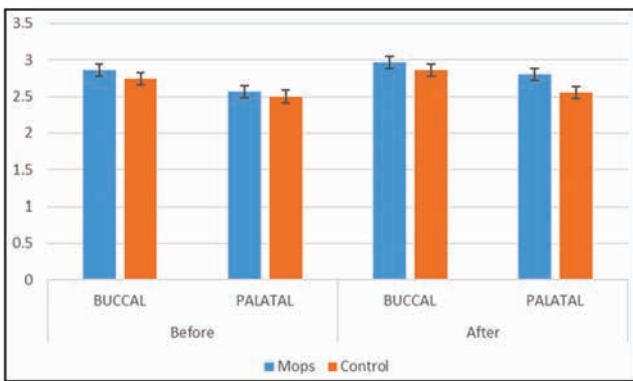


Figure 6: illustrating the differences in Bone height of the buccal and palatal side in MOPs and control groups

Table 5: Before and after root resorption multiple comparison using *post hoc* test

Side group	MOPs		Control		P-value
	Mean	SD	Mean	SD	
Before	22.71	.71	22.76	1.06	0.842
After	22.68	.71	22.71	1.14	0.886
P-value	0.934	0.929			

delaying extraction until retraction or after six months. To make sure that the extraction did not affect the study results, we performed it at the beginning of the orthodontic treatment.

Pain and discomfort recorded in both sides appear to be exactly similar, meaning that pain is not a considerable concern with MOPs. Likewise, almost all patients were willing to redo the treatment to accelerate the orthodontic treatments when they were asked about that [Table 6].

There are many variables that lead to root resorption, so if the study took a long time, it would have been more challenging to control these variables. We took the CBCT before and three months after the retraction. We assessed the root resorption and bone height.

CONCLUSION

MOP modality is a less aggressive and safe procedure, but it does not significantly speed up the tooth movement during orthodontic treatment. Further well-designed studies with larger sample size for longer treatment time are highly recommended.

ETHICAL CONSIDERATIONS

All the procedures have been performed as per the ethical guidelines laid down by Declaration of Helsinki and approved by the review board of stomatology department ethics committee of College of Medicine, Xi'an Jiaotong University, Xi'an, Shaanxi Province, China (approval number: Xjkq11 2017, dated: January 7, 2017, with number of trial: 06).

DATA AVAILABILITY

Datasets related to this article will be available from the corresponding author (Xia HY, Email: 369 hyx@163.com) on request.

ACKNOWLEDGEMENT

We would like to express our gratitude to the officials and other staff members at the department of orthodontics of the Hospital of Dentistry of Xi'an Jiaotong University for their help during the period of this project work.

DECLARATION OF PATIENT CONSENT

The authors certify that they have obtained all appropriate patient consent forms. In the form the patient(s) has/have given his/her/their consent for his/her/their images and other clinical information to be reported in the journal. The patients understand that their names and initials will not be published and due efforts will be made to conceal their identity, but anonymity cannot be guaranteed.

FINANCIAL SUPPORT AND SPONSORSHIP

Nil.

CONFLICTS OF INTEREST

There are no conflicts of interest.

REFERENCES

- Lee JW, Cha JY, Park KH, Kang YG, Kim SJ. Effect of flapless osteoperforation-assisted tooth movement on atrophic alveolar ridge: Histomorphometric and gene-enrichment analysis. *Angle Orthod* 2017;061217-388.1.
- Sangsuwon C, Alansari S, Nervina J, Teixeira C, Alikhani M. Micro-osteoperforations in accelerated orthodontics. *Clin Dent Rev* 2018;2:4.
- Patterson BM, Dalci O, Papadopoulou AK, Madukuri S, Mahon J, Petocz P, et al. Effect of piezocision on root resorption associated with orthodontic force: A microcomputed tomography study. *Am J Orthod Dentofacial Orthop* 2017;151:53-62.
- Alansari S, Sangsuwon C, Vongthongleur T, Kwal R, Chneh Teoa M, Lee YB, et al. Biological principles behind

Table 6: A, B, C, and D meaning were described in pain questionnaire, Short-form McGill Pain Questionnaire

MOPs pain%	Mild	Moderate	Severe
Experiments side	62.50%	37.50%	0.00%
Control side	62.50%	37.50%	0.00%

Table (5-A): Pain percentage calculated from the visual pain scale from 1–10, mild (1–3), moderate (4–6) and sever (7–10)

MOPs pain Q	A	B	C	D	Patient No
Experimental effects on daily life?	5	2	1		8
Is the pain compared to extraction pain?	7	1			8
Is the pain compared with TAD pain?	8				8
Are you willing to do the MOPs again to accelerate your treatment?	7	1			8

accelerated tooth movement. *Semin Orthod* 2015;21:151-61.

- Chishti M, Wen H, Pavlovskaja E, Ka Man C. Digitally modeling the deformation of gingival tissue during orthodontic treatment. U.S. Patent Documents number : 6685470 , Date of Patent: Feb.3, 2004.
- Sargolzaie N, Amel-Jamedar S, Reza Mokhtari M, Arab HR, Piroozi S. Evaluation of subgingival dental plaque microbiota changes in fixed orthodontic patients with syber green real time PCR. *J Dent Mater Tech* 2014;3:123-7.
- Tsai CY, Yang TK, Hsieh HY, Yang LY. Comparison of the effects of micro-osteoperforation and corticision on the rate of orthodontic tooth movement in rats. *Angle Orthodontist* 2015;86.
- Teixeira CC, Khoo E, Alikhani M. Different methods of accelerating tooth movement. *Clinical Guide to Accelerated Orthodontics*. Springer, Cham. 28 February 2017.
- Sant'Anna EF, Araujo MTS, Nojima Li, Cunha ACD, Silveira BLD, Markezan M. High-intensity laser application in orthodontics. *Dent Press J Orthod* 2017;22:99-109.
- Dalaie K, Hamed R, Kharazifard MJ, Mahdian M, Bayat M. Effect of low-level laser therapy on orthodontic tooth movement: A clinical investigation. *J Dent* 2015;12:249.
- Katchooi M, Cohanim B, Tai S, Bayirli B, Spiekerman C, Huang G. Effect of supplemental vibration on orthodontic treatment with aligners: A randomized trial. *Am J Orthod Dentofacial Orthop* 2018;153:336-46.
- Alpan D, Daher S, Bowman SJ. "Real-world" evaluation of AcceleDent. *Am J Orthod Dentofacial Orthop* 2017;151:633-5.
- Miles P, Fisher E, Pandis N. Assessment of the rate of premolar extraction space closure in the maxillary arch with the AcceleDent Aura appliance vs. no appliance in adolescents: A single-blind randomized clinical trial. *Am J Orthod Dentofacial Orthop* 2018;153:8-14.
- Shah-Parke C, Viraj D, Vinita V. Clinical guide to accelerated orthodontics. 2017;7:154.
- Akhoundi MSA, Sheikhzadeh S, Mirhashemi A, Ansari E, Kheirandish Y, Allaedini M, et al. Decreased bone density induced by antiepileptic drugs can cause accelerated orthodontic tooth movement in male Wistar rats. *Int Orthod* 2018;16:73-81.
- Abbas NH, Sabet NE, Hassan IT. Evaluation of corticotomy-facilitated orthodontics and piezocision in rapid canine retraction. *Am J Orthod Dentofacial Orthop* 2016;149:473-80.
- Dibart S, Sebaoun JD, Surmenian J. Piezocision: A minimally invasive, periodontally accelerated orthodontic tooth movement procedure. *Compend Contin Educ Dent* 2009;30:342.
- Aksakalli S, Calik B, Kara B, Ezirganli S. Accelerated tooth movement with piezocision and its periodontal-transversal effects in patients with Class II malocclusion. *Angle Orthod* 2016;86:59-65.
- Bakathir MA, Hassan AH, Bahammam MA. Piezocision as an adjunct to orthodontic treatment of unilateral posterior crossbite. *Saudi Med J* 2017;38:425-30.
- Eder SM. Accelerating tooth movement with micro-osteoperforation. *Orthod Prod* Available from: <http://www.orthodonticproductsonline.com/2012/09/accelerating-tooth-movement-with-micro-osteoperforatio/>. Published September 28, 2012.
- Feizbakhsh M, Zandian D, Heidarpour M, Zahra Farhad S, Reza Fallahi H. The use of micro-osteoperforation concept for accelerating differential tooth movement. *J World Fed Orthod* 2018;7:56-60.
- Raptis M. Micro-osteoperforation as an adjunct for the correction of negative anterior overjet in an adolescent patient with missing upper lateral incisors. *J Clin Orthod* 2017;51:47.
- Alfawal AM, Hajeer MY, Ajaj MA, Hamadah O, Brad B. Effectiveness of minimally invasive surgical procedures in the acceleration of tooth movement: A systematic review and meta-analysis. *Progress Orthod* 2016;17:33.
- Alkebsi A, Al-Maaitah E, Al-Shorman H, Abu Alhaija E. Three-dimensional assessment of the effect of micro-osteoperforations on the rate of tooth movement during canine retraction in adults with Class II malocclusion: A randomized controlled clinical trial. *Am J Orthod Dentofacial Orthop* 2018;153:771-85.
- Sukurica Y, Karaman A, Gurel Hg, Dolanmaz D. Rapid canine distalization through segmental alveolar distraction osteogenesis. *Angle Orthod* 2007;77:226-36.
- Yu JH, Shu KW, Tsai MT, Hsu JT, Chang HW, Tung KLI. A cone-beam computed tomography study of orthodontic apical root resorption. *Br Dent J* 2013;8:74-9.
- Makedonas D, Lund H, Hansen K. Root resorption diagnosed with cone beam computed tomography after 6 months and at the end of orthodontic treatment with fixed appliances. *Angle Orthod* 2013;83:389-93.
- Lund H, Gröndahl K, Gröndahl HG. Cone beam computed tomography evaluations of marginal alveolar bone before and after orthodontic treatment combined with premolar extractions. *Eur J Oral Sci* 2012;120:201-11.
- Okamoto A, Ohnishi T, Bandow K, Kakimoto K, Chiba N, Maeda A, et al. Reduction of orthodontic tooth movement by experimentally induced periodontal inflammation in mice. *Eur J Oral Sci* 2009;117:238-47.
- Ren Y, Kuijpers-Jagtman AM, Maltha JC. Immunohistochemical evaluation of osteoclast recruitment during experimental tooth movement in young and adult rats. *Arch Oral Biol* 2005;50:1032.

31. Haruyama N, Igarashi K, Saeki S, Otsuka-Isoya M, Shinoda H, Mitani H. Estrous-cycle-dependent variation in orthodontic tooth movement. *J Dent Res* 2002;81:406-10.
32. Zittermann A, Schwarz I, Scheld K, Sudhop T, Berthold HK, von Bergmann K, *et al.* Physiologic fluctuations of serum estradiol levels influence biochemical markers of bone resorption in young women. *J Clin Endocrinol Metab* 2000;85:95-101.
33. Risa UF, Hosomichi J, Ono N, Shibutani N, Kaneko S, Shimizu Y, *et al.* Occlusal hypofunction causes periodontal atrophy and VEGF/VEGFR inhibition in tooth movement. *Angle Orthod* 2013;83:48-56.
34. Knop LA, Shintcovsk RL, Retamoso LB, Ribeiro JS, Tanaka OM. Non-steroidal and steroidal anti-inflammatory use in the context of orthodontic movement. *Eur J Orthod* 2012;34:531-5.

1
2
3
4
5
6
7
8
9
10
11
12
13
14
15
16
17
18
19
20
21
22
23
24
25
26
27
28
29
30
31
32
33
34
35
36
37
38
39
40
41
42
43
44
45
46
47
48
49
50
51
52
53
54

1
2
3
4
5
6
7
8
9
10
11
12
13
14
15
16
17
18
19
20
21
22
23
24
25
26
27
28
29
30
31
32
33
34
35
36
37
38
39
40
41
42
43
44
45
46
47
48
49
50
51
52
53
54