



Isolated avulsion fracture of the lesser tuberosity of the humerus in an adolescent amateur boxer



Sam-guk Park, MD, PhD, Bum-jin Shim, MD, PhD^{*}, Hyun-gyu Seok, MD

Department of Orthopedic Surgery, Yeungnam University Medical Center, Daegu, Republic of Korea

ARTICLE INFO

Keywords:

Adolescent
arthroscopy
lesser tuberosity avulsion
isolated fracture
humerus
subscapularis tendon

Isolated avulsion fracture of the lesser tuberosity of the humerus is an uncommon injury in the pediatric population.^{2,4,7} Although there were controversies in the management of this fracture, most of the cases were treated operatively. The main problem is that it is not easy to detect and symptoms often get neglected.⁶ To our knowledge, there have been no reports on avulsion fracture of the lesser tuberosity in an adolescent amateur boxer. We report a case of successful rehabilitation of a surgically treated athlete who had satisfactory functional outcome.

Case report

A 13-year-old boy presented with pain in his left shoulder that began during boxing sparring 1 week earlier. He remembered that he felt a sudden severe shoulder pain when he tried an “overhand punch,” which has a looping circular arc as it is thrown over the shoulder with the palm facing away. Physical examination revealed no soft tissue swelling or bruise. Tenderness was noted localized on the anteromedial side of the left shoulder. The active range of motion of the left shoulder was 100° forward flexion and 90° abduction. The active range of external rotation was normal whereas the internal rotation was 30°. Active extension and adduction was limited by pain to 20°. The passive range of extension and adduction was 30° and 40°, respectively. The strength of abduction, internal rotation, and external rotation of the left shoulder was decreased compared

with the contralateral side (Table 1). Regarding preoperative clinical evaluation, the visual analog scale score was 5 points, Constant-Murley score was 66 points, the American Shoulder and Elbow Surgeons Standardized Shoulder Assessment Form score was 51.3 points, and the Disabilities of the Arm, Shoulder, and Hand score was 44.8 points. The anteroposterior and axillary plain radiographs of the left shoulder did not reveal any obvious fractures (Fig. 1). Computed tomographic (CT) scans of the left shoulder confirmed an isolated avulsion fracture of the lesser tuberosity of the humerus. The fragment displaced medially by about 2 mm. The fragment was 20 mm in length and 10 mm in width (Fig. 2). Magnetic resonance imaging (MRI) demonstrated a small bony avulsion of the lesser tuberosity and retraction of the lesser tuberosity with the attached subscapularis tendon (Fig. 3). The patient was treated surgically. The operative procedure was an all-arthroscopic repair using suture anchors in the lateral decubitus position. The operative arm was placed in 30° of abduction and 20° of forward flexion (Star Sleeve Traction System; Arthrex, Naples, FL, USA). Three routine arthroscopic portals (anterior, posterior, and anterolateral) were used to perform the arthroscopy. Initially, a glenohumeral examination was performed through the posterior portal. We identified isolated avulsion fracture of the lesser tuberosity of humerus with subscapularis tendon retraction. The biceps tendon was intact, and no abnormalities of other intra-articular structures were found. Preparation of the bone bed with a shaver and burr (Vortex Router and Linvatec Turbo Shaver System; Linvatec, Largo, FL, USA) and adequate débridement of chondral debris surrounding the avulsed fragment were carried out. Then, we mobilized the fractured fragment and brought it from its retracted position medially back to the anatomic

Institutional review board approval was not required for this case report

^{*} Corresponding author: Bum-jin Shim, MD, PhD, Department of Orthopaedic Surgery, Yeungnam University Hospital, 170 Hyeonchung-ro, Nam-Gu, Daegu 42415, Republic of Korea.

E-mail address: redpross@naver.com (B.-j. Shim).

<https://doi.org/10.1016/j.jsesint.2020.04.010>

2666-6383/© 2020 Published by Elsevier Inc. on behalf of American Shoulder and Elbow Surgeons. This is an open access article under the CC BY-NC-ND license (<http://creativecommons.org/licenses/by-nc-nd/4.0/>).

Table 1
Preoperative physical examination

	Left shoulder (affected side)	Right shoulder
Preoperative active ROM, degrees		
Flexion	100	180
Extension	20	60
Abduction	90	150
Adduction	20	50
Internal rotation	30	90
External rotation	90	90
Preoperative passive ROM, degrees		
Flexion	150	180
Extension	30	60
Abduction	90	150
Adduction	40	50
Internal rotation	40	90
External rotation	100	90
Preoperative clinical assessment		
VAS score	5	0
ASES score	51.3	
DASH score	44.8	
CMS	66	
Preoperative strength, lb		
Abduction	7	10
Internal rotation	4	12
External rotation	7	10

ROM, range of motion; VAS, visual analog scale; ASES, American Shoulder and Elbow Surgeons Standardized Shoulder Assessment Form; DASH, Disabilities of the Arm, Shoulder, and Hand; CMS, Constant-Murley score.

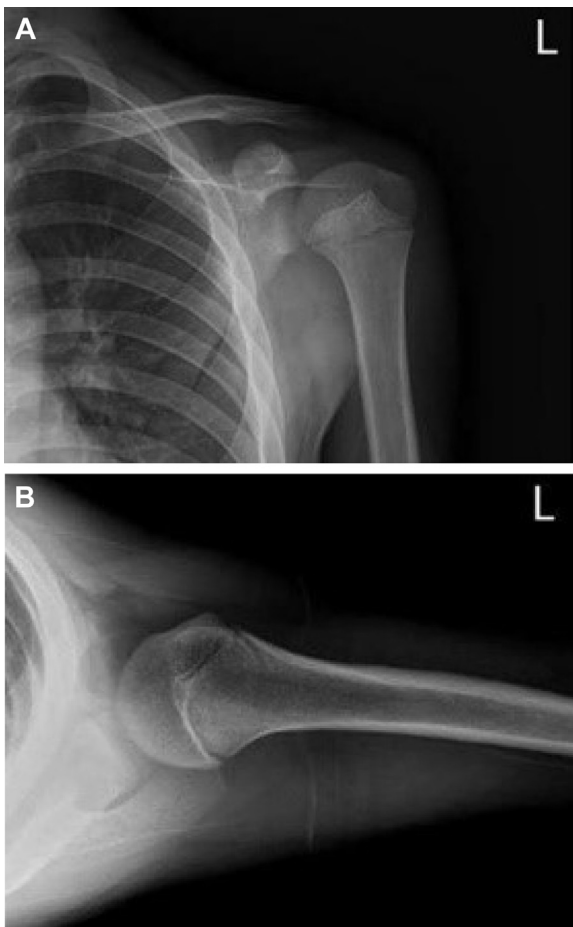

Figure 1 (A) Anteroposterior and (B) axillary radiographs of the left shoulder show no definite fracture line.

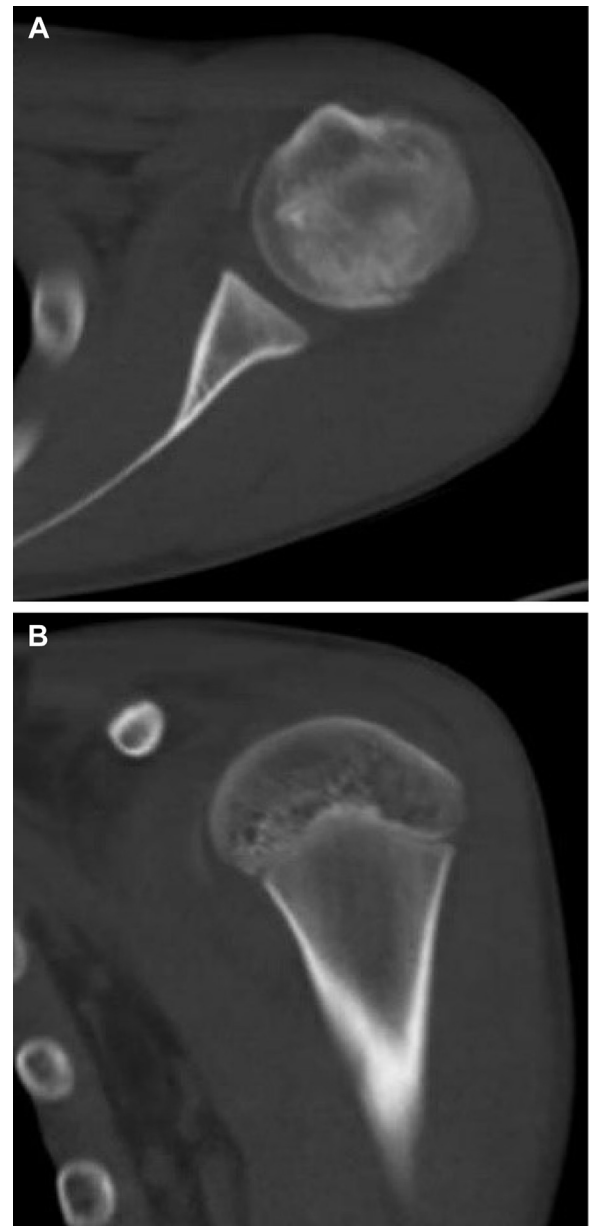


Figure 2 (A) Axial and (B) coronal cut of computed tomography of the left shoulder show avulsion fracture of the lesser tuberosity.

position, ensuring adequate mobilization of the avulsed fragment. Two 4.5-mm Bio-Corkscrew suture anchors (Arthrex) were used for the fixation. The finished repair demonstrated the avulsed fragment positioned securely in its anatomic position (Fig. 4). After surgery, the patient was placed in a shoulder immobilizer for a total of 6 weeks. The arms were placed in an abduction brace positioned in 30° of abduction. The patient underwent CT examinations at 2 weeks after surgery for assessment of the displacement of fracture. We found the fracture with 1 mm of displacement (Fig. 5) and continued on a shoulder brace for a further 4 weeks. After 6 weeks of immobilization, gentle, self-assisted, passive range-of-motion exercises, such as supine forward elevation or internal rotation using a towel, were performed. Three months post-operatively, we performed an interval ultrasonography, and it showed that the avulsion fracture was demonstrating signs of

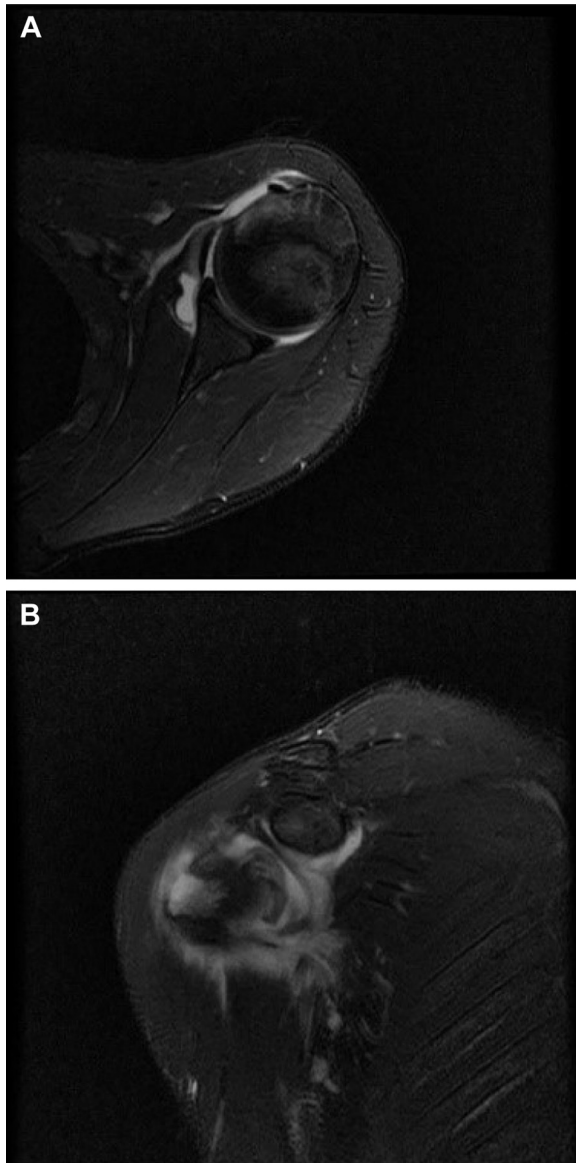


Figure 3 Axial cut of T2-weighted magnetic resonance imaging of the left shoulder demonstrating (A) avulsion and retraction of the lesser tuberosity with the subscapularis tendon and (B) associated humeral head bony edema.

healing (Fig. 6). The patient began isotonic strengthening exercises and was permitted to do light daily activities. At 6 months postoperatively, he regained normal muscle strength and full range of motion of the shoulder (Fig. 7). He could return to usual activities and restarted manual work. His visual analog scale score was 0 points, Constant-Murley score was 81 points, American Shoulder and Elbow Surgeons Standardized Shoulder Assessment Form score was 93.3 points, and Disabilities of the Arm, Shoulder, and Hand score was 5.2 points. Bone union was confirmed by MRI at 1 year after surgery (Fig. 8). He has been successful in rehabilitation and is currently active as a boxer.

Discussion

Isolated avulsion fracture of the lesser tuberosity is a relatively rare injury, especially in skeletally immature patients.² The

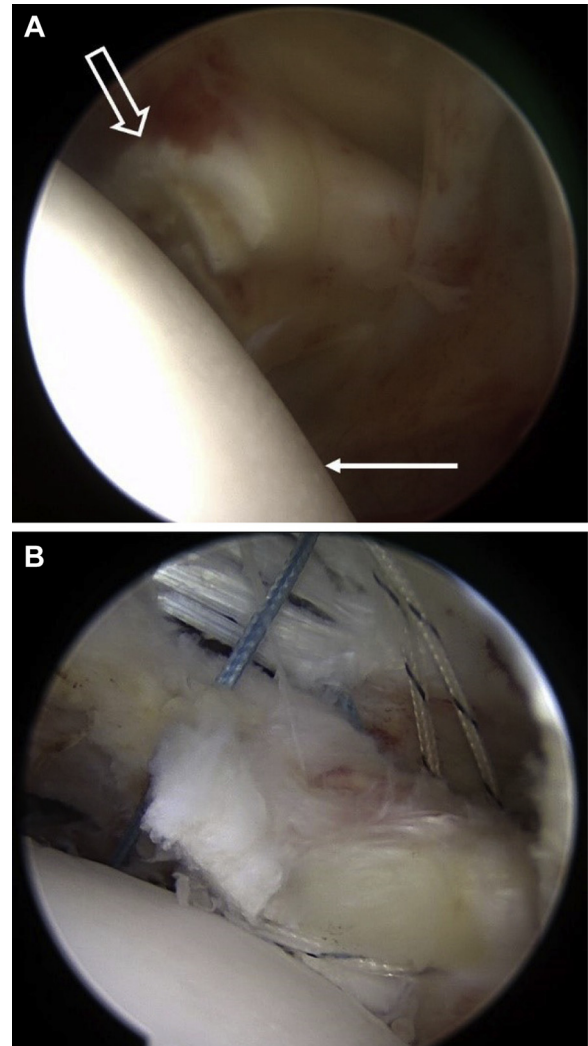


Figure 4 Arthroscopic view of the left shoulder viewed from the posterior portal with the patient in the lateral decubitus position. (A) The subscapularis tendon (arrowhead) retracted from the anterior articular surface of the humerus (arrow) with the lesser tuberosity avulsed fragment. (B) Suture anchor is used to repair the avulsion fracture of the lesser tuberosity.

mechanism of this injury involves an extremity being forced into external rotation and abduction. It is usually caused by an eccentric contraction of the subscapularis muscle that results in an avulsion fracture. It is difficult to diagnose and often missed, which may result in prolonged delays in treatment. It can be hard to find without suspicion.^{1,3–5}

Physical examination in the acute phase has found tenderness on the anteromedial side of the shoulder and increased passive range of external rotation. In the chronic phase, patients present with limitation in abduction, internal rotation, and with weakness in the subscapularis. They also can show an increase in external rotation.^{6,7,9} The isolated avulsed bony fragment may not always be evident on the anteroposterior and scapular views of plain radiographs, especially if it is small and minimally displaced. An axillary view should be taken to make a diagnosis. However, very small fragments are not visible in this view either. CT may be required for detection and further characterization of the avulsed fragment. MRI is required to detect the position of the biceps tendon or any pathology of the injured shoulder.^{2,7}

Management of avulsion fracture of the lesser tuberosity is still controversial. Some previous reports have suggested that

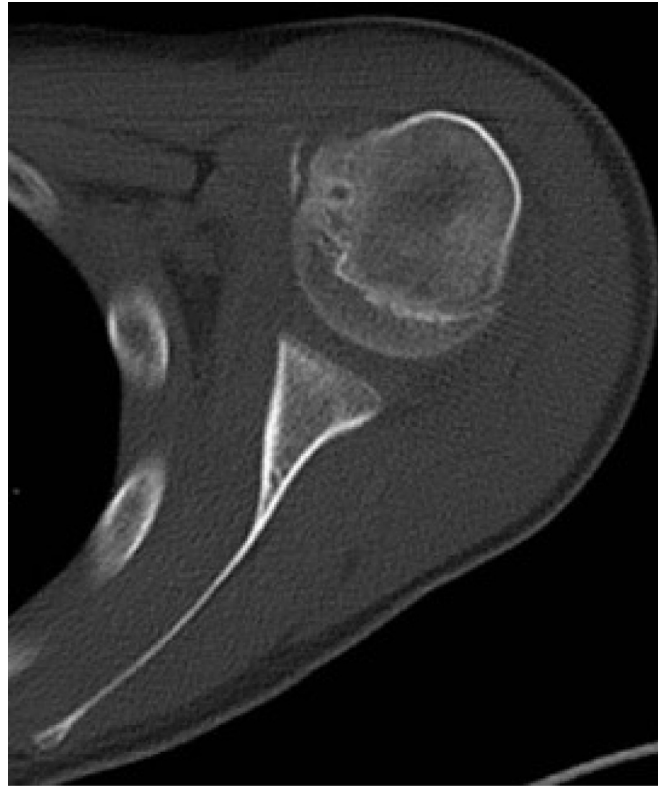


Figure 5 Postoperative 2-week axial cut of computed tomography of the left shoulder shows the avulsion fracture of the lesser tuberosity.

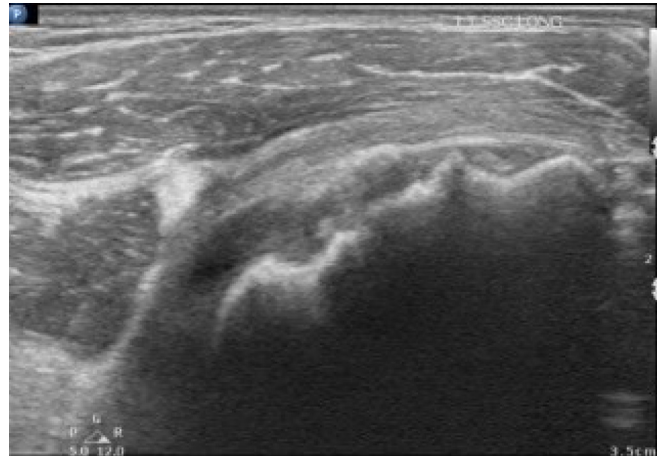


Figure 6 B-mode ultrasonographic image of the subscapularis: transverse view (long axis) shows signs that the avulsion fracture was healing.

nondisplaced fractures of the lesser tuberosity can be managed conservatively with good outcome. On the other hand, other studies have suggested that regardless of the size and displacement of the fragment, this injury needs surgical treatment to avoid complications such as displacement of the fracture, nonunion, malunion, and biceps tendon subluxation/dislocation.^{7–9} Most reported studies seem to agree that surgical procedures are needed in the presence of any displacement of the lesser tuberosity. In the past, open reduction and internal fixation using screws is the treatment of choice for avulsion fracture of the lesser tuberosity. To our knowledge, there have been few reports of arthroscopic treatment of avulsion fracture of the lesser tuberosity.² In the current case, the isolated avulsion fracture of the lesser tuberosity was

treated with an arthroscopic procedure. It was a time-saving and physal-sparing technique that could achieve satisfactory anatomic reduction with good clinical outcome.

Conclusion

Isolated avulsion fracture of the lesser tuberosity can easily be missed, so careful inspection and various examinations are needed. A correct, early diagnosis allows for proper treatment and can lead to a good clinical outcome. Operative treatment is generally indicated in the case of displaced fracture. Arthroscopic procedure can be an effective option to achieve a good clinical outcome even in a competitive athlete such as a boxer.

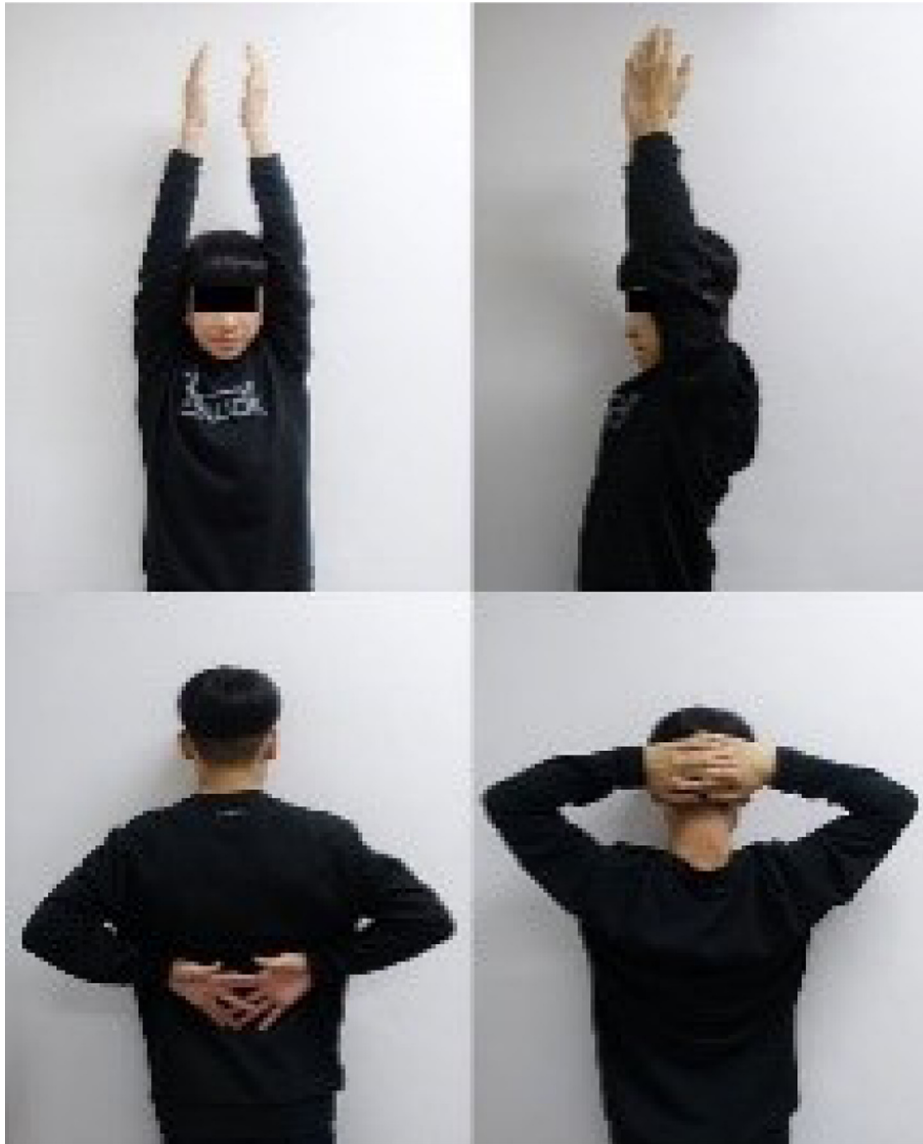

Figure 7 Functional outcome at 6-month follow-up with a satisfactory range of motion of the left shoulder.

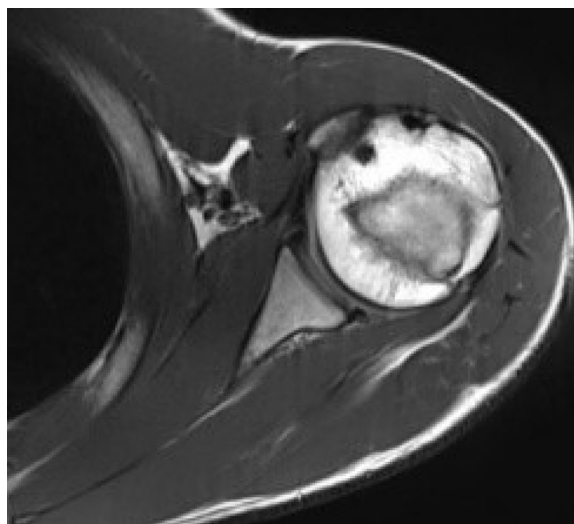


Figure 8 Postoperative 1-year axial cut of T1-weighted magnetic resonance imaging of the left shoulder demonstrating bony union.

Disclaimer

This work was supported by the 2020 Yeungnam University Research Grant.

The authors, their immediate families, and any research foundations with which they are affiliated have not received any financial payments or other benefits from any commercial entity related to the subject of this article.

References

1. Aagaard KE, Lunsjo K. Occult fracture of the lesser tuberosity in a 9-year-old female swimmer. *J Surg Case Rep* 2017;2017:rjw238. <https://doi.org/10.1093/jscr/rjw238>.
2. Cregar WM, MacLean IS, Verma NN, Trenhaile SW. Lesser tuberosity avulsion fracture repair using knotless arthroscopic fixation. *Arthrosc Tech* 2018;7:e899–905. <https://doi.org/10.1016/j.eats.2018.04.015>.
3. Garrigues GE, Warnick DE, Busch MT. Subscapularis avulsion of the lesser tuberosity in adolescents. *J Pediatr Orthop* 2013;33:8–13. <https://doi.org/10.1097/BPO.0b013e318270d0d6>.
4. LaMont LE, Green DW, Altchek DW, Warren RF, Wickiewicz TL. Subscapularis tears and lesser tuberosity avulsion fractures in the pediatric patient. *Sports Health* 2015;7:110–4. <https://doi.org/10.1177/1941738114533657>.
5. Mizrahi DJ, Averill LW, Blumer SL, Meyers AB. Chronic lesser tuberosity avulsion in an adolescent with an associated biceps pulley injury. *Pediatr Radiol* 2018;48:749–53. <https://doi.org/10.1007/s00247-017-4016-5>.
6. Paxinos O, Karavasili A, Manolarakis M, Paxinos T, Papavasiliou A. Neglected lesser tuberosity avulsion in an adolescent elite gymnast. *Shoulder Elbow* 2014;6:178–81. <https://doi.org/10.1177/1758573214531413>.
7. Vavken P, Bae DS, Waters PM, Flutie B, Kramer DE. Treating subscapularis and lesser tuberosity avulsion injuries in skeletally immature patients: a systematic review. *Arthroscopy* 2016;32:919–28. <https://doi.org/10.1016/j.arthro.2015.10.022>.
8. Vezeridis PS, Bae DS, Kocher MS, Kramer DE, Yen YM, Waters PM. Surgical treatment for avulsion injuries of the humeral lesser tuberosity apophysis in adolescents. *J Bone Joint Surg Am* 2011;93:1882–8. <https://doi.org/10.2106/JBJS.K.00450>.
9. Wu GB, Wang SQ, Wen SW, Yu GR. Isolated avulsion fractures of lesser tuberosity humerus: a case report and review of the literature. *Int J Clin Exp Med* 2014;7:780–4.