



Developmental Toxicity of the Neural Tube Induced by Titanium Dioxide Nanoparticles in Mouse Embryos

Nahid Mohamadzadeh, Masoumeh Zirak Javanmard *, Mojtaba Karimipour, and Gholamhosain Farjah

Department of Anatomical Sciences, Faculty of Medicine, Urmia University of Medical Sciences, Urmia, Iran

Abstract

Background: This study investigated the potential effects of Titanium dioxide nanoparticles (TiO₂NPs) followed by maternal gavage on fetal development and neural tube formation during pregnancy in mice.

Methods: Thirty pregnant mice were randomly divided into five main study groups including the untreated control and 4 experimental groups (n=6 per group). The control group was treated with normal saline and the experimental groups were orally treated with doses of 30, 150, 300, and 500 mg/kg Body Weight (BW) of TiO₂NPs during pregnancy. On gestational day 16 and 19 (n=3 per group), pregnant mice were euthanized and then examined for neural tube defects and compared with control. Serial transverse sections were prepared in both cranial region and in lumbar region of spinal cord.

Results: Treatment with TiO₂NPs resulted in low fetal weight and short length, dilation of lateral ventricle, thinning of cerebral cortex and spinal cord, spina bifida occulta and an increase in the number of apoptotic neurons in exposed embryos at doses of 300 and 500 mg/kg (p<0.05).

Conclusion: It seems that exposure to nanoparticles of TiO₂ during pregnancy induces growth retardation and for the first time, teratogenicity of this nanomaterial in neural tube development and induction of defects such as spinal bifida, reduction in cortical thickness and dilatation of lateral ventricles were verified which can be related to incidence of apoptosis in central nervous system.

Avicenna J Med Biotech 2021; 13(2): 74-80

Keywords: Fetal development, Mice, Neural tube defects, Titanium dioxide

* **Corresponding author:**
Masoumeh Zirak Javanmard,
Ph.D., Department of Anatomy,
Faculty of Medicine, Urmia
University of Medical Sciences,
Iran, Urmia, Iran
Tel: +98 44 33486216
E-mail:
zirakjavanmard.m@umsu.ac.ir
Received: 4 Aug 2020
Accepted: 7 Nov 2020

Introduction

During neurulation, the neuroepithelium elevates at both sides of Medial Hinge Point (MHP); it bends on the sides of dorsolateral walls and completes the fusion forming neural tube¹. Recent developments in the field of neurulation indicate that during elevation, the rate of cell proliferation increases and the neuroepithelial cells migrate ventro-dorsally; therefore, it seems that these two factors cause the fusion process². Some genetic, environmental and nutritional factors can affect the normal developmental process of neural tube formation and cause the incidence of Neural Tube Defects (NTDs) such as spina bifida which is one of the most common forms of human congenital defects¹. In contrast to other developmental disorders, closure of neural tube occurs in the first month of embryonic period, and many pregnant women do not avoid harmful factors due to unawareness of their pregnancy³.

An important consideration is the wide use of particles in industry, food packing, medical application,

water and air⁴⁻⁶. Titanium dioxide Nanoparticles (TiO₂NPs) are in the list of the five top nanoparticles with highest consumption⁷. The broad range of application, potential long term tissue accumulation and induction of tissue damages seem to raise concern with regard to its potential embryonic toxicity⁸. An expanding commercialization, massive production and wide use of personal care products of nanoparticles resulted in a high potential adverse health risk. People are exposed to NPs through various routes; sunscreen and toothpaste significantly contribute to TiO₂ dermal exposure. The estimated personal dermal exposure is 8 to 21.4 mg per day, while 10% of toothpaste is ingested daily⁹. Titanium dioxide (TiO₂) as a part of the modern diet will essentially increase their oral intake worldwide. TiO₂NPs are widely used as a food color in confectionaries in sauces, fondant and icing. The average daily exposure to TiO₂ for older adults is 0.5-1.1 mg and for children is 1.4-3.2 mg per kg body weight¹⁰.

While the risk of particle inhalation received much attention, gaps of knowledge exist regarding possible adverse health effects through digestion¹¹.

By any route of exposure, it enters the blood circulation and has the ability to cross the blood-barriers of testis, placenta and brain¹²⁻¹⁴. There are very few experiments that have reported about the teratogenicity of NPs. The injection of iron oxide NPs (10 mg/kg) during gestational days (GD 9-GD16) increased fetal death and induced external abnormality in limb, tail and ribs¹⁵. Injection of TiO₂ (35 nm size) to pregnant mice resulted in growth retardation, fusion of ribs, vertebrae, and phalanges¹³. Another study has reported that oral single dose of TiO₂ (51-65 nm, 100 and 1000 mg/kg) on GD10 induced limb and tail deformity and exencephaly, without weight loss of mice fetuses¹⁶. The most relevant reports to our research was oral administration of TiO₂ (diameter of 6.5 nm, dose of 50 and 100 mg/kg, GD 0-GD17) to pregnant ICR mice which induced growth retardation, skeletal malformations, exencephaly and spina bifida as a reduction of ossification in sacral arches by macroscopic evaluation using Menegola's method¹⁷.

The hazard to pregnant women and the possibility of NP_s reaching the developing fetus are of particular concern. Due to the lack of protection mechanism, embryos are more susceptible to environmental exposures¹⁸. The mouse is a common mammalian model for embryonic toxicity study. Despite the rapid introduction of nanomaterials to markets, their safety has not yet been well established. The CNS is the potential susceptible target of NP_s, but studies on this aspect are limited. Therefore, in this study, different concentrations of TiO₂ were used in experimental groups and it was hypothesized that higher doses of TiO₂ would result in more toxicity in embryonic development with neural tube defects in both cephalic and caudal parts.

Materials and Methods

Thirty-five female albino mice (20±5 g) were purchased from the Animal Center of Urmia University of Medical Sciences (Iran). Having been ensured the mice were non-pregnant, they were acclimated to the environment for 10 days, then were kept in cages at a ratio of 3:2 (Female: male) under a controlled environment at 22.00 °C and a 12-hr light-dark cycle for coupling. The next morning, the mice were examined for vaginal plug; the ones with a vaginal plug were isolated and it was the sign of day 0 of pregnancy.

Pregnant mice were housed individually and randomly divided into five main study groups including the untreated control and experimental (n=6 per group). The control group was treated with normal saline, whereas the experimental groups were treated with 30, 150, 300, and 500 mg/kg BW of nano-TiO₂¹⁷. Each experimental group was further divided into two sub-groups based on the day of sacrifice (Embryonic days E16 and E19) with 3 pregnant mice in each.

Animals received 30, 150, 300 and 500 mg/kg BW of nano-TiO₂ (99% anatase, crystal structure) with size of 10-25 nm in diameter (Sigma-Aldrich Japan., Tokyo) by oral gavage from gestational days 1 to, 15 and 18 in an isolated animal room. On gestational days 16 and 19, pregnant mice were anesthetized lightly with chloroform and euthanized. The uterus was quickly removed, and then 16-day and 19-day-old fetuses were removed from uterus and the weight and crown-rump length were measured. All experiments were performed in accordance with the National Institutes of Health Guidelines for the Care and Use of Laboratory Animals and approved by Ethics Committee of the Urmia University of Medical Sciences (Ir.UMSU. rec.1395.29).

Macroscopic examination

The uterus was opened to remove the fetuses and to record the number of absorbed or dead fetuses. All 16 and 19 day old fetuses in control and experimental groups were examined macroscopically under stereomicroscope for external morphological malformations.

Histopathological examination

For microscopic study, three fetuses in each litter were fixed in 4% paraformaldehyde. For further histological analysis, the paraffin cross sections of the developing cerebral cortex and lumbar spinal cord sections were cut at 5 μm and were stained with hematoxylin-eosin and TUNEL assay, respectively in order to follow up the toxic effect of TiO₂ in the neural tube tissue and apoptotic cells.

Morphometric analysis

Cross-sectional morphometric measurements were performed on each fetal telencephalon and spinal cord. In cerebral region, the measurement was performed in each fetal brain, identified in cross section by the presence of lateral ventricles, and third and fourth ventricles which were arranged from anterior to posterior part. The anteroposterior diameter of right lateral ventricle was drawn, and then the midpoint of diameter was considered for measuring lateral ventricular thickness. Also, the environment of right lateral ventricle was measured using Motic software. The criterion of spinal cord region was the presence of kidneys. In this level, the thickness of spinal cord was measured in posterior commissure. All measurements were performed and slides were screened at a 10× magnification.

Immunohistochemical staining

Cell quantification was performed on transverse sections of cortex and spinal cord of at least three animals in each group. To investigate whether TiO₂NP_s could decrease and/or increase the number of apoptotic neurons, immunohistochemical staining was performed via terminal deoxynucleotidyl Transferase dUTP Nick End Labeling (TUNEL) assay (In situ Cell Death Kit, POD, Mannheim, Germany) detecting DNA fragments ac-

cording to the manufacturer's instructions. Slides were incubated with 0.1% Triton $\times 100$ and exposed to terminal deoxynucleotidyl transferase and then peroxidase-conjugated antidigoxigenin antibody. For background staining, Mayer's hematoxylin was used. For quantification of apoptotic cells, TUNEL-stained sections were imaged at a $40\times$ magnification. The number of TUNEL- positive cells was counted and registered.

Statistical analysis

Statistical analyses were performed using SPSS version 16. One-way analysis of Variance (ANOVA) was run for comparison across groups. Statistical significance was set at $p \leq 0.05$.

Results

Pregnant mice were exposed to different doses of TiO_2 (30, 150, 300 or 500 mg/kg) at selected time points of embryonic development (E16 or E19) and were observed macroscopically and microscopically. Only one craniofacial malformation and one absorbed fetus were observed at dose of 500 mg/kg on embryonic day 19.

Fetal growth

Pregnant mice were euthanized on gestational days 16 and 19, and then fetal body weight and crown-rump length were measured. These two factors significantly decreased in TiO_2 exposed groups except the low dose treated group (30 mg/kg) compared to the untreated control group. With increasing dose of TiO_2 (Figure 1), weight and height loss was markedly observed.

Lateral ventricular dilatation

In order to identify possible damages in the cortical region, morphometric analysis was used. In the cortex of the control group with normal development, the molecular, external granular and external pyramidal layers

were recognized separately. Quantitative measurements demonstrated that the cortical thickness of TiO_2 exposed groups was mildly decreased at doses of 30 and 150 mg/kg , but reduction rate was significant at two high doses. The same result was obtained for morphometric parameters of right lateral ventricle at doses of 300 and 500 mg/kg (Figure 2).

Spinal cord development

The microscopic observations of transverse sections stained with H&E showed that TiO_2 affects the spinal cord development and formation of vertebrae. The thickness of spinal cord at the posterior commissure line decreased significantly in the 500 mg/kg exposed group as compared to the control. The vertebral column development showed the presence of spina bifida occulta in all exposed groups which was significantly higher in the 300 and 500 mg/kg treated groups. In the skeletal part of vertebral column, the body, pedicles, and transverse processes were formed and both laminae were fused together; spinous process started on embryonic day 16 (E16), and was well formed on E19. The ossification islands were apparent in all parts of control vertebrae, but in nano scale TiO_2 exposed groups, the ossification centers were absent or decreased. The incomplete formation of laminae or presence of spina bifida occulta was the most important defect in the process of vertebral column formation in treated groups (Figure 3).

Cortical and spinal cord apoptosis

Using TUNEL immunohistochemistry, apoptosis was analyzed in the embryonic neuroepithelium surrounding the lateral ventricle and spinal cord (Figure 4). In the cortical region, most cell deaths occurred in the outer layers of cortex. Cortical and spinal cord cells underwent apoptosis in response to TiO_2 even at low

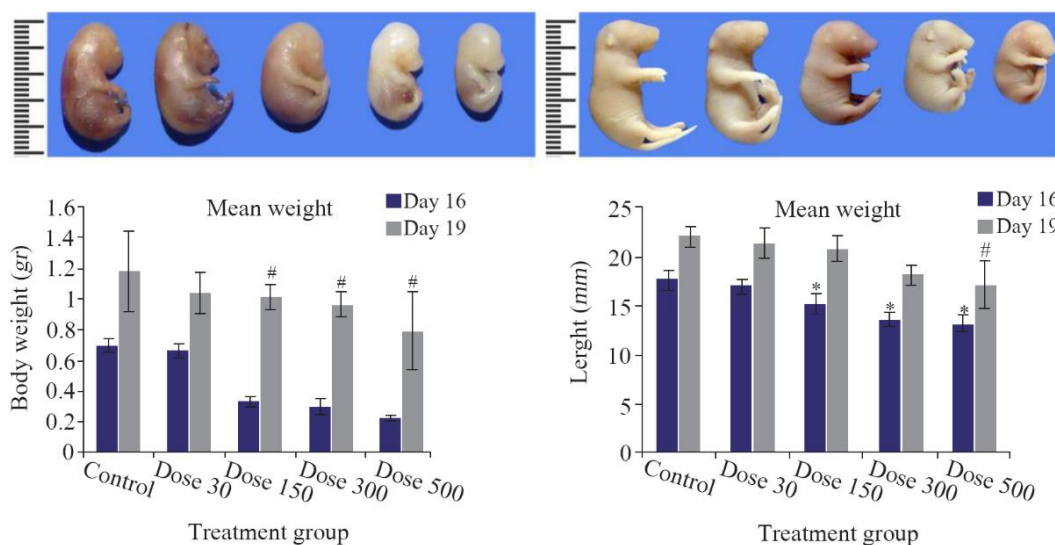


Figure 1. Macroscopic examination of fetuses on E16 (Upper row) and E19 (Lower row) revealed stunted growth including body weight loss and decrease of length in TiO_2 NPs exposed groups. Size reduction was significant at doses of 300 and 500 mg/kg of TiO_2 NPs compared with the control group, $p < 0.05$. # comparison with control on E16 and * E19.

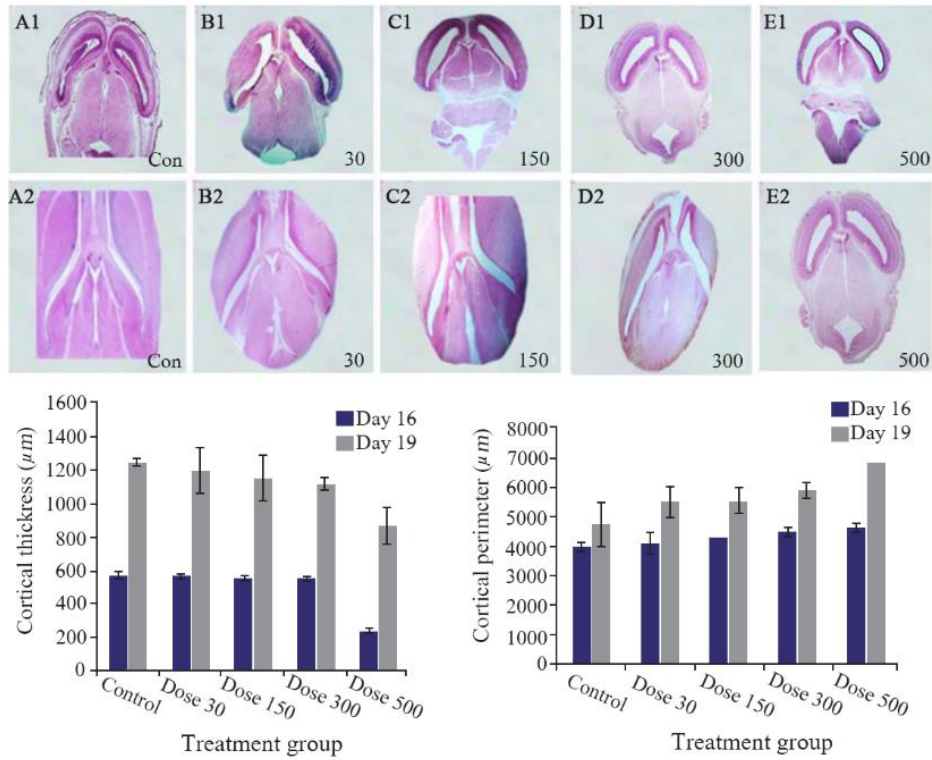


Figure 2. Reduction in cortical thickness and dilatation of lateral ventricles in the control and TiO_2 -NPs exposed embryos on E16 (A1-E1) and E19 (A2-E2). Heads of control and exposure groups were transversely sectioned and stained with H&E. Decreased cortical thickness and lateral ventricular dilatation after nanoparticle exposure increased significantly ($p < 0.05$) at higher doses (300 and 500 mg/kg) compared with control. Data are presented as mean \pm SD. # comparison with control on E16 and * E19.

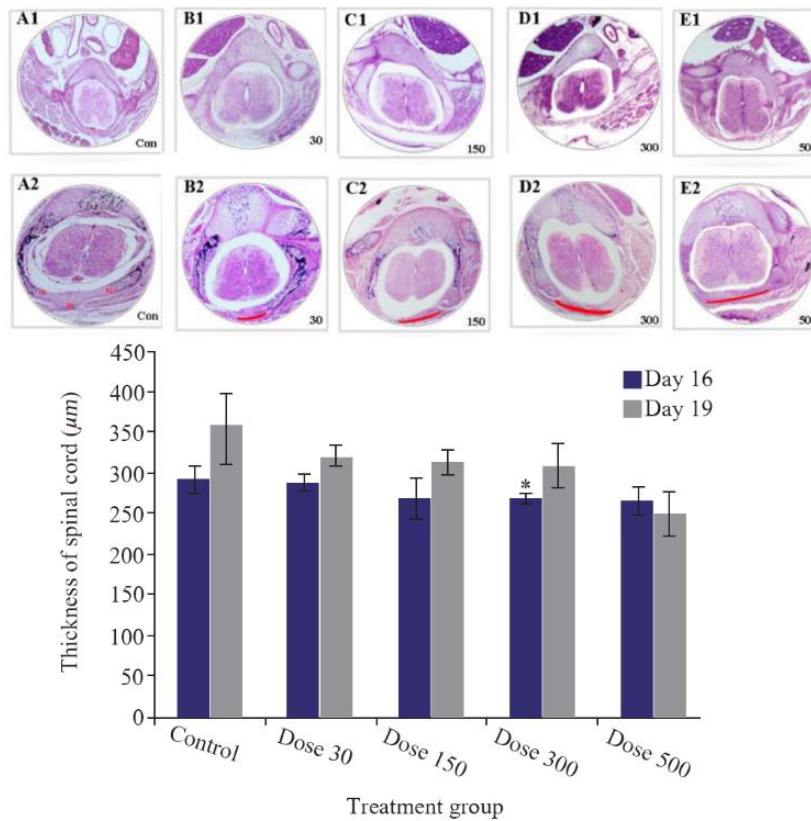


Figure 3. Transverse section of spinal cord and formation of vertebra in the control and TiO_2 -NPs exposed embryos on E16 (A1-E1) and E19 (A2-E2). Microscopic sections showing complete formation of vertebra in control group, fusion of Right Lamina (RL) and Left Lamina (LL) and formation of Spinous Process (SP). The red curve represents the distance between the laminae. Data are presented as mean \pm SD. # Comparison with control on E16 and * E19.

Embryonic Toxicity of Titanium Dioxide

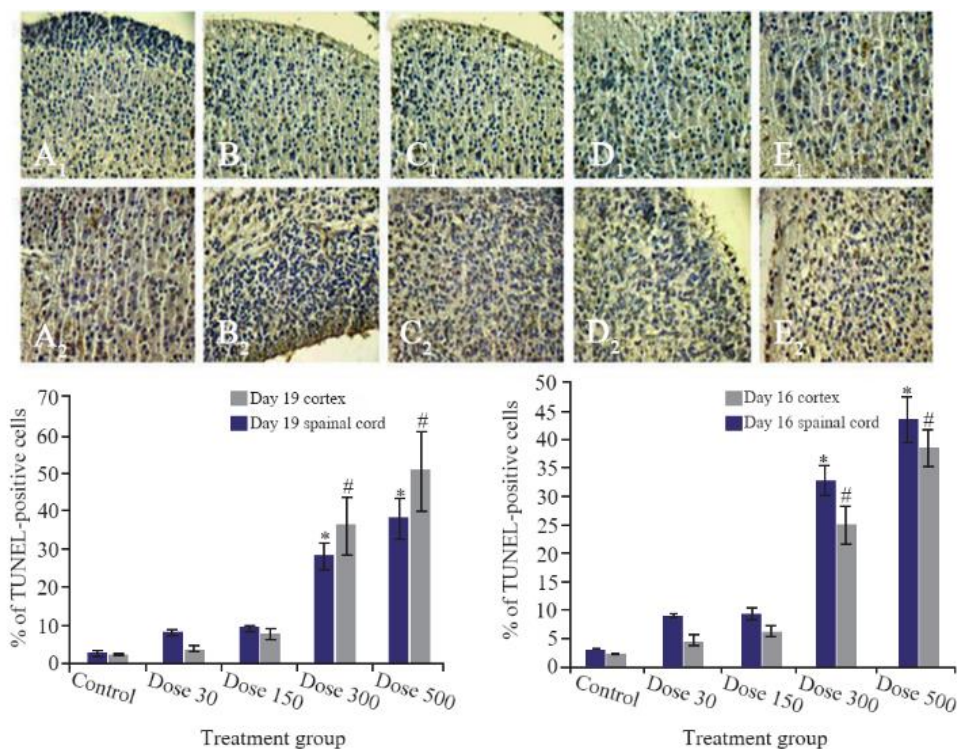


Figure 4. Photomicrographs of TUNEL-stained sections of fetuses in cortex (A1-E1) and spinal cord (A2-E2) on E19. The apoptotic cells were predominant in TiO_2 NPs groups compared to the control group. The number of TUNEL-positive cells (Red arrow) was significantly higher in the 300 and 500 mg/kg groups than in the control group, # comparison with control on E16 and * E19.

and moderate doses of nanoparticles. Finally, there was significant difference between 300 or 500 mg/kg groups compared to control on E16 and E19.

Discussion

In this study, growth retardation, decreased Body Weight (BW) and fetal crown-rump length were observed in TiO_2 exposed group, which became more severe with increasing doses. These results are in contrast to previous findings demonstrating that oral administration of titanium (21 nm , anatase/rutile) to rats during GD6-GD19 at a high dose (1000 mg/kg) would not result in significant weight loss in fetuses²⁰. This difference in developmental results is related to variability in animal species, chemical composition, particle size and duration of exposure²¹. However, the findings are consistent with the previous study which demonstrated that gavage of a dose of 100 mg/kg of TiO_2NP_s caused reduced fetal weight and length as markers of teratogenicity¹⁷. Another study has also reported that intravenous exposure to TiO_2 (35 nm) induced developmental retardation as smaller fetuses developed in mice²². According to a new published review, after parental exposure, TiO_2NP_s accumulate in placenta and cause impairment in nutrients conduction which in turn results in fetal growth retardation²³. Inhaled TiO_2 nanoparticles increased microvascular oxidative stress up to 60% and resulted in impairment of muscle arteriole

dilation²⁴. In addition, impaired coronary arteriolar endothelium-dependent dilation and increased ROS of vessels have been reported²⁵. Placenta is one of the target organs for this particle, thus some nano particles can affect the placental blood flow and substance transport. They induce anorexia and necrosis of uterus which probably results in reduced size of fetuses²⁶. It seems that developmental retardation may be related to impairment of placental capillaries in the villi, uterine vascular dysfunction and greater inflammatory response of vessels²⁷.

Incidence of spina bifida occulta and failure of closure of vertebral arch as well as decreased ossification centers of vertebrae at high doses (300 and 500 mg/kg) of exposure were seen in this study. Maternal exposure to TiO_2 during gestational days revealed increased titanium concentrations in maternal and fetal serum and resulted in reduction in the calcium and zinc contents, reduced ossification, rib and sternum absence¹⁷. *In vivo* experiment demonstrated that two weeks of mothers' exposure to TiO_2 degenerated chondrocytes and mesenchymal cells of forelimbs in mouse embryos²⁸. It has been reported that the aluminum nanoparticle through parental nutrition can impair bone mineralization and induce neurobiological delay²⁹. Inhibition of osteogenesis in cell cultures, by induction of YAP signaling pathway after exposure to 10 ppm titanium is another *in vitro* report³⁰. Changes and impairment of

placental blood flow may decrease the permeability of Ca^{+2} in the placenta. TiO_2 interferes with calcium metabolism in embryo and affects the ossification. These particles damage osteoblasts and increase osteoclast activity, which in turn would decrease the rate of ossification. The maternal calcium and zinc reduction may be an important cause of TiO_2 induced growth retardation¹⁷.

Thinning of the cortical plate and suppression of mitosis (Figure 2) in fetal neuroepithelial tissue of the exposed mice were the additional evidence that confirmed damage to the fetal cortical plate cells in the present experiment. The data of five measurements/groups obtained here on the fetal lateral ventricles demonstrate that the administration of TiO_2 NPs to pregnant mothers affects the central nervous system of offspring. Similar to our finding, exposure to TiO_2 NPs during pregnancy and lactation periods reduced cerebral thickness, number of neurons and induced edema in cerebellum and cerebral areas by the reduction of Rac1 and Cdc42 that are involved in the development of axon and dendrite³¹. Findings have showed that TiO_2 NPs accumulate in the brain and lead to hippocampal cells apoptosis, glial cells proliferation and induction of oxidative stress³². Oxidative stress and apoptosis are the main developmental toxicants which disrupt the cellular and molecular processes of physiological development and generate embryonic malformations³³. Another hypothesis suggests inhibition of the cell division following exposure to TiO_2 , which could result from a disturbance of the enzymes involved in DNA replication and cell cycle³⁴. It has been recently reported that after exposure to TiO_2 NPs, these particles accumulate in ventricles, cortex and cerebellum and induce an increase of necrotic cells in nervous tissue. A significant decrease in neuroblasts and an increase in apoptotic neural cells were observed in cortical cell cultures followed by TiO_2 treatment at the dose of 20 $\mu\text{g/ml}$ ³⁵. Immunohistochemical staining revealed ROS production and lipid peroxidation of cerebral cortex³⁶.

Conclusion

There is only one previous report which indicated incidence of spina bifida after exposure to TiO_2 NPs. The histological assessment of spina bifida, ventricles' enlargement and cortical thinning is the first report on teratogenicity of TiO_2 . Embryonic cell death and delay in growth may be responsible for the observed abnormalities. For this reason, more molecular researches are recommended to investigate the mechanism of neural tube defects.

Acknowledgement

This study was supported by Vice-Chancellor for Research of Urmia University of Medical Sciences.

Conflict of Interest

The authors notify that they have no conflicts of interest.

References

1. Ybot-Gonzalez P, Copp AJ. Bending of the neural plate during mouse spinal neurulation is independent of actin microfilaments. *Dev Dyn* 1999;215(3):273-83.
2. McShane SG, Molè MA, Savery D, Greene ND, Tam PP, Copp AJ. Cellular basis of neuroepithelial bending during mouse spinal neural tube closure. *Dev Biol* 2015; 404(2):113-24.
3. Kondo A, Matsuo T, Morota N, Kondo AS, Okai I, Fukuda H. Neural tube defects: risk factors and preventive measures. *Congenit Anom* 2017;57(5):150-6.
4. Lin QB, Li H, Zhong HN, Zhao Q, Xiao DH, Wang ZW. Migration of Ti from nano- TiO_2 -polyethylene composite packaging into food simulants. *Food Addit Contam Part A* 2014;31(7):1284-90.
5. Buly RL, Huo MH, Salvati E, Brien W, Bansal M. Titanium wear debris in failed cemented total hip arthroplasty: an analysis of 71 cases. *J Arthroplasty* 1992;7(3): 315-23.
6. Shandilya N, Le Bihan O, Bressot C, Morgeneyer M. Emission of titanium dioxide nanoparticles from building materials to the environment by wear and weather. *Environ Sci Technol* 2015;49(4):2163-70.
7. Rollerova E, Tulinska J, Liskova A, Kuricova M, Kovriznych J, Mlynarcikova A, et al. Titanium dioxide nanoparticles: some aspects of toxicity/focus on the development. *Endocr Regul* 2015;49(2):97-112.
8. Jia X, Wang S, Zhou L, Sun L. The potential liver, brain, and embryo toxicity of titanium dioxide nanoparticles on mice. *Nanoscale Res Lett* 2017;12(1):478.
9. Wu F, Hicks AL. Estimating human exposure to titanium dioxide from personal care products through a social survey approach. *Integr Environ Assess Manag* 2020;16 (1):10-6.
10. Sprong C, Bakker M, Niekerk M, Vennemann M. Exposure assessment of the food additive titanium dioxide (E 171) based on use levels provided by the industry. RIVM Letter report 2015-0195.
11. Winkler HC, Notter T, Meyer U, Naegeli H. Critical review of the safety assessment of titanium dioxide additives in food. *J Nanobiotechnology* 2018;16(1):51.
12. Morgan AM, Ibrahim MA, Noshay PA. Reproductive toxicity provoked by titanium dioxide nanoparticles and the ameliorative role of Tiron in adult male rats. *Biochem Biophys Res Commun* 2017;486(2):595-600.
13. Yamashita K, Yoshioka Y, Higashisaka K, Mimura K, Morishita Y, Nozaki M. Silica and titanium dioxide nanoparticles cause pregnancy complications in mice. *Nat Nanotechnol* 2011;6(5):321-8.
14. Chen IC, Hsiao IL, Lin HC, Wu CH, Chuang CY, Huang YJ. Influence of silver and titanium dioxide nanoparticles on in vitro blood-brain barrier permeability. *Environ Toxicol Pharmacol* 2016;47:108-18.

15. Di Bona KR, Xu Y, Ramirez PA, DeLaine J, Parker C, Bao Y, et al. Surface charge and dosage dependent potential developmental toxicity and biodistribution of iron oxide nanoparticles in pregnant CD-1 mice. *Reprod Toxicol* 2014;50:36-42.
16. Philbrook NA, Winn LM, Afroz AN, Saleh NB, Walker VK. The effect of TiO₂ and Ag nanoparticles on reproduction and development of *Drosophila melanogaster* and CD-1 mice. *Toxicol Appl Pharmacol* 2011;257(3):429-36.
17. Hong F, Zhou Y, Zhao X, Sheng L, Wang L. Maternal exposure to nanosized titanium dioxide suppresses embryonic development in mice. *Int J Nanomedicine* 2017;12:6197-204.
18. Anderson LM, Diwan BA, Fear NT, Roman E. Critical windows of exposure for children's health: cancer in human epidemiological studies and neoplasms in experimental animal models. *Environ Health Perspect* 2000;108(Suppl 3):573-94.
19. Rizk MZ, Ali SA, Hamed MA, El-Rigal NS, Aly HF, Salah HH. Toxicity of titanium dioxide nanoparticles: effect of dose and time on biochemical disturbance, oxidative stress and genotoxicity in mice. *Biomed Pharmacother* 2017;90:466-72.
20. Lee J, Jeong JS, Kim SY, Park MK, Choi SD, Kim UJ, et al. Titanium dioxide nanoparticles oral exposure to pregnant rats and its distribution. *Part Fibre Toxicol* 2019;16(1):31.
21. Rogers NJ, Franklin NM, Apte SC, Batley GE. The importance of physical and chemical characterization in nanoparticle toxicity studies. *Integr Environ Assess Manag* 2007;3(2):303-4.
22. Yamashita K, Yoshioka Y, Higashisaka K, Mimura K, Morishita Y, Nozaki M, et al. Silica and titanium dioxide nanoparticles cause pregnancy complications in mice. *Nat Nanotechnol* 2011;6(5):321-8.
23. Wu Y, Chen L, Chen F, Zou H, Wang Z. A key moment for TiO₂: Prenatal exposure to TiO₂ nanoparticles may inhibit the development of offspring. *Ecotoxicol Environ Saf* 2020;202:110911.
24. Nurkiewicz TR, Porter DW, Hubbs AF, Stone S, Chen BT, Frazer DG, et al. Pulmonary nanoparticle exposure disrupts systemic microvascular nitric oxide signaling. *Toxicol Sci* 2009;110(1):191-203.
25. Nurkiewicz T, Porter D, Hubbs A, Stone S, Moseley A, Cumpston J, et al. Pulmonary particulate matter and systemic microvascular dysfunction. *Res Rep Health Eff Inst* 2011;(164):3-48.
26. Jo E, Seo G, Kwon JT, Lee M, Cheun Lee B, Eom I, et al. Exposure to zinc oxide nanoparticles affects reproductive development and biodistribution in offspring rats. *J Toxicol Sci* 2013;38(4):525-30.
27. Stapleton PA, McBride CR, Yi J, Nurkiewicz TR. Uterine microvascular sensitivity to nanomaterial inhalation: an in vivo assessment. *Toxicol Appl Pharmacol* 2015;288(3):420-8.
28. Hayati Roodbari N, Parivar P, Badiei B, Zolfaghari Barogh S. Cytotoxic effects of nano-titanium dioxide on forelimb bud development in NMRI mouse embryos in vivo. *J Adv Med Biomed Res* 2014;22(91):11-24.
29. Willhite CC, Karyakina NA, Yokel RA, Yenugadhathi N, Wisniewski TM, Arnold IMF, et al. Systematic review of potential health risks posed by pharmaceutical, occupational and consumer exposures to metallic and nano-scale aluminum, aluminum oxides, aluminum hydroxide and its soluble salts. *Crit Rev Toxicol* 2014;44(Suppl 4):1-80.
30. Zhu WQ, Ming PP, Qiu J, Shao SY, Yu YJ, Chen JX, et al. Effect of titanium ions on the Hippo/YAP signaling pathway in regulating biological behaviors of MC3T3-E1 osteoblasts. *J Appl Toxicol* 2018;38(6):824-33.
31. Hong F, Zhou Y, Ji J, Zhuang J, Sheng L, Wang L. Nano-TiO₂ inhibits development of the central nervous system and its mechanism in offspring mice. *J Agric Food Chem* 2018;66(44):11767-74.
32. Ze Y, Hu R, Wang X, Sang X, Ze X, Li B, et al. Neurotoxicity and gene-expressed profile in brain-injured mice caused by exposure to titanium dioxide nanoparticles. *J Biomed Mater Res A* 2014;102(2):470-8.
33. Kupsco A, Schlenk D. Oxidative stress, unfolded protein response, and apoptosis in developmental toxicity. *Int Rev Cell Mol Biol* 2015;317:1-66.
34. Wu J, Sun J, Xue Y. Involvement of JNK and P53 activation in G2/M cell cycle arrest and apoptosis induced by titanium dioxide nanoparticles in neuron cells. *Toxicol Lett* 2010;199(3):269-76.
35. Valentini X, Deneufbourg P, Paci P, Rugira P, Laurent S, Frau A, et al. Morphological alterations induced by the exposure to TiO₂ nanoparticles in primary cortical neuron cultures and in the brain of rats. *Toxicol Rep* 2018;5:878-89.
36. Shrivastava R, Raza S, Yadav A, Kushwaha P, Flora SJ. Effects of sub-acute exposure to TiO₂, ZnO and Al₂O₃ nanoparticles on oxidative stress and histological changes in mouse liver and brain. *Drug Chem Toxicol* 2014;37(3):336-47.