



## Research article

Usage of pharmaceutical contraceptive drug for controlling *Eobania vermiculata* snails by baits techniqueMahmoud S. Abd El-Atti<sup>a,\*</sup>, Ashraf S.A. El-Sayed<sup>b</sup>, Radwa M. Said<sup>a</sup><sup>a</sup> Zoology Department, Faculty of Science, Zagazig University, Zagazig 44519, Egypt<sup>b</sup> Enzymology and Fungal Biotechnology Lab, Botany and Microbiology Department, Faculty of Science, Zagazig University, 44519, Egypt

## ARTICLE INFO

## Keywords:

Contraceptive drug  
Oviposition  
Hormones  
Histopathology  
*Eobania vermiculata*  
Food science  
Animal science  
Agronomy  
Pesticide  
Zoology

## ABSTRACT

The present study focused on evaluating the effects of oral administration of three different concentrations of Yasmin® combined contraceptive pills (estrogen and progesterone) on reproductive hormones levels, histology of the ovotestis and rate of oviposition of *E. vermiculata* for two months using baits technique. The levels of anti-müllerian hormone (AMH), Follicle stimulating hormone (FSH), Luteinizing hormone (LH), Estradiol (E2), Progesterone (PRG), Thyroid-stimulating hormone (TSH) and Testosterone (T) of treated snails were decreased with increasing the drug concentrations by percentages of -83.3%, -78.9%, -59.6%, -98.3%, -79.6%, -86.7% and 8.2%, respectively. Prolactin (PRL) level was significantly increased (86.9%) compared to control snails after 8 weeks of exposure. Histological investigations on the hermaphrodite glands of snails treated with 909 µg/gm. showed glandular hyperplasia, sloughing of germinal epithelium, acini sizes reduction, suppression of follicular growths, decreased luteinization and vasodilation. Male acini revealed histolytic of spermatogonia and mature sperms. The lowest concentration (303 µg/gm.) caused gradual decrease of the total egg counts that reach 50% at the 8<sup>th</sup> week of treatment. Higher doses (606 and 909 µg/gm.) resulted in dramatic dwindling of egg numbers and inspiring complete egg cessation at the 7<sup>th</sup> and 3<sup>rd</sup> weeks of treatments, respectively. The applications of combined contraceptive drugs as baits give promising results for controlling high population densities of *E. vermiculata* snails at Sharkia Governorate, Egypt.

## 1. Introduction

Terrestrial gastropods are one of the most prosperous classes of invertebrates inhabiting the terrestrial ecosystems (Arad et al., 1993). They have functional mechanisms versus starvation, desiccation and freezing (Riddle and Miller, 1988; Burla and Gosteli, 1993). Land snails are deliberated as serious economic pests feeding on algae, lichens and grasses in addition to roots, leaves, flowers, fruits and seeds of higher plants (2013; 2015; Lazaridou-Dimitriadou and Kattoulas, 1991; Speiser and Rowell-Rahier, 1993). The helicid chocolate-band *Eobania vermiculata* (Müller, 1774) snails are native to the Mediterranean region and have been found their way to invade many other countries (Neubert, 1998). They became the most widespread species worldwide excluding southern South America and some Pacific islands (Scott, 1997). This species is characterized by its survival capacities and has been introduced by human activities to numerous countries from the United States to Japan (Ueshima et al., 2004; Ronsmans and Van den Neucker 2016). *E. vermiculata* forayed many Egyptian agricultural fields (El-Sayed, 2013;

El-Sayed et al., 2018; 2019a; c, 2020). Their highest population densities on citrus trees at Sharkia Governorate were detected during spring while the highest vertical distribution on *Casuarina* trees was noticed during summer (Ismail et al., 2017). Chemical molluscicides degenerated lingeringly in the environment and inspiring critical ecological toxicities (Rug and Ruppel 2000; Gaber et al., 2006). The high expense and resistance exerted against synthetic pesticides encouraged the usage of naturally derived compounds in pests control managements (Ali et al., 2015; Massoud and Habib 2003). Nowadays, many countries have supported the usage of natural plant products and microbial pesticides due to their low mammalian toxicity, low costs and fast biodegradability (El-Sayed et al., 2020; El-Sayed and Ali, 2020; El-Sayed et al., 2018, 2019a, c; Singh et al., 2000; Genena and Mostafa, 2008; Abd El-Atti et al., 2020). Few studies have been carried out addressing the effect of hormones on reproduction of basommatophoran pulmonates snails and slugs but much fewer studies have done on stylommatophoran land snails (Kruatrachue et al., 1996). The developments of oral contraceptives in 1958 are among the most widely used pharmaceuticals and their

\* Corresponding author.

E-mail address: [mahmoudattil@yahoo.com](mailto:mahmoudattil@yahoo.com) (M.S. Abd El-Atti).

combined pills contain active exogenous estrogen and progestin (Pincus et al., 1958). The combination of the two steroids creates a synergistic effect that greatly increases their anti-gonadotropic and ovulation-inhibitory effects (Curtis et al., 2013). Exogenous steroids efficacies are due to a range of effects causing a decrease in FSH and LH, leading to the suppression of follicular activity and ovulation (Baerwald et al., 2004). In primates, estrogen and progestin have been shown to inhibit the growth of pre and medium-sized antral follicles through inhibition of FSH secretion (Koering et al., 1994).

Our goal was to determine the effect of Yasmin® (Estrogen and Progesterone) contraceptive drug on the reproductive hormones, histological structure of the hermaphrodite gland and rate of egg production of *E. vermiculata* under laboratory conditions using bait technique. This research aimed also to apply an environmentally safe method for decreasing fertilities of these harmful agricultural pests and consequently controlling their high populations on citrus trees at Sharkia Governorate, Egypt.

## 2. Materials and methods

### 2.1. Collection and acclimatization of snails

Adult *E. vermiculata* snails ( $29 \pm 0.4$  mm length,  $16 \pm 0.2$  mm width and  $2.6 \pm 1$  gm. weight) were collected from citrus fields at Alrobomaya village, Meniet El-kamh district, Sharkia Governorate, Egypt, during October 2019. The collected specimens were transferred to the laboratory and maintained in glass cages ( $40 \times 30 \times 30$  cm) filled with moist soil of about 10 cm height and covered with a nylon-mesh lid. They fed on fresh lettuce leaves daily for two weeks. The experimental animals were maintained at  $20 \text{ }^\circ\text{C} \pm 2 \text{ }^\circ\text{C}$  and relative humidity 80–90 %.

### 2.2. Synthetic hormones and baits formulation

Yasmin® is an Egyptian contraceptive drug containing 0.03 mg ethinyl estradiol (Estrogen) and 3 mg drospirenone (Progesterone)/tablet. Baits were formulated by adding 95 g wheat bran to 5 g of sugarcane syrup and the mixture was moistened with small amounts of water. Different baits concentrations (303, 606 and 909  $\mu\text{g/g}$ ) were prepared by grinding of one, two and three tablets, respectively with 10 g of the bait.

### 2.3. Experimental design and egg masses count

The chocolate-band snails were divided into four groups comprising 10 snails for each. The first group left as control group. The remaining three groups were fed on baits containing the tested drug concentrations for two months and three replicates were applied for each group. During oviposition, snails were not disturbed. The soil was inspected with the aid of hand lens for egg masses and the eggs were counted and removed

weekly for eight successive weeks. Oviposition was observed from mid of November 2019 to mid of January 2020.

### 2.4. Hormonal analysis

Soft tissues of control and treated with different doses of contraceptive drug for 8 weeks were dissected out and homogenized in Phosphate-buffered saline. The homogenates were centrifuged at 8000 rpm at  $5 \text{ }^\circ\text{C}$  and the supernatants were stored at  $-80 \text{ }^\circ\text{C}$ . Levels of anti-müllerian hormone (AMH), Follicle stimulating hormone (FSH), Luteinizing hormone (LH), Prolactin (PRL), Testosterone (T), Estradiol (E2) and Thyroid-stimulating hormone (TSH) were measured using kits, two-immunological step sandwich type assay (Immunotech version; Beckman Coulter, Marseille, France). Progesterone (PRG) hormone was analyzed by ELISA technique.

### 2.5. Histological investigations

The hermaphrodite glands of both control and treated snails were dissected out and fixed in alcoholic Bouin. Specimens were dehydrated in ascending series of ethanol, cleared in Xylene for 20 min and embedded in paraffin wax. Sections ( $4\text{--}5 \mu\text{m}$  thick) were cut, mounted, and stained with Hematoxylin and Eosin.

### 2.6. Statistical analysis

All data were performed using the Statistical Package for the Social Sciences software (version 20, IBM SPSS, Armonk, NY, USA). Two-way ANOVA was applied to examine the effect of different concentration of contraceptive drug and exposure time on the total egg count. Comparisons of the effects of different drug concentrations on hormonal levels were performed using one-way analysis of variance (ANOVA). Duncan test was used to calculate significant differences ( $P < 0.05$ ) between tested treatments. Variables were presented as mean  $\pm$  S.E.

### 2.7. Ethical approval

All the studies involving human participants were performed in accordance with the ethical standards of the institutional and/or national research committee and with the 1964 Helsinki declaration and its later amendments or comparable ethical standards.

## 3. Results and discussion

### 3.1. Hormonal levels of treated snails

Levels of tested hormones of treated snails with three different concentrations of Yasmin® (Estrogen and Progesterone) contraceptive drug were decreased significantly with increasing drug concentrations, while

**Table 1.** Mean values of reproductive hormones levels of *E. vermiculata* exposed to different concentrations of contraceptive drug for 8 weeks.

| Hormones     | Drug concentrations |                         |                         |                         | F-value | P-value |
|--------------|---------------------|-------------------------|-------------------------|-------------------------|---------|---------|
|              | Control             | 303 ( $\mu\text{g/g}$ ) | 606 ( $\mu\text{g/g}$ ) | 909 ( $\mu\text{g/g}$ ) |         |         |
| AMH (ng/ml)  | $3.71 \pm 0.41^a$   | $2.42 \pm 0.81^b$       | $1.2 \pm 0.2^c$         | $0.6 \pm 0.1^c$         | 59.26   | 0.001   |
| FSH (mIU/ml) | $1.42 \pm 0.21^a$   | $0.68 \pm 0.25^b$       | $0.48 \pm 0.06^b$       | $0.30 \pm 0.02^b$       | 13.69   | 0.014   |
| LH (mIU/ml)  | $1.51 \pm 0.29^a$   | $0.95 \pm 0.07^b$       | $0.77 \pm 0.06^b$       | $0.61 \pm 1.32^c$       | 12.55   | 0.02    |
| PRL (ng/ml)  | $1.69 \pm 0.31^a$   | $2 \pm 0.26^a$          | $2.44 \pm 0.07^{ab}$    | $3.16 \pm 0.16^b$       | 8.39    | 0.03    |
| T (ng/dl)    | $8.50 \pm 0.00^a$   | $8.30 \pm 0.2^a$        | $8.20 \pm 0.3^a$        | $7.8 \pm 0.75^a$        | 0.58    | 0.66    |
| E2 (Pg/ml)   | $1905.5 \pm 12.2^a$ | $1328.2 \pm 30^b$       | $1030 \pm 19.1^c$       | $32.70 \pm 5.97^d$      | 1701.3  | 0.00    |
| PRG (ng/dl)  | $2.50 \pm 0.04^a$   | $1.80 \pm 0.21^b$       | $1.02 \pm 0.12^c$       | $0.51 \pm 0.1^d$        | 45.72   | 0.001   |
| TSH (mU/ml)  | $0.15 \pm 0.01^a$   | $0.09 \pm 0.01^{ab}$    | $0.07 \pm 0.01^{bc}$    | $0.02 \pm 0.0^c$        | 8.03    | 0.04    |

Variables were presented as mean  $\pm$  S.E. Mean values with the same alphabetical superscripts are statistically insignificant. Values are statistically significant at  $P < 0.05$ .

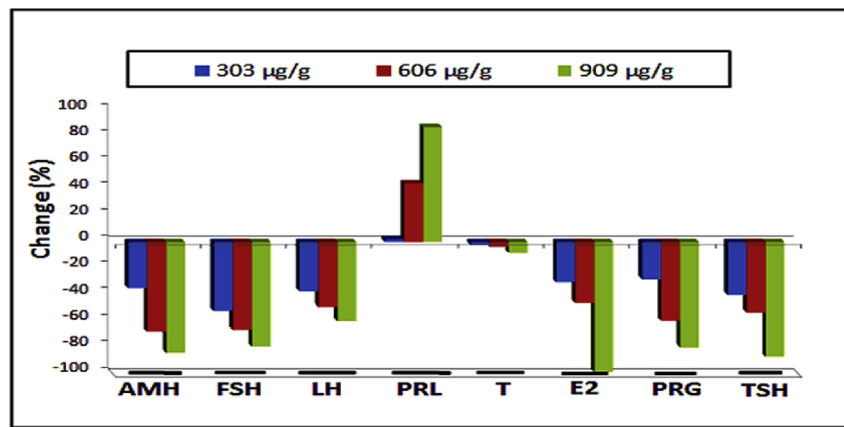


Figure 1. Changes (%) of reproductive hormones levels in *E. vermiculata* treated with different concentrations of contraceptive drug for 8 weeks.

Prolactin levels were significantly increased compared to control (Table 1). Percentage of decreases of anti-müllerian hormone (AMH), Follicle stimulating hormone (FSH), Luteinizing hormone (LH), Estradiol (E2), Progesterone (PRG), Thyroid-stimulating hormone (TSH) and Testosterone (T) of treated snails were decreased at the end of the 8<sup>th</sup> week by -83.3%, -78.9%, -59.6%, -98.3%, -79.6%, -86.7% and -8.2%, respectively compared to control. Prolactin (PRL) levels were increased significantly (86.9%) compared to control (Figure 1).

The endocrine role of the dorsal bodies in pulmonate snails was firstly reported by Lever (1958). Gonadal hormones of land snails control gametogenesis through a group of neuroendocrine mechanisms (Takeda, 1989). Synthetic steroids (estrogens and progestogens) are potent endocrine cripples altering endogenous hormone levels through interfering with the fabrication processes of hormones and this, in turn, alters various biochemical processes and disturbs reproduction and development in freshwater snails (Diaz-Cruz et al., 2003a). Anti-Müllerian hormone (AMH) is the best endocrine marker for detecting used to evaluate ovarian reserve and the age-related decrease of the ovarian pool in females (Grynnerup et al., 2012). In the present study, AMH levels were decreased significantly in treated snails and this decrease may be due to dramatic decrease in egg reserves within their hermaphroditic acini. Prolonged treatment with contraceptives drug caused a reduction of granulosa cell mass and this resulted in a significant decrease in AMH secretion (Sanna et al., 2013).

Follicle stimulating hormone (FSH) promotes the follicular growth in females and the development of primordial germ cells in males (Ulloa-Aguirre et al., 2018). Luteinizing hormone (LH) controls the ovulation and the production of both estrogen and progesterone from the ovary (Balasch et al., 2001; Kumar and Sait, 2011). FSH and LH regulate gonadal function and fertility (Osunkeye et al., 2019). The present study showed that FSH and LH levels were significantly decreased in treated *E. vermiculata* for 28 days. Synthetic hormones may decrease gonadotropin releasing hormones and consequently inhibiting FSH and LH secretion. The progestogen negative feedback and lack of estrogen positive feedback on LH secretion may stop the mid-cycle of LH flow and prevent ovulation (Baird and Glasier., 1993). Contrarily, exogenous administration of gonadotropin, Progesterone and 17 $\beta$ -oestradiol increased levels of gene expression of FSH receptors while LH receptors were not affected in all organ of treated *Archachatina marginata* snail (Osunkeye et al., 2019).

Estrogen is secreted from the ovaries and adrenal gland promotes the growth of the egg follicle (Diaz-Cruz et al., 2003b). Estradiol (E2) is a type of estrogen and its elevated levels may result in loss of sex drive while its low levels resulted in weight gain and cardiovascular disease (Schulster et al., 2016). The present results revealed that E2 levels of treated snails are decreased. Similarly, Omran and Salama (2016) found that E2 level decreased in gonadal tissue of *Biomphalaria alexandrina*

snails treated with sublethal concentrations of atrazine and glyphosate herbicides for 3 weeks. In accordance with this finding, Ibrahim and Sayed (2019) found that the level of E2 hormone were decreased significantly in the gonad tissue of the snail *Biomphalaria alexandrina* after exposure to sub-lethal concentrations of oxyfluorfen and attributed this decrease to the disturbance in the reproductive hormones. Progesterone (PRG) is a steroid sex hormone involved in embryogenesis of humans and other species and plays an important role in brain functions (Baulieu and Schumacher, 2000; Li et al., 2012). Progesterone levels of treated snails were decreased and this may be due to inhibition of the endocrine ovarian axis (Baird and Glasier., 1993). Testosterone (T) plays a key role in the development of male reproductive tissues (Bassil et al., 2009). Insufficient levels of testosterone in men may lead to abnormalities including frailty of bones (Tuck and Francis, 2009). Increasing levels of testosterone through a negative feedback inhibit the release of FSH and LH, respectively (Swerdlhoff et al., 1992). Testosterone levels were slightly decreased in treated *E. vermiculata* snails and this may be due to the inhibitory effects of the drug on the ovarian and adrenal androgens synthesis and/or increasing levels of sex hormones-binding globulin (Zimmerman et al., 2014). This finding is in agreement with Ibrahim and

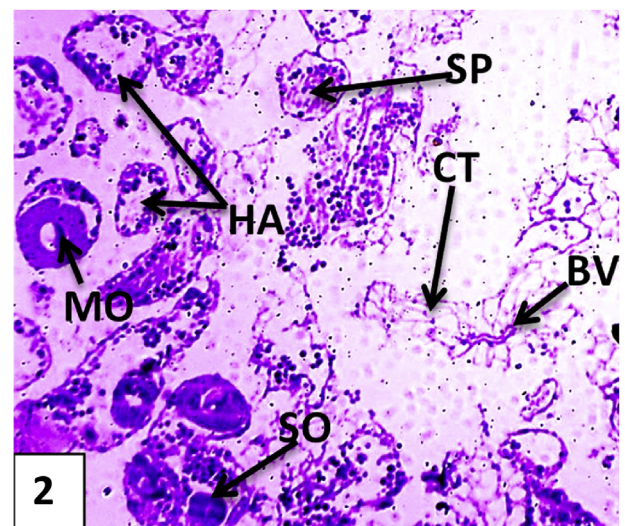


Figure 2. Photomicrographs showing sections in the hermaphrodite gland of control *E. vermiculata*. Hermaphroditic acini containing different developmental stages of oogenesis and spermatogenesis. H&E X 100. BV: blood vessel; CL: corpus luteum; CT: interacinar connective tissue; FC: Follicular cells; GE: germinal epithelium; HA: hermaphroditic acini; MO: mature oocyte; OO: oogonia; PS: primary spermatocytes; SD: spermatids; SO: secondary oocyte; SP: mature sperms; SR: Sertoli cell.

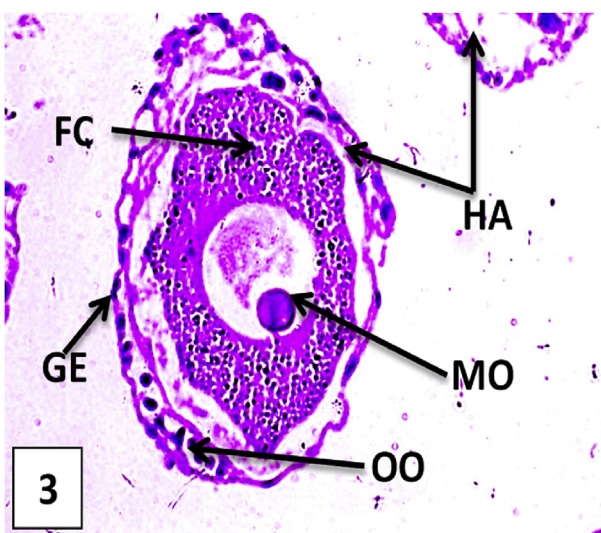


Sayed (2019) who found that the level of T hormone was decreased significantly in the gonad tissue of *B. alexandrina* treated with sub-lethal concentrations of some herbicides. Atrazine and glyphosate are toxic to Sertoli cells in mature rat and induced apoptosis at higher doses in germ cells (Clair et al., 2012). These results may suggest that oral contraceptive pills had side effects on male fertility by damaging developmental stages of spermatogenesis and cells which are responsible for producing testosterone hormone (Wafeeq, 2013). Thyroid-stimulating hormone (TSH) is a pituitary hormone that stimulates the thyroid gland to produce thyroxine ( $T_4$ ), and then triiodothyronine ( $T_3$ ) which promotes the metabolism of body tissues (Magner, 2014). It promotes growth and the maturation of bones and the central nervous system, increase carbohydrates, lipids and protein metabolism (Delitala et al., 2019). The decrease TSH in *E. vermiculata* may be due to disrupting effect of synthetic combined contraceptive drug. Prolactin (PRL), stimulates the mammary glands to produce milk which normally starts when levels of progesterone fall by the end of pregnancy and plays an important role in maternal behavior (Lucas et al., 1998). Elevated levels of prolactin decrease the levels of sex hormones — estrogen in women and testosterone in men (Freeman et al., 2000). Elevated prolactin secretion can suppress the secretion of FSH and GnRH, leading to hypogonadism and sometimes causing erectile dysfunction (Banerjee et al., 2004). There is no significant differences among hormones of *Archachatina marginata* snails at dormancy period except progesterone and testosterone and the mean concentrations of the hormones were found to be significantly influenced by the reproductive phases and aestivation (Okhale et al., 2018).

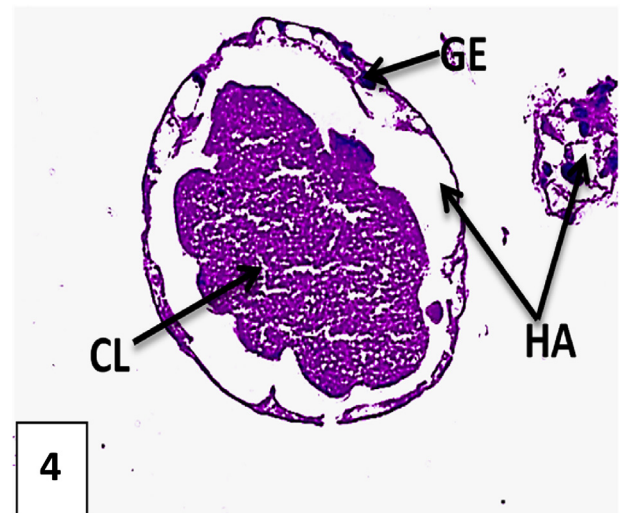
### 3.2. Histological investigations

#### 3.2.1. Normal hermaphrodite gland of *E. vermiculata*

The hermaphrodite gland (ovotestis) of *E. vermiculata* is embedded in the digestive gland and consists of many ovoid acini each is bounded by interacinar connective tissue supplied with blood vessels and containing some interstitial cells. It composed of many ovoid acini and each acinus is bordered by germinal epithelial layer and many Sertoli cells in between. Their lumens embrace developmental stages of spermatogenesis and oogenesis (Figures 2, 3, 4, and 5).



**Figure 3.** Photomicrographs showing sections in the hermaphrodite gland of control *E. vermiculata*. Mature oocyte surrounded with Graffian follicle. H&E X 400. BV: blood vessel; CL: corpus luteum; CT: interacinar connective tissue; FC: Follicular cells; GE: germinal epithelium; HA: hermaphroditic acini; MO: mature oocyte; OO: oogonia; PS: primary spermatocytes; SD: spermatids; SO: secondary oocyte; SP: mature sperms; SR: Sertoli cell.

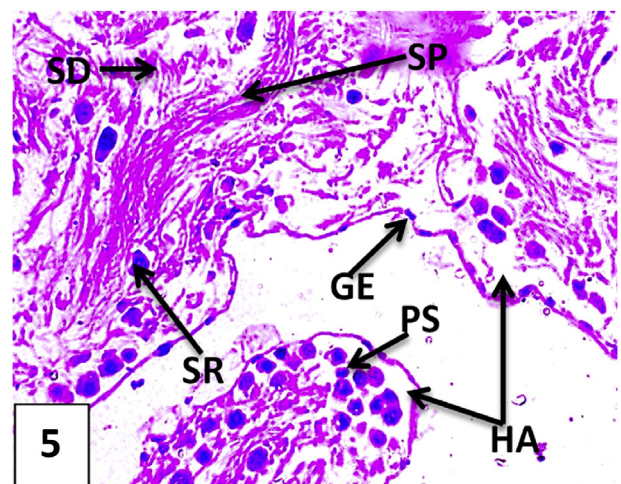


**Figure 4.** Photomicrographs showing sections in the hermaphrodite gland of control *E. vermiculata*. Corpus luteum lifted after releasing of mature oocyte. H&E X 400. BV: blood vessel; CL: corpus luteum; CT: interacinar connective tissue; FC: Follicular cells; GE: germinal epithelium; HA: hermaphroditic acini; MO: mature oocyte; OO: oogonia; PS: primary spermatocytes; SD: spermatids; SO: secondary oocyte; SP: mature sperms; SR: Sertoli cell.

#### 3.2.2. Histopathological alterations in treated snails

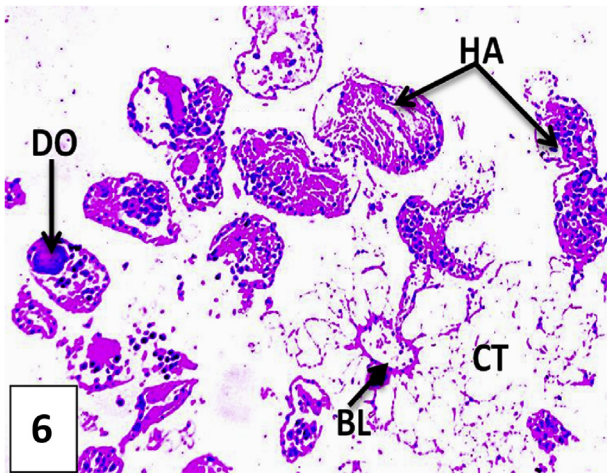
Histopathological investigations on the hermaphrodite glands of snails treated with 909  $\mu\text{g}/\text{gm}$  showed glandular hyperplasia, sloughing of germinal epithelial and with suppression of follicular growths (Figures 6 and 7). Cells of digestive gland tubules suffered from severe vacuolation (Figure 7). Size reduction associated with decreased luteinization and dilation of blood vessels of hermaphroditic acini were observed (Figure 8). Male acini showed histolytic developmental stages of spermatogenesis and mature sperms (Figure 9).

Reductions in the follicle-stimulating hormone (FSH), and the luteinizing hormone (LH) observed in this study are believed to suppress ovarian follicular development, and thus prevent ovulation (Taufert et al., 1980). Similarly, the injection of the gastropods *Achatina fulica* with vertebrate hormones such as estradiol, testoviron, progesterone and gonadotrophin caused serious histopathological changes in their



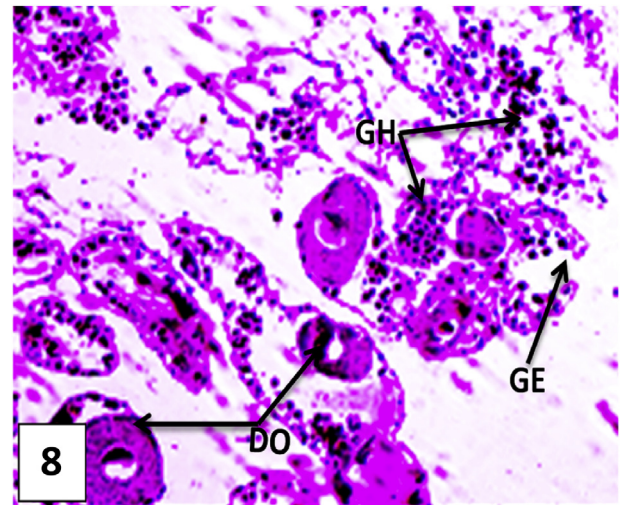
**Figure 5.** Photomicrographs showing sections in the hermaphrodite gland of control *E. vermiculata*. Hermaphroditic acini containing developmental stages of sperms. H&E X 400. BV: blood vessel; CL: corpus luteum; CT: interacinar connective tissue; FC: Follicular cells; GE: germinal epithelium; HA: hermaphroditic acini; MO: mature oocyte; OO: oogonia; PS: primary spermatocytes; SD: spermatids; SO: secondary oocyte; SP: mature sperms; SR: Sertoli cell.





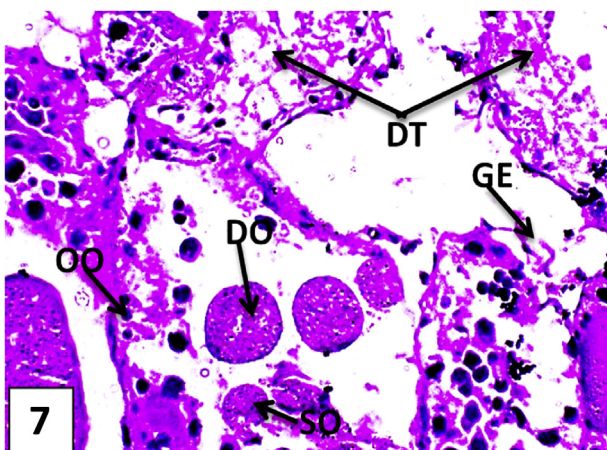
**Figure 6.** Photomicrographs showing sections in the hermaphrodite gland of *E. vermiculata* treated snails treated with 909 µg/g contraceptive pills for 8 weeks. Hermaphroditic acini showing glandular hyperplasia, decreased luteinization, dilation of blood vessels and oocytes deformations H&E X 100. BL: dilated blood vessel; CT: interacinai connective tissue; DO: Deformed oocytes; DS: Deformed spermatozoa; DT: Vacuolated digestive tubules cells; GE: Sloughed germinal epithelium; GH: Glandular hyperplasia; HA: hermaphroditic acini; OO: oogonia; PS: primary spermatocytes; SO: Secondary oocyte; SR: Sertoli cell; SS: Secondary spermatocytes.

ovotestis (Kruatrachue et al., 1996). Ovarian follicular development is not completely suppressed during the use of currently available combined oral contraceptives formulations in women (Baerwald et al., 2003). The changes in the ovaries appear to be a result of the suppressive effect of contraceptive steroids on pituitary gonadotropin secretion (Myhre, 1972). In agreement with this study, many histological alterations associated with oral contraceptive usage were detected in the ovaries and blood vessels of women as; glandular hyperplasia, ovarian size reduction suppression of follicle growth and decreased luteinization and fibrosis in blood vessels (Bernard, 1976). Inhibition of gonadotropin levels may result in inhibition of follicle maturation, luteinization as well as consequent reduction in ovarian size. Similarly, non-growing follicles

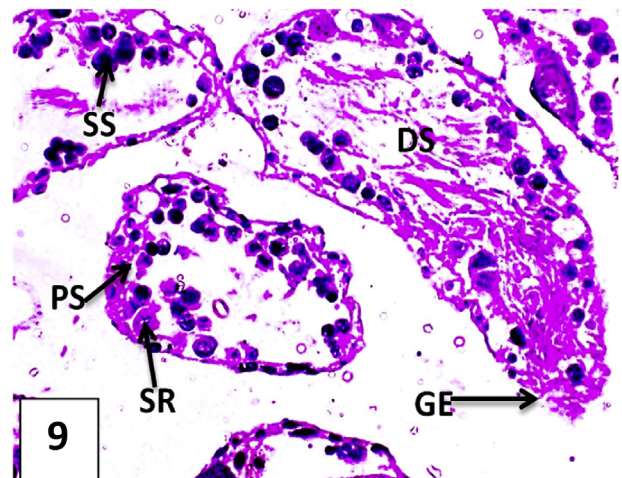


**Figure 8.** Photomicrographs showing sections in the hermaphrodite gland of *E. vermiculata* treated snails treated with 909 µg/g contraceptive pills for 8 weeks. Glandular hyperplasia, degenerated primordial follicles and oocyte deformation H&E X 400. BL: dilated blood vessel; CT: interacinai connective tissue; DO: Deformed oocytes; DS: Deformed spermatozoa; DT: Vacuolated digestive tubules cells; GE: Sloughed germinal epithelium; GH: Glandular hyperplasia; HA: hermaphroditic acini; OO: oogonia; PS: primary spermatocytes; SO: Secondary oocyte; SR: Sertoli cell; SS: Secondary spermatocytes.

and vacuolated interstitial cells were detected in female rabbits administered orally with combined pills (Gabri et al., 2010). Contraceptive pills might induce also proliferative changes in liver cells and this may be a result of vascular alterations (Carbia et al., 1970). Light microscopy revealed severe histopathological changes in the pituitary, thyroid and adrenal glands were represented by necrosis, cytoplasmic vacuolation and hyperplasia in Broiler chicken treated with Microgynon contraceptive pills (Layth and Majdy, 2018). Histopathological changes were observed in ovotestis acini of treated snails as damaged and destruction of germinal epithelial layer and reduction of spermatogenesis. Similar



**Figure 7.** Photomicrographs showing sections in the hermaphrodite gland of *E. vermiculata* treated snails treated with 909 µg/g contraceptive pills for 8 weeks. Sloughing of germinal epithelial tissue and many immature and deformed oocytes and vacuolation of digestive tubular cells. H&E X 400. BL: dilated blood vessel; CT: interacinai connective tissue; DO: Deformed oocytes; DS: Deformed spermatozoa; DT: Vacuolated digestive tubules cells; GE: Sloughed germinal epithelium; GH: Glandular hyperplasia; HA: hermaphroditic acini; OO: oogonia; PS: primary spermatocytes; SO: Secondary oocyte; SR: Sertoli cell; SS: Secondary spermatocytes.



**Figure 9.** Photomicrographs showing sections in the hermaphrodite gland of *E. vermiculata* treated snails treated with 909 µg/g contraceptive pills for 8 weeks. Hermaphroditic acini containing vacuolated and sloughed germinal epithelium histolytic of spermatogonia and mature sperms. H&E X 400. BL: dilated blood vessel; CT: interacinai connective tissue; DO: Deformed oocytes; DS: Deformed spermatozoa; DT: Vacuolated digestive tubules cells; GE: Sloughed germinal epithelium; GH: Glandular hyperplasia; HA: hermaphroditic acini; OO: oogonia; PS: primary spermatocytes; SO: Secondary oocyte; SR: Sertoli cell; SS: Secondary spermatocytes.

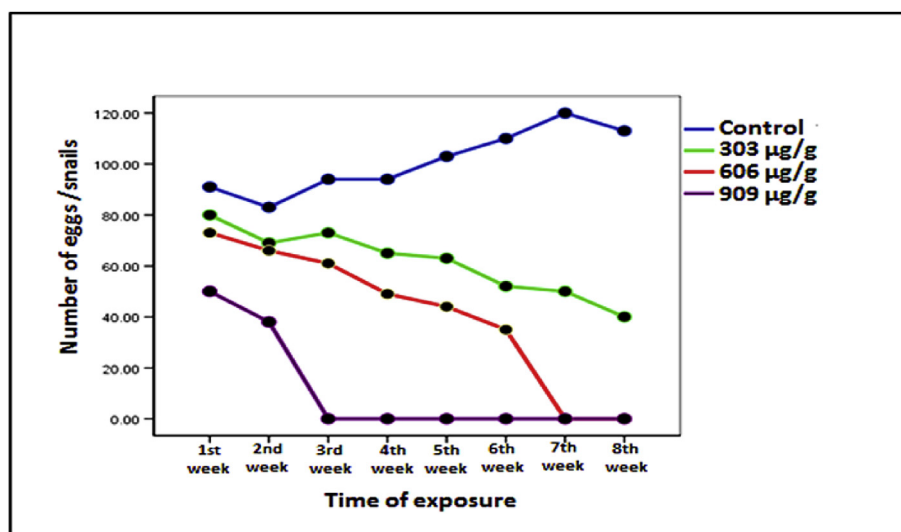


Figure 10. Egg count/10 *Eobania vermiculata* snails exposed to three different doses of contraceptive drug for 8 weeks.

results were observed in male mice treated with oral contraceptive pills (Wafeeq, 2013).

### 3.2.3. Rate of oviposition of *E. vermiculata*

Mean numbers of eggs/group of treated snails were significantly decreased with increasing the dose of the contraceptive drug and the time of treatments compared to control (Table 2). The lowest tested concentration (303 µg/gm.) caused gradual decrease of the total egg counts that reach 50% at the 8<sup>th</sup> week of exposure. Higher concentrations of contraceptive Pills (606 and 909 µg/gm.) caused dramatic dwindling of egg numbers and inspiring complete egg cessation at the 7<sup>th</sup> and 3<sup>rd</sup> weeks of treatments, respectively (Figure 10).

Egg production in several species of stylommatophoran gastropods is stimulated by mating behavior.

(Bride et al., 1991). The breeding period of land snails depends upon the climate of the geographic region, temperature and humidity (Attia, 2004). In Western Europe the breeding period lasts from April to June while at the Mediterranean multiple copulations and ovipositions within one reproduction period may occur and last from October to December and February to April (Nicolai et al., 2005). Important triggers of egg oviposition in *lymnaea stagnalis* pond snails were oxygen - rich clear

water, water quality and light (Ter Maat et al., 2012; El-Sayed et al., 2020). Oviposition period of *E. vermiculata* was averaged from 15 to 25 days (Mohamed and Ali 2009). In this study the mean numbers of eggs of treated snails were significantly decreased with increasing the dose of the contraceptive drug and the time of treatments. The combination of the estrogen and progesterone steroids creates a synergistic effect that greatly increases their anti-gonadotropic and ovulation-inhibitory effects (Curtis et al., 2013). Their efficacy may be due to a range of effects causing a decrease in FSH and LH, leading to the suppression of follicular activity and ovulation (Baerwald et al., 2004; El-Sayed et al., 2017). With no follicular development and the absence of luteinizing hormone flow to release the follicle, prevention of ovulation occurred (Baird and Glasier., 1993). Similarly, Sublethal concentrations of chlorfluazuron (IGR) complete absence of ova in the ovotestis of *E. vermiculata* (Mubarak, 2016). Contrary, low concentrations of 17- $\alpha$ -methyltestosterone (a synthetic hormone promoting male monosex in fish aquaculture) significantly increased the number of egg mass (Rivero-Wendt et al., 2014). There was a marked increase in the size of the ovotestis number of oocytes in *Achatina fulica* snails injected with estradiol and progesterone (Kruatrachue et al., 1996). Chitosan and emamectin benzoate caused prevention of egg production in treated *E. vermiculata* snails (Patel et al., 2016; Kandil et al., 2020). Finally, the squeaky decreases of the tested

Table 2. Mean numbers of eggs of *Eobania vermiculata* exposed to different doses of contraceptive tablets for 8 weeks.

| Exposure Time         | Drug conc.            |                      |                      |                      |
|-----------------------|-----------------------|----------------------|----------------------|----------------------|
|                       | Control               | 303 µg/g             | 606 µg/g             | 909 µg/g             |
| 1st week              | 91 ± 4 <sup>a</sup>   | 80 ± 10 <sup>a</sup> | 73 ± 3 <sup>ab</sup> | 50 ± 5 <sup>b</sup>  |
| 2nd week              | 83 ± 3 <sup>a</sup>   | 69 ± 8 <sup>a</sup>  | 66 ± 4 <sup>a</sup>  | 38 ± 2 <sup>b</sup>  |
| 3rd week              | 94 ± 14 <sup>a</sup>  | 73 ± 2 <sup>b</sup>  | 61 ± 6 <sup>b</sup>  | 0 ± 0.0 <sup>c</sup> |
| 4th week              | 94 ± 6 <sup>a</sup>   | 65 ± 14 <sup>b</sup> | 49 ± 11 <sup>b</sup> | 0 ± 0.0 <sup>c</sup> |
| 5th week              | 103 ± 7 <sup>a</sup>  | 63 ± 7 <sup>b</sup>  | 44 ± 4 <sup>b</sup>  | 0 ± 0.0 <sup>c</sup> |
| 6th week              | 110 ± 20 <sup>a</sup> | 52 ± 11 <sup>b</sup> | 35 ± 5 <sup>bc</sup> | 0 ± 0.0 <sup>c</sup> |
| 7th week              | 120 ± 10 <sup>a</sup> | 50 ± 3 <sup>b</sup>  | 0 ± 0.0 <sup>c</sup> | 0 ± 0.0 <sup>c</sup> |
| 8th week              | 113 ± 23 <sup>a</sup> | 40 ± 12 <sup>b</sup> | 0 ± 0.0 <sup>c</sup> | 0 ± 0.0 <sup>c</sup> |
| Two-way ANOVA         | F-Value               | P-value              |                      |                      |
| Exposure time         | 7.59                  | 0.000                |                      |                      |
| Tested concentrations | 169.04                | 0.000                |                      |                      |
| Exposure time x conc. | 5.11                  | 0.000                |                      |                      |

Variables were presented as mean ± S.E. Mean values with the same alphabetical superscripts are statistically insignificant. Values are statistically significant at P < 0.05.



reproductive hormones levels, malformations of sperms and ova and complete egg cessation at the third week after treatment of snails with contraceptive pills as baits may assure the efficacy of this method in controlling high population densities of *E. vermiculata* devouring citrus trees at Sharkia Governorate, Egypt.

#### 4. Conclusion

Yasmin® contraceptive drug caused dramatic inhibition of hormones levels, deleterious histopathological effects on the hermaphrodite glands in addition to egg cessation and sperms malformations. The application of contraceptive drugs for the first time was promising in controlling high populations of *E. vermiculata* snails. This environmentally safe baits technique was efficient control method and ensures survival of non-target organisms harmed by using synthetic molluscicides. Usage of contraceptive drugs in controlling *E. vermiculata* snails by baits technique was effective, easily applicable, ecofriendly technique and could be used in decreasing numbers of other types of land snails damaging economic crops at Egypt.

#### Declarations

##### Author contribution statement

Mahmoud S. Abd El-Atti, Ashraf S.A. El-Sayed: Conceived and designed the experiments.

Radwa M. Said: Performed the experiments.

##### Funding statement

This research did not receive any specific grant from funding agencies in the public, commercial, or not-for-profit sectors.

##### Data availability statement

Data included in article.

##### Declaration of interests statement

The authors declare no conflict of interest.

##### Additional information

No additional information is available for this paper.

#### References

- Abd El-Atti, M.S., Khalil, A.M., Elsheakh, A.A., Elgohary, S.W., 2020. Biological control of *Monacha cartusiana* "glassy clover land snails" by microbial biopesticides Biozed and Biogard, using bait technique. *Biocat. Agric. Biotech.* 25, 1–6.
- Ali, G.S., Norman, D., El-Sayed, A.S., 2015. Soluble and volatile metabolites of plant growth-promoting rhizobacteria (PGPRs): role and practical applications in inhibiting pathogens and activating induced systemic resistance (ISR). *Adv. Bot. Res.* 75, 241–284.
- Arad, Z., Goldenberg, S., Heller, J., 1993. Intraspecific variation in resistance to desiccation and climatic gradients in the distribution of the bush-dwelling snail *Trochoidea simulata*. *J. Zool. (London)*. 229, 249–265.
- Attia, J., 2004. Behavioural rhythms of land snails in the field. *Biol. Rhythm. Res.* 35, 35–41.
- Baerwald, A.R., Adams, G., Pierson, R., 2003. Characterization of ovarian follicular wave dynamics in women. *Biol. Reprod.* 69 (3), 23–31.
- Baerwald, A.R., Olatunbosun, O.A., Pierson, R.A., 2004. Ovarian follicular development is initiated during the hormone-free interval of oral contraceptive use. *Contraception* 70 (5), 371–377.
- Baird, D.T., Glasier, A.F., 1993. Hormonal contraception. *N. Engl. J. Med.* 328 (21), 1543–1549.
- Balash, J., Creus, M., Fabregues, F., Civico, S., Carmona, F., Puerto, B., 2001. The effect of exogenous luteinizing hormone (LH) on oocyte viability: evidence from a comparative study using recombinant follicle-stimulating hormone (FSH) alone or in combination with recombinant LH for ovarian stimulation in pituitary-suppressed women undergoing assisted reproduction. *J. Assist. Reprod. Genet.* 18, 250–256.

- Banerjee, S., Paul, P., Talib, V.J., 2004. Serum prolactin in seizure disorders. *Indian Pediatr.* 41 (8), 827–831.
- Bassil, N., Alkaade, S., Morley, J.E., 2009. The benefits and risks of testosterone replacement therapy: a review. *Therapeut. Clin. Risk Manag.* 5 (3), 427–448.
- Baulieu, E., Schumacher, M., 2000. Progesterone as a neuroactive neurosteroid, with special reference to the effect of progesterone on myelination. *Steroids* 65 (10–11), 605–612.
- Bernard, G.M.D., 1976. Histologic changes associated with oral contraceptive usage. *Ann. Clin. Lab. Sci.* 6 (4), 291–299.
- Bride, J., Gomot, L., Saleuddin, A.S.M., 1991. Mating and 20-hydroxyectyosone cause in increased galactogen synthesis in the albumen gland explants of *helix aspersa* (Mollusca). *Comp. Biochem. Physiol.* 98 (B), 369–373.
- Burla, H., Gosteli, M., 1993. Thermal advantage of pale coloured morphs of the snail *Arianta arbustorum* (Helicidae, Pulmonata) in alpine habitats. *Ecography* 16, 345–350.
- Carbia, E., Rubio -Linares, G., Alvarado -Duran, A., Lopex -Liera, M., 1970. Histologic study of the uterine cervix during oral contraception with ethynodiol diacetate and mestranol. *Obstet. Gynecol.* 35, 381–388.
- Clair, É., Mesnage, R., Travert, C., Séralini, G.É., 2012. A glyphosate-based herbicide induces necrosis and apoptosis in mature rat testicular cells in vitro, and testosterone decrease at lower levels. *Toxicol. Vitro* 26, 269–279.
- Curtis, K.M., Tepper, N.K., Jamieson, D.J., Marchbanks, P.A., 2013. Adaptation of the World Health Organization's selected practice recommendations for contraceptive use for the United States. *Contraception* 87 (5), 513–516.
- Delitala, A.P., Capobianco, G., Cherchi, P.L., Dessole, S., Delitala, G., 2019. Thyroid function and thyroid disorders during pregnancy: a review and care pathway. *Arch. Gynecol. Obstet.* 299 (2), 327–338.
- Diaz-Cruz, M.S., de Alda, M.J.L., Barcelo, D., 2003a. Environmental behaviour and analysis of veterinary and human drugs in soils, sediments and sludge. *Trends Anal. Chem.* 22, 340–351.
- Diaz-Cruz, M.S., Lopez de Alda, M.J., Lopez, R., Barcelo, D., 2003b. Determination of estrogens and progestogens by mass spectrometric techniques (GC/MS, LC/MS and LC/MS/MS). *J. Mass Spectrom.* 38 (9), 917–923.
- El-Sayed, H.E., 2013. Survey and distribution of terrestrial snails in fruit orchards and ornamental plants at Alexandria and El-Beheira Governorates, Egypt. *Alexandria Sci. Exch. J.* 34 (2), 242–248.
- El-Sayed, A.S.A., Ali, G.A., 2020. *Aspergillus flavipes* is a novel efficient biocontrol agent of *Phytophthora parasitica*. *Biol. Contr.* 140, 104072.
- El-Sayed, A.S.A., Yassin, M.A., Ali, G.S., 2015. Transcriptional and proteomic profiling of *Aspergillus flavipes* in response to sulfur starvation. *PLoS One* 10 (12), e0144304.
- El-Sayed, A.S.A., Moustafa, A.H., Hussein, H.A., El-Sheikh, A.A., El-Shafey, S.N., Fathy, N.A.M., Enan, G.A., 2020. Potential insecticidal activity of *Sarocladium strictum*, an endophyte of *Cynanchum acutum*, against Spodoptera littoralis, a polyphagous insect pest. *Biocat. Agric. Biotechnol.* 24, 101524.
- El-Sayed, A.S.A., Ruff, L.E., Ghany, S.E.A., Ali, G.S., Esener, S., 2017. Molecular and spectroscopic characterization of *Aspergillus flavipes* and *Pseudomonas putida* L-methionine  $\gamma$ -lyase in vitro. *Appl. Biochem. Biotechnol.* 181, 1513–1532.
- El-Sayed, A.S.A., Akbar, A., Iqar, I., Ali, R., Norman, D., Brennan, M., Ali, G.S., 2018. A glucanolytic *Pseudomonas* sp. associated with Smilax bona-nox L. displays strong activity against *Phytophthora parasitica*. *Microbiol. Res.* 207, 140–152.
- El-Sayed, A.S.A., Shindia, A.A., Zeid, A.A.A., Yassin, A.M., Sitohy, M.Z., Sitohy, B., 2019a. *Aspergillus nidulans* thermostable arginine deiminase-Dextran conjugates with enhanced molecular stability, proteolytic resistance, pharmacokinetic properties and anticancer activity. *Enzym. Microb. Technol.* 131 (12), 109432.
- El-Sayed, A.S.A., Mohamed, N.Z., Safan, S., Yassin, M.A., Shaban, L., Shindia, A.A., Shad Ali, G., Sitohy, M.Z., 2019c. Restoring the Taxol biosynthetic machinery of *Aspergillus terreus* by *Podocarpus gracilior* Pilger microbiome, with retrieving the ribosome biogenesis proteins of WD40 superfamily. *Sci. Rep.* 9 (1), 11534.
- Freeman, M.E., Kanyicska, B., Lerant, A., Nagy, G., 2000. Prolactin: structure, function, and regulation of secretion. *Physiol. Rev.* 80 (4), 1523–1631.
- Gaber, W.M., Youssef, A.S., Khidr, F.K., 2006. Molluscicidal effect of certain compounds against two land snail species *Monacha obstructa* and *Eobania vermiculata* under laboratory and field conditions. *Egypt. J. of Agric. Res.* 84 (1), 43–50.
- Gabri, S.M., Abdel kader, H.D., Mona, A., Ibrahim, A.M., Hassan, N.B., 2010. Histological and immunohistochemical changes in rabbit ovary under the effect of two types of contraceptive pills. *Egypt. J. Exp. Biol.* B (1), 1–7.
- Genena, M.A.M., Mostafa, F.A.M., 2008. Molluscicidal activity of six pesticides against the two land snails *Monacha cantiana* and *Eobania vermiculata* (Gastropoda: helicidae). *J. Agric. Sci. Mansoura Univ.* 33 (7), 5307–5315.
- Grynnerup, A.G., Lindhard, A., Sorensen, S., 2012. The role of anti-Müllerian hormone in female fertility and infertility - an overview. *Acta Obstet. Gynecol. Scand.* 91 (11), 1252–1260.
- Ibrahim, A.M., Sayed, D.A., 2019. Toxicological impact of oxyfluorfen 24% herbicide on the reproductive system, antioxidant enzymes, and endocrine disruption of *Biomphalaria alexandrina* (Ehrenberg, 1831) snails. *Environ. Sci. Pollut. Res.* 26 (8), 7960–7968.
- Ismail, Sh.A.A., Issa, M.A., Shettaia, S.Z.S., Khattab, M.M., 2017. Dispersal of the land snail *Eobania vermiculata* in citrus orchards in Sharkia Governorate. *J. Plant Prot. Path., Mansoura Univ.* 8 (4), 177–180.
- Kandil, M.A., Eweis, E.A., Mobarak, S.A., Abbas, N.M.T., 2020. Effects of chitosan and emamectin benzoate on the reproductive system of *Eobania vermiculata* (Muller) land snails. *Egypt. J. Biol. Pest Cont.* 30 (21), 2–8.
- Koering, M.J., Danforth, D.R., Hodgen, G.D., 1994. Early follicle growth in the juvenile macaca monkey ovary: the effects of estrogen priming and follicle-stimulating hormone. *Biol. Reprod.* 50, 686–694.

- Kruatrachue, M., Songmuang, K., Suchart, E.U., Sretarugsa, P., Chavadei, I., 1996. Effect of vertebrate hormones on the reproductive system of *Achatina fulica* (gasrtopoda: stylomatophora). *J. Sci. Thailand.* 22, 249–265.
- Kumar, P., Sait, F.S., 2011. Luteinizing hormone and its dilemma in ovulation induction. *J. Hum. Reprod. Sci.* 4 (1), 2–7.
- Lazaridou-Dimitriadou, M., Kattoulas, M.E., 1991. Energy flux in a natural population of the land snail *Eobania vermiculata* (Müller) (Gastropoda: pulmonata: Stylommatophora) in Greece. *Can. J. Zool.* 69, 881–891.
- Layth, M.M., Majdy, F.M., 2018. A Study of physiological and histopathological effect of oral contraceptive (Microgynon) overdose on female Broiler chicken. *Basrah J. Vet. Res.* 17 (1), 1–13.
- Lever, J., 1958. The medio-dorsal on the relation between the mid-dorsal bodies and the cerebral ganglia in some pulmonates. *Arch. Neerl. Zool.* 13, 194–201.
- Li, Z., Wang, B., Kan, Z., Zhang, B., Yang, Z., Chen, J., Wang, D., Wei, H., Zhang, J.N., Jiang, R., 2012. Progesterone increases circulating endothelial progenitor cells and induces neural regeneration after traumatic brain injury in aged rats. *J. Neurotrauma* 29 (2), 343–353.
- Lucas, B.K., Ormandy, C.J., Binart, N., Bridges, R.S., Kelly, P.A., 1998. Null mutation of the prolactin receptor gene produces a defect in maternal behavior. *Endocrinology* 139 (10), 4102–4107.
- Magner, J., 2014. Historical note: many steps led to the discovery of thyroid-stimulating hormone. *Europ. Thyro. J.* 3 (2), 95–100.
- Massoud, A.M., Habib, F.S.M., 2003. The effect of *Myrrh commiphora* molmol on the infected snails of *Schistosoma* species and their egg masses: effect on shedding of cercariae and on snail fecundity. *J. Egypt. Soc. Parasitol.* 33 (2), 585–596.
- Mohamed, M.I., Ali, R.F., 2009. Reproduction and life history in the two land snails *Monacha cartusiana* (Müller) and *Eobania vermiculata* (Müller) (Helicidae: Mollusca) in the laboratory. *Anim. Biol. Leiden J.* 1 (2), 99–107.
- Mubarak, S.A., 2016. The malformation effect of chlorfluazuron on the reproductive system of land snail *Eobania vermiculata*. *The J. Bas. & Appl. Zoo.* 74, 51–55.
- Myhre, E., 1972. Ovarian morphology following long-term treatment with sex hormones and contraceptive steroids in mice. *Acta Pathol. Microbiol. Scand.* 80 (23), 67–75.
- Neubert, E., 1998. Annotated checklist of the terrestrial and freshwater molluscs of the Arabian Peninsula with descriptions of new species. *Faun. Arab.* 17, 333–461.
- Nicolai, A., Vernon, P., Lee, M., Ansart, A., Charrier, M., 2005. Supercooling ability in two populations of the land snail *Helix pomatia* (Gastropoda: helicidae) and ice-nucleating activity of gut bacteria. *Cryobiology* 50, 48–57.
- Okhale, O.E., Omoyakhi, J.M., Edo-Taiwo, O., Aremu, O.T., 2018. Hormonal concentration of controlled and naturally induced aestivated snails (*Archachatina marginata*) at different reproductive phases. *J. Appl. Life Sci. Intern.* 16 (1), 1–9.
- Omran, N.E., Salama, W.M., 2016. The endocrine disruptor effect of the herbicides atrazine and glyphosate on *Biomphalaria alexandrina* snails. *Toxicol. Ind. Health* 32, 656–665.
- Osunkeye, O.J., Onagbesan, O.M., Abiona, J.A., Jinadu, S.O., 2019. Gene expression of follicle stimulating hormone (FSH) and luteinizing hormone (LH) receptors in some of the reproductive organs of Giant African land snail (*Archachatina marginata*). *J. Appl. Life Sci. Int.* 22 (3), 1–10.
- Patel, J.S., Vitoreli, A., Palmateer, A.J., El-Sayed, A., Norman, D.J., Goss, E.M., Brennan, M.S., Ali, G.S., 2016. Characterization of phytophthora spp. isolated from ornamental plants in Florida. *Plant Dis.* 100 (2), 500–509.
- Pincus, G., Rock, J., Garcia, C., 1958. Fertility control with oral medication. *Am. J. Obstet. Gynecol.* 75, 1333–1346.
- Riddle, W.A., Miller, V.J., 1988. Cold-hardiness in several species of land snail. *J. Therm. Biol.* 13, 163–167.
- Rivero-Wendt, C.L.G., Borges, A.C., Oliveira-Filho, E.C., Miranda-Vilela, A.L., Ferreira, M.F.N., Grisolia, C.K., 2014. Effects of 17 $\alpha$ -methyl testosterone on the reproduction of the freshwater snail *Biomphalaria glabrata*. *Genet. Mol. Res.* 13 (1), 605–615.
- Ronsmans, J., Van den Neucker, T., 2016. A persistent population of the chocolate-band snail *Eobania vermiculata* (Gastropoda: helicidae) in Belgium. *Belg. J. Zool.* 146 (1), 66–68.
- Rug, M., Ruppel, A., 2000. Toxic activities of the plant *Jatropha curcas* against intermediate snail hosts and larvae of schistosomes. *Trop. Med. Int. Health* 5, 423–430.
- Sanna, K., Johanna, P., Aimo, R., Tommi, V., Terhi, P., Juha, S.T., 2013. Antimüllerian hormone levels decrease in women using combined contraception independently of administration route. *J. Fert. Ster.* 99 (5), 1305–1310.
- Schulster, M., Bernie, M.A., Ramasamy, A., 2016. The role of estradiol in male reproductive function. *Asian J. Androl.* 18 (3), 435–440.
- Scott, B., 1997. Biogeography of the helicoidae (Mollusca: gastropoda: pulmonata). *Land snails with a pangean distribution. J. Biogeogr.* 24, 399–407.
- Singh, S.K., Yadav, R.P., Singh, A., 2000. Molluscicidal activity of *Thevetia peruviana* a common medicinal plant of India. *J. Med. Aromat. Plant Sci.* 22 (4A), 113–116. –23(1A).
- Speiser, B., Rowell-Rahier, M., 1993. Does the land snail *Arianta arbustorum* prefer sequentially mixed over pure diets? *Funct. Ecol.* 7, 403–410.
- Swerdlloff, R.S., Wang, C., Bhasin, S., 1992. Developments in the control of testicular function. *Baill. Clin. Endocr. Metab.* 6 (2), 451–483.
- Tafurt, C.A., Sobrevilla, L.A., de Estrada, R., 1980. Effects of progestin-estrogen combination and progestational contraceptives on pituitary gonadotropins, gonadal steroids and sex hormone-binding globulin. *Fertil. Steril.* 33, 261–266.
- Takeda, N., 1989. Hormonal control of reproduction in land snails. *VENUS, Jap. J. Malac.* 48 (2), 99–139.
- Ter Maat, A., Pieneman, A.W., Koene, J.M., 2012. The effect of light on induced egg laying in the simultaneous hermaphrodite *Lymnaea stagnalis*. *J. Molluscan Stud.* 78, 262–267.
- Tuck, S.P., Francis, R.M., 2009. Testosterone, bone and osteoporosis. *Advances in the management of testosterone deficiency. Front. Horm. Res.* 37, 123–132.
- Ueshima, R., Okamoto, M., Saito, Y., 2004. *Eobania vermiculata*, a land snail newly introduced into Japan. *Chiribotan* 35 (3), 71–74.
- Ulloa-Aguirre, A., Reiter, E., Crepitus, P., 2018. FSH receptor signaling: complexity of interactions and signal diversity. *Endocrinology* 159 (8), 3020–3035.
- Wafeeq, N.H.A., 2013. Histological and biochemical study on effect of the oral contraceptive pills in experimental male mice. *AL- Taq.* 26 (3), 37–45.
- Zimmerman, Y., Eijkemans, M.G.C., Coelingh Bennink, H.J., Blankenstein, M.A., Fauser, B.C.J.M., 2014. The effect of combined oral contraception on testosterone levels in healthy women: a systematic review and meta-analysis. *Hum. Reprod. Update* 20 (1), 76–105.