

Relationship between the risk of bile duct injury during laparoscopic cholecystectomy and the types of preoperative magnetic resonance cholangiopancreatography (MRCP)

Yun Ho Chung¹, Doo Jin Kim¹, In-Gyu Kim¹, Han Jun Kim¹, Seong Eun Chon¹, Jang Yong Jeon¹, Jae Pil Jung¹, Jin Cheol Jeong¹, Joo Seop Kim¹, and Eun Joo Yun²

Departments of ¹Surgery and ²Radiology, Hallym University Medical Center, Hallym University College of Medicine, Seoul, Korea

Backgrounds/Aims: Bile duct injury is one of the potential severe complications that can occur during laparoscopic cholecystectomy, which can be caused by anatomic variations in the confluence of the bile duct. Recently magnetic resonance cholangiopancreatography (MRCP) has become a helpful tool to detect bile duct variation on a preoperative basis and to prevent bile duct injury during laparoscopic cholecystectomy, as well as other hepatic surgeries. This study aimed to clarify the types of bile duct on MRCP and to search for a method of avoiding injury during laparoscopic cholecystectomy. **Methods:** Between January 2009 and December 2010, 277 patients underwent laparoscopic cholecystectomy with preoperative MRCP in our institution. On a retrospective basis, the bile ducts were categorized into 5 types according to the Couinaud classification system. **Results:** The proportion of types was revealed type A (70.4%), type B (8.7%), type C (19.5%), type D (0.7%), type E (0%), and type F (0.7%), respectively. Bile duct injury occurred in 4 cases (1.4%) during laparoscopic cholecystectomy. In particular, the possibility of aberrant extrahepatic confluence (Type C and F) represented the highest risk of duct injury (OR=11.89 [CI: 1.21-116.53]). **Conclusions:** Preoperative evaluation of the bile duct anatomy is important to avoid injury of duct during laparoscopic cholecystectomy. Specific types of bile duct variation should be considered as a high risk group for bile duct injury. (*Korean J Hepatobiliary Pancreat Surg* 2012;16:17-23)

Key Words: Bile duct; Magnetic resonance cholangiopancreatography; Cholecystectomy

INTRODUCTION

In the field of hepatobiliary pancreatic surgery, an understanding of the anatomical variations of the branching of bile duct is an essential factor for the surgical procedure. Recent technical advancement of various types of hepatectomy, such as laparoscopic hepatectomy and donor hepatectomy for living donor liver transplantation (LDLT), has increased the number of surgical plans that can be made only after surgeons have achieved a complete understanding of the branching of the bile duct.¹⁻³

There are some cases in which the anatomical variations of bile duct cannot be accurately confirmed because of a limited accessibility and an inability to palpate. Patients who underwent laparoscopic cholecystectomy might experience

unexpected injury to the bile duct.^{4,5} Once injury of the bile duct occurs, it is not only a matter of course that the surgery should be converted to laparotomy, but the occurrence of complications is increased. This may lead to death in severe cases.⁵ On a preoperative basis, various methods have been attempted to minimize injury to the bile duct. A magnetic resonance cholangiopancreatography (MRCP) is a non-invasive imaging modality that is useful in evaluating the anatomical variations of the bile duct system. Recently, the use of MRCP has increased.^{3,6,7}

At our institution, a preoperative MRCP is the increasingly preferred method for laparoscopic cholecystectomy. Given the above-mentioned backgrounds, we performed a retrospective analysis of the preoperative MRCP in patients who underwent laparoscopic cholecystectomy. Thus,

Received: October 24, 2011; **Revised:** December 10, 2011; **Accepted:** February 5, 2012

Corresponding author: Joo Seop Kim

Department of Surgery, Kang-dong Sacred Heart Hospital of Hallym University Medical Center, 445, Gil-dong, Gangdong-gu, Seoul 134-701, Korea

Tel: +82-2-2224-2222, Fax: +82-2-2224-2570, E-mail: drkdj@hallym.or.kr

we classified and then analyzed the anatomical variations of the bile duct. In addition, according to the results of the above analysis, we examined whether the difference in surgical outcomes and the anatomical variations of the bile duct was associated.

METHODS

The current retrospective study was conducted in 277 patients who underwent laparoscopic cholecystectomy following a preoperative MRCP at Kangdong Sacred Heart Hospital of Hallym University during a 2-year period from January of 2009 to December of 2010. In the current study, exclusion criteria include patients who underwent laparoscopic cholecystectomy without a preoperative MRCP and those who underwent a planned open cholecystectomy initially because of the gallbladder cancer, the stone in the common bile duct or other reasons. However, we enrolled patients with a stone in the common bile duct who had a complete removal of the stone in the common bile duct following the use of endoscopic retrograde cholangiopancreatography (ERCP) and then underwent a laparoscopic cholecystectomy. A surgical procedure was performed under the supervision of two hepatobiliary surgeons or trainees.

MRCP scans were obtained using a 1.5-T superconductive MRI system (Philips Medical systems, Intera, The Netherlands). With the use of single-shot fast spin echo (SSFSE), transverse and coronal source images were obtained. With the use of 3-dimensional turbo spin-echo (3DTSE), coronal source images were obtained. With the use of maximal intensity projection (MIP), 3-dimensional images were obtained.

The types of bile duct on MRCP were classified according to the Couinaud classification system,^{8,9} which was done by the radiologist and the hepatobiliary surgeon. Unless there was a concordance between them, the determination was made based on the surgical findings as follows:

- Type A: Typical anatomy of the confluence
- Type B: Triple confluence
- Type C: Ectopic drainage of a right sectoral duct into the common hepatic duct
- Type D: Ectopic drainage of a right sectoral duct into the left hepatic ductal system

Type E: Absence of the hepatic confluence

Type F: Ectopic drainage of the right posterior duct into the cystic duct

Schematic illustrations and MRCP findings, corresponding to the representative cases of each type, are shown in Fig. 1. Because there were few patients who could be classified into Type E in the current study, these images could not be obtained.

According to the Couinaud classification system, Types C, D and E have their own subtypes based on the types of secondary branching of the bile duct. However, it is not possible to determine these subtypes if there is a lack of the accurate follow-up on each pathway. In addition, it is difficult to confirm the pathway of the intrahepatic bile duct, and there is a limitation in the resolution of MRCP.

We have hypothesized that patients are at increased risks for injury to the bile duct because of the extrahepatic branching of bile duct among the abnormal branches of a bile duct during the laparoscopic cholecystectomy. Therefore, we classified Types A, B, D and E, where there are no increased risks during the cholecystectomy because of the intrahepatic branching, into a low-risk group of patients. The remaining Types C and F were classified into a high-risk group of patients. After this classification, the data underwent statistical analysis.

To examine the effects of the anatomical variations of the bile duct on laparoscopic cholecystectomy and the relevant clinical course, we performed an analysis on the following factors: patient age, sex, operation time, histopathological findings, the concurrent presence of the stone in the bile duct, the conversion to laparotomy, an intraoperative injury to the bile duct, operators, and length of postoperative hospital stay.

Statistical analysis was performed using SPSS (version 13.0). Mean values of the continuous variables were analyzed using an independent student's t-test and a Mann-Whitney U-test. In addition, a cross-tabulation analysis of the non-continuous variables was performed using a Pearson's Chi-square test and a Fisher's exact test. A *p*-value of <0.05 was considered statistically significant.

RESULTS

Clinical characteristics and variables in our clinical ser-

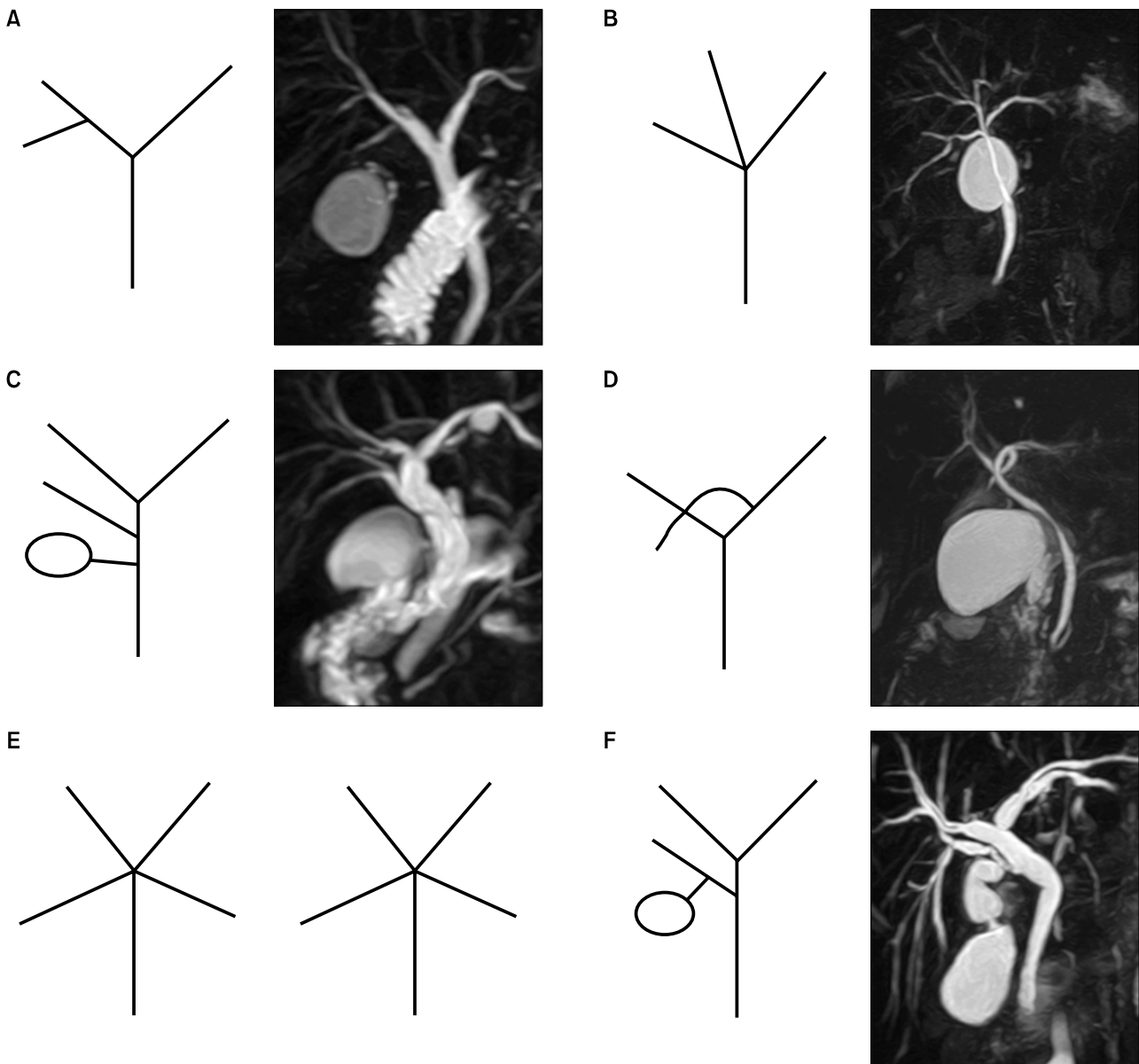


Fig. 1. Schematic Couinaud classification and findings of MRCP.

ies of patients were summarized in Table 1. Mean age of the patients was 54.6 ± 15.6 years (range: 16-89) and the male-to-female ratio was 1 : 1.18. In regard to the types of anatomical variants of the bile duct, there were types A (70.4%), B (8.7%), C (19.5%), D (0.7%) and F (0.7%). Type E was not found in the current study.

On an intraoperative basis, a conversion to laparotomy was performed in 14 cases (5.1%). Of these, 4 cases (1.4%) underwent a conversion laparotomy due to injury to the bile duct. In other cases, a conversion to laparotomy was determined based on the judgment of operators due to the presence of severe inflammation, uncontrolled bleeding,

and unexpected malignancy, etc.

The postoperative complications were defined as cases in which the medical or surgical treatments were required because of the unexpected situations that occurred while patients achieved a recovery. These complications, including injury to the bile duct, occurred in 18 cases (6.5%). There were no mortality cases as a result of surgery. In our series, the mean overall operation time was 118 ± 52.18 minutes (range: 35-365) and a mean length of postoperative hospital stay was 4.54 ± 2.65 days (range: 1-21). For cases in which there was no conversion to laparotomy, the mean operation time was 111 ± 42 minutes

(range: 35-315). In cases of no complications, a mean length of postoperative hospital stay was 4.03 ± 1.67 days (range: 1-12).

Based on the types of the bile duct anatomy on MRCP scans, patients were classified into 2 groups: a high-risk group of patients for injury to the bile duct during laparoscopic cholecystectomy (n=56) and a low-risk group of patients (n=221).

A comparison of the preoperative and postoperative outcomes was made between the 2 groups, whose results are represented in Table 2. There was no difference according to sex, age, the degree of conversion to laparotomy, the preoperative presence of the stone in the bile

duct, the presence of acute cholecystitis, operators, operation time, and a length of hospital stay between the 2 groups. In a high risk group of patients, however, injury to the bile duct occurred at a higher incidence, which was statistically significant. Following an analysis of risks for injury to the bile duct, the odds ratio (OR) was 11.9 and the confidence interval was 1.2-116.5. These results indicate an increase in risks for injury to the bile duct in the group where there was a branching of the extrahepatic bile duct on MRCP.

As mentioned earlier, there were 4 cases of injury to the bile duct during surgery. The injury to the bile duct was recognized intraoperatively in all patients. As the types of injury to the bile duct, there was one case of a partial perforation to the common bile duct and 3 cases in which the aberrant branches of the bile duct were confused with cystic duct or blood vessels and then dissected. In these cases, the types of bile duct included type A (1 case), type C (2 cases) and type F (1 case). In patients with injury to the common bile duct, the treatment was done with the insertion of T-tube and the primary closure for the sites of injury. In 2 cases of type C injury to the bile duct, the treatment was done with the insertion of stent and an end-to-end anastomosis at the sites of dissection. In cases of type F injury to the bile duct, the treatment was done with a hepaticojejunal Roux-en Y anastomosis. In one case of type C injury to the bile duct, there was an episode of re-admission due to cholangitis. In our clinical series of patients, there were no serious problems associated with surgery during a mean follow-up period of 12.2 months (range: 9-20) (Table 3).

Table 1. Clinical characteristics of patients that underwent laparoscopic cholecystectomy

	Number (%)
Sex	
Male/Female	127/150 (45.8/54.2)
Age (mean \pm SD, years)	54.6 \pm 15.6 (range: 16-89)
Duct anatomy type	
A/B/C/D/E/F	195/24/54/2/0/2 (70.4/8.7/19.5/0.7/0/0.7)
Open conversion	14/263 (5.1/94.9)
Bile duct injury	
+/-	4/273 (1.4/98.6)
CBD stone	
+/-	45/232 (16.2/83.8)
Biopsy result	
Acute cholecystitis	124 (44.8)
Symptomatic GB stone	153 (55.2)
Operation time (min)	118 \pm 52.18 (range: 35-365)
Hospital stay (days)	4.5 \pm 2.7 (range: 1-21)
Complication	
Present/absent	18/259 (6.5/93.5)

Table 2. Perioperative overall outcomes of laparoscopic cholecystectomy between the low- and high-risk groups

	Low-risk group (Types A, B, D and E)	High-risk group (Types C and F)	p-value
Total (person)	221	56	
Age	54.4 \pm 15.8	55.6 \pm 14.9	0.834*
Sex (Male/Female)	102/117 (46.6%/53.4%)	25/33 (43.1%/56.9%)	0.637 [†]
Bile duct injury	1 (0.46%)	3 (5.17%)	0.03 [‡]
Open conversion	10 (4.6%)	4 (6.9%)	0.471 [†]
Complication	13 (5.9%)	5 (8.6%)	0.461 [†]
CBD stone	35 (16.0%)	10 (17.2%)	0.817 [†]
Acute cholecystitis	102 (46.6%)	22 (37.9%)	0.239 [†]
Operator (2 person)	131/88	31/27	0.381 [†]
Operation time (min)	116.9 \pm 49.2	122.6 \pm 62.6	0.136*
Hospital stay (day)	4.6 \pm 2.7	4.2 \pm 2.3	0.325*

*Independent T-test, [†]Pearson's Chi-square test, [‡]Fisher's exact test

Table 3. The case of bile duct injuries associated with laparoscopic cholecystectomy

Age/ Sex	Type of duct	Injury factor	Recognition time of injury	Treatment	Op. time (min)	Hospital stay (day)	Long term result
65/F	C	Anomaly	Intraop	End-to-end anastomosis with stent	235	14	Good (22mo)
78/F	A	Severe inflammation	Intraop	End-to-end anastomosis with T-tube	209	14	Good (12mo)
38/F	C	Anomaly	Intraop	End-to-end anastomosis with stent	365	10	Recurrent cholangitis (17mo)
49/F	F	Anomaly	Intraop	Rt. Posterior hepaticojejunostomy	360	10	Good (8mo)

DISCUSSION

The incidence in variations of confluence in the bile duct in the hepatic hilum has been reported in 30-45%,^{10,11} these variations should be treated cautiously in the dissection and reconstruction of bile duct during hepatectomy.⁹ In particular, with the recent activation of LDLT, it has become essential to recognize variations of the sites of confluence of bile duct.

If variations of the bile duct would not be confirmed or would be overlooked prior to surgery, this would lead to the occurrence of bile duct complications in both recipients and donors. Variations of the bile duct would be essential for the screening of donors and the selection of methods of hepatectomy.^{12,13} Therefore, it has become very important to understand variations of biliary structure in the surgical management of LDLT. As a preoperative work-up for LDLT based on MRCP scans, the identification of variations of the bile duct and their clinical significance have been actively examined.^{12,14}

However, an insufficient number of studies have been conducted to examine whether variations in the confluence of bile duct on MRCP scans affect the outcomes and the course of laparoscopic cholecystectomy and whether this would increase risks for injury to the bile duct. In general, as factors that affect injury to the bile duct during laparoscopic cholecystectomy, there is the experience of the operator, the local status including inflammations at the surgical sites, the anatomical variation of the structure and the injury caused by laparoscopic instruments.¹⁵⁻¹⁷ With experienced operators, the incidence of injury to the bile duct has been reported to be less than 1%.^{18,19} Besides, it has also been reported that the anatom-

ical variation of bile duct, as well as the technical expertise of operators would be an essential factor for the occurrence of injury to the bile duct.^{19,20}

Given this background, we attempted to examine the correlations between the frequency and types of the aberrant branching of bile duct and injury to the bile duct during laparoscopic cholecystectomy. In regard to the classification of the variations of bile duct confluence, we have speculated that the Couinaud classification rather than Huang et al.²¹ or Ohkubo et al.²² classification were considered from the aspect of LDLT would be more rational during cholecystectomy. According to the Couinaud classification system, there were types A (57%), C (20%), B (12%), D (6%), E (3%) and F (2%) in decreasing order of the frequency.^{8,9} In the current study, on a similar level of these frequencies, there were types A (70.4%), C (19.5%), B (8.7%), D (0.7%) and F (0.7%) in a decreasing order of frequency. In the current study, however, the classification was made based on the interpretation of MRCP findings rather than an analysis of the actual anatomical structure. In particular, because it is not easy to make a differentiation between the Types C and D from a radiological perspective, it is probable that there might be errors. This might be one of the limitations of the current study.

Based on preoperative MRCP findings, in the group where the pathway of bile duct was abnormal, in particular in case of an extrahepatic branching, the aberrant bile duct was confused with the cystic duct and the cystic artery. From an anatomical perspective, there is a close proximity to the cystic duct. Therefore, it be expected that the degree of risks for injury to bile duct during laparoscopic cholecystectomy would be relatively higher unless

special attention is paid. Types C and F based on the Couinaud classification system have been classified as risk groups. Although there is no consensus regarding the classification into these risk groups between the authors, there are reports that the degree of surgical procedure may vary depending on the pattern of the confluence of cystic duct with the common bile duct during laparoscopic cholecystectomy.²³ Furthermore, it has also been reported that the degree of injury risk to the bile duct during laparoscopic cholecystectomy was increased by 3.2-8.4 times when there was an aberrant extrahepatic pathway of bile duct.^{24,25}

As shown in the current results, of the possible factors that might affect injury to the bile duct, there were no statistical differences in the operators, the severity of local inflammation and the factors associated with patients between the 2 groups. It was therefore shown that variations in the branching of the bile duct were the key risk factors for injury to the bile duct. In addition, in cases of injury to the bile duct, it would also be mandatory to take appropriate treatment. In association with this, it has been reported that a prognosis would vary depending on the intraoperative identification and the surgical treatment methods.²⁶⁻²⁸

In our clinical series of patients, there were 4 cases of injury to the bile duct. Because these cases were identified intraoperatively, appropriate treatment was performed following the conversion to laparotomy. Fortunately, there were no long-term complications. Because of a smaller size in the reconstruction of injury to the branches of bile duct rather than the common bile duct, there were disadvantages in the difficulty of surgical technique and the operation time. From this perspective, the degree of risks for injury to the bile duct was increased in the high risk groups. In addition, there were also disadvantages in the prevention of complications following the onset of injury to the bile duct.

To summarize, the anatomical abnormalities of the bile duct confluence during laparoscopic cholecystectomy should be treated as important from a clinical perspective. Besides, the proportion of types that did not correspond to the traditional type (type A) of the branching of the bile duct was approximate to 30%. In specific types (types C and F), the degree of risks for injury to the bile duct was very high. It can therefore be inferred that special attention should be paid for the prevention of injury to the bile duct

during laparoscopic cholecystectomy in cases in which any abnormalities of the pathway of bile duct are suspected on a preoperative work-up.

There were some limitations of this study, actually MRCP was not applied for identification for bile duct anatomy like LDLT donor, but for suspicion of common bile duct stone, biliary pancreatitis and abnormal liver function test in gall stone disease. Generally, the high-cost of MRCP is not accepted as a routine examination for gallstone disease and its usefulness is controversial. We do not insist on routine application of MRCP for laparoscopic cholecystectomy. However, many of our patients revealed a tendency to widely indicate for MRCP, according to physician preference.

In the early period of study, we did not pay sufficient attention to classify the type of bile duct and analysis of MRCP was done in post-factum at the end period. Therefore, we could not perform an analysis of the clinical effectiveness of MRCP scans and whether the preoperative identification of the variations of bile duct would reduce risks for injury to the bile duct during operation. We suggest that large-scale prospective control study should be needed.

REFERENCES

1. Lee VS, Morgan GR, Teperman LW, et al. MR imaging as the sole preoperative imaging modality for right hepatectomy: a prospective study of living adult-to-adult liver donor candidates. *AJR Am J Roentgenol* 2001;176:1475-1482.
2. Ayuso JR, Ayuso C, Bombuy E, et al. Preoperative evaluation of biliary anatomy in adult live liver donors with volumetric mangafodipir trisodium enhanced magnetic resonance cholangiography. *Liver Transpl* 2004;10:1391-1397.
3. Basaran C, Agildere AM, Donmez FY, et al. MR cholangiopancreatography with T2-weighted prospective acquisition correction turbo spin-echo sequence of the biliary anatomy of potential living liver transplant donors. *AJR Am J Roentgenol* 2008;190:1527-1533.
4. Adamsen S, Hansen OH, Funch-Jensen P, Schulze S, Stage JG, Wara P. Bile duct injury during laparoscopic cholecystectomy: a prospective nationwide series. *J Am Coll Surg* 1997;184:571-578.
5. Archer SB, Brown DW, Smith CD, Branum GD, Hunter JG. Bile duct injury during laparoscopic cholecystectomy: results of a national survey. *Ann Surg* 2001;234:549-558.
6. Taourel P, Bret PM, Reinhold C, Barkun AN, Atri M. Anatomic variants of the biliary tree: diagnosis with MR cholangiopancreatography. *Radiology* 1996;199:521-527.
7. Kapoor V, Peterson MS, Baron RL, Patel S, Eghtesad B, Fung JJ. Intrahepatic biliary anatomy of living adult liver donors: correlation of mangafodipir trisodium-enhanced MR cholangiography and intraoperative cholangiography. *AJR Am J Roentgenol* 2002;179:1281-1286.

8. Couinaud C. Le foi. Etudes anatomiques et chirurgicales. 1957.
9. Blumgart LH. Surgery of the Liver, Biliary Tract and Pancreas, 4th ed. 2-Volume Set with CD-ROM. 2007.
10. Puente SG, Bannura GC. Radiological anatomy of the biliary tract: variations and congenital abnormalities. *World J Surg* 1983;7:271-276.
11. Russell E, Yrizzary JM, Montalvo BM, Guerra JJ Jr, al-Refai F. Left hepatic duct anatomy: implications. *Radiology* 1990;174:353-356.
12. Karakas HM, Celik T, Alicioglu B. Bile duct anatomy of the Anatolian Caucasian population: Huang classification revisited. *Surg Radiol Anat* 2008;30:539-545.
13. Ran S, Wen TF, Yan LN, et al. Risks faced by donors of right lobe for living donor liver transplantation. *Hepatobiliary Pancreat Dis Int* 2009;8:581-585.
14. An SK, Lee JM, Suh KS, et al. Gadobenate dimeglumine-enhanced liver MRI as the sole preoperative imaging technique: a prospective study of living liver donors. *AJR Am J Roentgenol* 2006;187:1223-1233.
15. The Southern Surgeons Club. A prospective analysis of 1518 laparoscopic cholecystectomies. *N Engl J Med* 1991;324:1073-1078.
16. Walker AT, Brooks DC, Tumei SS, Braver JM. Bile duct disruption after laparoscopic cholecystectomy. *Semin Ultrasound CT MR* 1993;14:346-355.
17. Way LW, Stewart L, Gantert W, et al. Causes and prevention of laparoscopic bile duct injuries: analysis of 252 cases from a human factors and cognitive psychology perspective. *Ann Surg* 2003;237:460-469.
18. Andrén-Sandberg A, Johansson S, Bengmark S. Accidental lesions of the common bile duct at cholecystectomy. II. Results of treatment. *Ann Surg* 1985;201:452-455.
19. MacFadyen BV Jr, Vecchio R, Ricardo AE, Mathis CR. Bile duct injury after laparoscopic cholecystectomy. The United States experience. *Surg Endosc* 1998;12:315-321.
20. Hugh TB. New strategies to prevent laparoscopic bile duct injury—surgeons can learn from pilots. *Surgery* 2002;132:826-835.
21. Huang TL, Cheng YF, Chen CL, Chen TY, Lee TY. Variants of the bile ducts: clinical application in the potential donor of living-related hepatic transplantation. *Transplant Proc* 1996;28:1669-1670.
22. Ohkubo M, Nagino M, Kamiya J, et al. Surgical anatomy of the bile ducts at the hepatic hilum as applied to living donor liver transplantation. *Ann Surg* 2004;239:82-86.
23. Uchiyama K, Tani M, Kawai M, Ueno M, Hama T, Yamaue H. Preoperative evaluation of the extrahepatic bile duct structure for laparoscopic cholecystectomy. *Surg Endosc* 2006;20:1119-1123.
24. Seibert D, Matulis SR, Griswold F. A rare right hepatic duct anatomical variant discovered after laparoscopic bile duct transection. *Surg Laparosc Endosc* 1996;6:61-64.
25. Suhocki PV, Meyers WC. Injury to aberrant bile ducts during cholecystectomy: a common cause of diagnostic error and treatment delay. *AJR Am J Roentgenol* 1999;172:955-959.
26. Kwon SW, Yoon DS, Chi HS. Bile duct injury during laparoscopic cholecystectomy. *Korean J Hepatobiliary Pancreat Surg* 1998;2:111-116.
27. Lillemoe KD, Melton GB, Cameron JL, et al. Postoperative bile duct strictures: management and outcome in the 1990s. *Ann Surg* 2000;232:430-441.
28. Lee HJ, Hwang S, Lee SG, Song GW, Lee YJ, Kim KH. Treatments of proximal bile duct necrosis and stricture from iatrogenic bile duct injury of laparoscopic cholecystectomy. *Korean J Hepatobiliary Pancreat Surg* 2005;9:156-163.