



# Local Metastatic Neck Cancer Involving the Distal Internal Carotid Artery Treated with En Bloc Resection and Arterial Reconstruction after Mandibular Osteotomy

Nikolaos Kontopodis<sup>1</sup>, Dimosthenis Igoumenakis<sup>2</sup>, George Mastorakis<sup>2</sup>, Ioannis Logothetis<sup>2</sup>, Nikolaos Daskalakis<sup>1</sup>, and Christos V. Ioannou<sup>1</sup>

<sup>1</sup>Vascular Surgery Unit, Department of Vascular and Cardiothoracic Surgery, University of Crete Medical School, Heraklion,

<sup>2</sup>Department of Oral and Maxillofacial Surgery, Venizeleio General Hospital, Heraklion, Greece

Head and neck cancers represent an aggressive form of neoplastic diseases that warrant surgical resection, in order to achieve optimal outcomes. Moreover, the involvement of the carotid artery is associated with a dismal prognosis and radical tumor resection becomes challenging. The current case report presents a patient with locally metastatic neck carcinoma attached to the right carotid bifurcation, involving both the external and internal carotid arteries up to the distal segment of the internal carotid artery (ICA) at the level of the C1 vertebra. The patient underwent en bloc tumor and vessel resection. The carotid artery was reconstructed using an interposition graft from the common carotid artery to the ICA by means of an autologous saphenous vein graft. A vertical mandibular osteotomy was performed, in order to expose the distal ICA. The postoperative recovery was uneventful. The patient was under follow-up for six months, without any signs of recurrence.

**Key Words:** Head and neck neoplasms, Internal carotid artery, Mandibular osteotomy

Received July 13, 2020

Revised October 2, 2020

Accepted October 9, 2020

Published online November 12, 2020

**Corresponding author:** Nikolaos Kontopodis  
Vascular Surgery Unit, Department of Cardiothoracic and Vascular Surgery, University Hospital of Heraklion, University of Crete Medical School, PO-Box 1352, 711 10, Heraklion, Greece  
Tel: 30-2810-392-393  
Fax: 30-2810-375-365  
E-mail: kontopodisn@yahoo.gr  
<https://orcid.org/0000-0002-6792-5003>

Copyright © 2020 The Korean Society for Vascular Surgery

This is an Open Access article distributed under the terms of the Creative Commons Attribution Non-Commercial License (<http://creativecommons.org/licenses/by-nc/4.0>) which permits unrestricted non-commercial use, distribution, and reproduction in any medium, provided the original work is properly cited.

Vasc Specialist Int 2020;36(4):252-257 • <https://doi.org/10.5758/vsi.200046>

## INTRODUCTION

Generally, head and neck carcinomas have an aggressive natural history and the involvement of the carotid artery is considered to be associated with a dismal prognosis [1,2]. Literature has shown that surgical management is the treatment modality that can achieve optimal outcomes pertaining to the survival in the aforementioned group of patients, compared to the conservative or palliative treatments [3]. Carotid involvement represents a surgical challenge, on account of the fact that the scenario frequently warrants reconstruction after en bloc tumor and vessel resection.

Furthermore, the surgical management of recurrent or local metastatic carcinoma is more challenging, owing to the presence of scar tissue, while the need to approach the distal internal carotid artery (ICA) adds complexity to an extremely demanding surgical intervention [4]. Nevertheless, the fact that en bloc resection and arterial reconstruction represent the most radical and effective treatment option pertaining to the management of carcinoma patients with carotid involvement remains unchanged. The aforementioned treatment option prevents the local progression of the disease and results in longer survival periods, regardless of the challenges presented by the same. The aforesaid

rationale is in accordance with the recently introduced concept of oncovascular surgery, which proposes that the vascular surgeons play an essential and leading role in the management of cancer patients with vascular invasion [5].

The current case report presents a 35-year-old male patient with locally metastatic neck carcinoma that involved the carotid bifurcation and the ICA up to the level of the C1 vertebra. The patient underwent en bloc tumor and vessel resection and ICA reconstruction with an interposition graft from the common carotid artery (CCA). The saphenous vein was used as a conduit and a vertical mandibular osteotomy was performed to facilitate the access to the distal ICA at the base of the skull. The Institutional Review Board of the University of Crete Medical School, Greece has given approval for the report of this case (No. 346662011).

## CASE

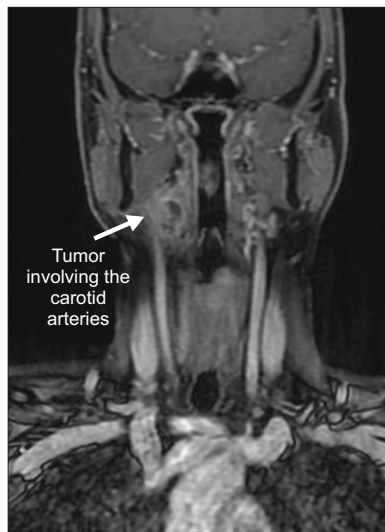
A 35-year-old male patient was diagnosed with a local metastatic neck carcinoma during regular follow-up after the resection of a T1N0M0 (stage I) squamous cell carcinoma of the right lateral border of the tongue. The primary surgical procedure was performed in the Oral and Maxillofacial Surgery department of our institution, 12 months prior to the detection of the metastatic carcinoma.

The initial surgical procedure comprised a transoral resection of the carcinoma and an extended supraomohyoid neck dissection. The surgical defect was covered by means of mucosal suturing and healed by primary intention. Histopathological examination revealed a tongue specimen with clear resection margins and a neck specimen with 40

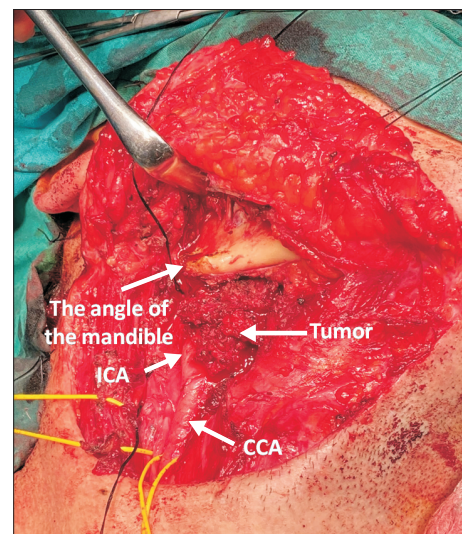
lymph nodes that were negative for metastatic infiltration. However, on account of depth of invasion of 10 mm and perineural infiltrations, the patient received postoperative adjuvant radiotherapy of 63 cGys.

One year after the primary surgical procedure, a metastatic neck mass of dimensions 22×20×15 mm was detected on a routine follow-up magnetic resonance imaging (MRI). The lesion involved the carotid bifurcation and the radiographic images gave the impression that the ICA was affected up to its distal part at the level of the C1 vertebra. However, the extension of the lesion could not be ascertained from the MRI images, owing to the lack of clarity (Fig. 1). In addition, computed tomography (CT) angiography was performed, which did not clarify the level of ICA involvement. Further radiographic investigation using a positron emission tomography scan revealed negative results pertaining to other metastatic foci.

The patient underwent neck exploration, which was performed by a multidisciplinary surgical team involving oral and maxillofacial and vascular surgeons. The lesion was approached through the previous incision. The CCA, external carotid artery (ECA), and ICA were encircled. During the surgical procedure, it became evident that the ICA was involved up to its distal part. The division of the posterior belly of the digastric muscle did not provide sufficient access to the uninvolved part of the ICA, distal to the neoplastic tissue (Fig. 2). The retrojugular approach to the ICA has been suggested to offer easier dissection, especially in



**Fig. 1.** Magnetic resonance imaging of the neck showing the neoplastic mass around the right carotid vessels.



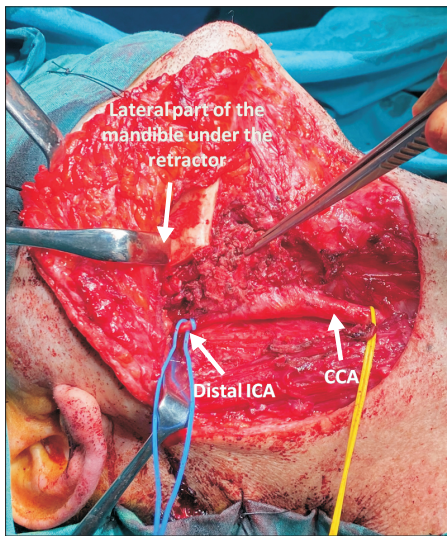
**Fig. 2.** Intraoperative photograph showing the neoplastic mass involving the carotid arteries. The mandible can be observed, which evidently shows that the involvement of ICA extended up to its distal segment. Total length of ICA involvement was approximately 5 cm. ICA, internal carotid artery; CCA, common carotid artery.

cases that warrant greater exposure. However, the aforementioned approach did not give the impression of being adequate in our case, which warranted control of the ICA up to the level of the C1 vertebra. Consequently, a vertical ramus mandibulotomy followed by anterior and cephalad retraction of the distal mandibular part facilitated access to the ICA at the level of the C1 vertebra. Prior to the osteotomy, preplating was performed using three miniplates. The osteotomy was placed posterior to the lateral mandibular foramen, in order to preserve the inferior alveolar nerve (Fig. 3). In the current patient, all the internal jugular veins were ligated, on account of the adherence to the tumor mass. Regarding the manipulation of cranial nerves, the hypoglossal, vagus, and accessory spinal nerves were identified during the surgical procedure. Unfortunately, the hypoglossal nerve could not be preserved and was sacrificed, in order to achieve complete excision of the tumor, whereas the vagus and accessory spinal nerves were recognized and

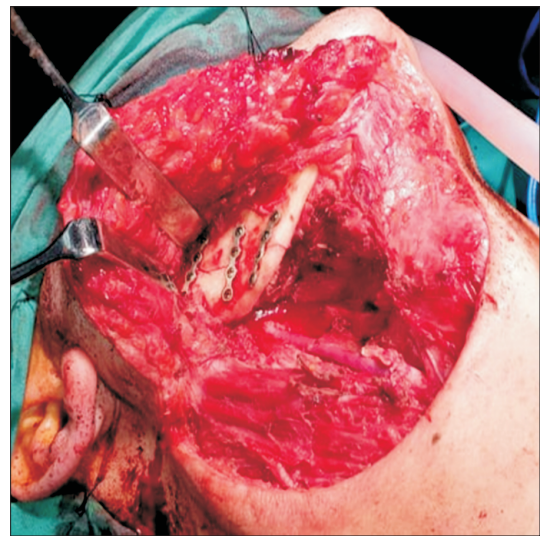
protected.

Clamping of the ICA did not have any significant effect on the cerebral oximetry, owing to normal collateralization through the circle of Willis. Consequently, it was decided that a shunt was not required. The ECA was ligated and an interposition graft was placed from the CCA to the distal ICA in a standard fashion, using a segment of the great saphenous vein (GSV) as a conduit. Prior to the tumor resection, revascularization was performed to ensure quick cerebral reperfusion, which provided sufficient time for the complete dissection and resection of the tumor. Subsequently, en bloc excision of the tumor with the ICA and ECA was performed (Fig. 4). The mandible was reconstructed by way of the fixation of the three miniplates in the corresponding preplating positions (Fig. 5).

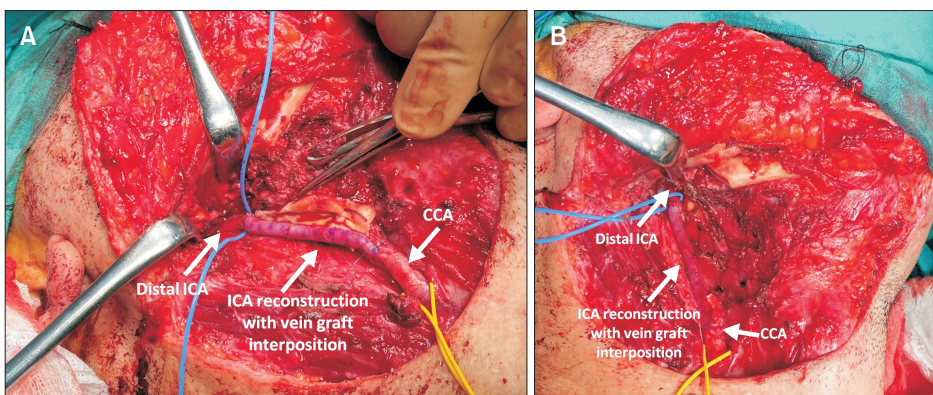
The patient had an uneventful recovery with normal neurological functions and was discharged on the fifth postoperative day. Postoperatively, the patient underwent adjuvant radiotherapy. No signs of recurrence were ob-



**Fig. 3.** Distal exposure of the ICA after mandibular osteotomy. ICA, internal carotid artery; CCA, common carotid artery.

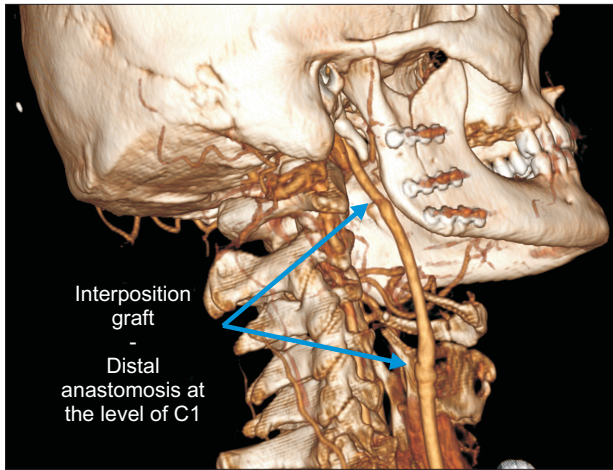


**Fig. 5.** Reconstruction of the mandible after tumor resection.



**Fig. 4.** (A) The interposition graft from the CCA to the ICA using a segment of the great saphenous vein as the conduit. (B) En bloc resection of the tumor and the vessels involved. ICA, internal carotid artery; CCA, common carotid artery.





**Fig. 6.** Three-dimensional reconstruction of the computed tomography angiography obtained six months after the surgical procedure. The patent graft with distal anastomosis at the level of the C1 vertebra is shown.

served during the course of the six-month follow-up. A follow-up CT angiography showed sufficient tumor excision and adequate graft patency (Fig. 6).

## DISCUSSION

The current case report describes a patient with local metastatic carcinoma that involved the carotid bifurcation up to the distal ICA at the level of the C1 vertebra, who underwent en bloc resection and successful reconstruction using a saphenous vein interposition graft, subsequent to a vertical mandibular osteotomy. An aggressive surgical approach in the management of patients with vascular involvement remains debatable, on account of the overall poor prognosis and the questionable survival benefit. Nonetheless, previous literature shows that radical surgical management is associated with increased survival rates, compared to the conservative or palliative modes of therapy, and studies have reported encouraging survival rates pertaining to this strategy [1-4]. In addition to the aspects pertaining to mortality, the aforementioned approach might allow the patients to avoid local complications, such as discomfort from a visible growing mass on the neck, respiratory distress, dysphagia, pain, and anxiety, and offers a better quality of life [4]. Regarding the optimal conduit that can be used to perform revascularization, the debate pertaining to the use of autologous vein grafts (mainly the great saphenous vein) and synthetic materials, such as polytetrafluoroethylene grafts, has not reached a definitive conclusion. Vein grafts are considered to be more resistant to infections, which is a possible scenario in the patients

with scarred or previously irradiated surgical field or tumors that may require the intraoperative manipulation of the trachea or esophagus. Conversely, there are concerns that the vein grafts may be more susceptible to stenosis in the event of subsequent radiotherapy [2,4]. The authors opted for a venous conduit, on account of the aforementioned arguments, along with the fact that in the present case, the size of the GSV was similar to that of the distal ICA and, in consequence, there was no mismatch, at least at the site of the distal anastomosis. However, the authors acknowledge the fact that a synthetic graft would be appropriate as well.

Other surgical options, such as arterial wall peeling, have been used in the past to achieve radical tumor resection. The implementation of the aforementioned surgical options necessitate the adoption of a hypothesis that the arterial wall is resistant to neoplastic cell infiltration. However, recent literature suggests that the arterial wall is invaded in at least half of the cases [4,6]. Consequently, local recurrence rates pertaining to this technique should be expected to be significantly higher, compared to the en bloc resection, as reported in recent literature [3,4,7]. In addition to the fact that peeling does not represent a curative or complete oncological procedure, the approach involves removal of the adventitia, which may result in the loss of arterial wall integrity and strength with a subsequent risk of arterial rupture. Indeed, fatal arterial bleeding from carotid artery rupture has been reported in a significant minority of the patients who underwent arterial wall peeling [3,7].

Another surgical option that has been used for the management of patients with vascular involvement is the carotid artery resection without reconstruction. However, the aforementioned therapeutic modality results in an unacceptable rate of neurological morbidity. Elective ligation of the ICA has resulted in neurologic complication rates of more than 50% in some case series studies, while other studies have reported complication rates of approximately 30% [8,9]. Taking everything into account, the aforesaid results compare unfavorably with the stroke rate of 0%-5% that was reported in the patients who underwent reconstruction of the ICA [4,10]. Techniques to assess collateral circulation and determine the need for reconstruction, as opposed to simple ligation (i.e., temporary occlusion balloon), are not usually reliable, in view of the fact that stroke can occur within the first to the fifth postoperative day, owing to the thrombus propagation from the distal stump of the ICA [11,12].

An important technical aspect pertaining to the present case report is the vertical mandibular osteotomy that was employed, in order to approach the distal carotid artery at the level of the C1 vertebra. The aforementioned or similar distal exposures cannot be achieved using the standard ap-



proach or by means of simple additional maneuvers, such as the division of the posterior belly of the digastric muscle. Previous literature has reported the use of mandibular subluxation for this purpose and the authors were able to identify at least two patients who underwent the surgical management of neck cancer that involved the aforementioned manipulation of the mandible [4]. Nevertheless, anterior subluxation must occur with the nasotracheal intubation and should be anticipated, planned, and performed before the carotid exposure [13]. Conversely, vertical mandibular osteotomy offers the advantage that it is not necessary to be performed in advance. Consequently, the technique allows the operators to evaluate the need for this manipulation, intraoperatively. For instance, in the present case, pre-operative imaging was insufficient to determine the extent of distal exposure. Moreover, mandibular osteotomy allows for more distal exposure of ICA, compared to the anterior subluxation, and grants control of the ICA up to the base of the skull.

Despite the abovementioned advantages, the technique of mandibular osteotomy is not devoid of complications. The frequently encountered complications include wound dehiscence, inferior alveolar nerve injury, dental injury, and plate exposure or mobility. Nevertheless, all the aforementioned complications are of low severity and can be managed through either conservative treatment or minor surgical interventions under local anesthesia [14]. Furthermore, complications are frequently associated with the osteotomies located in the dentate areas of the mandible involving the oral mucosa. Conversely, in the present case, a vertical ramus mandibulotomy was employed, which is designed to preserve the inferior alveolar nerve, located in an edentulous area, and the osteotomy and osteosynthesis plates are covered by the masseter muscle. Consequently, the risk of complications is much lower. Indeed, the patient did not

present any postoperative complications with regard to the mandibulotomy.

In conclusion, en bloc tumor and vessel resection can be performed safely during the treatment of locally metastatic neck cancer involving the carotid artery. Vertical mandibular osteotomy is a manageable maneuver, which allows access to the distal ICA and the arterial reconstruction can be performed safely in cases with high vascular involvement.

## CONFLICTS OF INTEREST

The authors have nothing to disclose.

## ORCID

Nikolaos Kontopodis

<https://orcid.org/0000-0002-6792-5003>

Dimosthenis Igoumenakis

<https://orcid.org/0000-0002-4366-0960>

George Mastorakis

<https://orcid.org/0000-0002-0669-7537>

Ioannis Logothetis

<https://orcid.org/0000-0001-5194-3752>

Nikolaos Daskalakis

<https://orcid.org/0000-0001-5385-4294>

Christos V. Ioannou

<https://orcid.org/0000-0002-9929-6184>

## AUTHOR CONTRIBUTIONS

Concept and design: NK, DI, CVI. Analysis and interpretation: GM, IL, ND. Data collection: NK, DI. Writing the article: NK, DI, CVI. Critical revision of the article: GM, IL, ND. Final approval of the article: all authors. Obtained funding: none. Overall responsibility: CVI.

## REFERENCES

- 1) Manzoor NF, Russell JO, Bricker A, Koyfman S, Scharpf J, Burkey B, et al. Impact of surgical resection on survival in patients with advanced head and neck cancer involving the carotid artery. *JAMA Otolaryngol Head Neck Surg* 2013;139:1219-1225.
- 2) Ozer E, Agrawal A, Ozer HG, Schuller DE. The impact of surgery in the management of the head and neck carcinoma involving the carotid artery. *Laryngoscope* 2008;118:1771-1774.
- 3) Roh JL, Kim MR, Choi SH, Lee JH, Cho KJ, Nam SY, et al. Can patients with head and neck cancers invading carotid artery gain survival benefit from surgery? *Acta Otolaryngol* 2008;128:1370-1374.
- 4) Illuminati G, Schneider F, Minni A, Calio FG, Pizzardi G, Ricco JB. Resection of recurrent neck cancer with carotid artery replacement. *J Vasc Surg* 2016;63:1272-1278.
- 5) Han A, Ahn S, Min SK. Oncovascular surgery: essential roles of vascular surgeons in cancer surgery. *Vasc Specialist Int* 2019;35:60-69.
- 6) Nishinari K, Krutman M, Valentim LA, Chulam TC, Yazbek G, Kowalski LP, et al. Late surgical outcomes of carotid resection and saphenous vein graft revascularization in patients with advanced head and neck squa-

- mous cell carcinoma. *Ann Vasc Surg* 2014;28:1878-1884.
- 7) Zhengang X, Colbert S, Brennan PA, Xue B, Yongfa Q, Pingzhang T, et al. Surgical management of metastases that involve the carotid artery in cases of primary squamous cell carcinoma of the head and neck. *Int J Oral Maxillofac Surg* 2013;42:440-445.
- 8) Meleca RJ, Marks SC. Carotid artery resection for cancer of the head and neck. *Arch Otolaryngol Head Neck Surg* 1994;120:974-978.
- 9) Brennan JA, Jafek BW. Elective carotid artery resection for advanced squamous cell carcinoma of the neck. *Laryngoscope* 1994;104(3 Pt 1):259-263.
- 10) Katsuno S, Takemae T, Ishiyama T, Usami SI. Is carotid reconstruction for advanced cancer in the neck a safe procedure? *Otolaryngol Head Neck Surg* 2001;124:222-224.
- 11) Wright JG, Nicholson R, Schuller DE, Smead WL. Resection of the internal carotid artery and replacement with greater saphenous vein: a safe procedure for en bloc cancer resections with carotid involvement. *J Vasc Surg* 1996;23:775-780; discussion 781-782.
- 12) Kroecker TR, O'Brien JC. Carotid resection and reconstruction associated with treatment of head and neck cancer. *Proc (Bayl Univ Med Cent)* 2011;24:295-298.
- 13) Simonian GT, Pappas PJ, Padberg FT Jr, Samit A, Silva MB Jr, Jamil Z, et al. Mandibular subluxation for distal internal carotid exposure: technical considerations. *J Vasc Surg* 1999;30:1116-1120.
- 14) Nabil S, Nazimi AJ, Nordin R, Hariri F, Mohamad Yunus MR, Zulkiflee AB. Mandibulotomy: an analysis of its morbidities. *Int J Oral Maxillofac Surg* 2018;47:1511-1518.