

➤ **Original Article** ◀

Mid-Term Report on the Safety and Effectiveness of Endovenous Radiofrequency Ablation for Varicose Veins

Kiyoshi Tamura, MD, PhD and Toshiyuki Maruyama, MD

Objective: Endovenous radiofrequency ablation (RFA), a relatively new technique for treating great saphenous varicose veins, is less invasive compared with stripping surgery. This study examined the mid-term safety and effectiveness of RFA for varicose veins.

Materials and Methods: We enrolled 104 patients (147 limbs) who underwent RFA for varicose veins of the lower extremities (females, 67; 64.4%). The mean age was 68.9 ± 9.2 years (39–85 years). In 121 limbs (82.3%), there were great saphenous veins. All patients were observed as outpatients for 12 months after the procedure. RFA was performed using ClosureFast™ catheters with tumescent local anesthesia.

Results: There was 99.4% occlusion of the treated veins, and partial recanalization was observed in one limb. Endovenous heat-induced thrombosis (EHIT) was identified in five limbs (3.4%). All EHITs were class 1 according to the Kabnick classification, and they disappeared within 1 month of the intervention without antithrombotic therapy. No other major complications were observed. Mean venous clinical severity scores improved from 5.31 at the baseline to 1.10, 0.39, 0.14, and 0.06 at 1, 3, 6, and 12 months, respectively.

Conclusion: RFA is a safe and effective strategy for varicose veins of the lower extremities.

Keywords: varicose vein, radiofrequency ablation, venous clinical severity score

Introduction

Varicose veins (VV) of the lower extremities affect approximately 26% of adults and are a frequent cause of discomfort, loss of productivity, and deterioration in health-related quality of life.¹⁾ The initial treatment for

VV is elastic compression stockings. Anti-platelet and/or anticoagulation drugs are helpful for patients with some symptoms and sclerosing injections are also effective. Standard surgical treatments include stripping of saphenous various veins and high ligation of the saphenofemoral junction.

Endovenous radiofrequency ablation (RFA) is a relatively new, minimally invasive technique that is common in Japan. Although RFA is associated with fewer postoperative complications, there is little evidence to suggest an overall advantage for any particular treatment procedure. The aim of this study was to investigate the mid-term results of RFA for VV.

Materials and Methods

This retrospective study was approved by the ethics committee, and written informed consent was obtained from all patients.

A total of 124 patients underwent surgical interventions for VV in our institution between January 2015 and August 2016. All patients returned as outpatients for 12 months of follow-up. Patients with a preoperative vein diameter of < 10 mm at the saphenofemoral junction were selected for RFA. For patients with diameters of > 10 mm, the intervention was stripping of the great saphenous vein. Patients treated with stripping were excluded from this study. Therefore, 147 limbs in 104 patients were enrolled in this study.

All patients with VV of the lower extremities underwent ultrasonography and magnetic resonance venography (MRV) to detect deep vein thrombus (DVT). We routinely perform MRV because it detects DVT in middle femoral veins that may not be easily detected by ultrasonography.²⁾

RFA was performed using ClosureFast™ catheters. For the RFA procedure, the patient's leg was prepped with an antiseptic solution and draped in a sterile fashion. The vein was cannulated under ultrasound guidance. The RFA catheter was accessed with a 7Fr sheath, and the RFA catheter was passed to the point of the saphenofemoral junction. Radiofrequency energy was delivered at 120°C.

Department of Cardiovascular Surgery, Soka Municipal Hospital, Soka, Saitama, Japan

Received: May 31, 2017; Accepted: August 7, 2017
Corresponding author: Kiyoshi Tamura, MD, PhD. Department of Cardiovascular Surgery, Soka Municipal Hospital, 2-21-1 Soka, Soka, Saitama 340-8560, Japan
Tel: +81-48-946-2200, Fax: +81-48-946-2211
E-mail: tamura.cvsg@tmd.ac.jp



Table 1 Demographic characteristics of all patients before interventions

	n (%)
Age (year)	68.9±9.2 (39–85)
Sex (female)	67 (64.4%)
Varix of great saphenous vein (number of limbs)	82 (78.8%) (121, 82.3%)
Varix of short saphenous vein (number of limbs)	22 (21.2%) (26, 17.7%)
CEAP classification	
C2	56 (53.9%)
C3	38 (36.5%)
C4a	7 (6.7%)
C4b	3 (2.9%)

CEAP: Clinical-Etiology-Anatomy-Pathophysiology

Each 7-cm venous segment was treated in a 20-s cycle.

To assess endovenous heat-induced thrombosis (EHIT) and the occlusion rate of treated veins, duplex ultrasound scanning was performed 1 day; 1 week; and 1, 3, 6, and 12 months after treatment.

The following characteristics were analyzed at the time of diagnosis: demographic features, predisposing family history and past personal history, clinical features, treatments, and outcomes. Preoperative examinations included echocardiographic studies, radiologic images, and the results of routine laboratory tests, including hematological values, lipid parameters, liver and renal function, and inflammatory parameters.

The patient characteristics are shown in **Table 1**. There were 67 (64.4%) female patients. The mean age was 68.9±9.2 years (39–85 years). Great saphenous VV were present in 82 patients (78.8%) and 121 limbs (82.3%). VV were evaluated according to the Clinical-Etiology-Anatomy-Pathophysiology classification before RFA: 100 limbs (90.4%) were graded as C2 and C3.

Continuous variables are expressed as medians±SD with ranges when appropriate. Categorical variables are expressed as percentages (%), and continuous variables were compared using the Student's t-test. Parametric data were analyzed with contingency tables and Fisher's exact test, as appropriate. Differences were considered significant at $p<0.05$. Stat View for Windows version 6.0 (SAS Institute Inc., Cary, NC, USA) was used for all calculations.

Results

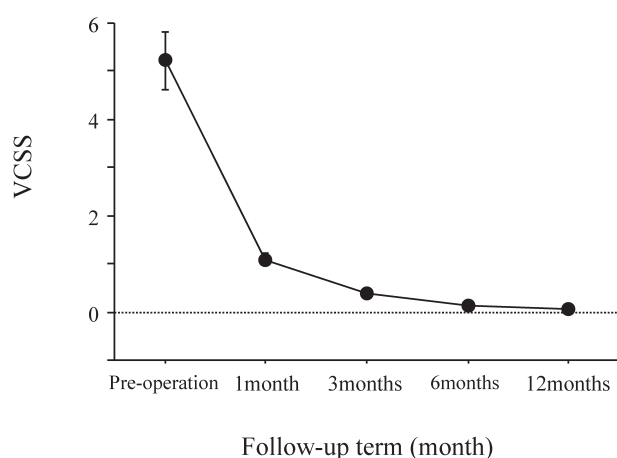
Complications after RFA are shown in **Table 2**. A partial recanalization was observed in one limb (0.6%), resulting in a 99.4% occlusion rate for treated veins. Recurrent VV were caused by residual tributaries.

EHITs were identified in five limbs (3.4%, **Table 2**).

Table 2 Complications after RFA

	n (%)
EHIT (leg)	5 (3.4%)
Recanalization of great saphenous vein (leg)	1 (0.6%)
Pain	26 (25.0%)
Numbness	10 (9.6%)
Induration	7 (6.7%)
Muscle cramping	4 (3.8%)
Edema	3 (2.9%)
Localized hot flashes	3 (2.9%)
Dullness	1 (1.0%)
Red flare	1 (1.0%)
Procedural pain	12 (11.5%)
Procedural bruising	13 (12.5%)

EHIT: endovenous heat-induced thrombosis



	Pre-operation	1month	3months	6months	12months
VCSS	5.31 ± 0.60	1.10 ± 0.13 *	0.39 ± 0.09 *	0.14 ± 0.06 *	0.06 ± 0.03 *

* $p<0.001$; VCSS: venous clinical severity score

Fig. 1 Changes in the venous clinical severity score. In comparison to preoperative scores, VCSSs during the follow-up were significantly decreased.

All EHITs were class 1 according to the Kabnick classification,³⁾ and they disappeared within 1 month after intervention without antithrombotic therapy. There were no other major complications, including DVT and nerve injury.

Minor complications after RFA included pain, numbness, induration, muscle cramping, edema, localized hot flashes, dullness, and red flare (**Table 2**). Procedural pain was observed in 12 patients (11.5%) and procedural bruising in 13 patients (12.5%). However, these complications were significantly improved at the end of the follow-up period, and venous clinical severity scores (VCSS) improved from 5.31±0.60 at the baseline to 1.10±0.13, 0.39±0.09, 0.14±0.06, and 0.06±0.03 at 1, 3, 6, and 12 months, respectively ($p<0.0001$, **Fig. 1**).

Discussion

RFA is a minimally invasive technique that serves as an alternative to conventional stripping surgery. We experienced fewer perioperative complications using the RFA procedure. Although many RFA studies have been reported in Europe and the United States,⁴⁻⁷ there are few studies on the mid-term results of this approach in Japan. We observed excellent mid-term clinical outcomes, indicating that RFA is a safe and effective procedure.

In this study, only one limb showed evidence of partial recanalization on follow-up (Table 2). This procedure led to successful vein occlusion in 99.4% of limbs. Although there are few studies on the performance of RFA on recanalization, Kayssi et al.⁸ reported an occlusion rate of 99% during the follow-up period. In contrast, there are many reports on the occlusion rate of endovenous laser ablation (EVLA).⁹⁻¹¹ Alder and Rahi reported an occlusion rate of 98% at the 14-month follow-up.¹⁰ At the 2-year follow-up, Min et al.¹¹ reported that treated portions of great saphenous veins remained closed in 113 of 121 limbs (93.4%). Additionally, Ravi et al.¹² reported that postprocedure duplex ultrasound showed 2.0% recanalization or incomplete occlusion of great saphenous veins in patients treated with EVLA and 3.7% in those treated with RFA. Thus, RFA is similar to or more effective than EVLA.

EHITs were present in 3.4% of the patients in this study (Table 2). Reported rates of EHIT post-EVLA widely vary from 0 to 16%.¹³⁻¹⁶ Marsh et al.¹⁴ reported a low incidence of EHIT post-EVLA, with no differences from RFA. Kurihara et al.¹⁷ reported that EHITs caused by RFA were mainly class 1 according to the Kabnick classification. All EHITs in our study were class 1 and disappeared without antithrombotic therapy. The reported incidence of DVT was much lower in RFA (0.29-0.7%)^{14,17} than in EVLA, and there were no patients with DVT in this study.

Minor complications of RFA include muscle cramping, localized hot flashes, induration, numbness, skin discoloration, and persistent pain.^{8,18} Similar complications were observed in our study (Table 2), and at the end of the follow-up period, VCSS had improved significantly without antithrombotic therapy (Fig. 1). No major complications, including nerve injury, were noted.

There are several reports that postprocedural complications, such as pain and bruising, are less frequent after RFA than after ELVA.^{5,7} Surgical pain was observed in approximately 30% of patients after 980-nm EVLA,¹⁹ and Jin et al.²⁰ reported that 21.6% of all the patients had RFA-associated pain. In the present study, the level of postprocedural pain was lower (11.5%, Table 2). Bruising after 1470-nm ELVA was noted in 60% of patients.²¹ On the other hand, Vasquez et al.⁴ suggested that complications, including ecchymosis, were observed after RFA in

13.1% patients. We observed postoperative bruising in 12.5% of patients (Table 2). However, Hirokawa et al.²² reported that 1470-nm EVLA had lesser incidences of postoperative pain (0% vs. 25%, respectively) and bruising (7.0% vs. 57.1%, respectively; $p < 0.0001$ for both) than 980-nm EVLA. Doganci and Demirkilic²³ also reported that 1470-nm EVLA had lesser incidences of bruising than 980-nm EVLA (6.7% vs. 43.3%, $p < 0.01$). Although the incidence of postprocedural complications with RFA might be similar to or lesser than 1470-nm ELVA, further prospective studies with a large cohort are needed.

This study had some limitations. It was a retrospective study with a relatively small number of patients from a single-center. Despite these limitations, our study showed that RFA is a clinically useful procedure.

Conclusion

RFA is a safe and effective strategy for VV of lower extremities and should be considered clinically useful.

Disclosure Statement

There is no conflict of interest for this article.

Author Contributions

Study conception: KT, TM

Data collection: KT

Analysis: KT

Investigation: KT

Writing: KT

Funding acquisition: none

Critical review and revision: all authors

Final approval of the article: all authors

Accountability for all aspects of the work: all authors

References

- 1) van Rij AM, Chai J, Hill GB, et al. Incidence of deep vein thrombosis after varicose vein surgery. *Br J Surg* 2004; **91**: 1582-5.
- 2) Tamura K and Nakahara H. MR venography for the assessment of deep vein thrombosis in lower extremities with varicose veins. *Ann Vasc Dis* 2014; **7**: 399-403.
- 3) Kabnick LS, Ombellino M, Agis H, et al. Endovenous heat-induced thrombus (EHIT) at the superficial-deep venous junction: a new post-treatment clinical entity, classification, and potential treatment strategies. 18th Annual Meeting of the American Venous Forum, Miami, Florida, 2006.
- 4) Vasquez MA, Wang J, Mahathanaruk M, et al. The utility of the venous clinical severity score in 682 limbs treated by radiofrequency saphenous vein ablation. *J Vasc Surg* 2007; **45**: 1008-15.e2; discussion, 1015.

- 5) Proebstle TM, Alm BJ, Göckeritz O, et al. Five-year results from the prospective European multicentre cohort study on radiofrequency segmental thermal ablation for incompetent great saphenous veins. *Br J Surg* 2015; **102**: 212-8.
- 6) Woźniak W, Mlosek RK, Ciostek P. Complications and failure of endovenous laser ablation and radiofrequency ablation procedures in patients with lower extremity varicose veins in a 5-year follow-up. *Vasc Endovascular Surg* 2016; **50**: 475-83.
- 7) Sydnor M, Mavropoulos J, Slobodnik N, et al. A randomized prospective long-term (>1 year) clinical trial comparing the efficacy and safety of radiofrequency ablation to 980 nm laser ablation of the great saphenous vein. *Phlebology* 2017; **32**: 415-24.
- 8) Kayssi A, Pope M, Vucemilo I, et al. Endovenous radiofrequency ablation for the treatment of varicose veins. *Can J Surg* 2015; **58**: 85-6.
- 9) Go SJ, Cho BS, Mun YS, et al. Study on the long-term results of endovenous laser ablation for treating varicose veins. *Int J Angiol* 2016; **25**: 117-20.
- 10) Alder LS and Rahi MA. Single-visit endovenous laser treatment and tributary procedures for symptomatic great saphenous varicose veins. *Ann R Coll Surg Engl* 2014; **96**: 279-83.
- 11) Min RJ, Khilnani N, Zimmet SE. Endovenous laser treatment of saphenous vein reflux: long-term results. *J Vasc Interv Radiol* 2003; **14**: 991-6.
- 12) Ravi R, Trayler EA, Barrett DA, et al. Endovenous thermal ablation of superficial venous insufficiency of the lower extremity: single-center experience with 3000 limbs treated in a 7-year period. *J Endovasc Ther* 2009; **16**: 500-5.
- 13) Mozes G, Kalra M, Carmo M, et al. Extension of saphenous thrombus into the femoral vein: a potential complication of new endovenous ablation techniques. *J Vasc Surg* 2005; **41**: 130-5.
- 14) Marsh P, Price BA, Holdstock J, et al. Deep vein thrombosis (DVT) after venous thermoablation techniques: rates of endovenous heat-induced thrombosis (EHIT) and classical DVT after radiofrequency and endovenous laser ablation in a single center. *Eur J Vasc Endovasc Surg* 2010; **40**: 521-7.
- 15) Dexter D, Kabnick L, Berland T, et al. Complications of endovenous lasers. *Phlebology* 2012; **27 Suppl 1**: 40-5.
- 16) Kane K, Fisher T, Bennett M, et al. The incidence and outcome of endothermal heat-induced thrombosis after endovenous laser ablation. *Ann Vasc Surg* 2014; **28**: 1744-50.
- 17) Kurihara N, Hirokawa M, Yamamoto T. Postoperative venous thromboembolism in patients undergoing endovenous laser and radiofrequency ablation of the saphenous vein. *Ann Vasc Dis* 2016; **9**: 259-66.
- 18) Izumi M, Ikeda Y, Yamashita H, et al. Safety and effectiveness of endovenous laser ablation combined with ligation for severe saphenous varicose veins in Japanese patients. *Int Heart J* 2016; **57**: 87-90.
- 19) Hirokawa M. An update on endovenous laser ablation treatment of varicose veins. *J Clin Exp Med* 2012; **240**: 518-21. (in Japanese)
- 20) Jin HY, Ohe HJ, Hwang JK, et al. Radiofrequency ablation of varicose veins improves venous clinical severity score despite failure of complete closure of the saphenous vein after 1 year. *Asian J Surg* 2017; **40**: 48-54.
- 21) Maurins U, Rabe E, Pannier F. Does laser power influence the results of endovenous laser ablation (EVLA) of incompetent saphenous veins with the 1470-nm diode laser? A prospective randomized study comparing 15 and 25 W. *Int Angiol* 2009; **28**: 32-7.
- 22) Hirokawa M, Ogawa T, Sugawara H, et al. Comparison of 1470 nm laser and radial 2ring fiber with 980 nm laser and bare-tip fiber in endovenous laser ablation of saphenous varicose veins: a multicenter, prospective, randomized, non-blind study. *Ann Vasc Dis* 2015; **8**: 282-9.
- 23) Doganci S and Demirkilic U. Comparison of 980 nm laser and bare-tip fibre with 1470 nm laser and radial fibre in the treatment of great saphenous vein varicosities: a prospective randomised clinical trial. *Eur J Vasc Endovasc Surg* 2010; **40**: 254-9.