



Motorized spiral enteroscope-assisted retrieval of video capsule in a patient with Crohn's disease

Pradev Inavolu, MD, DM,¹ Aniruddha Pratap Singh, MD, DM,¹ Haranath Kanakagiri, MD,²
D. Nageshwar Reddy, MD, DM,¹ Mohan Ramchandani, MD, DM¹

A 36-year-old man with chronic kidney disease on maintenance hemodialysis was evaluated elsewhere for obscure GI bleeding requiring multiple blood transfusions. A capsule endoscopy (CE) performed at that center showed ileal stricture and poor progression of the capsule beyond the stricture. CT showed the CE device in the proximal ileal loop, with no signs of small-bowel obstruction. Laboratory test results showed highly sensitive C-reactive protein and fecal calprotectin levels (>500 $\mu\text{g}/\text{mg}$) suggestive of inflammatory bowel disease. He was treated with oral steroids for suspected Crohn's disease and management of retained capsule. After 6 months, on patient preference, retrograde enteroscopy was attempted at that center for persistent

prolonged capsule retention but was unsuccessful. He was referred to us for further management.

Anterograde motorized spiral enteroscopy (MSE; Olympus Corp, Tokyo, Japan) (Fig. 1) was performed with the patient in the supine position and under general anesthesia with nasal endotracheal intubation. A scout fluoroscopic image showed a retained capsule endoscope in the small bowel (Fig. 2). Esophageal dilatation was performed with boogie dilators up to 20 mm, which is a standard procedure.

The enteroscope was introduced and pushed gently beyond the ligament of Trietz (Video 1, available online at www.VideoGIE.org). The presence of a dedicated




Figure 1. A, Integrated motor in motorized spiral enteroscope. B, Power spiral tube. C, Foot switch with forward and backward pedal. D, Power spiral enteroscope. E, force gauge on power spiral control unit for visual indication of the rotational direction. Pictures courtesy of Olympus Corp, Tokyo, Japan.

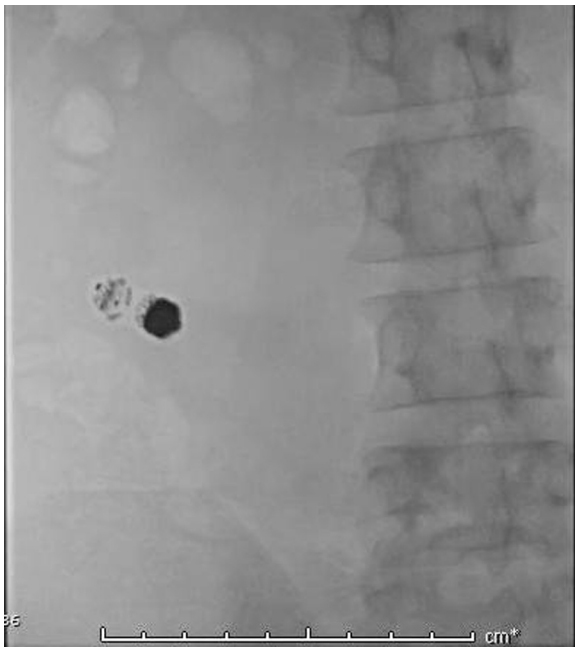


Figure 2. Scout image showing capsule endoscopy device.

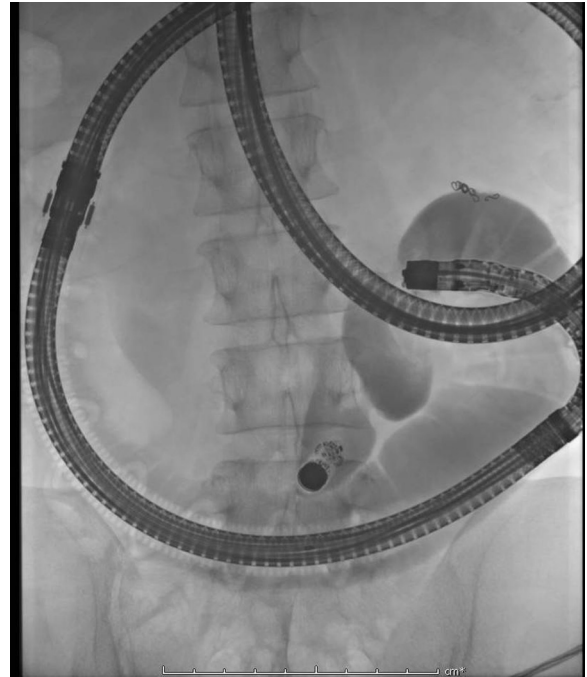


Figure 4. Multifocal stricture ileal segment with retained capsule endoscopy device.

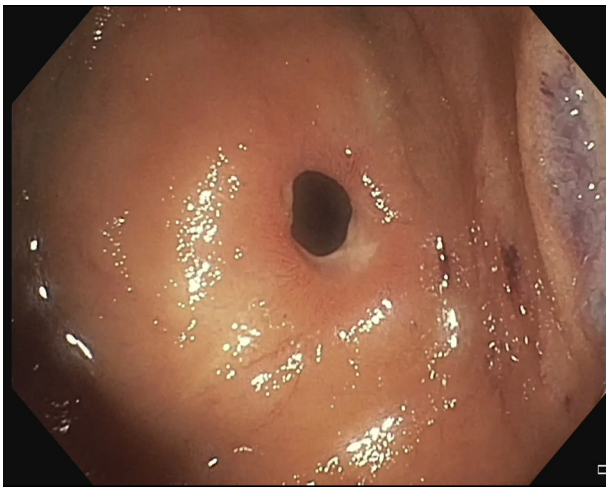


Figure 3. Nontraversable proximal ileal stricture.

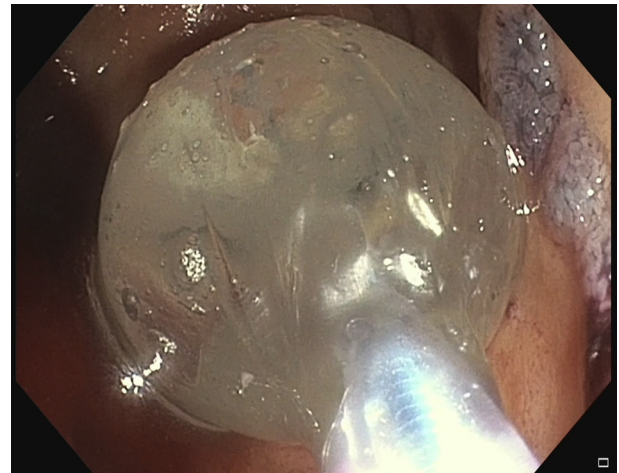


Figure 5. Endoscopic balloon dilatation of the proximal ileal stricture.

water jet helped in using the water immersion technique, which increases the depth of insertion into the small bowel. Within 25 minutes of starting the procedure, the proximal ileal stricture was visualized (Fig. 3). Narrow-band imaging showed edematous mucosa with prominent villi. A contrast fluoroscopic image at the stricture site showed multifocal small-bowel strictures and proximally dilated bowel with a retained capsule beyond the second stricture (Fig. 4). The first stricture was nontraversable, so antegrade graded dilatation was done up to 20 mm using a through-the-scope hydrostatic balloon (balloon length, 5.5 cm). Careful dilatation was done under direct

visual and fluoroscopic guidance (Fig. 5). The second stricture was dilated in a similar graded fashion by approximating the endoscope tip to the proximal end of the balloon to minimize barotrauma (Figs. 6 and 7). The retained capsule was visualized after dilatation and was seen proximal to another tight stricture (Fig. 7). The CE device was retrieved and removed with the help of a foreign body retrieval net with a length of 230 cm and net size of 3 × 6 cm (Fig. 8). The postprocedural period was uneventful.

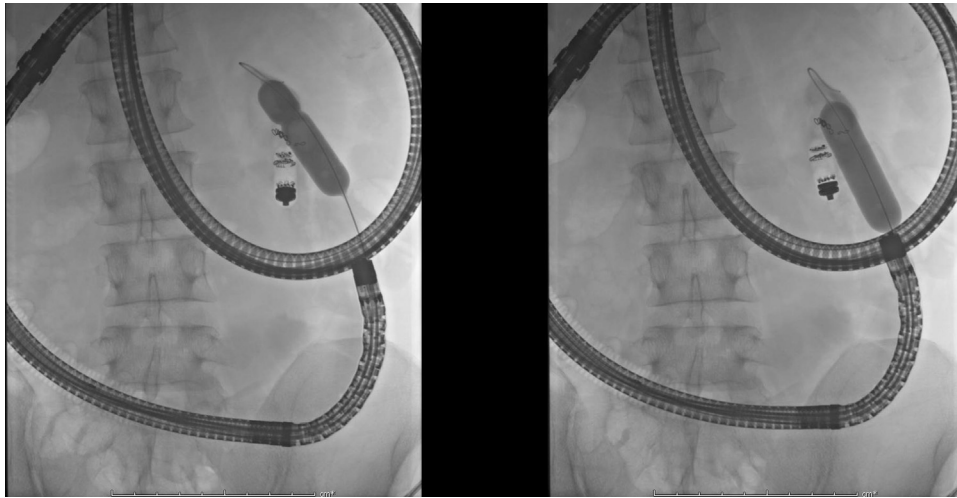


Figure 6. Fluoroscopic image showing stricture dilatation—“waist disappearance.”

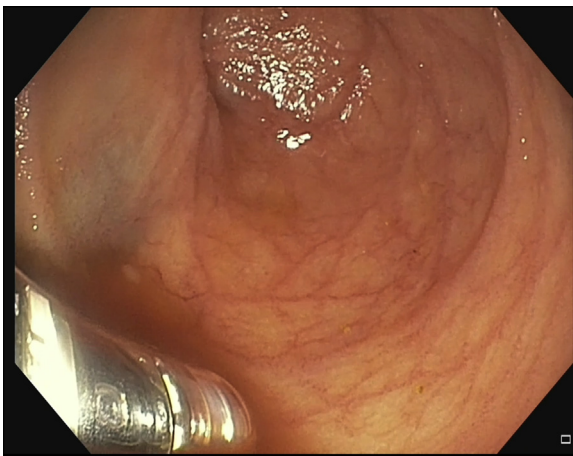


Figure 7. Visible capsule endoscopy device identified after stricture dilation.

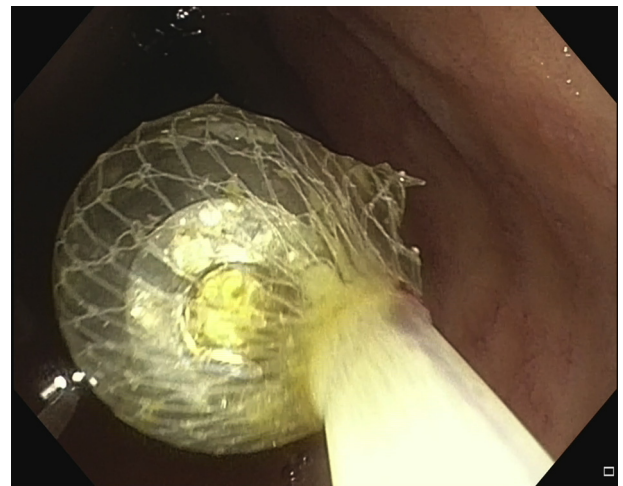

Figure 8. Retrieval of capsule endoscopy device using Roth net.

DISCUSSION

Capsule endoscope retention rates have been reported to be 1% to 2%, with a higher incidence (13%) in patients with Crohn's disease.¹⁻³ In the majority of cases, capsule retention is asymptomatic, but capsule retrieval should be attempted in the event of symptoms or in patients with prolonged retention (especially in the presence of strictures) because of the risk of perforation or disintegration of the capsule.²⁻⁴

Novel MSE incorporates a motor in the handle of the enteroscope and a disposable short spiral overtube mounted on the insertion end, which has distinct advantages. Motorization ensures smooth and safe insertion and withdrawal of the enteroscope. Because of the presence of a large therapeutic channel and the shorter length of the endo-

scope, all standard colonoscopy accessories can be used with better maneuverability during therapeutic interventions. MSE may be a good alternative in deep enteroscopy because of the ease and shorter time taken to perform procedures, with maximum visualization of the small bowel.^{5,6} MSE-assisted, through-the-scope balloon dilatation may be safe and efficacious. To our knowledge, data regarding MSE-assisted stricture dilatation and retrieval of a capsule endoscope are scarce. More prospective studies are required to compare it with conventional enteroscopies.

To conclude, we demonstrate here the technique of MSE-assisted dilatation of a small-bowel stricture and retrieval of a retained video capsule. MSE can be an effective alternative in diagnostic and therapeutic deep enteroscopy.

ACKNOWLEDGEMENT

Supported by a Robert W. Summers grant from the American Society for Gastrointestinal Endoscopy.

DISCLOSURE

All authors disclosed no financial relationships.

Abbreviations: CE, capsule endoscopy; MSE, motorized spiral enteroscopy.

REFERENCES

1. Liao Z, Gao R, Xu C, et al. Indications and detection, completion, and retention rates of small-bowel capsule endoscopy: a systematic review. *Gastrointest Endosc* 2010;71:280-6.
2. Lee HS, Lim YJ, Kim KO, et al. Outcomes and management strategies for capsule retention: a Korean Capsule Endoscopy Nationwide Database Registry Study. *Dig Dis Sci* 2019;64:3240-6.

3. Nemeth A, Wurm Johansson G, Nielsen J, et al. Capsule retention related to small bowel capsule endoscopy: a large European single-center 10-year clinical experience. *United European Gastroenterol J* 2017;5:677-86.
4. Rondonotti E. Capsule retention: prevention, diagnosis and management. *Ann Transl Med* 2017;5.
5. Beyna T, Arvanitakis M, Schneider M, et al. 47 first prospective clinical trial on total motorized spiral enteroscopy (Tmset) [abstract]. *Gastrointest Endosc* 2019;89:AB48.
6. Mans L, Arvanitakis M, Neuhaus H, et al. Motorized spiral enteroscopy for occult bleeding. *Dig Dis* 2018;36:325-7.

Department of Medical Gastroenterology, AIG Hospitals, Hyderabad, Telangana, India (1), Department of Anaesthesia, AIG Hospitals, Hyderabad, Telangana, India (2).

Copyright © 2020 American Society for Gastrointestinal Endoscopy. Published by Elsevier Inc. This is an open access article under the CC BY-NC-ND license (<http://creativecommons.org/licenses/by-nc-nd/4.0/>).

<https://doi.org/10.1016/j.vgie.2020.05.014>

VideoGIE Quiz

Think you can outsmart *VideoGIE*? Try your luck with our new Quiz series. Using cases published in *VideoGIE*, we post questions designed to improve the education of our fellows. Go to <http://www.videogie.org> to submit your answer, and keep checking back for more quizzes!