

CASE REPORT

Basaloid squamous cell carcinoma of retromolar trigone: A case report with review of literature

JR Rachel, NS Kumar, NK Jain

Department of Oral and Maxillofacial Surgery, Vinayaka Mission's Sankarachariyar Dental College and Hospital, Ariyanoor, Salem, India

Address for correspondence:

Dr. Reena Rachel John,
Department of Oral and Maxillofacial Surgery,
Vinayaka Mission's Sankarachariyar Dental
College and Hospital, Sankari Main Road,
Ariyanoor, Salem - 636 308, India.
E-mail: johnbjohn2005@yahoo.com

ABSTRACT

Basaloid squamous cell carcinoma (BSCC) is a rare distinct histologic variant of squamous - cell carcinoma of the head and neck region. BSCC is more aggressive and has a poorer prognosis, although histologically, it is associated with squamous cell carcinoma and squamous atypia. The usual site of occurrence for BSCC is the upper aerodigestive tract, floor of the mouth and base of the tongue. This is a case report of an unusual case of BSCC of retromolar trigone, which is quite rare.

Key words: Basaloid squamous cell carcinoma, squamous cell carcinoma, retromolar trigone

INTRODUCTION

Basaloid squamous cell carcinoma (BSCC) is an uncommon variant of squamous cell carcinoma. It was first described by Wain *et al* in 1986.^[1] BSCC is included as a distinct entity in the revised classification of tumors of head and neck by *WHO* in 1991.^[2] Generally, it has a predilection for head and neck region, particularly the upper aerodigestive tract, i.e. larynx-hypo pharynx.^[3] In the oral cavity, BSCC has a predilection for the tongue, though it has been described in other locations such as floor of the mouth, palate, retromolar trigone and gingival mucosa.^[4]

The aggressive biological behavior of BSCC has been commonly associated with early recurrence, cervical lymph node involvement and distant metastasis with spread to the lungs and liver.^[5] Most BSCC's are diagnosed at advanced clinical stages and have an unfavorable prognosis because of poor overall patient survival rate.

Clinically, patients with BSCC present features similar to those of the patients with squamous cell carcinoma and have the same etiological risk factors, e.g. tobacco and alcohol consumption.^[6] The recommended treatment for BSCC is surgery followed by radiotherapy and chemotherapy.^[7]

CASE REPORT

A 65 year - old male patient reported with a chief complaint of pain in right lower back tooth region of 6 months duration. The patient gave a history of difficulty in mouth opening and swallowing. He had a history of beedi smoking for a period of 50 years, with a frequency of 12/day.

Extra oral clinical examination revealed palpable, mobile submandibular and upper jugular lymph nodes on the right side, measuring approximately 1×1 cm and they were firm and non-tender to palpation. On intra-oral examination, an ulceroproliferative lesion involving the right side of the retromolar trigone region, measuring about 2×2 cm. was seen [Figure 1]. The ulcer was tender on palpation, exhibiting irregular margins with ill-defined borders and white slough surrounded by erythematous area. Oral hygiene was poor with generalized stains and calculus. Generalized attrition was present with right posterior teeth tender on percussion. No limitation of mouth opening was seen. Tongue movements were not affected.

A provisional clinical diagnosis of malignant ulcer was given. After obtaining written consent from the patient, an incisional biopsy was performed under local anesthesia and sent for histopathologic examination. An orthopantomogram [Figure 2] was taken which showed irregular radiolucency distal to 3rd molar with erosion of the ascending border of the ramus of the mandible, measuring 2 × 2 cm. An ultrasonogram of neck was done. The report showed metastatic changes in submandibular and level II group of lymph nodes. The histopathologic report [Figure 3] was poorly differentiated squamous cell carcinoma. The lesion was T₄N₁M_x.

Access this article online

Quick Response Code:



Website:
www.jomfp.in

DOI:
10.4103/0973-029X.84495

The treatment planned was hemimandibulectomy with supraomohyoid neck dissection under general anesthesia, followed by radiotherapy. An apron incision extending from the midline of the chin along the second crease of the neck extending to the mastoid process was made. Anteriorly, the incision was continued around the chin to split the lower lip in the midline. Dissection was done in the subplatysmal layer and supraomohyoid neck dissection was done. The nodes in the level I and level II regions of the neck were surgically removed. The submandibular salivary gland was excised [Figure 4]. Hemimandibulectomy was done. Hemostasis was achieved. Wound closure was done. Postoperative recovery of the patient was uneventful. The histopathologic picture of the excised specimen was reported as BSCC. The histopathologic report was given by three oral pathologists from different centers.

The patient has undergone radiotherapy with 5000 cGy fractionated over 6 weeks. Barium meal test, chest X-ray and endoscopic evaluation of the upper aerodigestive tract were done, which showed no evidence of lesion or metastasis. The patient has been reviewed regularly for the last 3 months and is disease free.

BSCC has been defined in the 2005 WHO blue book as an aggressive high grade variant of squamous cell carcinoma of both basaloid and squamous components.^[8] Wain *et al.*^[1] first introduced this histopathological entity and called it as BSCC in 1986. Till date approximately 45 cases of BSCC involving the oral cavity have been reported in literature, with a strong predilection for base of the tongue (61%) and floor of the mouth (30%).^[9]

The histogenesis of this neoplasm is controversial. It is suggested that the tumor originates from the totipotential cells in the basal layer of squamous epithelium. When we review the etiology, it is seen that the possible relationship of BSCC and viruses is a matter of debate and has been reported in some locations like nasopharynx and penis.^[10,11] The obtained data are controversial, while Kleist *et al.*^[12] and El mofty *et al.*^[13] have very recently detected a high frequency of HPV and HSV in basaloid tumors than in conventional squamous cell carcinoma in the head and neck, others have found no difference.

The various sites of origin of BSCC reported by authors were gingiva (Eiji Hirai *et al.*^[14]), oral mucosa and maxillary tuberosity (C. Wedenberg *et al.*^[15]), floor of the mouth (Kunal Sah *et al.*^[16]), retromolar trigone (Marcia Sampaio Campos *et al.*^[17]), nasal cavity (Joong Seob Lee *et al.*^[18]), hypopharynx with extensive spindle cell component (Tokuhiko kimura *et al.*^[19]), conjunctiva and paranasal sinus (Pooja Vasudev^[20]), urinary bladder (Funda Vakar –Lopez *et al.*^[21]) and uterine cervix (Yong Soon Kwon^[22]) [Table 1].

Domenico Coppola *et al.*^[23] studied the clinicopathological and immunohistochemical features of eight BSCC of floor of the mouth which reveals high recurrence, worse prognosis,

metastasis, mortality and shorter survival than squamous cell carcinoma. Grossly, most of the previously reported BSCCs are flat or slightly elevated tumors, often with a central ulceration similar to our case. Very few cases show a polypoid pattern. Interestingly these cases are always associated with a spindle cell component.^[18,19] Jung Yeon Kin *et al.*^[24] reported that all BSCC showed positivity for high molecular weight cytokeratin (HMW CK) with heterogenous or diffuse staining pattern, but lacked activity for neuroendocrine markers and bcl-2 oncoprotein. Pinar Atasoy *et al.*^[25] reported a case of BSCC of lungs whose cells showed a high mitotic rate and peripheral palisading. The immunohistological examination for neuroendocrine markers was negative. Tie-Jun Li *et al.*^[26] studied BSCC of esophagus without adenoid cystic features. Grazia Salerno *et al.*^[27] reported that low levels of p27^{Kip 1} expression significantly correlated with poor prognosis, biological aggressiveness and consequent shortened survival. The supposed higher clinical aggressiveness of BSCC compared with the conventional Squamous cell carcinoma remains a continuous matter of debate. Banks *et al.*, Luna *et al* and De sampaio *et al.*^[28] did not find significant differences in behaviour between these two neoplasms in different anatomical sites while others did. Cosmo E *et al.*^[29] discussed the clinicopathological and follow-up study of 40 cases and review of literature and concluded that solid nest with typical cell population, basaloid at the periphery [Figure 5] and squamous at the centre, are the most common growth patterns of BSCC, which was the histopathologic picture seen in our case.

DISCUSSION

BSCC is a rare and aggressive variant of squamous cell carcinoma which is reported to occur predominantly in men between 60 to 70 years of age.^[1] It is reported in individuals with history of tobacco and alcohol abuse. The most frequent site to be affected by BSCC is the upper aerodigestive tract with strong predilection for the base of the tongue, supraglottic larynx and hypopharynx, but it is also found in the anus, thymus and uterine cervix. Clinically, it is an aggressive tumor with high rates of nodal (64%) and distant metastases (44%). Results of a case control study by Soriano *et al* found a 6 times higher risk of distant metastases compared to the usual type of squamous cell carcinoma. Some authors recommend a chest CT and FDG- PET in all cases to rule out early distant metastases. Treatment of choice is complete surgical excision of the lesion with neck dissection supplemented by radiotherapy or adjuvant chemotherapy.

Our case report was a BSCC in the retromolar trigone which is an unusual site of occurrence. Marcia sampaio campos *et al.*^[7] has also reported an atypical presentation of oral BSCC in the retromolar trigone in a 39 year old man, in which he described the immunohistochemical characteristics of the lesion. Due to its biological and morphologic features, it may be confused with adenoid cystic carcinoma of the solid subtype, small cell neuroendocrine carcinoma undifferentiated carcinoma,

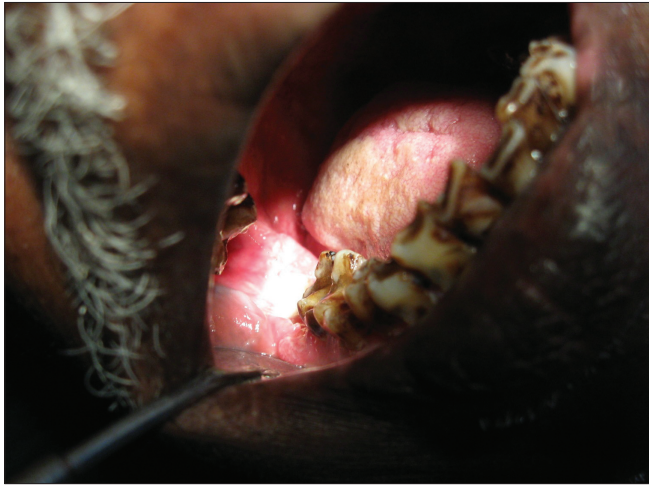

Figure 1: Clinical picture of the lesion

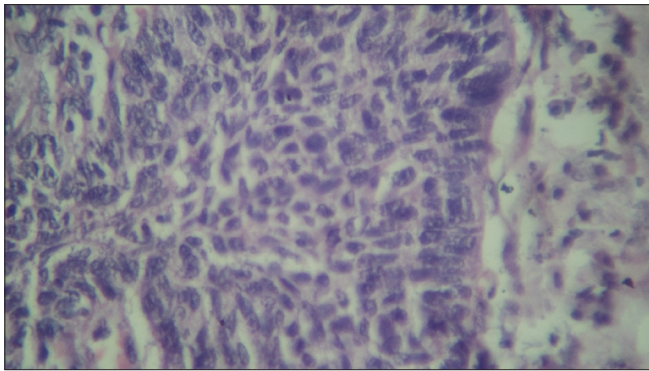


Figure 3: Incisional biopsy – histological section (H and E stain, 40×)

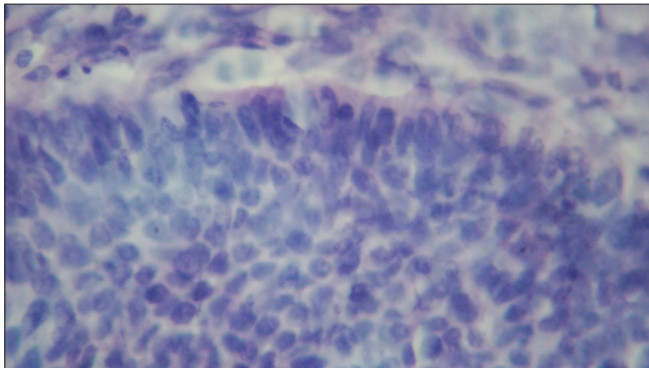


Figure 5: Histological picture of basal cell palisading (H and E stain, 40×)

basal cell adenocarcinoma and squamous or adenosquamous carcinoma. In the large majority of cases, the distinction between these tumors is readily made on the basis of standard H&E morphology. However, immunohistochemical markers have been reported to be useful in differentiating these tumors.

Our case mimics squamous cell carcinoma clinically and was reported on incisional biopsy as poorly differentiated squamous cell carcinoma. On examining the deeper sections of the excisional biopsy, the histologic picture showed nests and cords of closely packed pleomorphic basaloid cells with

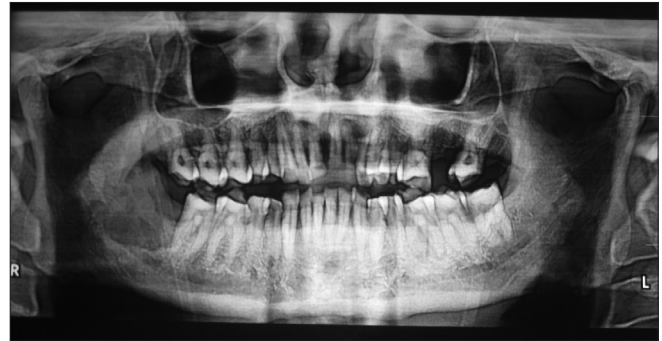

Figure 2: Radiograph showing erosion of the bone on the right side ascending border of ramus

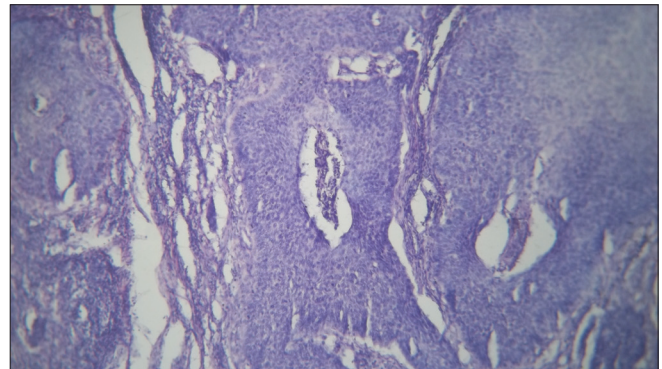


Figure 4: Invasion of the lesion in the lymph nodes (H and E stain, 4×)

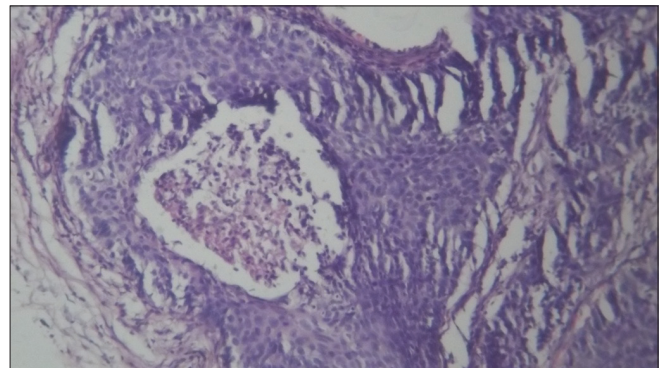


Figure 6: Histopathological picture on high power magnification showing comedo necrosis (H and E stain, 10×)

nuclear palisading along the periphery of the neoplastic nests surrounded by a fibrous stroma with prominent areas of comedo necrosis. Hence the histopathologic report of BSCC was given.

Wain *et al.*^[1] and recently Barnes *et al.*^[30] put down the following criteria to diagnose cases of BSCC.

The features included:

- Predilection for head and neck region in men in their 60s or 70s.
- An ulcerated or exophytic mass with submucosal soft tissue infiltration.
- Solid basaloid appearing dysplastic island with biphasic pattern showing comedo type necrosis [Figure 6] and pseudo-glandular pattern.

Table 1: Review of the site, clinical and immunohistological features

Journal /Author	Study done	Pt. volume	Site of the lesion	Outcome
Eiji Hirai <i>et al.</i> ^[14]	Case report	2	Gingiva	
C.Wedenberg <i>et al.</i> ^[15]	Case report	1	Oral mucosa and maxillary tuberosity	
Kunal <i>et al.</i> ^[16]	Case report	1	Floor of the mouth	
Marcia Sampaio Campose <i>et al.</i> ^[17]	Case report	1	Retromolar trigone	
Joong Seob Lee <i>et al.</i> ^[18]	Case report	1	Nasal cavity	
Tokuhiro kimura <i>et al.</i> ^[19]	Case report	1	Hypopharynx	
Pooja Vasudev ^[20]	Case report	1	Conjunctiva and paranasal sinus	
Funda Vakar–Lopez <i>et al.</i> ^[21]	Case report	1	Urinary bladder	
Domenico Coppola <i>et al.</i> ^[23]	Clinicopathological and immunohistochemical features	8	Floor of the mouth	Reveals high recurrence, worse prognosis, metastasis, mortality and shorter than sq. Cell carcinoma positivity for high molecular weight cytokeratin (HMW CK) but lacked activity for neuroendocrine markers and bcl-2 oncoprotein
Jung Yeon Kin <i>et al.</i> ^[24]	Immunohistochemical features			high mitotic rate and peripheral palisading and neuroendocrine markers was negative
Pinar Atasoy <i>et al.</i> ^[25]	Histopathological and immunohistochemical features	1	Lung	without adenoid cystic features
Tie–Jun Li <i>et al.</i> ^[26]	Clinical features		Esophagus	low levels of p27 ^{Kip1} expression significantly correlated with poor prognosis, biological aggressiveness and consequent shortened survival
Grazia Salerno <i>et al.</i> ^[27]	Immunohistochemistry			solid nest with typical cell population, basaloid at the periphery and squamous at the centre, are most common growth patterns of BSCC
Cosmo Ereno <i>et al.</i> ^[29]	Clinical and follow up study	40		

- Abrupt foci of squamous differentiation with or without keratin pearls, and surface mucosal epithelium showing dysplastic features.

Quite recently, however Coletta *et al.*^[31] have demonstrated the importance of cytokeratins 1, 7 and 14 in the diagnosis of SCC and have shown significantly higher AgNOR and PCNA positivity in BSCC when compared with squamous cell carcinoma. Immuno staining for p53 also showed a higher percentage of positive cells in BSCC. The glandular carcinomas can be excluded as glandular lesion present immunoreactivity for CK7 unlike BSCC. Expression of MMP-1, MMP-2 and MMP-9 were reported higher in cells of BSCC than in cells of squamous cell carcinoma, suggesting of aggressive behaviour. Emanuel *et al.*^[32] have stressed the value of p63 in making the distinction between BSCC and adenoid cystic carcinoma of head and neck.

Though in a comparative study of oral BSCC and squamous cell carcinoma done by Ferrada C Grizza *et al.*^[4] they concluded that their study supported the opinion that the prognosis of BSCC does not differ from that of conventional

squamous cell carcinoma of the oral cavity when matched for clinical classification.^[4]

Nodal metastasis is quite common in laryngeal, hypopharyngeal and tracheal BSCC. Regional nodal metastasis was seen in 75% and distant nodal metastasis was seen in 35-50% of the cases in Wizenburg *et al* series, lung is reported to be the main target for distant metastasis in BSCC. In our case, the patient showed no clinical or radiographic evidence of lung metastasis. Finding a second primary tumor is a common clinical situation in the head and neck. Cosmo E *et al.* have observed in 17.5% of their patients, a second primary tumor and therefore support Thompson's advice for keeping in mind the possibility of finding a second primary tumor in any sites either synchronic or metachronic, when diagnosing a BSCC in the head and neck

CONCLUSION

BSCC, a distinct clinicopathological entity with aggressive clinical behavior, which usually is reported to occur in the upper aerodigestive tract, has been reported by us occurring

in the retromolar trigone area which is an uncommon site for an uncommon lesion such as BSCC.

REFERENCES

- Wain SL, Kier R, Volmer RT. Basaloid squamous cell carcinoma of the tongue, hypopharynx and larynx report of 10 cases. *Hum Pathol* 1986;17:1158-6.
- World Health Organization. *Histological typing of tumour of upper respiratory tract and ear* Berlin, Germany: Springer Verlag; 1991.
- Sundharam BS, Krishnan PA. Basaloid squamous cell carcinoma report of a case and review of literature. *Indian J Dent Res* 2003;14:184-6.
- de Sampaio Góes FC, Oliveira DT, Dorta RG, Nishimoto IN, Landman G, Kowalski LP. Prognoses of oral basaloid squamous cell carcinoma and squamous cell carcinoma. *Arch Otolaryngol head neck surg* 2004;130:83-6.
- Sampio -Goes FC, Oliveira DT, Dorta RG, Nonogaki S, Landman G, Nishimoto IN, et al. Expression of PCNA, p53, BAXA and Bcl-X in oral poorly differentiated and Basaloid squamous cell carcinoma relationship with prognosis. *Head Neck* 2005;27:982-9.
- Winzenburg SN, Niehans GA, George E, Daly K, Adams GL. Basaloid squamous cell carcinoma: A clinical comparison of two histological types with poorly differentiated squamous cell carcinoma. *Otolaryngeal Head Neck Surg* 1998;119:471-5.
- Lu SY, Eng HL, Huang CC, Chien CY, Lui CC, Lin JW. Basaloid squamous cell carcinoma of the sinonasal tract - report of two cases. *Otolaryngol Head Neck Surg* 2006;134:883-5.
- Cardesa A, Zidar N, Erenoc. Basaloid squamous cell carcinoma. *World health organization classification of tumors*. Lyon, france: IARC Press; 2005.p.124-5.
- Ide F, Shimoyama T, Horie N, Kusama K. Basaloid squamous cell carcinoma of oral mucosa: A new case and review of 45 cases in literature. *Oral Oncol* 2002;38:120-4.
- Wan SK, Chan JK, Lau WH, Yip TT. Basaloid squamous carcinoma of the nasopharynx. An epstein-barr virus-associated neoplasm compared with morphologically identical tumors occurring in other sites. *Cancer* 1995;76:1689-93.
- Cubilla AL, Reuter VE, Gregoire L, Ayala G, Ocampos S, Lancaster WD, et al. Basaloid squamous cell carcinoma: A distinctive human papilloma virus related penile neoplasm: A report of 20 cases. *Am J Surg Pathol* 1998;22:755-61.
- Kleist B, Bankau A, Lorenz G, Jager B, Poetschet M. Different risk factors in basaloid and common squamous head and neck cancer. *Laryngoscope* 2004;114:1063-8.
- El-Mofty SK, Patil S. Human papillomavirus (HPV)-related oropharyngeal nonkeratinizing squamous cell carcinoma: Characterization of a distinct phenotype. *Oral Surg Oral Med Oral Pathol Oral Radiol Endod* 2006;101:339-45.
- Hirai E, Yamamoto K, Yamamoto N, Yamashita Y, Kounoe T, Kondo Y, et al. Basaloid squamous cell carcinoma of mandible: Report of two cases. *Oral Surg Oral Med Oral Pathol Oral Radiol Endod* 2009;108:e54-8.
- Wedenberg C, Jesslén P, Lundqvist G, Lundgren J, Hellquist HB. Basaloid squamous cell carcinoma of the maxilla. *Oral Oncology* 1997;33:141-4.
- Sah K, kale A, Hallikerimah S. Basaloid squamous cell carcinoma involving floor of the mouth. *J Oral Maxillofac Surg* 2008;12:61-3.
- Campos MS, Modolo F, de Oliveira JS, Pinto-Júnior DS, de Sousa SC. Atypical presentation of oral basaloid squamous cell carcinoma. *J Contemp Dent Pract* 2009;10:98-104.
- Lee JS, Ko JJ, Jun SY, Kim JY. Basaloid squamous cell carcinoma in nasal cavity. *Clin Exp Otorhinolaryngol* 2009;2:207-10
- Kimura T, Mukai M, Shiotani A, Moro K, Ikeda A, Okada Y. Basaloid squamous cell carcinoma of the hypopharynx with an extensive spindle cell component exhibiting a pedunculated polypoid mass. *Arch patho lab med* 2005;129:e94-6.
- Vasudev P, Boutross-Tadross O, Radhi J. Basaloid squamous cell carcinoma: Two case reports. *Cases J* 2009;2:9351.
- Vakar-López F, Abrams J. Basaloid squamous cell carcinoma occurring in the urinary bladder. *Arch Pathol Lab Med* 2000;124:455-9.
- Yong SK, Yong MK, Choi GW, Kim YT, Nam JH. Pure basaloid squamous cell carcinoma of the uterine cervix: A case report. *J Korean Med Sci* 2009;24:542-5.
- Coppola D, Catalano E, Tang CK, Elfenbein IB, Harwick R, Mohr R. Basaloid squamous cell carcinoma of floor of mouth. *Cancer* 1993;72:2299-05.
- Kim JY, Cho KJ, Lee SS, Khang SK, Shim YS. Clinicopathologic study of basaloid squamous cell carcinoma of the upper aerodigestive tract. *J Korean Med* 1998;13:269-74.
- Atasoy P, Bozdogan N, Dizbay SS, Akay H. Basaloid carcinoma of the lung. *Turk J Cancer* 2000;30:36-9.
- Li TJ, Zhang YX, Wen J, Cowan DF, Hart J, Xiao SY. Basaloid Squamous cell carcinoma of the esophagus with or without adenoid cystic features. *Arch Pathol Lab Med* 2004;128:1124-30.
- Salerno G, Di Vizio D, Staibano S, Mottola G, Quaremba G, Mascolo M, et al. Prognostic value of p27Kip1 expression in basaloid squamous cell. *BMC Cancer* 2006;6:146.
- Banks ER, Frierson HF, Covell JL. Fine needle aspiration cytologic findings in metastatic basaloid squamous cell carcinoma of the head and neck. *Acta Cytol* 1992;36:126-31.
- Cosme E, Ayman G, Maddi G, Carmen E, Francisco J, Bilbao J, et al. Basaloid squamous cell carcinoma of the head and neck. *Head Neck Pathol* 2008;2:83-91.
- Barnes L, Ferlito A, Altavilla G, MacMillan C, Rinaldo A, Doglioni C. Basaloid squamous cell carcinoma of head and neck: Clinicopathological features and differential diagnosis. *Ann Otol Rhino Laryngol* 1996;105:75-82.
- Coletta RD, Cotrim P, Vargas PA, Villalba H, Pires FR, de Moraes M, et al. Basaloid squamous cell carcinoma of oral cavity report of 2 cases and study of AGNOR, PCNA, p53 and MMP expression. *Oral Surg Oral Med Oral Pathol Oral Radiol Endod* 2001;91:563-9.
- Emanuel P, Wang B, Wu M, Burstein DE. p63 immunohistochemistry in the distinction of adenoid cystic carcinoma from basaloid squamous cell carcinoma. *Mod Pathol* 2005;18:645-50.

How to cite this article: Rachel JR, Kumar NS, Jain NK. Basaloid squamous cell carcinoma of retromolar trigone: A case report with review of literature. *J Oral Maxillofac Pathol* 2011;15:192-6.

Source of Support: Nil. **Conflict of Interest:** None declared.