



Successful Management of a Rare Distant Endodontic Lesion: A Case Report

Mohammad Jafar Eghbal ^a , Ardavan Parhizkar ^a , Saeed Asgary ^{a*}

^a Iranian Centre for Endodontic Research, Research Institute for Dental Sciences, Shahid Beheshti University of Medical Sciences, Tehran, Iran

Article Type: Case Report

Received: 08 Feb 2024

Revised: 23 Feb 2024

Accepted: 02 Mar 2024

Doi: 10.22037/iej.v19i2.44860

*Corresponding author: Saeed Asgary, Iranian Centre for Endodontic Research, Research Institute for Dental Sciences, Shahid Beheshti University of Medical Sciences, Daneshjoo Blv, Evin, Chamran Highway, Tehran 1983963113, Iran.

E-mail: saasgary@yahoo.com

The current case report aims to document a rare presentation of a distant odontogenic lesion of a 35-year-old male patient with mild clinical discomfort in the mandibular right first molar; exploring the diagnostic and therapeutic intricacies of an uncommon distant endodontic pathosis ultimately resolved through meticulous nonsurgical retreatment. Despite a normal oral examination, diagnostic radiography revealed a suboptimal root canal treatment and apical lesions surrounding mesial- and distal-root apices; including a distinct radiolucency beneath the apex of the second mandibular molar discovered through panoramic radiography, and confirmed via cone-beam computed tomography. In addition, the computed tomography disclosed a previously unreported and unusually large endodontic lesion that extended toward the mandibular canal; highlighting a necessity for the continued exploration of a unique endodontic presentation. A nonsurgical endodontic retreatment led to a remarkable reduction in the radiolucent lesions within one year; emphasizing the significance of comprehensive diagnostic approaches and individualized treatments.

Keywords: Cone-beam Computed Tomography; Distant Endodontic Lesion; Endodontic Pathology; Nonsurgical Retreatment

Introduction

Endodontic lesions, *e.g.* apical periodontitis (AP), represent a diverse spectrum of pathologies within endodontics; often associated with inflammatory reactions and microbial invasions. Such lesions have been conventionally visualised through periapical radiography which reveals characteristic features; *e.g.*, radiolucencies and/or radiopacities around the apical region(s) of the involved tooth. Nonetheless, the landscape of diagnosing lesions has recently undergone a paradigm shift with the introduction of cone-beam computed tomography (CBCT); which is able to provide enhanced three-dimensional views into their intricacies [1]. While initial evaluations principally rely on periapical radiography, CBCT significantly elevates the diagnostic capabilities *via* offering richer visualization of (i) complex anatomical structures, (ii) root canal configurations, and (iii) associated variations in lesion characteristics [2].

The clinical challenges posed by endodontic lesions may extend beyond the expected problems; as demonstrated by rare cases reporting pulpal necrosis in an adjacent, seemingly healthy tooth due to a periapical lesion caused by another infected tooth [3, 4]. The above-mentioned condition highlights the importance of prompt treatment to prevent the progression of AP.

Additionally, there have been instances where endodontic lesions are presented in unexpected regions; challenging conventional diagnostic usual norms. A specific case notably revealed an apical lesion in the first premolar with spontaneous pain and swelling, extending to maxillary incisors [5]. Another case showed the diagnostic challenges of AP in maxillary premolars and exhibited the limited efficacy of exclusive clinical findings and dental radiography [6]. Besides, regular follow-ups have become crucial to monitor and manage potentially extensive lesions, even in teeth seemingly unaffected by conventional aetiological factors.

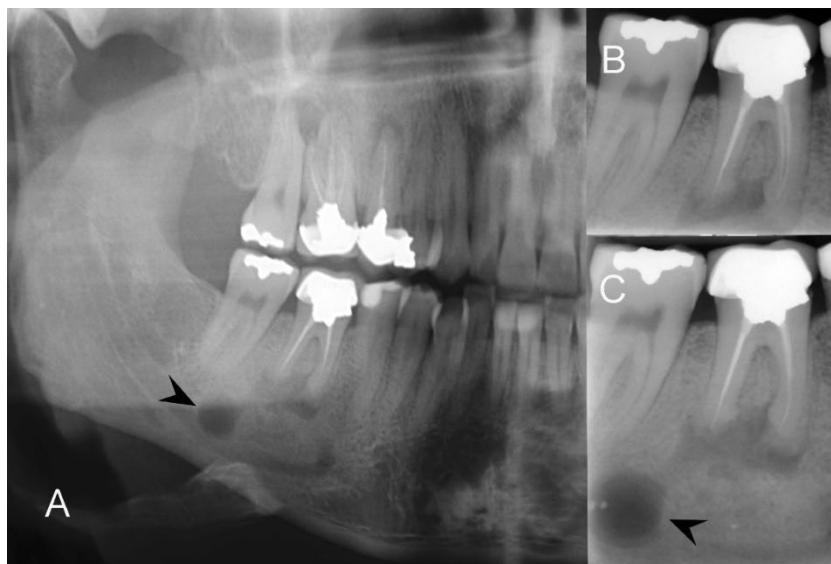


Figure 1. Radiographic findings of mandibular right first molar with distant radiolucency; A) Panoramic radiography; displaying a large apical lesion attributed to the failure of endodontic treatment in the tooth #46. Additionally, a distinct and well-bordered radiolucency is observed at a considerable distance from both the first and second mandibular molars (black arrow head); B) Intraoral periapical radiography; showing the involved tooth with evidence of poor root canal filling and periradicular radiolucency but a well-executed prosthetic crown. The second unusual radiolucent lesion is not visible in this radiograph due to its farther distance; C) A subsequent intraoral periapical radiograph with a modified vertical positioning of the film to enhance the visibility of the unusual lesion (black arrow head); In this view, both separate lesions are distinctly visible

The aim of the current study is to contribute to the thorough understanding of endodontic pathology through exploring the intricate diagnostic and therapeutic aspects of a rare distant endodontic lesion. In addition, the presented case emphasizes the evolving role of advanced imaging, specifically CBCT, in unraveling complexities, guiding effective treatment strategies, and promoting optimal patient outcomes.

Case Presentation

A 35-year-old male patient, previously treated for pulpal necrosis and asymptomatic AP, was referred to our endodontic clinic due to a persistent mild clinical discomfort associated with the mandibular right molars. Despite the completion of primary endodontic treatment, the patient reported symptomatic episodes in recent months. His medical history was noncontributory, with no known systemic illnesses or relevant medication use.

During the initial visit, the patient reported a mild discomfort during mastication localised to the mandibular right molars. Clinical examination revealed a well-fitted prosthetic crown on tooth #46 and normal responses to sensibility tests of adjacent teeth. However, tooth #46 exhibited tenderness to palpation/percussion. No evidence of sinus tract, discolouration, deep periodontal pocketing or mobility was noted. Notably, no

overt abnormality was observed upon examination of the mouth.

Diagnostic investigations included panoramic and intraoral radiography, which revealed suboptimal outcomes of the previous primary endodontic treatment on the first mandibular molar (Figures 1A, 1B). Treatment failure was evident with apical lesions observed at both apices. Nevertheless, a subsequent intraoral periapical radiograph with a modified vertical positioning of the film could detect an unusual radiolucency; a separate lesion distinctly visible beneath the apex of the second mandibular molar (Figure 1C). Successive CBCT unveiled a previously unreported and unusually large endodontic lesion with a relatively narrow isthmus connecting the two lesions surrounding the first molar apices (Figure 2). The findings of CBCT indicated the presence of a dumbbell-shaped lesion measuring ≥ 22 mm in diameter, which had obliquely spread from the apical region of tooth #46; reaching the mandibular canal (Figure 2A-C).

The differential diagnosis process involved a systematic exploration of potential causes for the distant endodontic lesion observed in the tooth #46. Primary considerations included evaluating the persistence as well as the recurrence of apical pathology associated with the initial endodontic treatment. However, given the atypical characteristics of the lesion, alternative differential diagnoses were considered; e.g., odontogenic cysts, regional tumours, or rare anatomical variations.

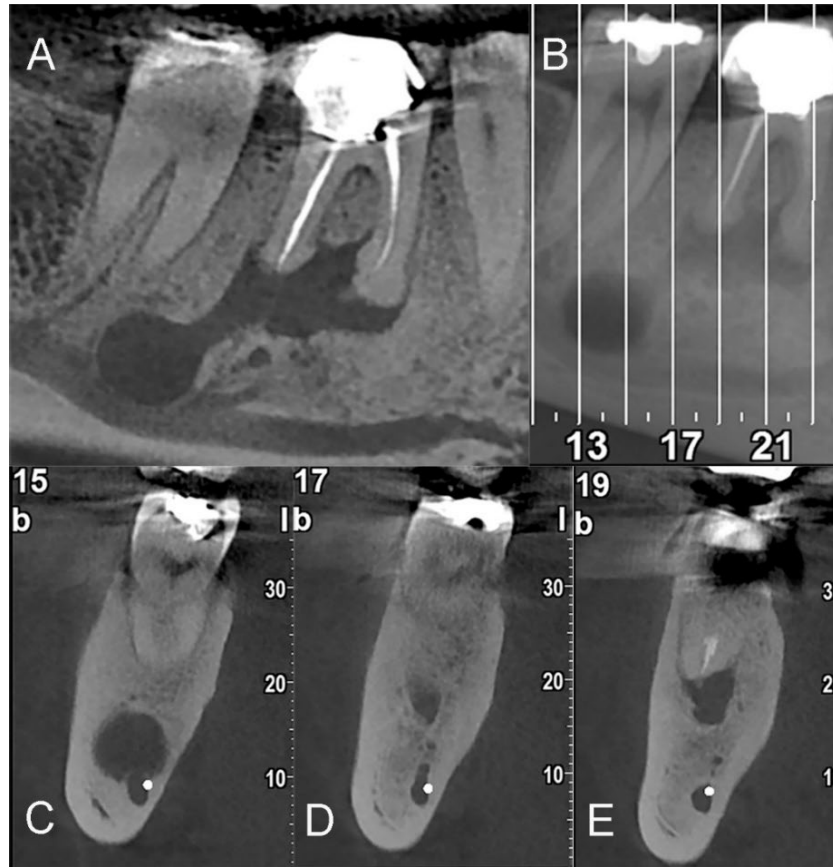


Figure 2. CBCT Analysis of the distant endodontic lesion; A, B) CBCT in sagittal plans; illustrating the direct relationship between the two lesions, revealing a relatively narrow isthmus connecting them, creating an unusual dumbbell shape; C-E) Coronal plans show slices at 15, 17, and 19; revealing the nature of the lesion, with specific emphasis on the “D” image highlighting the inter-lesional connection

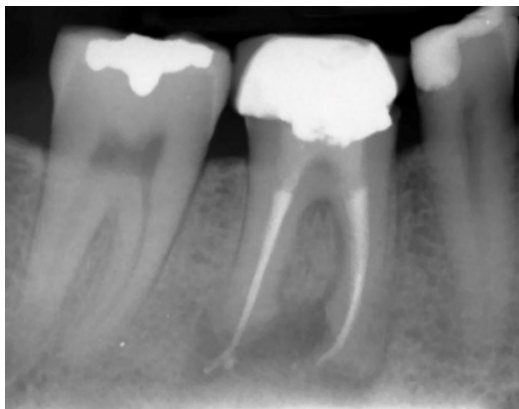


Figure 3. Nonsurgical endodontic retreatment. Nonsurgical endodontic retreatment was performed with the prosthetic crown in place. The access cavity was prepared through the crown, and the previous filling and gutta-percha were removed. The root canal system was thoroughly cleaned, shaped and obturated. An intra-orifice barrier using calcium-enriched mixture cement was inserted, followed by coronal restoration with resin-based dental composite restorative material. The access cavity was filled and sealed with a permanent filling

The use of advanced imaging, specifically CBCT, played a crucial role in refining the differential diagnosis by providing detailed three-dimensional views for a comprehensive assessment of the lesion’s characteristics.

The clinical examination and diagnosis concluded that AP originated from the tooth #46. Treatment choices, including tooth extraction/replacement and non-surgical/surgical endodontics, were explained to the patient, who chose the non-surgical option, as documented in his informed consent.

The treatment plan involved the retreatment of the root canals of the first molar identified as the causative tooth. The prosthetic crown was accessed, and under isolation, the previous filling and gutta-percha were completely removed. The working length of the canals was determined, and full-strength sodium hypochlorite was used as the irrigant of choice for all intermediary procedures. After root canal preparation, canal obturation was performed using zinc oxide eugenol sealer with lateral condensation technique; a sealer extrusion was observed. An intra-orifice barrier (calcium-enriched mixture cement;

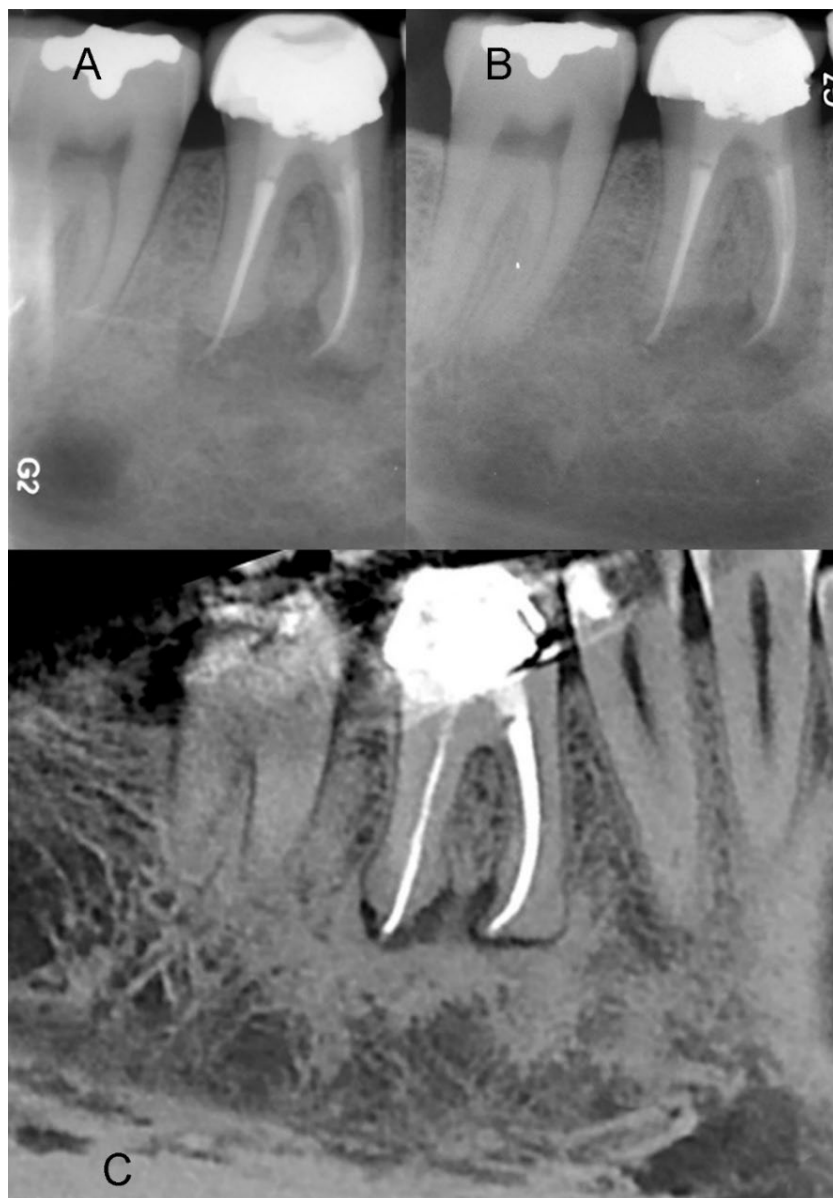


Figure 4. Follow-up radiographic evaluation; A) Six-month follow-up; showing slight resolution of both lesions; the patient reported total disappearance of symptoms; B) One-year follow-up radiograph; displaying almost complete resolution of endodontic lesions, replaced by newly formed bone; C) Cross-sectional views from CBCT at one-year follow-up; confirming the successful resolution of both lesions, with evidence of newly formed bone which filled the previously observed radiolucencies

BioniqueDent, Tehran, Iran) was placed followed by coronal restoration with resin-based dental composite (Figure 3).

Post-treatment follow-ups included visits at 1 week and concurrently, during which the patient reported the complete resolution of primary symptoms. At 6-month follow-up, clinical examination revealed the tooth to be asymptomatic and functional. Moreover, the radiograph showed a slight resolution of both lesions; aligning with the patient's complete disappearance of symptoms (Figure 4A).

At one-year follow-up, the tooth remained clinically asymptomatic and functional, with a significant reduction in radiolucent lesions within the apical region of the mandibular right first molar (Figure 4B). The obtained outcomes affirmed the success of the non-surgical retreatment approach. Cross-sectional views from CBCT at one-year follow-up further confirmed the resolution of both lesions, accompanied by the evidence of newly formed bone (Figure 4C).

Discussion

The present case report highlights the diagnostic and therapeutic challenges associated with a distant endodontic lesion; emphasising the critical role of advanced imaging techniques, namely CBCT. Traditional and conventional diagnostic methods, *e.g.*, periapical radiography, may fall short in revealing the complete extent and detailed characteristics of intricate endodontic lesions and cause flaws in the diagnosis and post-treatment follow-up limitations [7]. Furthermore, advanced technology greatly assists in detecting minor changes in hard tissues [8]. Additionally, bone destruction associated with endodontic infection can be observed on computed tomography before it can be detected on conventional radiographs [9]. In the current case, the initial radiographs revealed the suboptimal outcomes of previous compromised endodontic treatment in the first molar. However, an additional, distinct lesion beneath the second molar remained concealed due to its greater distance from the examined molars; emphasising the limitations of two-dimensional imaging techniques in capturing the complexities of remote lesions. Although a modified vertical positioning of the intraoral periapical radiograph aimed to enhance visibility, the true nature of the obscured lesion became well apparent only when CBCT was used. The three-dimensional views provided by CBCT unveiled an unusually/rare distant/large endodontic lesion with a narrow isthmus connecting the two parts; emphasising the pivotal role of advanced imaging in accurately diagnosing and characterising comparable atypical presentations. However, it should be noted that the routine use of CBCT for the detection of AP ought to be cautioned due to the associated high radiation exposure [10]. Thus, CBCT is recommended to be reserved for specific cases where the cause cannot be otherwise identified, acknowledging that its application sometimes did not help in diagnosis of endodontic lesions [11].

To manage the large endodontic lesions, a two-visit approach with the assistance of triple antibiotics has been recommended [12, 13]. However, given the complexity of the current case, a single-visit nonsurgical retreatment approach was chosen. The decision-making process involved weighing options; from tooth extraction and its subsequent replacement to non-surgical and surgical endodontics. The patient's choice of the nonsurgical approach emphasised the important role of patients participating in making treatment decisions and obtaining subsequent informed consent. The nonsurgical retreatment comprised cleaning, shaping and obturation of the root canal system complemented by the insertion of an intra-orifice barrier and application of a well-executed coronal seal,

both critical for successful outcomes [14]. The symptoms and postoperative pain significantly reduce within one week of the treatment [15]. Nonsurgical root canal (re)treatment may even heal large cyst-like periapical lesion [16] and can improve the oral health-related quality of life of patients having asymptomatic AP [17]. The success of the performed treatment was evident in the significant reduction of lesions within one year; aligned with the patient's reported resolution of his primary symptoms.

In obturation procedures, sealer extrusion, although not uncommon, is generally considered a minor complication. While its presence may initially raise concerns regarding potential inflammation or discomfort, studies have shown that the resorption of sealer over time often occurs naturally without adverse effects [18], as observed in the present case. This phenomenon underscores the dynamic nature of periapical tissues and their remarkable capacity for adaptation and healing. In the current case, although sealer extrusion occurred during the procedure, it did not have any significant implications for the treatment outcome.

The current case report contributes to the advancement of our understanding on endodontic pathology, specifically through addressing the complexities and achievements in managing distant endodontic lesions. In the aforementioned investigation, the use of CBCT played a pivotal role in unravelling the intricacies of the case; and highlighted the ongoing necessity for exploring advanced diagnostic tools in endodontic practice. Also, the case underscores the significance of tailoring treatment strategies to unique characteristics of each case; exemplifying the success of a nonsurgical approach in resolving a challenging endodontic scenario.

Conclusion

This case study offers significant insights into the diagnostic and therapeutic complexities associated with rare/distant endodontic lesions. It underscores the crucial role of advanced imaging techniques, particularly CBCT, in accurately diagnosing and characterizing such lesions. Additionally, the implementation of personalized treatment approaches, such as one-visit nonsurgical endodontic retreatment, is highlighted as a key factor in achieving successful outcomes. As endodontic practice evolves, the current case could encourage clinicians to adopt innovative diagnostic tools and personalised strategies for optimal treatment outcomes.

Acknowledgments

Not applicable

Conflict of interest

The authors of this manuscript claim that there are no conflicts of interest related to this study.

Funding support

No funding was received for this study.

Authors' contributions

SA, MJE, and AP contributed to the conception and design of the study. S.A. collected /analysed the clinical data, performed the radiographic examinations, and interpreted the imaging findings. SA drafted the manuscript, and MJE and AP critically revised it for important intellectual content. All authors approved the final version of the manuscript to be submitted for publication.

References

- Rosen E, Taschieri S, Del Fabbro M, Beitlitum I, Tsisis I. The Diagnostic Efficacy of Cone-beam Computed Tomography in Endodontics: A Systematic Review and Analysis by a Hierarchical Model of Efficacy. *J Endod*. 2015;41(7):1008-14.
- Venskutonis T, Plotino G, Juodzbalys G, Mickevičienė L. The importance of cone-beam computed tomography in the management of endodontic problems: a review of the literature. *J Endod*. 2014;40(12):1895-901.
- Asgary S, Marvasti LA. Necrosis of intact premolar caused by an adjacent apical infection: a case report. *Restor Dent Endod*. 2013;38(2):90-2.
- Asgary S, Roghanizadeh L. Partial necrosis consequence of the infection spreading from an adjacent apical periodontitis: a case report. *Iran Endod J*. 2018;13(3):420-3.
- Abe S, Muramatsu T. Use of Cone Beam Computed Tomography for Identification of a Distant Causative Tooth: An Unusual Case of an Apical Lesion from a Maxillary Premolar Mimicking That from Maxillary Incisors. *Case Rep Dent*. 2020;2020:8830524.
- Fujii R, Suehara M, Sekiya S, Miyayoshi N, Asai T, Morinaga K, Muramatsu T, Furusawa M. CBCT-based Diagnosis of Periapical Lesion of Maxillary First Premolar Mimicking That of Second Premolar. *Bull Tokyo Dent Coll*. 2016;57(4):291-7.
- Maia Filho EM, Calisto AM, De Jesus Tavearez RR, de Castro Rizzi C, Bezerra Segato RA, Bezerra da Silva LA. Correlation between the Periapical Index and Lesion Volume in Cone-beam Computed Tomography Images. *Iran Endod J*. 2018;13(2):155-8.
- Asgary S. Micro-computed Tomography Assessment of Full Pulpotomy in a Mature Molar after Five Years: A Case Report. *Iran Endod J*. 2022;17(4):223-4.
- Kiarudi AH, Eghbal MJ, Safi Y, Aghdasi MM, Fazlyab M. The applications of cone-beam computed tomography in endodontics: a review of literature. *Iran Endod J*. 2015;10(1):16-25.
- Scarfè WC, Farman AG. What is cone-beam CT and how does it work? *Dent Clin North Am*. 2008;52(4):707-30, v.
- Fazlyab M, Asgary S. Failure of Cone-Beam Computed Tomography in Detection of Fiber Post Perforation. *Iran Endod J*. 2017;12(3):396-400.
- Asgary S, Parhizkar A. Healing of large endodontic lesions using a new combination of triple antibiotics: A case report. *Clin Case Rep*. 2023;11(1):e6879.
- Asgary S, Parhizkar A. Healing of Large Endodontic Lesions Using Long-Term Application of a New Combination of Triple Antibiotics: A Series of Cases. *Case Rep Dent*. 2023;2023:6889019.
- Mehta S, Ramugade M, Abrar S, Sapkale K, Giuliani V, Burbano Balseca MJ. Evaluation of coronal microleakage of intra-orifice barrier materials in endodontically treated teeth: A systematic review. *J Conserv Dent*. 2022;25(6):588-95.
- Scardini IL, Sarra G, Braga MM, Dos Santos M, Freire LG. The Effect of Number of Visits, Use of Solvent and Gutta-percha Removal Technique on Postoperative Pain following Nonsurgical Endodontic Retreatment; A Systematic Review and Meta-analysis. *Iran Endod J*. 2023;18(2):71-84.
- Ghorbanzadeh S, Ashraf H, Hosseinpour S, Ghorbanzadeh F. Nonsurgical Management of a Large Periapical Lesion: A Case Report. *Iran Endod J*. 2017;12(2):253-6.
- do Nascimento AL, Weissheimer T, Gomes MS, Pereira JR, da Rosa RA, Reis Só MV. Impact of Nonsurgical Treatment of Asymptomatic Apical Periodontitis on the Oral Health-related Quality of Life: A Prospective Study. *Iran Endod J*. 2022;17(4):179-84.
- Goldberg F, Cantarini C, Alfie D, Macchi R, Arias A. Relationship between unintentional canal overfilling and the long-term outcome of primary root canal treatments and nonsurgical retreatments: a retrospective radiographic assessment. *Int Endod J*. 2020;53(1):19-26.

Please cite this paper as: Eghbal MJ, Parhizkar A, Asgary S. Beyond Convention; an Unprecedented Distant Endodontic Lesion: A Case Report. *Iran Endod J*. 2024;19(2): 124-9. *Doi:* 10.22037/iej.v19i2.44860.