



# The Caliber of Optociliary Shunt Vessels Is Associated with Macular Blood Flow and Visual Acuity in Central Retinal Vein Occlusion

Masanori Kanai, MD,<sup>1</sup> Susumu Sakimoto, MD, PhD,<sup>1,2</sup> Chikako Hara, MD, PhD,<sup>1</sup> Yoko Fukushima, MD, PhD,<sup>1,2</sup> Kaori Sayanagi, MD, PhD,<sup>1</sup> Kentaro Nishida, MD, PhD,<sup>1</sup> Hirokazu Sakaguchi, MD, PhD,<sup>1</sup> Kohji Nishida, MD, PhD<sup>1,2</sup>

**Purpose:** To define the role of optociliary shunt vessels (OSVs) in eyes with central retinal vein occlusion (CRVO) using OCT angiography (OCTA) with macular parameters.

**Design:** Retrospective, observational, consecutive case series.

**Participants:** Forty-one eyes in 38 consecutive patients with CRVO were analyzed in this study.

**Methods:** Optic disc and macula were imaged by swept-source OCTA (3 × 3 mm) as well as by high-quality fundus photography.

**Main Outcome Measures:** We compared macular vessel density (VD) and visual acuity between eyes in which OSVs developed and those in which they did not. Furthermore, we measured the diameter of the OSVs and analyzed the correlation with macular VD and visual acuity.

**Results:** Optociliary shunt vessels were found in 25 eyes (61%). Central retinal vein occlusion with OSVs did not show any statistical difference compared with CRVO without OSVs in either macular VD of the total retina ( $0.31 \pm 0.07$  and  $0.26 \pm 0.09$ , respectively;  $P = 0.0937$ ) or final best-corrected visual acuity (BCVA) ( $0.30 \pm 0.43$  logarithm of the minimum angle of resolution [logMAR] and  $0.59 \pm 0.54$  logMAR, respectively;  $P = 0.0705$ ). The mean OSV diameter was  $71 \pm 30 \mu\text{m}$  in CRVO with OSV. The diameter of the OSVs was correlated positively with superficial VD ( $r = 0.443$ ;  $P = 0.027$ ), deep VD ( $r = 0.494$ ;  $P = 0.012$ ), and total VD ( $r = 0.491$ ;  $P = 0.013$ ). Furthermore, the OSV diameter was also negatively correlated with BCVA (logMAR) at the final visit ( $r = -0.531$ ;  $P = 0.006$ ).

**Conclusions:** The results demonstrated that the diameter of the OSVs was associated with macular VD and visual acuity in patients with CRVO. The development of large OSVs on the optic disc may be a good indicator of the maintenance of blood flow in the macula. *Ophthalmology Science* 2022;2:100083 © 2021 by the American Academy of Ophthalmology. This is an open access article under the CC BY-NC-ND license (<http://creativecommons.org/licenses/by-nc-nd/4.0/>).

Optociliary shunt vessels (OSVs), also referred to as disc collateral vessels, retinociliary collaterals on the optic disc, optociliary veins, or retinochoroidal collaterals,<sup>1–15</sup> are vessels located on the optic disc, reportedly allowing retinal venous blood to bypass the obstructed central retinal vein through the choroidal circulation.<sup>14</sup> Optociliary shunt vessels are widely known to develop in the course of central retinal vein occlusion (CRVO) as well as optic nerve meningioma and papilledema.<sup>3,8,12</sup> Although not much is known about the physiologic significance of OSVs in CRVO, it has been postulated that the pressure gradient between an obstructed vessel and neighboring unobstructed vessel can cause the flow of blood through collateral channels in retinal vein occlusion.<sup>16</sup> A histologic study revealed that the collaterals typically form on or adjacent to the optic nerve and connect the retinal veins to the choroidal venous system.<sup>12</sup> Additionally, an indocyanine green angiography study revealed that blood

flow was drained through retinal veins into vortex veins and choroidal circulation through OSVs.<sup>14</sup>

Earlier reports have shown that OSVs (diagnosed by color fundus photography or fundus ophthalmoscopy) were found in 30% to 50% of eyes with CRVO.<sup>5,15</sup> However, for visual prognosis in CRVO and OSVs, assertions in the literature are conflicting. Some authors have reported better visual acuity in eyes with CRVO with OSVs.<sup>1,2,10</sup> Furthermore, recent articles indicate an association of collaterals with worse prognosis in CRVO.<sup>5–7,9,11,13,15</sup> Thus, the clinical significance of OSVs should be re-evaluated with OCT, which has not been done in previous studies. Moreover, the visual prognosis of CRVO with OSVs, under the effect of anti-vascular endothelial growth factor (VEGF) therapy, remains elusive.

OCT angiography (OCTA) is a recently developed noninvasive imaging method that visualizes microvascular abnormalities at a high resolution without the use of dyes.<sup>17</sup> The

Table 1. Patient Characteristics

Parameter	Data
Age (yrs)	76 ± 9.3
Gender (male/female)	17/21
Ischemic type	11 (27)
BCVA (logMAR)	
Initial visit	0.38 ± 0.42
Last examination	0.41 ± 0.50
Pretreatment CST (μm)	537 ± 227
OSV	25 (61)
Macular VD in macula 3 × 3 mm	
SCP	0.29 ± 0.08
DCP	0.25 ± 0.08
Total retina	0.29 ± 0.08
Follow-up (mos)	35 ± 30
No. of anti-VEGF injections	8.8 ± 9.6

BCVA = best-corrected visual acuity; CST = central subfield thickness; DCP = deep capillary plexus; OSV = opticiliary shunt vessel; SCP = superficial capillary plexus; VD = vessel density; VEGF = vascular endothelial growth factor.

Data are presented as no., no. (%), or mean ± standard deviation.

technique creates an image of retinal blood flow using the movement of red blood cells.<sup>18</sup> This technology, combined with B scan, allows segmented evaluation of macular capillary networks. With these advantages, OCTA should potentially be more efficacious than color fundus photography, indocyanine green angiography, or fluorescein angiography for detecting OSVs; OCTA provides not only an image of the microvasculature without dye leakage, but also 3-dimensional information of OSVs in the optic disc. The purpose of this study was to redefine the significance of OSVs delineated by OCTA on the visual outcomes in eyes with CRVO.

## Methods

### Study Design and Setting

The institutional review board of Osaka University Hospital approved this study, which adhered to the tenets of the Declaration of Helsinki. All participants provided informed consent. This was a retrospective, observational, consecutive case series. The participants were patients who visited Osaka University Hospital from October 2018 through June 2020. The inclusion criteria

Table 2. Optociliary Shunt Vessel Characteristics

Parameter	Data
Maximum diameter of OSV (μm)	71 ± 30
Maximum diameter of central venous first branch (μm)	101 ± 22
Maximum OSV diameter to maximum central venous first branch diameter ratio	0.74 ± 0.37
Distribution from optic disc (superior/nasal/inferior/temporal)	9/11/6/3

OSV = opticiliary shunt vessel.

Data are presented as no. or mean ± standard deviation.

were patients with CRVO or hemi-CRVO who underwent both 3 × 3-mm OCTA and fundus photography of the disc and macula at the same visit, with follow-up of more than 3 months. All the patients received the appropriate pro re nata anti-VEGF therapy; if they had ischemic CRVO, they underwent panretinal photocoagulation before the examinations. The follow-up period was defined as the term between the first visit to our institution with the aim of treating CRVO and the visit for fundus photography and OCTA examination of the disc and macula. The exclusion criteria were as follows: any previous intraocular surgery excluding uncomplicated phacoemulsification, history of any fundus and optic nerve diseases other than open-angle glaucoma with well-tolerated intraocular pressure by topical medication, history of inflammatory eye disorders, and eyes with poor-quality OCT and OCTA scans and fundus photographs. Patients who could not receive appropriate pro re nata anti-VEGF therapy also were excluded. Eyes with optic disc neovascularization evaluated by fluorescein angiography (detailed below) also were not included in this study.

### OCT Angiography

OCT angiography images were obtained using swept-source OCT (Plex Elite 9000; Carl Zeiss Meditec, Inc). En face images of the retinal vessels were made from the total retina, superficial capillary plexus (SCP), and deep capillary plexus (DCP) based on automated layer segmentation performed by the software installed in the OCTA device. Manual segmentation was performed to assess the total retina, SCP, and DCP exactly, if needed. To compute vessel density (VD), the 3 × 3-mm OCTA images were changed to 8 bits and a value of 255 (complete white) was assigned to all pixels with a positive gray level and a value of 0 (complete black) to the others by the Otsu auto local threshold method (radius, 75 pixels; parameter 1, default; parameter 2, default) using ImageJ software.<sup>19</sup> Vessel density was calculated as the ratio of the space occupied by vessels (white pixels) divided by the total image space (all pixels) in the binary image of the total retina, SCP, and DCP. Central subfield thickness (CST) was automatically measured using spectral-domain OCT software (Cirrus 6000; Carl Zeiss Meditec, Inc). When CST could not be measured correctly, we measured it manually.

### Optociliary Shunt Vessels

Optociliary shunt vessels were defined as venous vessels located near the edge of the optic disc, communicating retinal vessels to peripapillary choroidal vessels. Masked graders (M.K., S.S.) used OCTA images—en face images of neural retina and the neural retina and choroid and B scan images with flow overlay and complementary color fundus photographs—to identify OSVs. We first checked the neural retinal slab to confirm if we identified suspected OSV. Subsequently, we searched for the connection between OSV and the choroidal vessels using the choroidal slabs. If differences occurred between the 2 graders, another retina specialist (C.H.) resolved the ambiguity. The diameter of the OSVs was defined as the diameter on the thickest part of the largest OSV. The central venous first branches were defined as the nearest vessels separated from the central retinal vessel. The maximum diameter of these vessels was measured using ImageJ software based on 3 × 3-mm OCTA images. We calculated the ratio of the largest OSV diameter to the central venous first branch diameter to show how large OSVs were compared with patients' inherent retinal vessels. The distribution of OSVs in the 4 quadrants around the optic disc also was investigated to clarify whether the OSV in the nasal quadrant affects the visual outcomes, as reported previously.<sup>14</sup>

Table 3. Differences in Optociliary Shunt Vessel Formation

Parameter	Optociliary Shunt Vessel Present (n = 25)	Optociliary Shunt Vessel Absent (n = 16)	P Value
BCVA (logMAR)			
First visit	0.36 ± 0.44	0.41 ± 0.39	0.6849
Last examination	0.30 ± 0.43	0.59 ± 0.54	0.0705
VD (%)			
Total retina	0.31 ± 0.07	0.26 ± 0.09	0.0937
SCP	0.30 ± 0.07	0.26 ± 0.09	0.0779
DCP	0.27 ± 0.07	0.23 ± 0.09	0.1671
Follow-up (mos)	38 ± 30	32 ± 31	0.582
Pretreatment CST (μm)	520 ± 229	564 ± 222	0.5508
Ischemic type no. (%)	4 (17)	7 (33)	0.0504

BCVA = best-corrected visual acuity; CST = central subfield thickness; DCP = deep capillary plexus; logMAR = logarithm of the minimum angle of resolution; SCP = superficial capillary plexus; VD = vessel density. Data are presented as no. (%) or mean ± standard deviation.

### Definition of Ischemic Central Retinal Vein Occlusion

Fluorescein angiography was performed in accordance with a standard protocol after intravenous injection of 5 mL of 10% sodium fluorescein into 1 antecubital vein using Optos 200Tx, which produced 200° widefield images. The conformations of the retinal vessels and hypofluorescent areas were assessed in the early phase (approximately 2 minutes after intravenous fluorescein injection). Optic disc neovascularization appears as a fine lacy network of vessels with significant dye leakage and late hyperfluorescence. The retinal nonperfusion area was defined as parts of the fundus devoid of retinal arterioles or capillaries and was detected by angiographic characteristics such as a continuous area of hypofluorescence resulting from retinal capillary loss and precapillary arteriole and postcapillary venule obstruction.<sup>20</sup> We differentiated ischemic CRVO from nonischemic CRVO based on the following criteria: nonperfusion area of > 10 disc diameters.<sup>7</sup>

### Treatments

Patients received injections of an anti-VEGF agent—ranibizumab (Lucentis, Novartis International AG) or aflibercept (Eylea, Bayer AG)—for macular edema in a pro re nata fashion if it was thought to be necessary. The eyes with ischemic CRVO underwent pan retinal photocoagulation.

### Statistical Analysis

A *t* test was used to compare best-corrected visual acuity (BCVA), CST, follow-up period, VD in the total retina, SCP, and DCP with or without OSVs. Regarding the distribution of OSVs on the optic disc, we also used *t* tests to determine whether OSVs exist in the nasal quadrant, in 1 quadrant, or in multiple quadrants. The relationship between the maximum diameter of OSVs and logMAR BCVA at the first visit and final visit, VD in the total retina, and SCP and DCP were determined using Spearman’s rank correlation coefficient. The Fisher exact test was used to compare the 2 groups regarding whether they were of the ischemic type.

## Results

### Patients

Forty-one eyes of 38 patients (17 men and 21 women; mean age, 75.8 years; range, 56–91 years) were enrolled. Nine eyes (20%) were diagnosed with hemi-CRVO. Eleven eyes (27%) had ischemic CRVO. The mean follow-up period was 35.5 ± 30.2 months. Before OCTA examination, 37 eyes (90%) received anti-VEGF therapy. The mean number of anti-VEGF treatments before examination per eye was 8.8 ± 9.6. Patient characteristics are shown in Table 1.

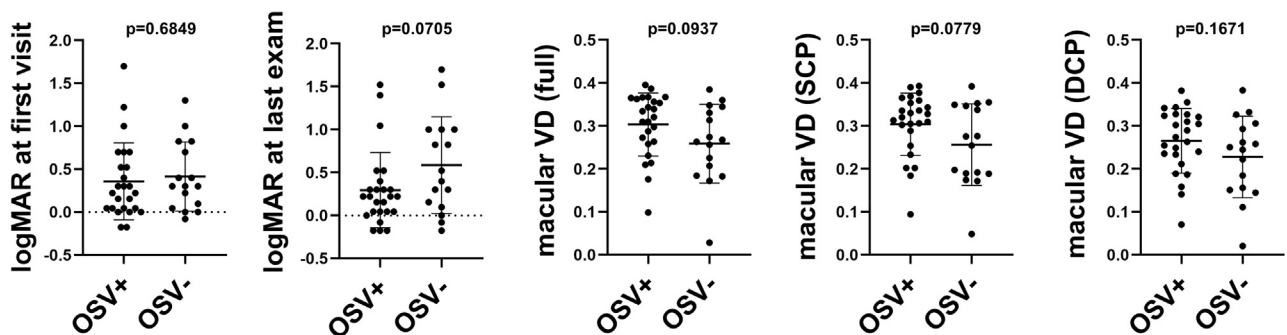
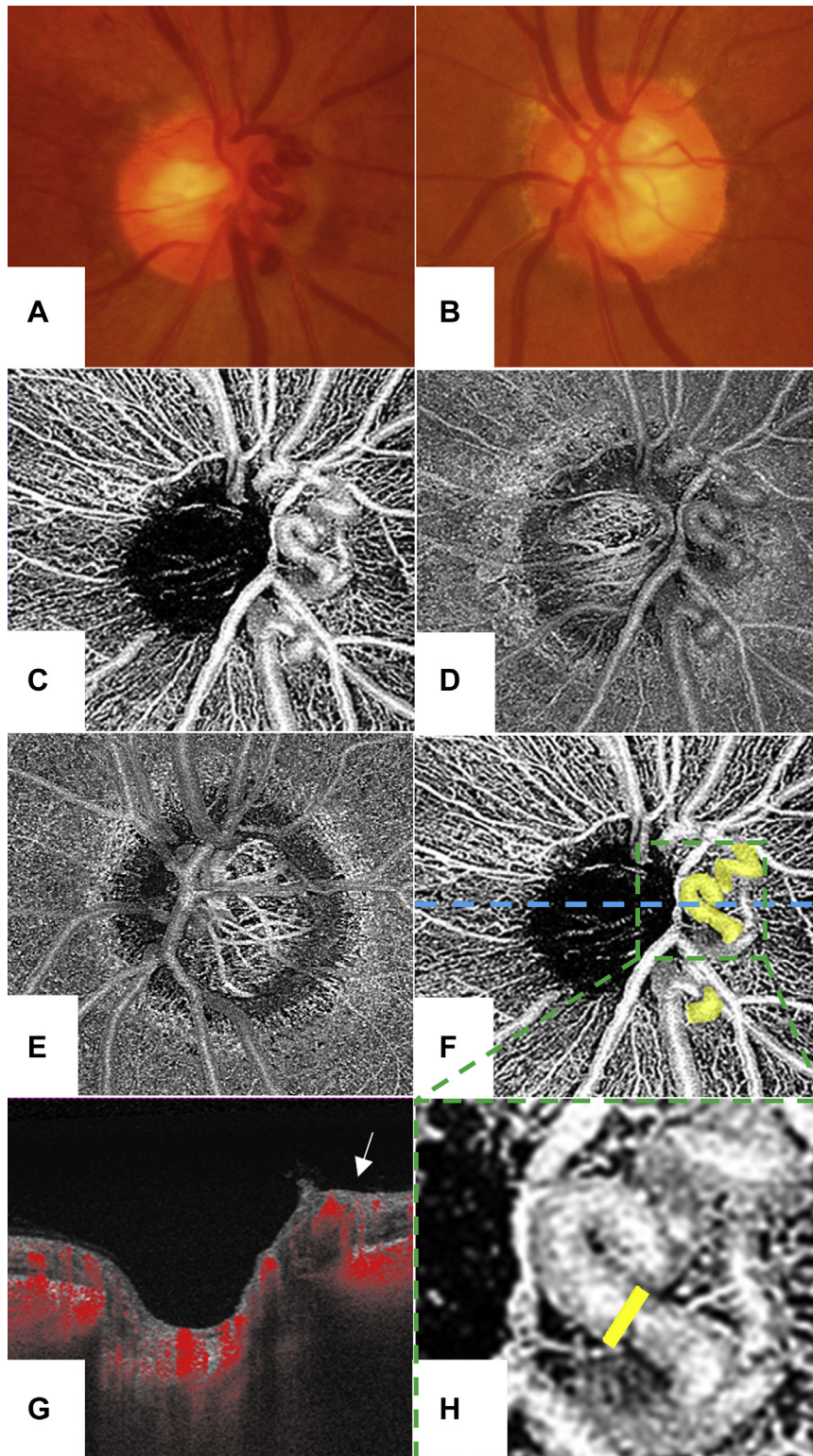
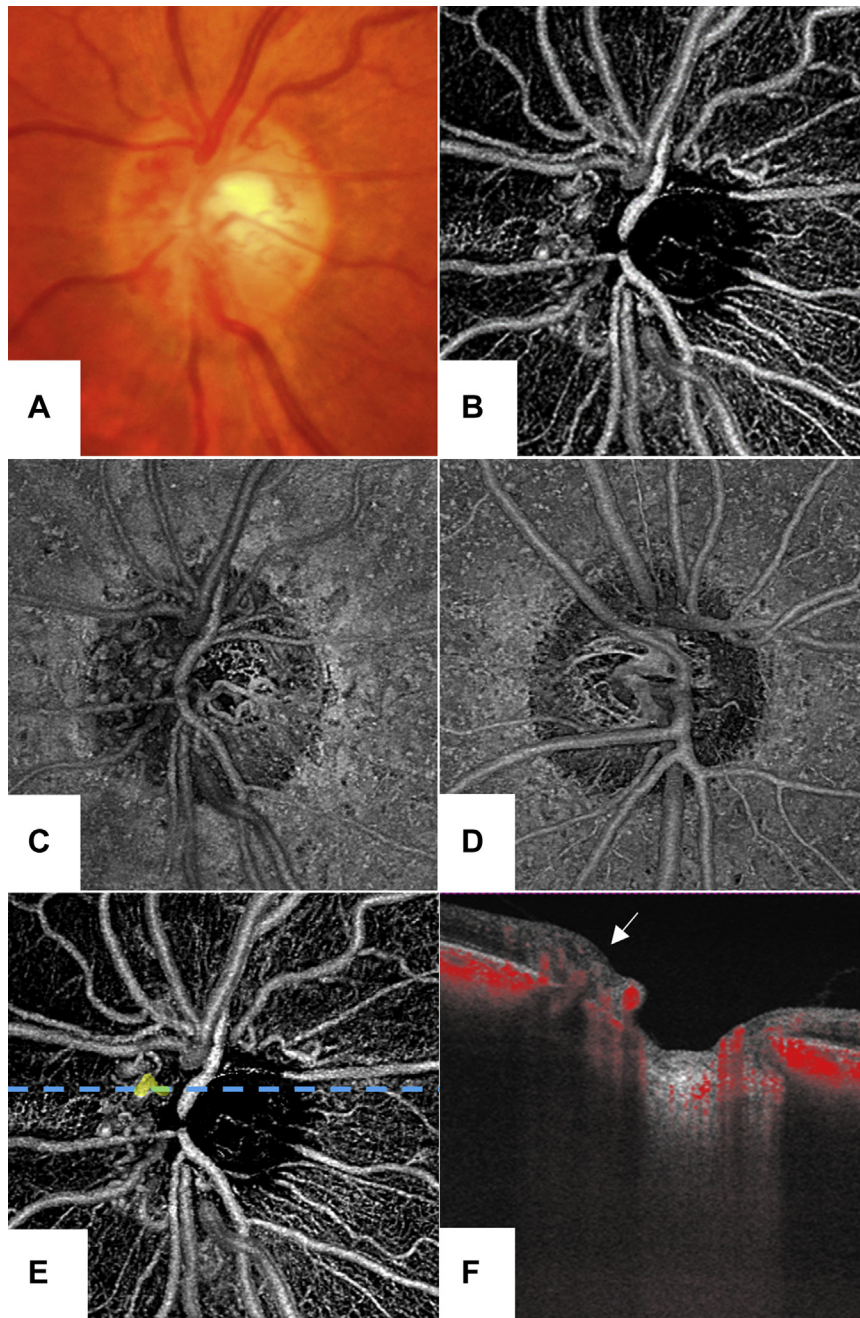


Figure 1. Scatterplots showing best-corrected visual acuity (BCVA; in logarithm of the minimum angle of resolution [logMAR]) at first visit and final visit, macular vessel density (VD) in total retina, and superficial capillary plexus (SCP) and deep capillary plexus (DCP) with (+) or without (–) optociliary shunt vessels (OSVs). All the parameters were scattered as well, independent of the presence or absence of OSVs.



**Figure 2.** Central retinal vein occlusion (CRVO) associated with large opticiliary shunt vessels (OSVs). **A, B,** Fundus photographs of optic disc in **(A)** an eye with CRVO and **(B)** the contralateral eye. **C, D,** En face  $3 \times 3$ -mm OCT angiography image of the optic disc showing large OSVs in the nasal disc: **(C)** neural retina and **(D)** neural retina and choroid. **E,** OCT angiography image of optic disc in the contralateral eye. **F,** En face  $3 \times 3$ -mm OCT angiography image showing OSVs defined in this study in yellow in the same image as **(C)**. **G,** B scan image with flow dot (red) corresponding to the section of blue dashed bar in **(F)**. White arrow shows the section of OSV. **H,** Magnified image of green dashed square in **(F)**. Diameter of OSV shown as yellow bar.



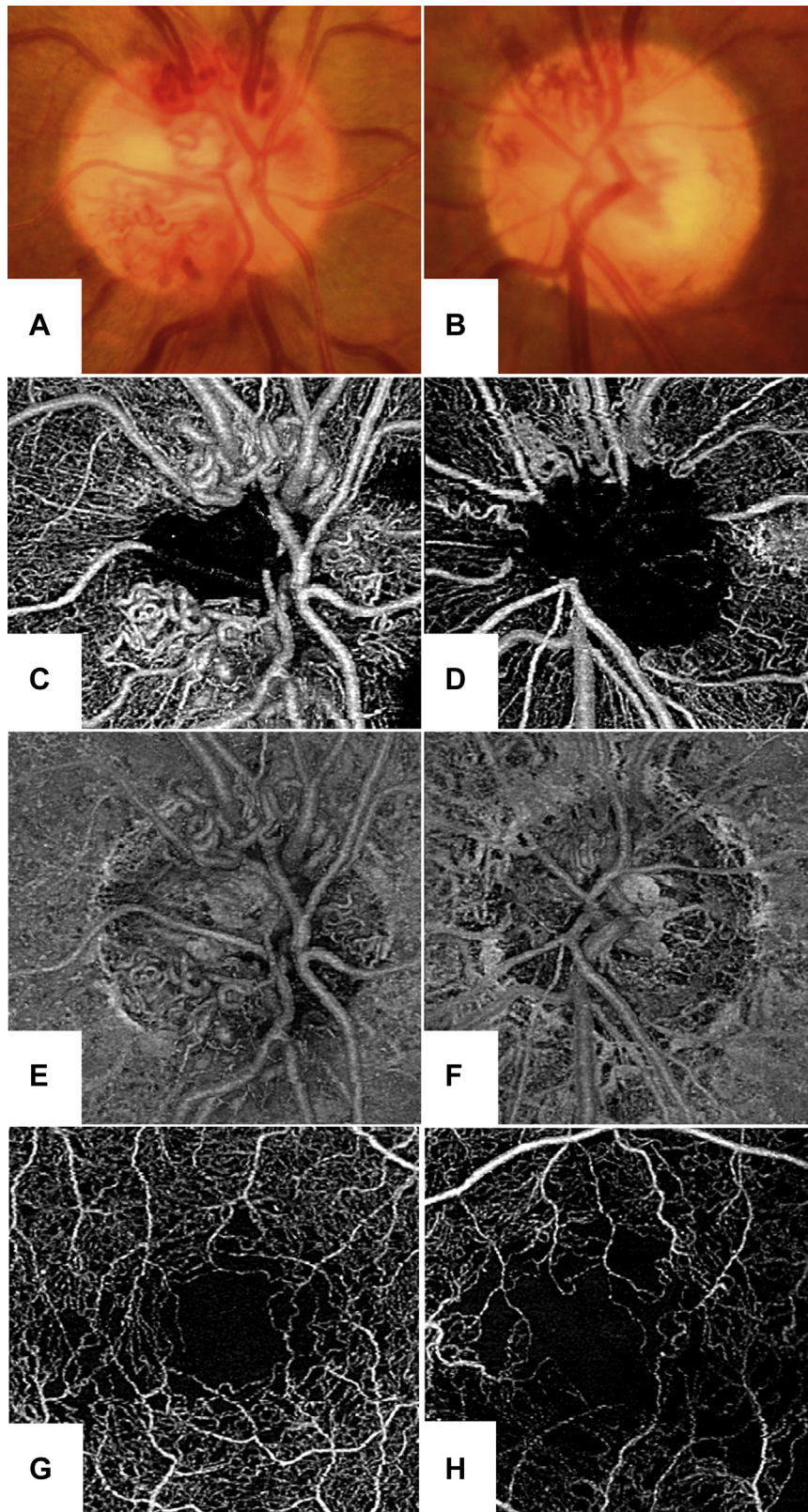
**Figure 3.** Central retinal vein occlusion (CRVO) associated with small optociliary shunt vessels (OSVs). **A**, Fundus photograph of optic disc in an eye with CRVO. **B**, **C**, En face 3 × 3-mm OCT angiography images of the optic disc showing small OSVs in the nasal disc. **D**, OCT angiography image of optic disc in the contralateral eye. **E**, En face 3 × 3-mm OCT angiography image showing an OSV defined in this study in yellow in the same image of (**B**). **F**, B-scan image with flow dot (red) corresponding to the section of blue dashed bar in (**E**). White arrow shows the section of OSV.

### Optociliary Shunt Vessels

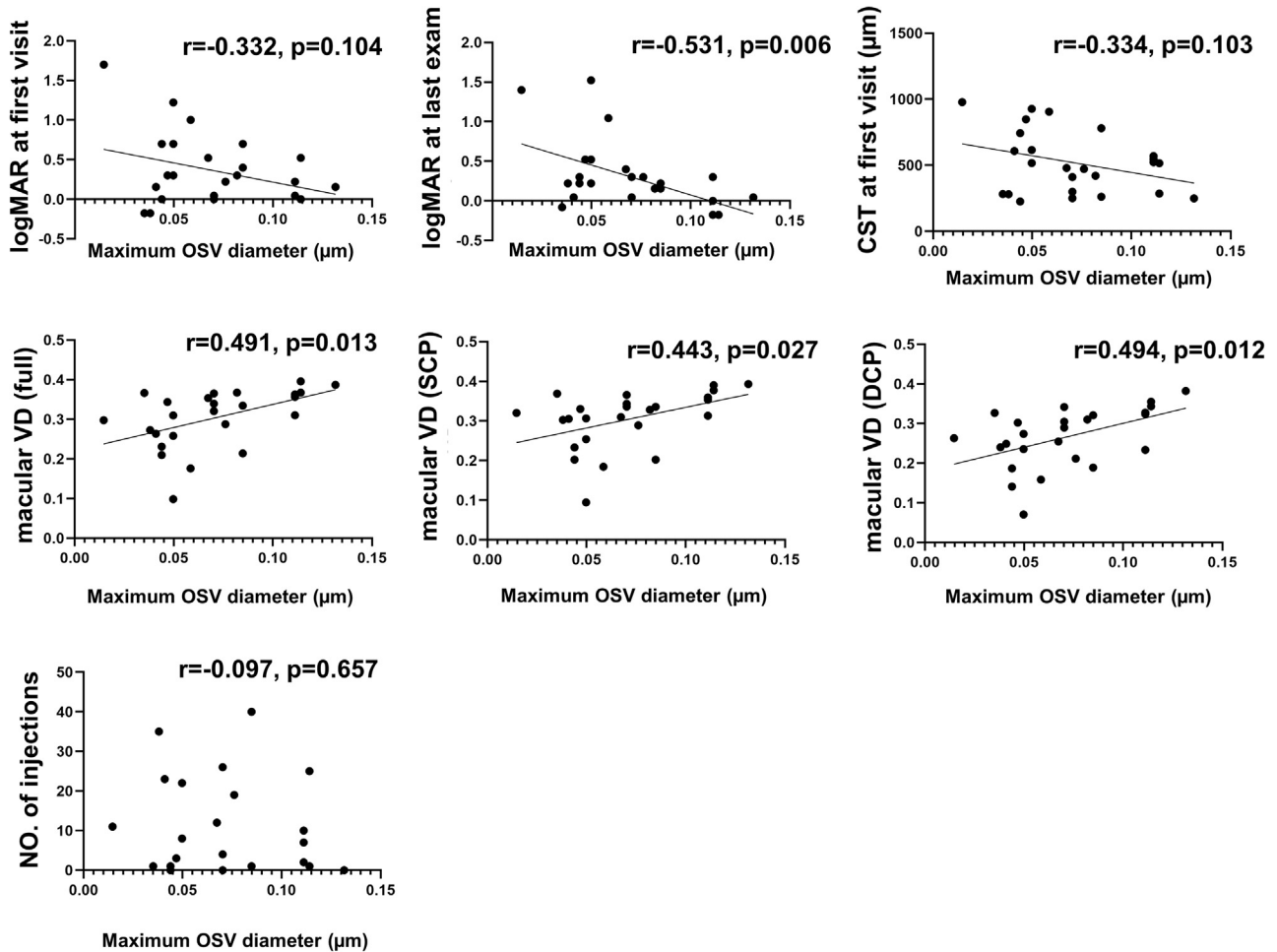
Optociliary shunt vessels were found in 25 eyes (61%). The diameter of the OSVs was  $70.8 \pm 30.2 \mu\text{m}$  (range, 14.6–131.6  $\mu\text{m}$ ). The diameter of the central venous first branch was  $100.7 \pm 22.2 \mu\text{m}$  (range, 79.0–102.3  $\mu\text{m}$ ). The OSV diameter to central venous first branch diameter ratio was  $0.74 \pm 0.37$  (range, 0.29–1.70). The results are shown in [Table 2](#).

### Comparison between Presence or Absence of Optociliary Shunt Vessels and Patient Demographic Data

As shown in [Table 3](#), logMAR BCVA at the first visit and final visit, VD in the total retina, SCP and DCP, follow-up period, and CST were compared with and without OSVs. No statistically significant differences were found between the 2 groups in any parameters. Vessel densities in the total



**Figure 4.** Images from a 75-year-old woman with central retinal vein occlusion (CRVO) in both eyes. The patient was referred to our clinic because of CRVO in left eye, and 2 months later, she demonstrated CRVO in the right eye as well. She started anti-vascular endothelial growth factor therapy in a pro re nata fashion and Snellen visual acuity at the OCT angiography (OCTA) examination was 20/40 in the right eye and 20/400 in the left eye. **A, B,** Fundus photographs showing the optic disc. **C, D,** OCT angiography images showing the neural retina in the optic disc. **E, F,** OCT angiography images of neural retina and choroid in the optic disc. **G, H,** En face OCTA images showing the macular lesion. **A, C, E, G,** Right eye associated with CRVO and large opticiliary shunt vessels (OSVs). **B, D, F, H,** Left eye associated with CRVO and small OSVs. Note that macular vessel density is decreased in the left eye compared with the right eye.



**Figure 5.** Scatterplots showing the maximum diameter of optociliary shunt vessels (OSVs), best-corrected visual acuity (BCVA; in logarithm of the minimum angle of resolution [logMAR]) at the first and final visits, central subfield thickness (CST), vessel density (VD) in the total retina, superficial capillary plexus (SCP) and deep capillary plexus (DCP), and number of anti-vascular endothelial growth factor injections. The maximum diameter of OSVs was significantly negatively associated with logMAR BCVA at final visit and significantly positively with VD in the total retina, SCP, and DCP in the group with OSVs.

retina and SCP were likely to be higher in the group with OSVs than in the group without them, but the difference was not statistically significant ( $P = 0.0937$  and  $P = 0.0779$ , respectively; Fig 1). The logMAR BCVA at the final visit was likely to be lower in the group with OSVs than in the group without them, but this was not statistically significant ( $P = 0.0705$ ). Fewer ischemic type eyes were found among the eyes with OSVs than among those without OSVs ( $P = 0.0504$ ).

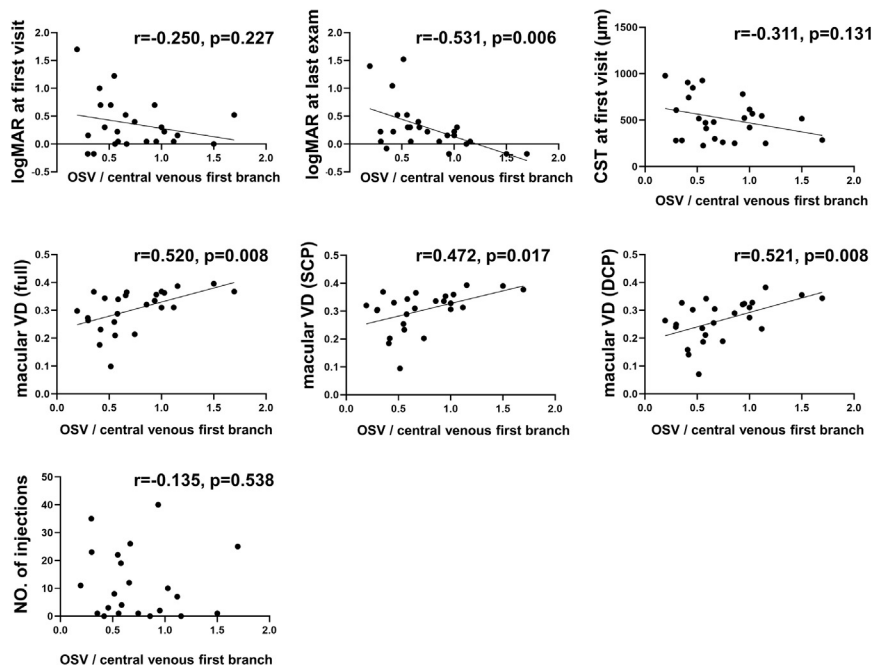
### The Maximum Diameter of Optociliary Shunt Vessels

The diameter of the OSVs was negatively associated with logMAR BCVA at the final visit ( $r = -0.531$ ;  $P = 0.006$ ) and was positively associated with VD in the total retina ( $r = 0.491$ ;  $P = 0.013$ ), SCP ( $r = 0.443$ ;  $P = 0.027$ ), and DCP ( $r = 0.494$ ;  $P = 0.012$ ) in the group with OSVs (Figs 2, 3, 4, and 5). The ratio of the OSV diameter to the central venous first branch diameter was negatively

associated with logMAR BCVA at the final visit ( $r = -0.531$ ;  $P = 0.006$ ) and was positively associated with VD in the total retina ( $r = 0.520$ ;  $P = 0.008$ ), SCP ( $r = 0.472$ ;  $P = 0.017$ ), and DCP ( $r = 0.521$ ;  $P = 0.008$ ; Fig 6). However, logMAR BCVA at the first visit and CST were not correlated with the maximum diameter of OSVs or the ratio of the OSV diameter to the central venous first branch diameter. The number of anti-VEGF treatments was not correlated with the maximum OSV diameter ( $r = -0.097$ ;  $P = 0.657$ ), CV diameter ( $r = 0.089$ ;  $P = 0.682$ ), or the ratio of the OSV diameter to the central venous first branch diameter ( $r = -0.134$ ;  $P = 0.538$ ).

### Distribution of Optociliary Shunt Vessels on Optic Disc

Optociliary shunt vessels were found in the optic disc in the superior quadrant in 9 eyes, in the nasal quadrant in 11 eyes, in the inferior quadrant in 6 eyes, and in the temporal quadrant in 3 eyes. Only 3 eyes showed OSVs in 2

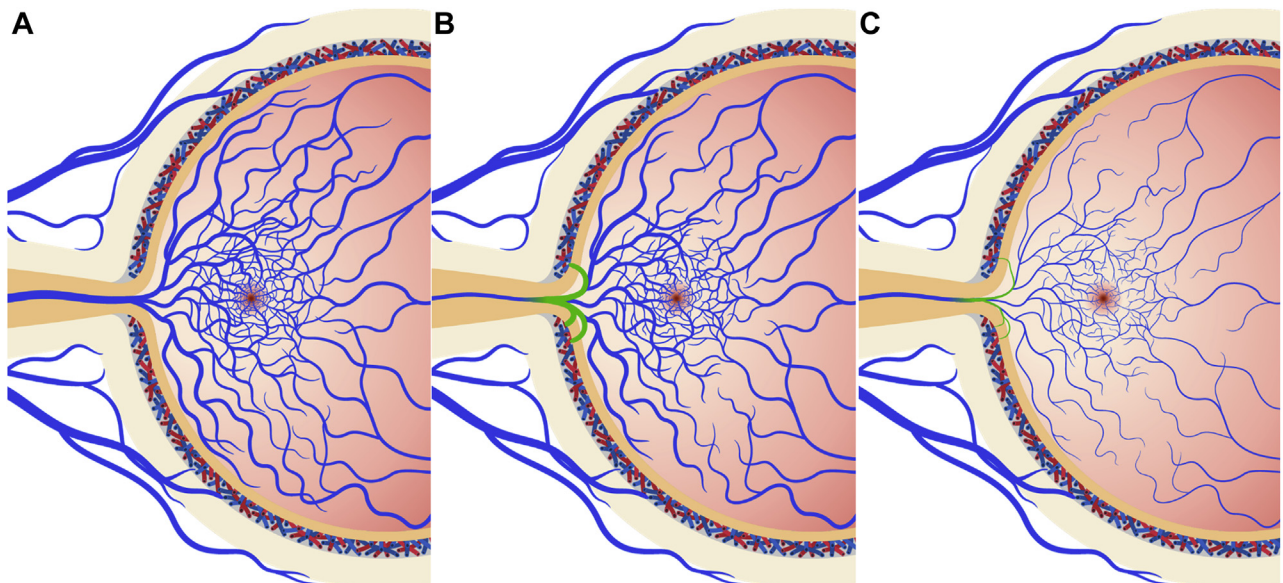


**Figure 6.** Scatterplots showing the ratio of the largest opticiliary shunt vessel (OSV) diameter to the central venous first branch diameter, best-corrected visual acuity (BCVA; in logarithm of the minimum angle of resolution [logMAR]) at first and final visits, central subfield thickness (CST), vessel density (VD) in total retina, superficial capillary plexus (SCP) and deep capillary plexus (DCP), and number of anti-vascular endothelial growth factor injections. The ratio of the largest OSV diameter to the central venous first branch diameter was significantly negatively associated with logMAR BCVA at the final visit and significantly positively with VD in the total retina, SCP, and DCP in the group with OSVs.

quadrants or more. We analyzed whether OSVs in the nasal quadrant and in 1 quadrant or more were related to logMAR BCVA at the first visit and final visit, VD in the total retina, SCP and DCP, and CST. No statistically significant differences were found between the groups.

## Discussion

In the current study, we first analyzed OSVs using OCTA in eyes with CRVO. High-quality images obtained by OCTA technologies enabled us to measure the diameter of the



**Figure 7.** Schematic diagrams showing the retinal venous system. **A**, Normal retinal vessels and macular blood flow without opticiliary shunt vessels (OSVs). **B**, **C**, Eyes with central retinal vein occlusion and OSVs (green vessels). Large OSVs can compensate for narrowed venous drainage route and improve macular blood flow. **B**, Small OSVs cannot maintain plenty of venous bloodstream. **C**, Macular blood flow is severely damaged.



OSVs, and that diameter (but not the presence or absence of OSVs) was significantly associated with visual outcomes in CRVO. More shunted blood flow featured by the larger diameter of OSVs could potentially explain amelioration of macular perfusion and subsequently could lead to better visual outcomes.

In this series, we found OSVs in 61% of eyes with CRVO, which was a relatively higher proportion compared with that of previous reports.<sup>1,2,4-7,11,15</sup> Many studies that aimed to characterize OSVs were conducted using fundus photography or fundus ophthalmoscopy, which can be affected by numerous factors such as optic media, disc hemorrhage, disc edema, and even the ability of photographic cameras. OCT angiography provides clearer images of vessels than color fundus photography; thus, we might have observed a relatively higher rate of incidence of OSVs in CRVO.

An impression existed among previous ophthalmologists that the presence of OSVs contributes to better visual prognosis in CRVO by improving the retinal perfusion through bypassing the occlusion (Fig 7). Earlier studies suggested that disc collaterals contribute to a better prognosis in eyes with CRVO.<sup>1,2,4,10</sup> However, a previous natural history study by Hayreh et al<sup>7</sup> documented that OSVs developed in eyes with nonischemic CRVO and were associated with poorer visual outcomes than eyes in which collaterals did not develop. The authors discussed that the development of OSVs depends on the site of occlusion; that is, in mild CRVO, if the site of occlusion in the optic nerve occurs downstream to the central retinal vein, a greater number of tributaries within the optic nerve are available to establish collateral circulation. In contrast, in severe CRVO, the closer the site of occlusion to the lamina cribrosa, namely upstream to the central retinal vein, the fewer tributaries are available in the optic nerve to establish collateral circulation. Previous large clinical randomized trials that evaluated the efficacy of intravitreal triamcinolone for CRVO revealed that collateral channels on the disc were neither necessary nor sufficient for improved vision after CRVO.<sup>15</sup> In the study cohort, we also observed both very mild nonischemic CRVO and severe ischemic CRVO in eyes without any OSVs, so that more variation was found in those without OSVs compared with those with OSVs (see VD graphs in

Fig 1). However, larger collaterals were significantly associated with better macular perfusion and visual outcomes in patients with CRVO and OSVs. This study aimed to show if the visual outcomes were affected by the diameter of the OSVs in CRVO treated with anti-VEGF therapy.

Treatment of macular edema resulting from retinal vein occlusion has benefited greatly from the development of specific antagonists of VEGF.<sup>21</sup> The protective effects of anti-VEGF therapy on many pathologic features in retinal vein occlusion may result in different outcomes from previous reports describing the role of OSVs. We still have no answer regarding how OSVs develop in CRVO and why OSVs do or do not develop in CRVO. However, in the case of OSVs developing in CRVO, larger collaterals can improve retinal circulation, draining the congested blood flow.

Takahashi et al<sup>14</sup> reported that the extraocular drainage routes of OSVs were nasal vortex veins (10/10 eyes) and temporal vortex veins (3/10 eyes). These findings may suggest that nasal vortex veins are important as drainage routes. However, presence of OSVs on the nasal side did not improve macular VD or visual acuity, any more than in the other sides in our study. Moreover, OSVs at more distributions were not significantly related to any parameters. This may be because we could not fully visualize the deep choroidal blood circulation, which starts from the disc edge.

Regarding the limitations of this study, it was retrospective and cross-sectional; therefore, the timing of OCTA examination was not controlled among the patients. Second, we ideally should have counted the number of OSVs to measure total blood flow going through OSVs. Priluck et al<sup>10</sup> suggested some difficulty in distinguishing between true OSVs and just dilated capillaries. It may be time-consuming to measure the diameter of OSVs in busy clinics. Technological advancement in OCTA measurement may make it possible to evaluate OSVs more effectively and efficiently.

In conclusion, the maximum diameter of OSVs correlated closely with the VD of the macula and visual acuity. Development of OSVs on the optic disc may be a good indicator of maintenance of blood flow in the macula.

## Footnotes and Disclosures

Originally received: March 8, 2021.

Final revision: October 23, 2021.

Accepted: November 12, 2021.

Available online: November 20, 2021. Manuscript no. D-21-00029.

<sup>1</sup> Department of Ophthalmology, Osaka University Graduate School of Medicine, Osaka, Japan.

<sup>2</sup> Integrated Frontier Research for Medical Science Division, Institute for Open and Transdisciplinary Research Initiatives, Osaka University, Suita, Japan.

Disclosure(s):

All authors have completed and submitted the ICMJE disclosures form.

The author(s) have made the following disclosure(s): H.S.: Financial support — Menicon; Lecturer — Alcon, Novartis, Hoya, Senju

HUMAN SUBJECTS: Human subjects were included in this study. The human ethics committees at Osaka University Hospital approved the study. All research adhered to the tenets of the Declaration of Helsinki. All participants provided informed consent.

No animal subjects were included in this study.

Author Contributions:

Conception and design: Kanai, Sakimoto

Analysis and interpretation: Kanai, Sakimoto, Hara, Fukushima, Sayanagi, Nishida, Sakaguchi, Nishida

Data collection: Kanai, Sakimoto, Hara

Obtained funding: N/A

Overall responsibility: Kanai, Sakimoto

Abbreviations and Acronyms:

**BCVA** = best-corrected visual acuity; **CRVO** = central retinal vein occlusion; **CST** = central subfield thickness; **DCP** = deep capillary plexus; **logMAR** = logarithm of the minimum angle of resolution; **OCTA** = OCT angiography; **OSV** = opticiliary shunt vessel; **SCP** = superficial capillary plexus; **VD** = vessel density; **VEGF** = vascular endothelial growth factor.

Keywords:

Central retinal vein occlusion, OCT angiography, Optociliary shunt vessel, Retina, Vessel density.

Correspondence:

Susumu Sakimoto, MD, PhD, Department of Ophthalmology, Osaka University Medical School, Room E7, 2-2 Yamadaoka, Suita, Osaka 565-0871, Japan. E-mail: susumu.sakimoto@ophthal.med.osaka-u.ac.jp.

## References

- Blinder KJ, Khan JA, Giangiacoimo J, Ide CH. Optociliary veins and visual prognosis after central retinal vein occlusion. *Ann Ophthalmol.* 1989;21:192–194.
- Coscas G, Gaudric A. Natural course of nonaphakic cystoid macular edema. *Surv Ophthalmol.* 1984;28(Suppl):471–484.
- Eggers HM, Sanders MD. Acquired optociliary shunt vessels in papilloedema. *Br J Ophthalmol.* 1980;64:267–271.
- Fuller JJ, Mason 3rd JO, White Jr MF, et al. Retinochoroidal collateral veins protect against anterior segment neovascularization after central retinal vein occlusion. *Arch Ophthalmol.* 2003;121:332–336.
- Giuffre G, Palumbo C, Randazzo-Papa G. Optociliary veins and central retinal vein occlusion. *Br J Ophthalmol.* 1993;77:774–777.
- Glacet-Bernard A, Coscas G, Chabanel A, et al. Prognostic factors for retinal vein occlusion: prospective study of 175 cases. *Ophthalmology.* 1996;103:551–560.
- Hayreh SS, Podhajsky PA, Zimmerman MB. Natural history of visual outcome in central retinal vein occlusion. *Ophthalmology.* 2011;118:119–133.e1–e2.
- Lee JJ, Yap EY. Optociliary shunt vessels in diabetes mellitus. *Singapore Med J.* 2004;45:166–169.
- Minturn J, Brown GC. Progression of nonischemic central retinal vein obstruction to the ischemic variant. *Ophthalmology.* 1986;93:1158–1162.
- Priluck IA, Robertson DM, Hollenhorst RW. Long-term follow-up of occlusion of the central retinal vein in young adults. *Am J Ophthalmol.* 1980;90:190–202.
- Quinlan PM, Elman MJ, Bhatt AK, et al. The natural course of central retinal vein occlusion. *Am J Ophthalmol.* 1990;110:118–123.
- Schatz H, Green WR, Talamo JH, et al. Clinicopathologic correlation of retinal to choroidal venous collaterals of the optic nerve head. *Ophthalmology.* 1991;98:1287–1293.
- Sinclair SH, Gragoudas ES. Prognosis for rubeosis iridis following central retinal vein occlusion. *Br J Ophthalmol.* 1979;63:735–743.
- Takahashi K, Muraoka K, Kishi S, Shimizu K. Formation of retinochoroidal collaterals in central retinal vein occlusion. *Am J Ophthalmol.* 1998;126:91–99.
- Weinberg DV, Wahle AE, Ip MS, et al. SCORE Study Investigator Group. Score Study report 12: development of venous collaterals in the Score Study. *Retina.* 2013;33:287–295.
- Danis RP, Moorthy RS, Savage J. Microhemodynamics of retinal collateral vessel formation. *Med Hypotheses.* 1995;44:103–109.
- de Carlo TE, Romano A, Waheed NK, Duker JS. A review of optical coherence tomography angiography (OCTA). *Int J Retina Vitreous.* 2015;1:5.
- Kashani AH, Lee SY, Moshfeghi A, et al. Optical coherence tomography angiography of retinal venous occlusion. *Retina.* 2015;35:2323–2331.
- Sonoda S, Sakamoto T, Yamashita T, et al. Choroidal structure in normal eyes and after photodynamic therapy determined by binarization of optical coherence tomographic images. *Invest Ophthalmol Vis Sci.* 2014;55:3893–3899.
- Sakimoto S, Gomi F, Sakaguchi H, et al. Analysis of retinal nonperfusion using depth-integrated optical coherence tomography images in eyes with branch retinal vein occlusion. *Invest Ophthalmol Vis Sci.* 2015;56:640–646.
- Campochiaro PA, Aiello LP, Rosenfeld PJ. Anti-vascular endothelial growth factor agents in the treatment of retinal disease: from bench to bedside. *Ophthalmology.* 2016;123:S78–S88.