

## Acute Bilateral Anterior Uveitis after a Single Intravenous Infusion of Zoledronic Acid in Metastatic Breast Cancer

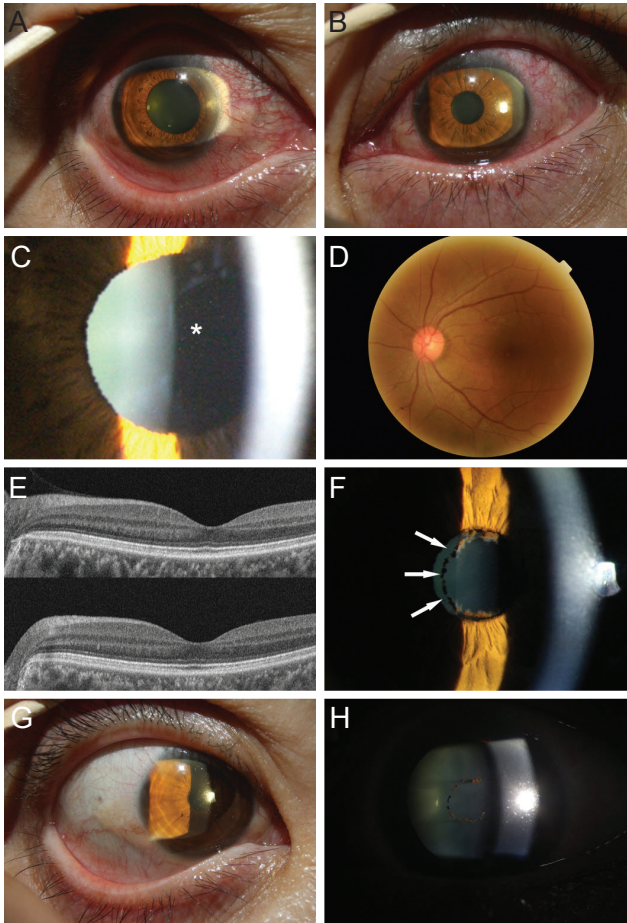
Dear Editor,

Acute anterior uveitis (AAU) induced by zoledronic acid is a rare but severe adverse event that can develop after intravenous bisphosphonate administration. Recently, AAU has been considered a part of an acute phase reaction occurring during bisphosphonate administration [1,2]. Although the underlying mechanism of this inflammation is unclear, nitrogen-containing bisphosphonates (pamidronate, alendronate, risedronate, and zoledronate) could elevate proinflammatory cytokines, interleukin-6, or tumor necrosis factor- $\alpha$  produced by activated T-cells [3]. Sixteen cases of AAU induced by zoledronic acid have been reported worldwide, but the present report is the first case occurring in Korea.

A 47-year-old woman consulted our department because of severe, pain with febrile sensation and myalgia after a single intravenous infusion of zoledronic acid (4 mg, Zometa; Novartis, Basel, Switzerland). She had received her first dose of zoledronic acid for bone metastasis of breast cancer 4 days previous. Visual acuity was 20 / 20 and intraocular pressure was 12 mmHg in both eyes. Slit-lamp examination showed severely engorged vessels of the bulbar conjunctiva and ciliary injection (Fig. 1A and 1B), with grade 1+ cell reaction in the right eye and grade 3+ cell reaction in the left (Fig. 1C). Fundus and optical coherence tomography revealed no vitreal inflammation or macular edema (Fig. 1D and 1E). The C-reactive protein level and erythrocyte sedimentation rate were 0.92 mg/dL (normal, 0–0.5 mg/dL) and 55 mm/hr (<25 mm/hr in women), respectively; differential complete blood count showed no abnormality. Loteprednol etabonate 0.5% (Lotemax; Bausch & Lomb, Rochester, NY, USA) was instilled bihourly, and 0.1% bromfenac sodium (Bronuck; Taejoon Pharm, Seoul, Korea) was instilled twice a day into both eyes. Af-

ter 3 days, the cellular reaction of the right eye subsided considerably; however, cellular reaction of the left eye was 2+, and posterior synechiae had presented (Fig. 1F). Atropine 0.5% (Isopto Atropine; Alcon, Fort Worth, TX, USA) was instilled three times a day. After 1 week, the cellular reactions of both eyes and engorgement of conjunctival vessels had subsided, synechiae of the left eye had resolved (Fig. 1G and 1H), and final visual acuity was 20 / 20 in both eyes. Inflammation had not recurred at the 1-month follow-up, but the oncologist decided not to no longer use intravenous zoledronic acid for management of bone metastasis.

Zoledronic acid, a third-generation bisphosphonate, is used for osteoclastic bone resorption diseases such as Paget's disease of the bone, osteoporosis, and bone metastasis [4]. Bisphosphonates have played a crucial role in prevention of bone loss in postmenopausal women. Additionally, intravenous bisphosphonates are being recommended to lower the frequency of gastrointestinal adverse events and improve patient compliance [4]. In particular, zoledronic acid is effective when administered as a single yearly infusion. Despite the increasing reliance on intravenous bisphosphonates for treatment of bone resorption diseases, AAU caused by this drug had not previously been reported in Korea. Although a large cohort study reported a relatively high incidence of AAU (0.8%–1.1%) [1,5], only a small number of cases have been reported, which could be due to misdiagnosis or underdiagnosis, as this disease entity is not well known to physicians, especially ophthalmologists. With the increased use of bisphosphonates in Korea [5], the probability of an ophthalmologist encountering AAU in clinical practice also increases. A randomized controlled trial reported unocular involvement in patients within  $3 \pm 2$  days after a single intravenous infusion [1]. For treating uveitis, intensive topical steroid with mydriatics is recommended. As the severity of the acute phase reaction significantly decreases during the second infusion, the severity of AAU is also expected to decrease [5]. Although two cases without AAU after the second infusion were mentioned in a previous report [5], physicians are not convinced of the safety of intravenous bisphosphonates. In



**Fig. 1.** Ocular findings of anterior acute uveitis after administration of intravenous zoledronic acid (A) and (B) slit-lamp photographs show severe bilateral vascular engorgement of the bulbar conjunctiva. (C) Moderate cellular reaction (grade 3+) of the anterior chamber was seen in the left eye (asterisk). (D) Color fundus photography shows no abnormal finding. (E) Optical coherence tomography shows no macular edema in the right (upper) or left (lower) eye. (F) Posterior synechiae occurred in the left eye after 3 days despite frequent steroid and non-steroidal anti-inflammatory drug eye drop instillations (arrows). (G) After 10 days of treatment, injections of both bulbar conjunctiva subsided after using topical medications. (H) Synechiae were resolved after the use of atropine eye drops.

the present case, binocular involvement was observed, but the severity was greater in the left eye 4 days after a single infusion. At that time, the patient was experiencing severe hot flushes and myalgia. Despite immediate bihourly instillation of topical steroid in both eyes, posterior synechiae

occurred in the left eye after 3 days of follow-up. After using mydriatics, the posterior synechiae were resolved, and the cellular reaction of the anterior chamber showed good response to the topical steroid within 1 week.

In conclusion, AAU induced by zoledronic acid is a rare adverse reaction of bisphosphonate infusion. However, the incidence of bisphosphonate use is increasing rapidly; hence, it should be recognized that anterior uveitis might occur because of an acute phase reaction caused by these drugs.

Jong Hwa Jun

Department of Ophthalmology, Dongsan Medical Center,  
Keimyung University School of Medicine, Daegu, Korea  
E-mail: junjonghwa@gmail.com

## Conflict of Interest

No potential conflict of interest relevant to this article was reported.

## References

1. Patel DV, Horne A, House M, et al. The incidence of acute anterior uveitis after intravenous zoledronate. *Ophthalmology* 2013;120:773-6.
2. Peterson JD, Bedrossian EH Jr. Bisphosphonate-associated orbital inflammation: a case report and review. *Orbit* 2012;31:119-23.
3. Sauty A, Pecherstorfer M, Zimmer-Roth I, et al. Interleukin-6 and tumor necrosis factor alpha levels after bisphosphonates treatment *in vitro* and in patients with malignancy. *Bone* 1996;18:133-9.
4. Belliveau MJ, Almeida DR, Urton TE. Acute anterior uveitis following zoledronic acid infusion for osteoporosis. *Can J Ophthalmol* 2012;47:e22-3.
5. Patel DV, Bolland M, Nisa Z, et al. Incidence of ocular side effects with intravenous zoledronate: secondary analysis of a randomized controlled trial. *Osteoporos Int* 2015;26:499-503.