

# Fine-Needle Aspirate CYFRA 21-1, an Innovative New Marker for Diagnosis of Axillary Lymph Node Metastasis in Breast Cancer Patients

Ji Soo Choi, MD, PhD, Kyung Hwa Han, MS, Eun-Kyung Kim, MD, PhD, Hee Jung Moon, MD, PhD, Jung Hyun Yoon, MD, and Min Jung Kim, MD, PhD

**Abstract:** To compare the value of cytokeratin fragment 21-1 (CYFRA 21-1) concentration in the fine-needle biopsy aspirates (fine needle aspirate [FNA] CYFRA 21-1) with cytopathology of fine-needle aspiration biopsy (FNA cytology) and to assess whether CYFRA 21-1 concentrations from ultrasound-guided fine-needle aspiration biopsy (US-FNAB) specimens (FNA CYFRA 21-1) is not inferior to FNA cytology in the diagnosis of axillary lymph node (ALN) metastasis of breast cancer patients.

This study received institutional review board approval, and written informed consent was obtained from all patients. US-FNAB was performed in 373 ALNs from 358 patients with invasive breast cancer. Concentrations of CYFRA 21-1 were measured from washouts of the syringe used during US-FNAB (FNA CYFRA 21-1), and ALN metastasis was determined using a cutoff value of 1.93 ng/mL. FNA cytology, intraoperative sentinel lymph node biopsy, and surgical pathology results were reviewed and analyzed. The noninferiority margin for the difference in accuracies between FNA cytology and FNA CYFRA 21-1 was set as 5%.

Among 373 ALNs, 136 (36.5%) were benign, and 237 (63.5%) were metastatic. The mean FNA CYFRA 21-1 was significantly higher in metastatic ALNs compared to that in benign ALNs ( $P = 0.001$ ). For the diagnosis of ALN metastasis, the sensitivity, specificity, positive predictive value, negative predictive value, and accuracy of FNA CYFRA 21-1 (cutoff value 1.93 ng/mL) were not significantly different from those of FNA cytology ( $P > 0.05$ ). FNA CYFRA 21-1 reached statistical noninferiority to FNA cytology in terms of diagnostic accuracy for ALN metastasis. Of the 20 ALNs (8 metastasis, 12 benign) that showed insufficient results on FNA cytology, FNA CYFRA 21-1 accurately diagnosed 15 ALNs (4 metastasis, 11 benign).

The diagnostic performance of FNA CYFRA 21-1 is comparable with that of FNA cytology for breast cancer ALN metastasis. Our results

indicate that FNA CYFRA 21-1, using an US-FNAB specimen, can be a useful method equal to FNA cytology in terms of diagnostic accuracy.

(*Medicine* 94(19):e811)

**Abbreviations:** ALN = axillary lymph node, ALND = axillary lymph node dissection, CK19 = cytokeratin 19, CYFRA 21-1 = cytokeratin fragment 21-1, ER = estrogen receptor, FISH = fluorescent in situ hybridization, FNA CYFRA 21-1 = CYFRA 21-1 concentrations from US-FNAB specimens, FNA = fine needle aspirate, HER2 = human epidermal growth factor receptor 2, IHC = immunohistochemical, NPV = negative predictive value, OSNA = one-step nucleic acid amplification, PR = progesterone receptor, SLNB = sentinel lymph node biopsy, SLN = sentinel lymph node, US-FNAB = ultrasound-guided fine-needle aspiration biopsy, US = ultrasound.

## INTRODUCTION

Axillary lymph node (ALN) status is a most important prognostic factor in breast cancer, and a large number of metastatic ALNs are associated with poor prognosis.<sup>1,2</sup> Sentinel lymph node biopsy (SLNB) is a standard surgical procedure in the axillary evaluation of patients presenting with invasive breast cancer.<sup>3,4</sup> This technique can decrease the morbidity of axillary staging by preventing unnecessary axillary lymph node dissection (ALND), which is linked to high morbidity.<sup>5,6</sup> Sentinel lymph node (SLN) metastasis is usually determined by hematoxylin and eosin-based frozen section or imprint cytology; however, these intraoperative diagnostic methods have low sensitivity and variation in protocols across institutions.<sup>7,8</sup> To overcome this issue, one-step nucleic acid amplification (OSNA), a rapid quantitative method for analyzing cytokeratin 19 (CK19) mRNA expression, has been proposed as a diagnostic method for SLNB by some researchers.<sup>9–13</sup> On the contrary, SLNB is an invasive surgical procedure involving the risk of radiation exposure to the operating team and has high associated costs and prolonged operation time.<sup>14</sup> Therefore, nonsurgical methods that can preoperatively determine ALN status would be clinically beneficial to treatment decisions and to reducing unnecessary SLNB.

For preoperative detection of ALN metastasis in breast cancer, axillary ultrasound (US) and adjunctive ultrasound-guided fine-needle aspiration biopsy (US-FNAB) for ultrasonographically suspicious ALNs are the most commonly used methods.<sup>15–19</sup> When patients have breast cancers and positive results on US-guided fine needle aspirate (FNA) cytology of ALN, surgeons can eliminate SLNB and advance directly to ALND. In addition, preoperative diagnosis of ALN metastasis using US-FNAB could be applicable to preoperative decision-making concerning treatment options such as neoadjuvant chemotherapy for breast cancer patients. Also, axillary US

Editor: Marek Sierzega.

Received: November 27, 2014; revised: March 27, 2015; accepted: April 3, 2015.

From the Department of Radiology, Research Institute of Radiological Science, Yonsei University College of Medicine (JSC, E-KK, HJM, JHY, MJK); Department of Radiology, Breast Cancer Center, Samsung Medical Center (JSC); Department of Research Affairs, Yonsei University College of Medicine, Seoul, Korea (KHH).

Correspondence: Min Jung Kim, Department of Radiology, Yonsei University College of Medicine, 50-1 Yonsei-ro, Seodaemun-gu, Seoul 120-752, Korea (e-mail: mines@yuhs.ac).

This study was supported by a faculty research grant from Yonsei University College of Medicine for 2013 (6–2013–0094).

The funders had no role in study design, data collection and analysis, decision to publish, or preparation of the manuscript.

The authors have no conflicts of interest to disclose.

Copyright © 2015 Wolters Kluwer Health, Inc. All rights reserved.

This is an open access article distributed under the Creative Commons Attribution-NonCommercial License, where it is permissible to download, share and reproduce the work in any medium, provided it is properly cited.

The work cannot be used commercially.

ISSN: 0025-7974

DOI: 10.1097/MD.0000000000000811

combined with US-FNAB is a useful method for the early detection of regional lymph node recurrence, which is associated with poor prognosis in asymptomatic patients after breast cancer surgery.<sup>20</sup> However, researchers who examined the diagnostic performance of axillary US combined with US-guided FNA cytology have reported broad sensitivity ranges (21%–86%) and negative predictive values (NPVs, 65%–90%).<sup>14–19,21</sup> Consequently, SLNB is performed to confirm ALN status for patients with negative or indeterminate results on FNA cytology. Given this situation, some studies have reported that concentrations of several tumor markers from US-FNAB ALN specimens may be helpful for the preoperative diagnosis of ALN metastasis in patients with breast cancer.<sup>22,23</sup> Among the tumor markers proposed, serum cytokeratin fragment 21-1 (CYFRA 21-1) is a soluble fragment of CK19, which has been considered the most appropriate marker due to its high expression in body fluids and solid tumors of breast cancer patients.<sup>9,13,24,25</sup> In a recent study, the combination of FNA cytology and measuring CYFRA 21-1 concentrations from US-FNAB specimens (FNA CYFRA 21-1) of ALN showed significantly higher performance than FNA cytology alone in the diagnosis of ALN metastasis in breast cancer patients.<sup>22</sup> Moreover, the diagnostic accuracy of FNA CYFRA 21-1 alone was comparable with that of FNA cytology (91.7% vs. 89.1%, respectively). Therefore, we conducted this study to externally validate FNA CYFRA 21-1 as a nonsurgical method that can determine ALN status in breast cancer patients.<sup>22</sup> The purpose of this study was to compare the value of FNA CYFRA 21-1 and FNA cytology and to assess whether FNA CYFRA 21-1 is not inferior to FNA cytology in the diagnosis of ALN metastasis in breast cancer patients.

## MATERIALS AND METHODS

### Study Population

This prospective study was approved by the institutional review board of Severance Hospital, Yonsei University College of Medicine, and written informed consent was obtained from all patients. Between August 2010 and August 2014, 358 breast cancer patients with 373 ALNs examined by US-FNAB were consecutively enrolled in this study. In 343 patients, US-FNAB was performed for one suspected ALN. Nine patients underwent US-FNA of 2 ALNs located at different levels of the ipsilateral axilla, and 5 patients underwent US-FNA of 1 ipsilateral and 1 contralateral ALN. One patient had bilateral cancers and underwent US-FNA of bilateral ALNs.

Among the 358 patients, 254 patients (70.9%) had unilateral breast surgery and ipsilateral SLNB or ALND. Among these, 130 patients received neoadjuvant chemotherapy before surgery. The remaining 104 patients (1 patient with bilateral breast cancers and bilateral metastatic ALNs) did not undergo operation due to the presence of distant metastasis ( $n = 68$ ) or, in postmastectomy patients, benign FNA cytology with improvement or no change on follow-up imaging examination for  $\geq 1$  year ( $n = 36$ ).

### US and US-FNA of Axillary Lymph Nodes

Axillary US was performed by 1 of 7 breast radiologists with different degrees of experience (2–13 years). The US systems were Phillips ATL HDI, iU22 (Phillips-Advanced Technology Laboratories, Bothell, WA, USA) machines equipped with high-frequency linear transducers (5–12 MHz). Bilateral axillae were carefully examined in an orthogonal direction along the axillary artery from the lower axilla to the junction of the axilla and

upper arm. The US features of suspicious metastatic ALNs were defined as the following: absence of fatty hilum, cortical thickening ( $>3$  mm), irregular or round shape, marked hypoechoogenicity of cortex, or increased peripheral blood flow on Doppler US.<sup>23,26,27</sup> ALNs that showed one or more suspicious US features were considered suspicious, and US-FNAB was performed for all suspected metastatic ALNs.

US-FNAB was performed with a 23-gauge needle attached to a 2-mL disposable syringe using freehand technique, and each ALN was aspirated at least twice. Aspirated samples were immediately expelled onto glass slides and smeared. All smears were immediately fixed in 95% alcohol for Papanicolaou staining. The remaining aspirated materials in the needle and syringe were rinsed with 1 mL of saline, and then the washout was made. The CYFRA 21-1 concentration was measured in the washout samples. These procedures were performed on the same day.

### FNA CYFRA 21-1 Analysis

CYFRA 21-1 concentrations in the FNAB washout specimens of ALNs were measured by automated immunoanalyzer system with chemiluminescent immunoassays (E411; Roche Diagnostics, Germany). A noncompetitive immunometric sandwich assay format containing monoclonal antibody for CYFRA 21-1 was used with the immunoassay reagent.

### Surgical Management of Axillary Lymph Nodes

Breast surgery including evaluation of the axillary nodal status was performed by 1 of 4 breast surgeons with 9 to 24 years of experience in breast surgery. ALNs with positive FNA cytology underwent ALND without SLNB. ALNs with negative FNA cytology underwent SLNB, and according to these SLNB results, ALND was performed on patients showing positive histology on SLNB, while no further nodal dissection was done if SLNB histology results were negative, except for patients who underwent neoadjuvant chemotherapy. In addition, our surgeons were aware of the size and location of the aspirated ALNs described on preoperative US, and efforts were made to find the correlating ALN at surgery.

### Pathologic Analysis

Five cytopathologists (nonauthors with 1–15 years of experience) interpreted the FNAB specimens of ALN. FNA cytology results were divided into 2 categories. Reports of metastasis from breast cancer or atypical cells were considered positive. Reports of reactive hyperplasia or specific benign diagnoses (eg, tuberculosis) were considered negative. Reports of insufficient material were considered negative, because a patient with insufficient material on FNA cytology should undergo SLNB just like a patient with negative cytology.<sup>19,23,28</sup>

The reference standards for primary breast cancers were the final histopathological results of surgical or core needle biopsy specimens. The reference standards for ALNs were surgical histopathological results ( $n = 254$ ) or the combination of FNA cytology results and clinical evidence during the follow-up ( $n = 119$ ).

Immunohistochemical (IHC) stains for estrogen receptor (ER), progesterone receptor (PR), and human epidermal growth factor receptor 2 (HER2) were performed on formalin-fixed, paraffin-embedded tissue sections. In brief, 5- $\mu$ m sections were cut with a microtome, transferred onto adhesive slides, and dried at 62°C for 30 minutes. After incubation with primary antibodies against ER (clone SP1, 1:100; Thermo Scientific, Fremont, CA, USA), PR (clone PgR, 1:50; DAKO), or HER2

(polyclonal, 1:1500; DAKO, Glostrup, Denmark), immunodetection was performed with biotinylated antimouse immunoglobulin, followed by streptavidin-conjugated peroxidase from a streptavidin biotin kit with 3,3'-diaminobenzidine as the chromogen substrate. A cutoff value of >1% positively stained nuclei was used to determine ER- and PR-positivity.<sup>29</sup> HER2 staining was scored in the range of 0 to 3+, according to the guidelines of the American Society of Clinical Oncology/College of American Pathologists.<sup>30</sup> Cases scored as 3+ were considered HER2-positive, whereas cases scored as 0 to 1+ were regarded as negative. Cases showing 2+ required further examination using fluorescent in situ hybridization (FISH) to measure HER2 amplification. *HER2* gene/chromosome 17 ratio of higher than 2.2 was considered HER2-positive by FISH.

**Data and Statistical Analysis**

Clinicopathologic data were gathered through review of medical records. Clinicopathologic characteristics included size of aspirated ALNs, status of ER, PR, and HER2 expression in primary breast cancer, and presence of distant metastasis at the time of diagnosis. Size of aspirated ALNs was measured as the maximum diameter on either transverse or longitudinal scans of preoperative US. Information on expression status of ER, PR, and HER2 was determined based on the patients' final pathologic reports. Primary breast cancers were grouped into luminal (type A or B), HER2-enriched, or triple negative cancers according to IHC analysis.<sup>31,32</sup>

The Wilcoxon rank-sum test was used to compare the median values of FNA CYFRA 21-1 between benign and metastatic ALNs. In the analysis of diagnostic performance of FNA CYFRA 21-1, ALN metastasis was determined using a cutoff value of 1.93 ng/mL.<sup>22</sup> The FNA CYFRA 21-1 statuses of ALNs were divided into 2 categories (negative or positive) according to the FNA CYFRA 21-1 cutoff value. Sensitivity, specificity, positive predictive value, NPV, and accuracy were calculated based on reference standards for FNA cytology and FNA CYFRA 21-1, respectively. These values of diagnostic performances of FNA cytology and FNA CYFRA 21-1 were compared using logistic regression with a generalized estimating equation. For testing noninferiority between FNA cytology and FNA CYFRA 21-1, the noninferiority margin for the difference in accuracies between FNA cytology and FNA CYFRA 21-1 was set at 5% based on the differences in accuracies of axillary US alone, axillary US combined with US-guided FNA cytology or FNA CYFRA 21-1 in a previous study.<sup>14,22</sup> The sample size and 97.5% one-sided confidence interval were calculated by Wald-type based statistics. Additionally, the diagnostic performance of FNA CYFRA 21-1 was compared with that of FNA cytology according to IHC subtype of corresponding primary breast cancers. Statistical analysis was performed with SAS for Windows, v. 9.0 (SAS Institute, Cary, NC, USA). Two-sided *P* values <0.05 were considered statistically significant. For the noninferiority test, a one-sided *P* value of <0.025 was considered to indicate statistical significance.

**RESULTS**

**Clinicopathologic Patient Characteristics**

The mean age of the patients was 49.5 years (range 27–83 years). The median size of aspirated ALNs was 12 mm (interquartile range 9–17 mm). The number of each histologic type of the primary breast cancers was 350 invasive ductal carcinomas

in 349 patients, 4 invasive lobular carcinomas in 4 patients, 2 mucinous carcinomas in 2 patients, 2 tubular carcinomas in 2 patients, and 1 neuroendocrine carcinoma in 1 patient. Among the 263 cancers with available IHC analysis results, there were 197 luminal, 32 HER2-enriched type, and 34 triple negative cancers. At final diagnosis, 237 (63.5%) of 373 ALNs were positive for metastasis and 136 (36.5%) were negative. Distant metastasis was observed in 69 cancers (19.2%) from 68 patients, and the metastatic sites consisted of bone, lung, liver, brain, and neck node, in order of frequency.

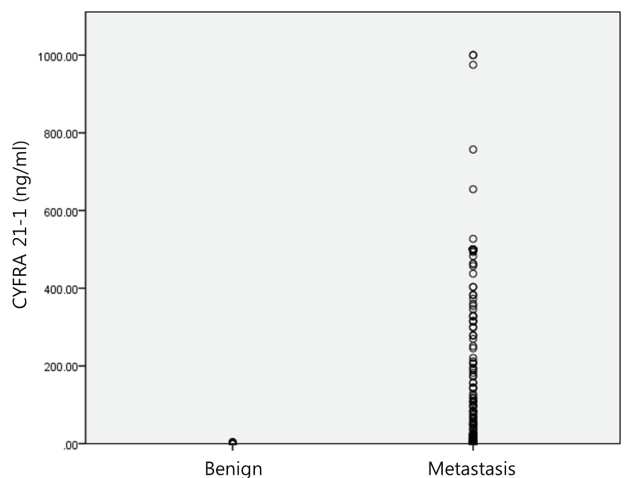
**Diagnostic Performance of FNA CYFRA 21-1 and FNA Cytology in Diagnosis of ALN Metastasis**

The median value of FNA CYFRA 21-1 was significantly higher in metastatic ALNs (93.3 ng/mL, interquartile range 6.7–500.0 ng/mL) compared with benign ALNs (0.7 ng/mL, interquartile range 0.5–0.9 ng/mL) (*P* < 0.001) (Figure 1).

FNA cytology results from US-FNAB of 237 final metastatic ALNs were positive for metastasis in 198, and negative in 39 nodes (31 benign and 8 insufficient) (Table 1). All 136 final benign nodes had negative FNA cytology results (124 benign and 12 insufficient). Of the 237 metastatic ALNs, 200 ALNs had positive results (>1.93 ng/mL) by FNA CYFRA 21-1 analysis. Of the 20 ALNs (8 metastasis, 12 benign) that showed insufficient results on FNA cytology, FNA CYFRA 21-1 accurately diagnosed 15 ALNs (4 metastasis, 11 benign). The mean value of 2 false-positive ALNs on FNA CYFRA 21-1 analysis was 3.7 ng/mL (range 2.7–4.7 ng/mL).

Table 2 shows the diagnostic performance of FNA CYFRA 21-1 and FNA cytology in the diagnosis of ALN metastasis. There were no significant differences in the diagnostic performance of FNA CYFRA 21-1 and FNA cytology (*P* > 0.05). FNA CYFRA 21-1 and FNA cytology showed the same accuracy of 89.5% for the diagnosis of ALN metastasis. In testing for noninferiority, the lower boundary of the one-sided 97.5% confidence interval (−0.027 to 1) lay above the pre-defined noninferiority margin, and the *P* value was <0.025 (*P* < 0.001). Accordingly, the noninferiority of FNA CYFRA 21-1 to FNA cytology was established.

The diagnostic performances of the two methods were compared according to IHC subtype of the corresponding



**FIGURE 1.** FNA CYFRA 21-1 of 373 axillary lymph nodes in 353 patients with invasive breast cancers. FNA CYFRA 21-1 = CYFRA 21-1 concentrations from US-FNAB specimens.

**TABLE 1.** Correlation of FNA CYFRA 21-1 and FNA Cytology of 373 ALNs by Final ALN Diagnosis

Final Diagnosis	FNA CYFRA 21-1		FNA Cytology	
	Positive (n = 202)	Negative (n = 171)	Positive (n = 198)	Negative (n = 175)
Benign (n = 136)	2 (0.6)	134 (35.9)	0 (0.0)	136 (36.5)
Metastasis (n = 237)	200 (53.6)	37 (9.9)	198 (53.1)	39 (10.4)

Non-numeric data are presented as the number of lymph nodes (percentage).

ALN = axillary lymph node, FNA = fine needle aspirate, FNA CYFRA 21-1 = CYFRA 21-1 concentrations from US-FNAB specimens.

primary breast cancers (Table 3). There were no significant differences in the diagnostic performances of FNA CYFRA 21-1 and FNA cytology, according to IHC subtype of the corresponding primary breast cancers.

## DISCUSSION

CYFRA 21-1, the proteolytic part of CK19, can be detected in serum and other body fluids, and elevated levels of CYFRA 21-1 have been observed in various malignancies, especially lung cancer.<sup>24,33,34</sup> For breast cancer, a high level of serum CYFRA 21-1 is significantly associated with advanced stage or recurrent breast cancer, and has been proposed for use in monitoring treatment response or disease relapse in breast cancer patients.<sup>24,33,35,36</sup> Moreover, a recent study reported that CYFRA 21-1 concentrations in the US-FNAB specimens obtained from metastatic ALNs can be helpful for the diagnosis of ALN metastasis in patients with breast cancer, as CYFRA 21-1 concentrations of metastatic ALNs are significantly higher than those of benign ALNs.<sup>22</sup> In accordance with a previous study, we confirmed that metastatic ALNs expressed significantly higher FNA CYFRA 21-1 than benign ALNs. The values of sensitivity (84.4%) and specificity (98.5%) as a diagnostic marker of ALN metastasis were also similar to the values previously reported.<sup>22</sup>

In the current study, FNA CYFRA 21-1 and FNA cytology using the US-FNAB specimen did not significantly differ in terms of their diagnostic performance for ALN metastasis in breast cancer patients. These two methods showed the same diagnostic accuracy (89.5%), and comparable sensitivity (83.5–84.4%) and specificity (98.5–100%). Moreover, FNA CYFRA 21-1 reached statistical noninferiority to FNA cytology in terms of diagnostic accuracy.

We additionally performed subgroup analysis according to the IHC features of corresponding primary breast cancers, because ER, PR, and HER2 status determined by IHC analysis

are currently used for breast cancer subtype classification.<sup>10,31,32</sup> The diagnostic performance of FNA CYFRA 21-1 was not significantly different from that of FNA cytology in the subgroups classified by IHC subtype of primary breast cancers. Our overall results indicate that FNA CYFRA 21-1 can be applied to all breast cancer patients regardless of their cancer subtypes as a substitute for FNA cytology. In addition, our results are in accordance with those from previous studies, which found that the CK19 expression rate was as high as 98.4% in breast adenocarcinoma,<sup>11,37</sup> whereas a smaller group of breast cancer with basal-like subtype expressed CK5/6, CK14, and CK17.<sup>38,39</sup> That is the same reason why CK-19 is used as a diagnostic marker in OSNA for the detection of metastases in SLNs of breast cancer.<sup>9–13</sup>

FNA CYFRA 21-1 has the primary advantage of enabling preoperative or pretreatment diagnosis of ALN metastasis, because it also uses US-FNAB specimens like FNA cytology. Therefore, FNA CYFRA 21-1 can be an equally useful method for breast cancer patients who are considering neoadjuvant chemotherapy prior to surgery or who have suspected metastatic ALNs on postoperative follow-up imaging study. In addition to diagnostic performance, FNA CYFRA 21-1 has strong clinical advantages compared with FNA cytology. FNA cytology may provide subjective results that may differ from one pathologist to another, and insufficient results that require additional testing, such as repeated FNA or surgical biopsy. However, FNA CYFRA 21-1 can provide objective results using a cutoff value, and may enhance the diagnostic value of US-FNAB in cases with insufficient results on FNA cytology. Among the 20 ALNs (8 metastatic, 12 benign) with insufficient FNA cytology results of this study, 15 ALNs (4 metastatic, 11 benign) were accurately diagnosed by FNA CYFRA 21-1. On the contrary, FNA cytology interpretation is time-consuming, and may take several days to provide definitive results according to the cytologists' schedule. In comparison, measuring FNA CYFRA 21-1 takes a relatively short time as long as the equipment for the evaluation of CYFRA 21-1 is available. Consequently, FNA CYFRA 21-1 using US-FNAB specimens may be more useful than FNA cytology for the diagnosis of ALN metastasis, due to strong clinical advantages and comparable diagnostic performance to FNA cytology.

Our study had several limitations. First, we used a cutoff value of 1.93 ng/mL, determined by previous preliminary study,<sup>22</sup> to assess the diagnostic performance of FNA CYFRA 21-1. Although diagnostic performance of FNA CYFRA 21-1 was as good as that of FNA cytology, there were two false-positive ALNs with FNA CYFRA 21-1, but no false-positives with FNA cytology in this study. Accordingly, further study with a larger number of patients is needed to determine the best cutoff value of FNA CYFRA 21-1 in the diagnosis of ALN metastasis from breast cancer. Second, we cannot estimate the cost of each FNA CYFRA 21-1 test, because this is a

**TABLE 2.** Diagnostic Performance of FNA CYFRA 21-1 and FNA Cytology in Predicting Metastatic ALN

Diagnostic Method	FNA CYFRA 21-1	FNA Cytology	P
Sensitivity	84.4 (79.7, 88.3)	83.5 (78.8, 88.3)	0.683
Specificity	98.5 (96.5, 100)	100.0 (100.0, 100.0)	0.157
PPV	99.0 (97.6, 100)	100.0 (100.0, 100.0)	0.155
NPV	78.3 (72.2, 84.5)	77.7 (71.6, 83.9)	0.769
Accuracy	89.5 (86.4, 92.7)	89.5 (86.4, 92.7)	–

Data are presented as percentages (95% confidence interval).

ALN = axillary lymph node, FNA = fine needle aspirate, FNA CYFRA 21-1 = CYFRA 21-1 concentrations from US-FNAB specimens, NPV = negative predictive value, PPV = positive predictive value.

**TABLE 3. Diagnostic Performance of FNA CYFRA 21-1 and FNA Cytology in Predicting Metastatic ALN According to Immunohistochemical Subtype of Primary Breast Cancers**

	Sensitivity			Specificity			PPV			NPV			Accuracy		
	Cytology	CYFRA	P	Cytology	CYFRA	P	Cytology	CYFRA	P	Cytology	CYFRA	P	Cytology	CYFRA	P
Luminal (n = 197)	83.0 (76.2, 88.2)	85.6 (79.1, 90.3)	0.285	100.0 (100, 100)	100.0 (100, 100)	–	100.0 (100, 100)	100.0 (100, 100)	–	66.7 (55.5, 76.2)	70.3 (58.6, 79.6)	0.283	87.3 (82.0, 91.2)	89.3 (84.2, 92.8)	0.285
HER2- enriched (n = 32)	87.0 (66.5, 95.7)	82.6 (61.8, 93.3)	0.655	100.0 (100, 100)	90 (55.5, 99.8)	0.292	100.0 (100, 100)	95.0 (75.1, 99.9)	0.305	76.9 (47.9, 92.4)	69.2 (40.9, 88.0)	0.546	90.9 (75.3, 97.0)	84.9 (68.4, 93.6)	0.414
Triple negative (n = 34)	83.3 (63.1, 93.6)	87.5 (67.6, 95.9)	0.317	100.0 (100, 100)	100.0 (100, 100)	–	100.0 (100, 100)	100.0 (100, 100)	–	73.3 (46.7, 89.6)	78.6 (50.6, 92.9)	0.305	88.6 (73.2, 95.6)	91.4 (76.6, 97.2)	0.317

Cases with no available results on each characteristic were excluded from data analysis. Data are presented as percentages (95% confidence interval). ALN = axillary lymph node, FNA = fine needle aspirate, FNA CYFRA 21-1 = CYFRA 21-1 concentrations from US-FNAB specimens, NPV = negative predictive value, PPV = positive predictive value.

preliminary study. Therefore, cost-effectiveness analysis of this method may be needed in the future. Third, we cannot entirely rule out the possibility that the aspirated ALN was not the SLN for patients who only underwent SLNB. However, we believe that this limitation is inevitable because routine ALND is not currently recommended in breast cancer patients. Also, we think that our method of surgical management for ALNs may not have much effect on our results, because the purpose of this study was to assess whether FNA CYFRA 21-1 is not inferior to FNA cytology in the diagnosis of ALN metastasis in breast cancer patients. Fourth, we did not evaluate the association between the FNA CYFRA 21-1 value and tumor burden of aspirated metastatic ALN or nonaspirated, but surrounding metastatic, ALN. According to the American College of Surgeons Oncology Group Z0011 randomized trial, SLN dissection alone did not result in inferior survival compared with ALND among patients with limited SLN metastatic breast cancer treated with breast conservation surgery, radiation, and systemic therapy.<sup>40</sup> Under these circumstances, if the FNA CYFRA 21-1 values correlate with nodal tumor burden or number of metastatic ALNs, they may be useful not only in the diagnosis of ALN metastasis, but also in determining the appropriate surgical procedure for ALN metastasis. Accordingly, further study is needed to evaluate the utility of FNA CYFRA 21-1 in predicting advanced nodal stage.

In conclusion, the diagnostic performance of FNA CYFRA 21-1 is comparable to that of FNA cytology for the diagnosis of ALN metastasis in breast cancer patients. Our results indicate that FNA CYFRA 21-1 using an US-FNAB specimen can be a novel and useful method that is as good as FNA cytology in terms of diagnostic accuracy.

**REFERENCES**

- Banerjee M, George J, Song EY, et al. Tree-based model for breast cancer prognostication. *J Clin Oncol.* 2004;22:2567–2575.
- Fisher B, Bauer M, Wickerham DL, et al. Relation of number of positive axillary nodes to the prognosis of patients with primary breast cancer. An NSABP update. *Cancer.* 1983;52:1551–1557.
- Fraile M, Rull M, Julian FJ, et al. Sentinel node biopsy as a practical alternative to axillary lymph node dissection in breast cancer patients: an approach to its validity. *Ann Oncol.* 2000;11:701–705.
- Veronesi U, Paganelli G, Galimberti V, et al. Sentinel-node biopsy to avoid axillary dissection in breast cancer with clinically negative lymph-nodes. *Lancet.* 1997;349:1864–1867.
- Keshtgar MR, Baum M. Axillary dissection over the years: where to from here? *World J Surg.* 2001;25:761–766.
- Purushotham AD, Upponi S, Klevesath MB, et al. Morbidity after sentinel lymph node biopsy in primary breast cancer: results from a randomized controlled trial. *J Clin Oncol.* 2005;23:4312–4321.
- Pathmanathan N, Jones W, Salisbury E, et al. Intraoperative imprint cytology of sentinel lymph nodes in breast cancer: initial experience and lessons learnt in establishing a new practice. *Pathology.* 2006;38:321–327.
- Tanis PJ, Boom RP, Koops HS, et al. Frozen section investigation of the sentinel node in malignant melanoma and breast cancer. *Ann Surg Oncol.* 2001;8:222–226.
- Tsujimoto M, Nakabayashi K, Yoshidome K, et al. One-step nucleic acid amplification for intraoperative detection of lymph node metastasis in breast cancer patients. *Clin Cancer Res.* 2007;13:4807–4816.

10. Snook K, Layer G, Jackson P, et al. Multicentre evaluation of intraoperative molecular analysis of sentinel lymph nodes in breast carcinoma. *Br J Surg*. 2011;98:527–535.
11. Sagara Y, Ohi Y, Matsukata A, et al. Clinical application of the one-step nucleic acid amplification method to detect sentinel lymph node metastasis in breast cancer. *Breast Cancer*. 2013;20:181–186.
12. Peg V, Espinosa-Bravo M, Vieites B, et al. Intraoperative molecular analysis of total tumor load in sentinel lymph node: a new predictor of axillary status in early breast cancer patients. *Breast Cancer Res Treat*. 2013;139:87–93.
13. Alvarenga CA, Paravidino PI, Alvarenga M, et al. Expression of CK19 in invasive breast carcinomas of special histological types: implications for the use of one-step nucleic acid amplification. *J Clin Pathol*. 2011;64:493–497.
14. Cools-Lartigue J, Meterissian S. Accuracy of axillary ultrasound in the diagnosis of nodal metastasis in invasive breast cancer: a review. *World J Surg*. 2012;36:46–54.
15. van Rijk MC, Deurloo EE, Nieweg OE, et al. Ultrasonography and fine-needle aspiration cytology can spare breast cancer patients unnecessary sentinel lymph node biopsy. *Ann Surg Oncol*. 2006;13:31–35.
16. Park SH, Kim MJ, Park BW, et al. Impact of preoperative ultrasonography and fine-needle aspiration of axillary lymph nodes on surgical management of primary breast cancer. *Ann Surg Oncol*. 2011;18:738–744.
17. Koelliker SL, Chung MA, Mainiero MB, et al. Axillary lymph nodes: US-guided fine-needle aspiration for initial staging of breast cancer – correlation with primary tumor size. *Radiology*. 2008;246:81–89.
18. Jain A, Haisfield-Wolfe ME, Lange J, et al. The role of ultrasound-guided fine-needle aspiration of axillary nodes in the staging of breast cancer. *Ann Surg Oncol*. 2008;15:462–471.
19. Deurloo EE, Tanis PJ, Gilhuijs KG, et al. Reduction in the number of sentinel lymph node procedures by preoperative ultrasonography of the axilla in breast cancer. *Eur J Cancer*. 2003;39:1068–1073.
20. Moon HJ, Kim MJ, Kim EK, et al. US surveillance of regional lymph node recurrence after breast cancer surgery. *Radiology*. 2009;252:673–681.
21. Choi JS, Kim MJ, Moon HJ, et al. False negative results of preoperative axillary ultrasound in patients with invasive breast cancer: correlations with clinicopathologic findings. *Ultrasound Med Biol*. 2012;38:1881–1886.
22. Yoon JH, Han KH, Kim E-K, et al. Fine-needle aspirates CYFRA 21-1 is a useful tumor marker for detecting axillary lymph node metastasis in breast cancer patients. *PLoS One*. 2013;8:e57248.
23. Kim MJ, Park B-W, Lim J-B, et al. Axillary lymph node metastasis: CA-15-3 and carcinoembryonic antigen concentrations in fine-needle aspirates for preoperative diagnosis in patients with breast cancer. *Radiology*. 2010;254:691–697.
24. Marrakchi R, Ouerhani S, Benammar S, et al. Detection of cytokeratin 19 mRNA and CYFRA 21-1 (cytokeratin 19 fragments) in blood of Tunisian women with breast cancer. *Int J Biol Markers*. 2008;23:238–243.
25. Saloustros E, Perraki M, Apostolaki S, et al. Cytokeratin-19 mRNA-positive circulating tumor cells during follow-up of patients with operable breast cancer: prognostic relevance for late relapse. *Breast Cancer Res*. 2011;13:R60.
26. Moore A, Hester M, Nam MW, et al. Distinct lymph nodal sonographic characteristics in breast cancer patients at high risk for axillary metastases correlate with the final axillary stage. *Br J Radiol*. 2008;81:630–636.
27. Krishnamurthy S, Snejce N, Bedi DG, et al. Role of ultrasound-guided fine-needle aspiration of indeterminate and suspicious axillary lymph nodes in the initial staging of breast carcinoma. *Cancer*. 2002;95:982–988.
28. Ciatto S, Brancato B, Risso G, et al. Accuracy of fine needle aspiration cytology (FNAC) of axillary lymph nodes as a triage test in breast cancer staging. *Breast Cancer Res Treat*. 2007;103:85–91.
29. Hammond ME, Hayes DF, Dowsett M, et al. American Society of Clinical Oncology/College Of American Pathologists guideline recommendations for immunohistochemical testing of estrogen and progesterone receptors in breast cancer. *J Clin Oncol*. 2010;28:2784–2795.
30. Wolff AC, Hammond ME, Schwartz JN, et al. American Society of Clinical Oncology/College of American Pathologists guideline recommendations for human epidermal growth factor receptor 2 testing in breast cancer. *J Clin Oncol*. 2007;25:118–145.
31. Sorlie T, Perou CM, Tibshirani R, et al. Gene expression patterns of breast carcinomas distinguish tumor subclasses with clinical implications. *Proc Natl Acad Sci U S A*. 2001;98:10869–10874.
32. Perou CM, Sorlie T, Eisen MB, et al. Molecular portraits of human breast tumours. *Nature*. 2000;406:747–752.
33. Nakata B, Ogawa Y, Ishikawa T, et al. Serum CYFRA 21-1 is one of the most reliable tumor markers for breast carcinoma. *Cancer*. 2000;89:1285–1290.
34. Molina R, Agusti C, Filella X, et al. Study of a new tumor marker, CYFRA 21-1, in malignant and nonmalignant diseases. *Tumour Biol*. 1994;15:318–325.
35. Rodriguez CA, Cruz JJ, Martin T, et al. Serum CYFRA 21-1 is one of the most reliable tumor markers for breast carcinoma. *Cancer*. 2002;95:670–671 author reply 671.
36. Nakata B, Takashima T, Ogawa Y, et al. Serum CYFRA 21-1 (cytokeratin-19 fragments) is a useful tumour marker for detecting disease relapse and assessing treatment efficacy in breast cancer. *Br J Cancer*. 2004;91:873–878.
37. Chu PG, Weiss LM. Keratin expression in human tissues and neoplasms. *Histopathology*. 2002;40:403–439.
38. Rakha EA, Reis-Filho JS, Ellis IO. Basal-like breast cancer: a critical review. *J Clin Oncol*. 2008;26:2568–2581.
39. Laakso M, Loman N, Borg A, et al. Cytokeratin 5/14-positive breast cancer: true basal phenotype confined to BRCA1 tumors. *Mod Pathol*. 2005;18:1321–1328.
40. Giuliano AE, Hunt KK, Ballman KV, et al. Axillary dissection vs. no axillary dissection in women with invasive breast cancer and sentinel node metastasis: a randomized clinical trial. *JAMA*. 2011;305:569–575.