



# Endoscopic ultrasound–guided liver biopsy: needle types and suction methods

Catherine Vozzo, DO,<sup>1</sup> Mohannad Abou Saleh, MD,<sup>1</sup> Richard Drake, PhD,<sup>2</sup> Prabhleen Chahal, MD<sup>1</sup>

## INTRODUCTION

Endoscopic ultrasound–guided liver biopsy (EUS-LB) is gaining traction among hepatologists and endosonographers. It is safe and effective at delivering excellent liver biopsy cores and can be time saving if another endoscopic procedure is required at the same time.<sup>1</sup> Although the first EUS-guided biopsy of a liver lesion was described in 1997, EUS-LB for routine assessment of elevated liver biochemistries or evidence of cirrhosis was later reported in 2008.<sup>2,3</sup> There is no clear consensus on the optimal tools and techniques used in EUS-LB. Herein, we describe the various types of needles used in this procedure and suction techniques available.

## EUS-LB

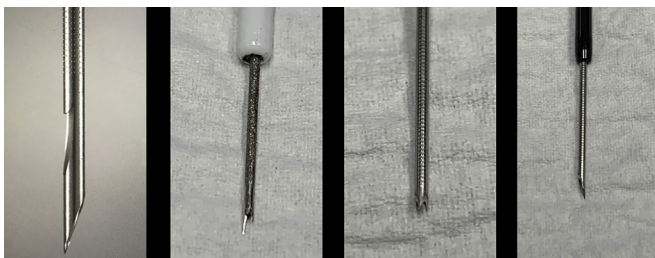
Before initiating the procedure, it is important to review the indications and contraindications. Indications are similar to those for percutaneous or transjugular liver biopsy and include identifying the etiology of complex liver disease, staging of liver disease (nonalcoholic steatohepatitis or cirrhosis), and tissue acquisition of focal hepatic lesions.<sup>4</sup> Contraindications can be extrapolated from EUS-guided FNA in GI tract lesions and may include inability to tolerate sedation, gastric outlet obstruction, no clear biopsy path without collaterals, abnormal coagulation factors, or hemodynamic instability.

Both EUS-FNA and fine-needle biopsy (FNB) can be used in EUS-LB (Fig. 1). Three different EUS-FNB needle types are commercially available: ProCore, SharkCore, and Acquire. Each has a different needle type consisting

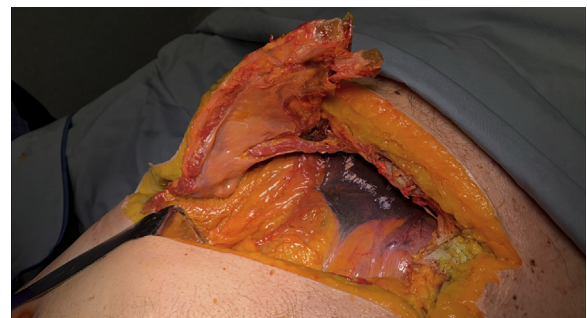of a reverse-bevel core, Fork tip (SharkCore; Medtronic, Minneapolis, Minn), and Franseen tip (Acquire; Boston Scientific, Natick, Mass), respectively (Fig. 1). A discrepancy in the literature exists regarding the superiority of FNA versus FNB needles based on the most recent meta-analyses available.<sup>5-8</sup> However, data may favor FNB needles in terms of diagnostic yield. In a meta-analysis by Khan et al,<sup>7</sup> diagnostic yield was similar between FNA and FNB needles only when FNA was accompanied by rapid onsite evaluation of the specimen. In addition, a 2020 meta-analysis by Baran et al<sup>8</sup> found that FNB needles yielded a higher number of complete portal tracts.

There are 6 reported tissue acquisition techniques that can be used in EUS-LB (Fig. 2).<sup>9-11</sup> The wet suction technique may improve diagnostic yield compared with dry suction when using FNA.<sup>9</sup> Another useful FNA technique is wet heparin, which reportedly has less tissue fragmentation, more complete portal tracts, and increased aggregate specimen length compared with dry techniques.<sup>10</sup> Heparin priming of the needle may decrease blood clots within the specimen, leading to less blood contamination, and enhance tissue processing and interpretation.<sup>10</sup> Video 1 outlines the EUS-LB tools and techniques, a brief ex vivo cadaveric EUS-LB, and an in vivo real-world example of EUS-LB (Video 1, available online at [www.giejournal.org](http://www.giejournal.org); Fig. 2).

Adverse events may be related to sedation, may be well-recognized endoscopic adverse events, or may be biopsy-related, including bleeding, abdominal pain, infection, or needle tract seeding of malignant cells. Although FNB needles in 1 study conferred a higher likelihood of pain post-procedure compared with FNA, no studies to date have shown a higher bleeding risk in EUS-LB based on needle type or size.<sup>1</sup>



**Figure 1.** Needle types. From left to right: ProCore FNB Needle, SharkCore FNB Needle, Acquire FNB Needle, and Expect FNA Needle.



**Figure 2.** Suction techniques. Ex vivo cadaveric liver.

## SUMMARY

EUS-LB is now more routinely used for diagnostic purposes in liver pathology. Several suction techniques using different needle options have been described over the past decade. Outcomes are comparable, and there is currently no consensus regarding the optimal approach to EUS-LB.

## DISCLOSURE

*All authors disclosed no financial relationships.*

*Abbreviations: EUS-LB, EUS-guided liver biopsy; FNB, fine-needle biopsy.*

## REFERENCES

1. Mok SRS, Diehl DL. The role of EUS in liver biopsy. *Curr Gastroenterol Rep* 2019;21:6.
2. Bentz JS, Kochman ML, Faigel DO, et al. Endoscopic ultrasound-guided real-time fine-needle aspiration: clinicopathologic features of 60 patients. *Diagn Cytopathol* 1998;18:98-109.
3. Mathew A. EUS-guided routine liver biopsy in selected patients. *Am J Gastroenterol* 2007;102:2354-5.
4. Sbeit W, Kadah A, Mahamid M, et al. A state-of-the-art review on the evolving utility of endoscopic ultrasound in liver diseases diagnosis. *Diagnostics (Basel)* 2020;10:512.
5. Mohan BP, Shakhathreh M, Garg R, et al. Efficacy and safety of EUS-guided liver biopsy: a systematic review and meta-analysis. *Gastrointest Endosc* 2019;89:238-46.e3.
6. Bang JY, Hawes R, Varadarajulu S. A meta-analysis comparing ProCore and standard fine-needle aspiration needles for endoscopic ultrasound-guided tissue acquisition. *Endoscopy* 2016;48:339-49.
7. Khan MA, Grimm IS, Ali B, et al. A meta-analysis of endoscopic ultrasound-fine-needle aspiration compared to endoscopic ultrasound-fine-needle biopsy: diagnostic yield and the value of onsite cytopathological assessment. *Endosc Int Open* 2017;5:E363-75.
8. Baran B, Kale S, Patil P, et al. Endoscopic ultrasound-guided parenchymal liver biopsy: a systematic review and meta-analysis. *Surg Endosc*. Epub 2020 Oct 14.
9. Attam R, Arain MA, Bloechl SJ, et al. "Wet suction technique (WEST)": a novel way to enhance the quality of EUS-FNA aspirate. Results of a prospective, single-blind, randomized, controlled trial using a 22-gauge needle for EUS-FNA of solid lesions. *Gastrointest Endosc* 2015;81:1401-7.
10. Mok SRS, Diehl DL, Johal AS, et al. A prospective pilot comparison of wet and dry heparinized suction for EUS-guided liver biopsy (with videos). *Gastrointest Endosc* 2018;88:919-25.
11. Tong T, Tian L, Deng M, et al. Comparison between modified wet suction and dry suction technique for endoscopic ultrasound-guided fine-needle biopsy in pancreatic solid lesions. *J Gastroenterol Hepatol* 2021;36:1663-9.

Department of Gastroenterology and Hepatology, Cleveland Clinic Foundation, Cleveland, Ohio (1), Cleveland Clinic Lerner College of Medicine of Case Western Reserve University Cleveland, Ohio (2).

Copyright © 2021 American Society for Gastrointestinal Endoscopy. Published by Elsevier Inc. This is an open access article under the CC BY-NC-ND license (<http://creativecommons.org/licenses/by-nc-nd/4.0/>).

<https://doi.org/10.1016/j.vgie.2021.06.007>

**Read Articles in Press Online Today!  
Visit [www.videogie.org](http://www.videogie.org)**

*VideoGIE* posts in-press articles online in advance of their appearance in a monthly edition of the journal. These articles are available on the *VideoGIE* website by clicking on the "Articles in Press" tab. Articles in Press represent the final edited text of articles that are accepted for publication but not yet scheduled to appear in a specific issue. They are considered officially published as of the date of Web publication, which means readers can access the information and authors can cite the research months prior to its availability in an issue. To cite Articles in Press, include the journal title, year, and the article's Digital Object Identifier (DOI), located in the article footnote. Visit the website today to stay current on the latest research in the field of gastrointestinal endoscopy.