





Chronic Inflammatory Response in the Rat Lung to Commonly Used Contrast Agents for Videofluoroscopy

Rumi Ueha, MD, PhD ; Nogah Nativ-Zeltzer, PhD ; Taku Sato, MD; Takao Goto, MD;
Takaharu Nito, MD, PhD; Koichi Tsunoda, MD, PhD ; Peter C. Belafsky, MD, PhD ;
Tatsuya Yamasoba, MD, PhD

Objectives: Contrast agents (CAs) are essential for upper gastrointestinal and videofluoroscopic swallow studies (VFSSs). Recently, we reported that small amounts of Ba aspiration caused severe acute lung inflammation in a rodent model. However, the underlying molecular biological mechanisms of chronic response to CA aspiration remain unclear. The aims of this study were to explore the underlying molecular biological mechanisms of the chronic response to three kinds of CA aspiration on the lung.

Study Design: Animal model.

Methods: Eight-week-old male Sprague Dawley rats were divided into five groups (n = 6, each group). Three groups underwent tracheal instillation of one of three CAs: barium sulfate (Ba), ionic iodinated contrast agent (ICA), and nonionic iodinated contrast agent (NICA). A sham group was instilled with air and a control group was instilled with saline. All animals were euthanized 30 days after treatment and histological and gene analyses were performed.

Results: No animal died after CA or sham/control aspiration. Ba particles remained after 30 days and caused histopathologic changes and inflammatory cell infiltration. Iodinated ICA and NICA did not result in perceptible histologic change. Expression of Tnf, an inflammatory cytokine was increased in only Ba aspirated rats ($P = .0076$). Other inflammatory cytokines and fibrosis-related genes did not alter between groups.

Conclusion: Aspirated Ba particles did not clear from the lung within a month and caused mild chronic pulmonary inflammation. ICA and NICA did not cause any inflammatory responses in the lungs, suggesting that ICA and NICA may be safer CAs for VFSS than Ba.

Key Words: Contrast agents, chronic response, lung, inflammatory cells, inflammatory cytokines.

Level of Evidence: NA

INTRODUCTION

The use of swallowing function tests for evaluating patients with dysphagia is prevalent.¹ Contrast videofluoroscopic swallow studies (VFSSs) are an essential part of the diagnostic checkup for persons with a suspected swallowing disorder.² Radiographic contrast agents (CAs) are essential in VFSS and upper gastrointestinal studies. Barium sulfate (Ba), ionic iodinated contrast agent (ICA: diatrizoic acid), and nonionic iodinated contrast agent (NICAs: iohexol, iodixanol) are the most common agents currently used for VFSS and upper gastrointestinal investigations.³

This is an open access article under the terms of the Creative Commons Attribution-NonCommercial-NoDerivs License, which permits use and distribution in any medium, provided the original work is properly cited, the use is non-commercial and no modifications or adaptations are made.

From the Department of Otolaryngology (R.U., T.S., T.G., T.N., T. Y.), The University of Tokyo, Tokyo, Japan; Department of Otolaryngology (N.N.-Z., P.C.B.), The University of California, Davis, California, U.S.A.; Department of Artificial Organs and Otolaryngology (K.T.), National Institute of Sensory Organs, Tokyo, Japan

Conflict of Interest: The authors declare that the research was conducted in the absence of any commercial or financial relationships that could be construed as a potential conflict of interest.

Send correspondence to Rumi Ueha, Department of Otolaryngology, The University of Tokyo, 7-3-1 Hongo Bunkyo-ku, Tokyo 113-8655, Japan. Email: ruu1025@yahoo.co.jp

DOI: 10.1002/liv.2.269

CA aspiration is a well-known complication and presents a risk of increased morbidity and mortality.^{4,5} The consequence of CA aspiration must be considered, because these studies are frequently performed on people with risk of aspiration. Basic science studies examining the effects of aspirated CAs on the respiratory system are limited^{2,6} and have focused solely on morphological and histological examinations. Recently, we histologically and biologically demonstrated that small amounts of Ba aspiration caused more acute lung inflammation in a rodent model than ICA and NICA on day 2 following aspiration and suggested that immunological responses may be induced due to insoluble Ba particles being identified as foreign. In addition, we revealed that ICA aspiration induced a high expression of transforming growth factor beta 1 [*Tgfb1*], implying that ICA may cause pulmonary fibrosis in the chronic stage. To gain a further understanding of the effects of aspirated CAs on the respiratory system, detailed investigations of chronic stages following CA aspiration are desirable.

To date, only a few reports have mentioned chronic pulmonary complications due to Ba aspiration, such as pulmonary fibrosis and bronchial granuloma.⁷⁻⁹ The underlying molecular biological mechanisms of the chronic response to Ba aspiration in the respiratory organs remain unclear. Furthermore, pulmonary complications at the chronic stage following ICA and NICA

aspiration have not yet been well elucidated. The purpose of this investigation was to explore the underlying molecular biological mechanisms of the chronic response to three kinds of CA aspiration on the respiratory organs and to clarify the differences in chronic responses to the different agents.

MATERIALS AND METHODS

Rats

Eight-week-old male Sprague Dawley rats (CLEA Japan, Inc., Tokyo, Japan) were housed in a temperature-controlled environment under a 12-hour light–dark cycle with access to food and water ad libitum. All animal experiments were conducted in accordance with institutional guidelines and with the approval of the Animal Care and Use Committee of the University of Tokyo (No. P17-126).

Contrast Agents

We prepared three formulations of CAs; Ba suspension (Barytgen HD, 60% wt/vol, FUSHIMI Pharmaceutical, Kagawa, Japan), ICA (diatrizoate sodium solution: Gastrografin, iodine: 370 mg/mL, Osmolality: 1,940 mOsm/kg H₂O, Viscosity: 8.9 mPa s, Daiichi-Sankyo, Tokyo, Japan), and NICA (iohexol: Omnipaque, iodine: 300 mg/mL, Osmolality: 640 mOsm/kg H₂O, Viscosity: 6.1 mPa s, Daiichi-Sankyo).

Experimental Protocols

The CA instillation procedures were conducted in accordance with the method described in our previous study.³ Rats were allocated to the following five groups (n = 6, Fig. 1). Group 1 received an air injection and served as a sham model. Group 2 received saline injection (60 μ L) and served as a control model. Group 3, 4, and 5 received administration of 60 μ L of Ba suspension (60% wt/vol), ICA, and NICA, respectively. The aspirated amount of 60 μ L in a rat is comparable to 10 mL for 50 kg in human.

Saline and CAs were administered via the larynx to the trachea under direct laryngoscopy under ketamine hydrochloride and xylazine hydrochloride anesthesia (50 μ g/kg body weight and 10 μ g/kg body weight, respectively, ip). Sham and control rats

received air injection and saline administration according to the same schedule as CA-treated rats. All rats were sacrificed on day 30 after the intratracheal procedures. Survival rate of rats was calculated in each group. Chronic responses after each treatment were examined by histological and gene analyses and compared among groups 1–5.

Tissue Preparation

The left and right lobes of the lung were harvested for histological and quantitative real-time polymerase chain reaction (qPCR) analyses on day 30 after intratracheal administration of CA as described previously.³ Histological samples and qPCR samples were obtained from the same rats.

Histological Analyses

Histological analysis was performed on the inferior lobe of the right lung. After fixation in 4% paraformaldehyde for 24 hours, the tissues were dehydrated in a series of graded ethanol solutions, then embedded in paraffin. Serial paraffin sections were cut in 4 μ m thick and prepared for hematoxylin and eosin staining (for evaluation of whole tissue structure) or immunostaining (for inflammatory cells).

Before immunostaining, antigen-retrieval was performed using antigen retrieval solution (S1700; Dako, Tokyo, Japan) and sections were treated with 3% hydrogen peroxide to block endogenous peroxidase activity. The sections were then incubated with Blocking One (Nacalai Tesque, Tokyo, Japan) for 30 minutes at room temperature to block unspecific binding of the antibodies. Primary antibodies against CD3 (1:300 dilution; rabbit monoclonal, Nichirei Corporation, #413601; Tokyo, Japan), and Myeloperoxidase (MPO, 1:300 dilution; rabbit polyclonal, Abcam, ab9535; Cambridge, UK) were detected with peroxidase conjugated appropriate secondary antibodies and a diaminobenzidine substrate. Images of the lungs were captured using a digital microscope camera (Keyence BZ-X700) with \times 4 and \times 20 objective lenses.

Quantitative Real-Time Polymerase Chain Reaction

Total RNA was isolated from the left lobe of the lungs using TRIzol reagent (Life Technologies, Tokyo, Japan) on day 30, then reverse-transcribed into cDNA using ReverTra Ace qPCR RT Master Mix with gDNA Remover (Toyobo, Osaka, Japan),

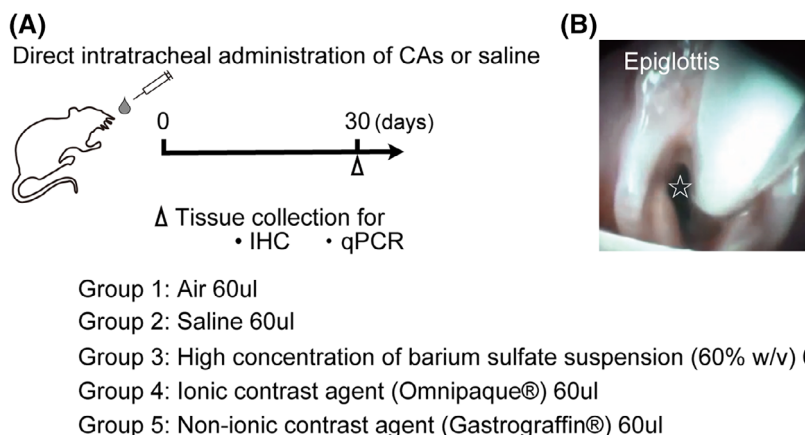


Fig. 1. (A) Experimental timeline. Rats were administered intratracheally CAs or air or saline. Subsequently, the lungs were collected for analyses by IHC and qPCR on day 30. (B) The endoscopic view of intratracheal administration. A white star shows the airway lumen. CAs = contrast agents; IHC = immunohistochemistry; qPCR = quantitative real-time polymerase chain reaction.

TABLE I.
Primers and Probes Used for Real-Time PCR.

Gene		Sequence (5'-3')	Dye
<i>Tnf</i>	Forward	TGTGCCTCAGCCTCTTCTC	FAM probe
	Reverse	GAGCCATTTGGGAACCTCT	
<i>Il1b</i>	Forward	TGTGATGAAAGACGGCACAC	
	Reverse	CTTCTTCTTTGGGTATTGTTTGG	
<i>Actb</i>	Forward	CTAAGGCCAACCGTGAAAAG	SYBR green
	Reverse	ACCAGAGGCATACAGGGACA	
<i>Il6</i>	Forward	CCTGGAGTTGTGAAGAACAAC	
	Reverse	GGAAGTTGGGGTAGGAAGGA	
<i>Ifng</i>	Forward	TGAAAGCCTAGAAAGCTGAAGAAC	
	Reverse	CGTGTACCCTCCTTTTGC	
<i>Tgfb1</i>	Forward	CATTGCTGTCCCGTCAGCA	
	Reverse	AGGTAACGCCAGGAATTGTTGCTA	
<i>Pdgfa</i>	Forward	CTGAGGATGCCTTGGAGACAAC	
	Reverse	TCTTGCAAACCTGCGGGAATG	

PCR = polymerase chain reaction.

according to the manufacturer's instructions. qPCR analysis was performed in duplicate using THUNDERBIRD SYBR qPCR Mix (Toyobo) and an ABI 7500 sequence detection system (Life Technologies). Gene expressions of inflammatory cytokines (tumor necrosis factor [*Tnf*], interleukin-1beta [*Il1b*], interleukin-6 [*Il6*], and interferon gamma [*Ifng*]) and fibrosis-related factors (*Tgfb1* and platelet derived growth factor subunit A [*Pdgfa*]) were evaluated. From various inflammatory cytokines, we selected *Tnf*, *Il1b*, *Il6*, which are common proinflammatory cytokines, and *Ifng*, a T cell and macrophage-related cytokine. The gene specific primers and probes used were rat *Actb* as endogenous control, rat *Tnf*, rat *Il1b*, rat *Il6*, rat *Ifng*, rat *Tgfb1*, and rat *Pdgfa*. The gene-specific primers and probes are shown in Table I. The expression levels of each gene were normalized to the level of *Actb* expression for each sample.

Statistical Analysis

The significance of the results was calculated using one-way analysis of variance with post hoc Tukey's tests for comparing multiple groups. Statistical analyses were performed using GraphPad Prism software (version 6.0; GraphPad Software, Inc.). qPCR data were subjected to logarithmic transformation before analysis. *P* values <.05 was considered to be statistically significant.

RESULTS

Mortality

No animals died in any group.

Barium Particles Are Not Cleared from the Lung and Induce Histological Changes over 30 Days

In group 3, Ba particles stayed in alveolar cavities and induced prolonged pathological changes in the lung such as thickened bronchiolar and alveolar walls, and granulation of the alveoli even on day 30 after tracheal administration of Ba suspension. However, these Ba particles were not phagocytosed by many inflammatory cells comparing with those at the acute stage of the previous study.³ In contrast, saline, ICA, and NICA did not cause pathologic changes in the lung. The persistence of Ba particles in the lung may continue to induce chronic pathologic responses (Fig. 2).

The Majority of Inflammatory Cells Induced by Barium Aspiration in the Chronic Stage Were Lymphocytes

To discriminate the type of inflammatory cells, we next performed immunohistochemical staining. MPO⁺ and CD3⁺ cells were rarely detected in the lungs of airsham, saline-control, ICA-treated, and NICA-treated groups.

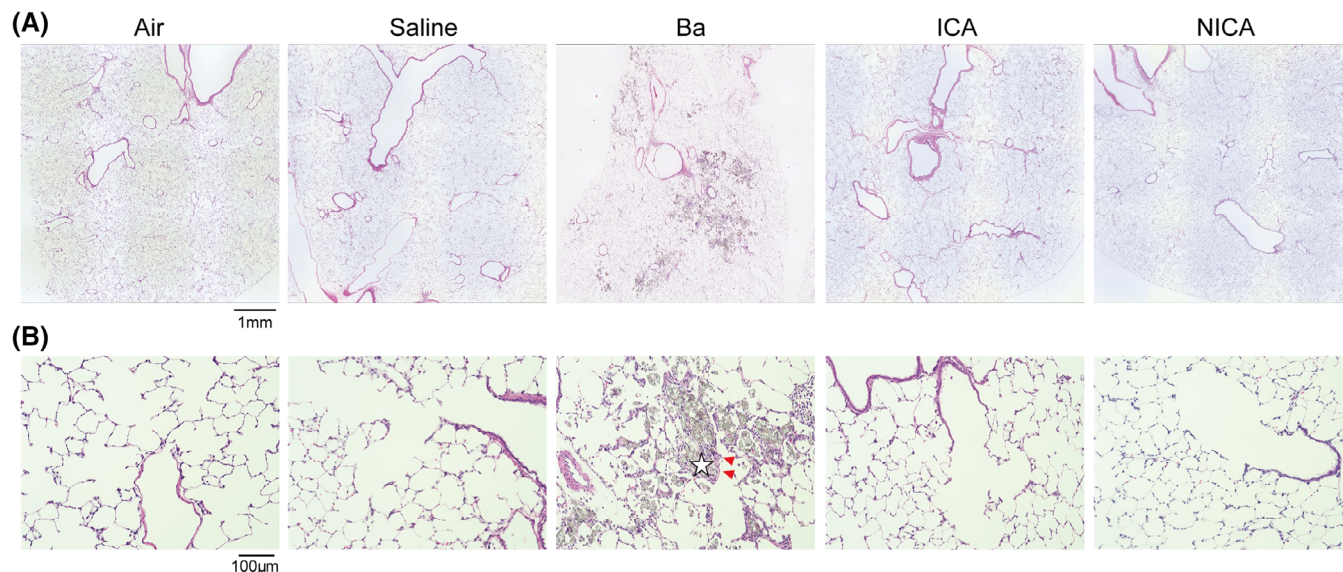


Fig. 2. Representative images of hematoxylin and eosin-stained sections of the lungs from all groups (A, $\times 40$ magnification; B, $\times 200$ magnification). Barium particles were diffusely found in alveolar cavities with inflammatory cells (white stars). Triangles indicate thickening of the alveolar ducts in the Ba-treated rats. ICA = ionic iodinated contrast agent; NICA = nonionic iodinated contrast agent.

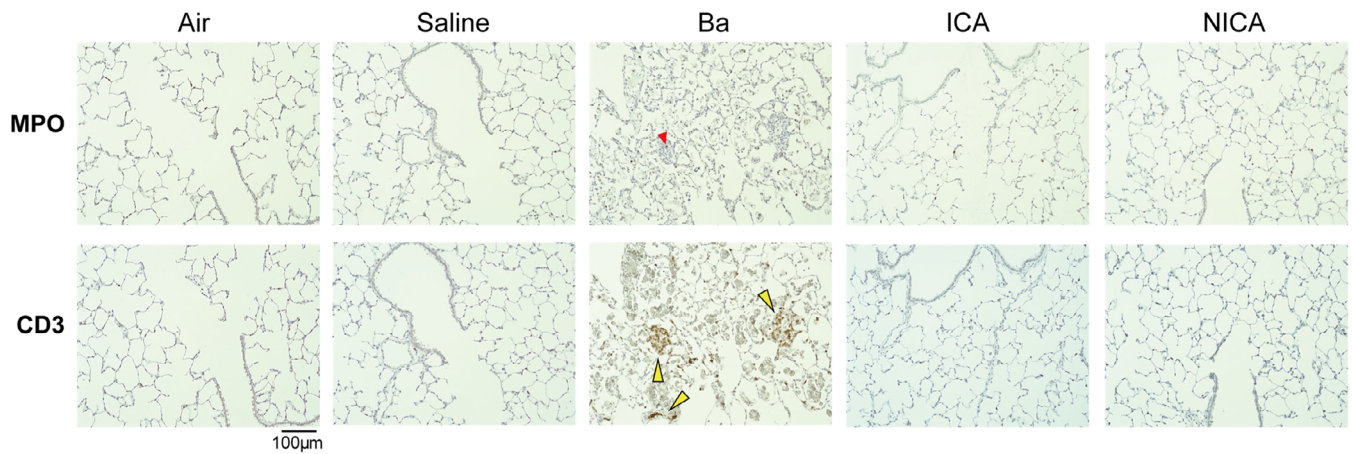


Fig. 3. Representative images ($\times 200$ magnification) of tissues stained with antibodies against myeloperoxidase (MPO, red arrow heads) and CD3 (yellow arrow heads) were shown. In Ba-treated group, MPO⁺ granulocytes and macrophages were rarely found in the alveolar walls, and CD3⁺ lymphocytes infiltrated in the walls of bronchioles and aggregated in granulation tissue. ICA = ionic iodinated contrast agent; NICA = non-ionic iodinated contrast agent.

In the Ba-treated group, however, MPO⁺ granulocytes and macrophages slightly infiltrated in the alveolar walls, and CD3⁺ lymphocytes infiltrated in the walls of the bronchioles and aggregated in granulation tissue (Fig. 3). On the other hand, there were no detectable MPO⁺ and CD3⁺ inflammatory cells in any other group.

Only Barium Sulfate Increases Expression of *Tnf* in the Lung on Day 30 Following Aspiration

To determine the molecular background of chronic respiratory inflammation by CAs aspiration, we analyzed the expression of inflammatory cytokines and fibrosis-related genes in the lungs. qPCR analyses revealed that the expression level of *Tnf* in the Ba-treated group was significantly higher than the air-treated (sham) and saline-treated (control) groups (*Tnf*: $P = .0076, .0497$) (Fig. 4). The expression levels of fibrosis-related genes did not increase significantly in the Ba-treated group, though histological analyses revealed scattered granulation tissue in the lung. In the ICA and NICA groups, there were no significant differences in expression of inflammatory cytokines and fibrosis-related genes in comparison to the sham and control groups ($P > .05$). These results were consistent with the results from histologic analyses and suggest that Ba aspiration-induced pulmonary inflammation persisted at least for a month, and both ICA and NICA caused no chronic inflammatory responses in the lungs.

DISCUSSION

We previously reported on acute pulmonary changes due to CA aspiration, including infiltration of inflammatory cells and pulmonary congestion, and elucidated the background molecular biological mechanisms of acute responses to CA aspiration.³ The results were histologically concordant with many other studies.^{6,10} However, the underlying molecular biological mechanisms of chronic responses to CA aspiration in the lungs have not

been well examined. In this study, we performed histological and molecular-biological examinations of the lungs at the chronic stage (day 30) using a clinically representative animal model with the same dose contrast aspiration as our previous study. We obtained the following results: Ba existed in the lungs 30 days after aspiration, and induced thickening of the bronchioles, CD3⁺ lymphocyte infiltration, and an increase in expression of *Tnf*, an inflammatory cytokine. ICA and NICA did not cause any histological changes and increases in gene expressions of inflammatory cytokines and fibrosis-related factors.

As is well known, Ba particles are insoluble, but both ICA and NICA are water-soluble agents. Thus, the mechanisms of possible pulmonary complications by aspiration may be different depending on the type of aspirated chemicals. In Ba-treated rats, chronic findings such as thickened bronchiolar and alveolar walls, granulation formation in the alveoli, mild infiltration of CD3⁺ lymphocytes, and significant increase of *Tnf* expression were recognized on day 30 after aspiration, but the expression levels of other inflammatory cytokines (*Il1b*, *Il6*, *Ifng*) did not show significant changes. Considering these results, immunological responses that identified insoluble Ba particles as foreign in the acute stage³ may weaken with time.

Ba-induced pulmonary reactions can be quantity-dependent or vary depending on the volume of aspiration.⁵ Cases of incidental diagnosis of Ba aspiration have been reported in asymptomatic individuals long after the aspiration event.^{8,11} Therefore, small quantities of Ba may not have negative pulmonary consequences despite existence of the particles in the lung, either due to an initial weak immune response to Ba particles or the acquisition of immune tolerance. However, persistence of Ba particles and formed granulation tissue may lead to pulmonary fibrosis and dysfunction after a long period of time, and may induce synergistic negative effects on the pulmonary system, particularly in individuals with other pulmonary diseases. Moreover, it is reported that large quantities of Ba aspiration can cause airflow obstruction due to its viscosity and the difficulty to clear its particles

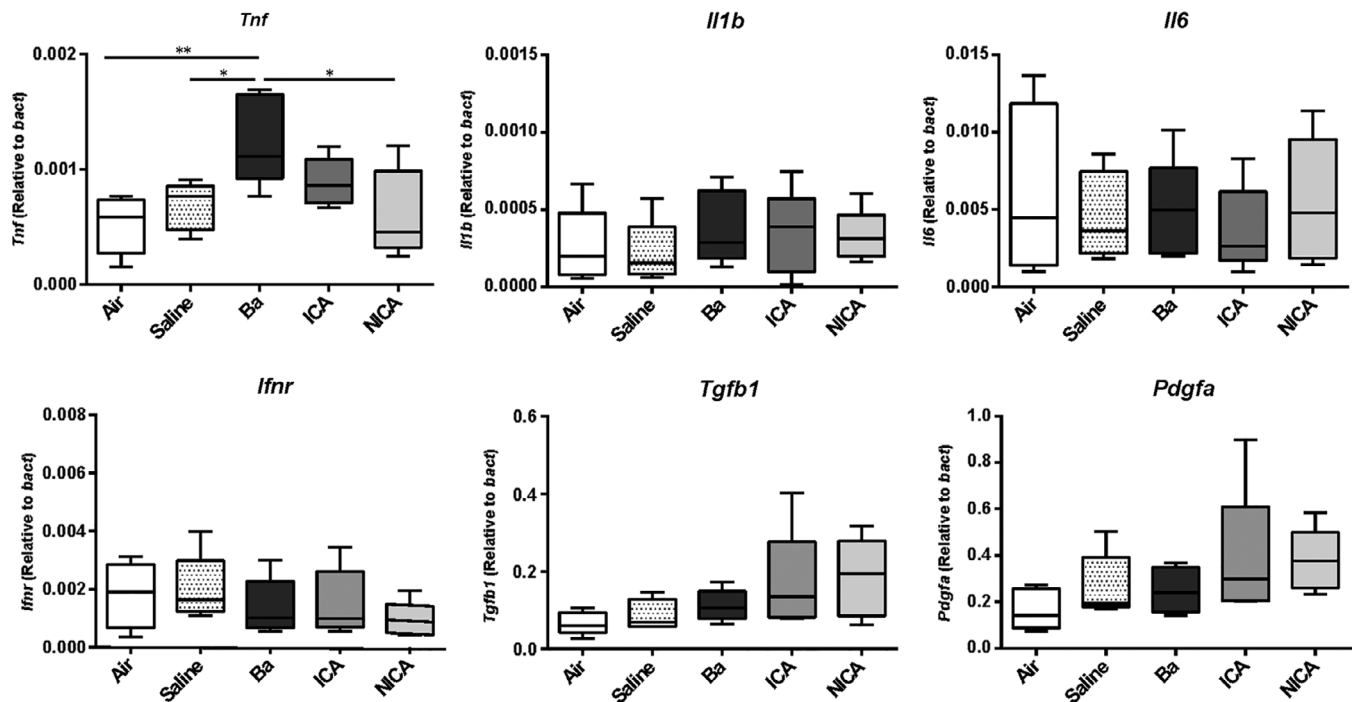


Fig. 4. Tumor necrosis factor (*Tnf*), interleukin-1beta (*Il1b*), interleukin-6 (*Il6*), interferon gamma (*Ifng*), transforming growth factor beta 1 (*Tgfb1*), and platelet derived growth factor subunit A (*Pdgfa*) expression levels in the lungs were quantified by quantitative real-time polymerase chain reaction, and are expressed relative to the expression of the endogenous control gene *Actb*. Data represent the mean, minimum, and maximum (n = 6, *P < .05; **P < .01, one-way analysis of variance).

from the lung, which can lead to hypoxemia and respiratory failure.^{5,12} Hence, confirmation of the amount of aspirated Ba is important for the prediction of pulmonary complications after Ba aspiration, as the extent of lung damage by Ba aspiration has been shown to be directly proportional to the amount.⁵ However, the critical amount of aspirated Ba to cause symptoms is unknown and host factors likely also play a role in determining the onset of illness.

Aspiration of saline, ICA, and NICA did not cause any pathological pulmonary changes and immunological responses in the chronic phase. The high-osmolality of ICA has been associated with pulmonary congestion in the acute stage,² and pulmonary congestion and edema after ICA aspiration are improved within a few days after aspiration.^{3,9} In the chronic stage, it is reported that the reactions to ICA aspiration considerably decreased by the 42nd day,⁹ and a similar result was obtained in this study. In addition, NICA induced little acute inflammation responses in the lung when aspirated in small quantities,³ and the same volume of NICA did not cause any chronic pulmonary reactions. Thus, in the chronic stage, small quantities of ICA and NICA aspiration may not cause pulmonary inflammation and fibrosis, even if some acute inflammatory responses occur after aspiration.

As for limitations of the present study, the evaluation was performed on young rats, which does not reflect the majority of the current clinical population at risk for aspiration. Considering that CA aspiration often occurs in the elderly population or in unhealthy individuals, detailed investigations using aging animal models or

disease animal models such as smoking, asthma, and pulmonary fibrosis would be desirable.

CONCLUSION

Using a rodent model of pulmonary aspiration, this study demonstrated that aspirated Ba particles did not clear from the lung within a month and caused mild chronic pulmonary inflammation. ICA and NICA did not cause any inflammatory responses in the lungs, suggesting that ICA and NICA may be safer CAs for use in VFSS than Ba sulfate. This study utilized both histopathologic and gene analyses to elucidate the underlying mechanisms of chronic inflammatory responses to different CAs.

AUTHOR CONTRIBUTIONS

R. U., T. S., and T. G. developed the concept, designed and performed the experiments, and analyzed the data. N. N.-Z., T. N., K. T., P. C. B., and T. Y. developed the concept and designed the experiments. All authors contributed to interpretation of the data and writing of the manuscript.

BIBLIOGRAPHY

- Horton J, Atwood C, Gnagi S, Teufel R, Clemmens C. Temporal trends of pediatric dysphagia in hospitalized patients. *Dysphagia* 2018;33:655-661.
- Siddiqui MT, Litts JK, Cheney DM, Kuhn MA, Nativ-Zeltzer N, Belafsky PC. The effect of aspirated barium sulfate, iodixanol, and diatrizoic acid on survival and lung injury in a lagomorph model. *Laryngoscope* 2017;127:E148-E152.

3. Ueha R, Nativ-Zeltzer N, Sato T, et al. Acute inflammatory response to contrast agent aspiration and its mechanisms in the rat lung. *Laryngoscope* 2018. <https://doi.org/10.1002/lary.27663>
4. Venkatraman B, Rehman HA, Abdul-Wahab A. High resolution computed tomography appearances of late sequelae of barium aspiration in an asymptomatic young child. *Saudi Med J* 2005;26:665–667.
5. Hamid M, Ullah W, Ur Rashid M, Amjad W, Mukhtar M, Hurairah A. An esophagogram or tracheobronchogram? A review of barium sulfate aspiration. *J Investig Med High Impact Case Rep* 2018;6:2324709618802872. <https://doi.org/10.1177/2324709618802872>
6. Ratcliffe JF. Effect of contrast agents on the lung. *Br J Radiol* 1985;58: 574–576.
7. Hundemer GL, Kumar V, Vaduganathan M. Large-volume barium aspiration. *Proceedings* 2015;28:183–184.
8. Voloudaki A, Ergazakis N, Gourtsoyiannis N. Late changes in barium sulfate aspiration: HRCT features. *Eur Radiol* 2003;13:2226–2229.
9. Ginai AZ, ten Kate FJ, ten Berg RG, Hoornstra K. Experimental evaluation of various available contrast agents for use in the upper gastrointestinal tract in case of suspected leakage. Effects on lungs. *Br J Radiol* 1984;57: 895–901.
10. Davenport D, Cohen MD, Hanna MP, Bugaieski E, Heifetz SA. Studies of iodixanol in the rabbit lung and peritoneum. *Pediatr Radiol* 1999;29: 724–730.
11. Katsanoulas C, Passakiotou M, Mouloudi E, Georgopoulou V, Gritsi-Gerogianni N. Severe barium sulphate aspiration: a report of two cases and review of the literature. *Signa Vitae* 2007;2:25–28.
12. Varatharaj A, Roome C, Allsup S. Barium aspiration. *QJM* 2012;105: 903–904.