

Demonstrating a rare anatomical variation of cardiovascular system by using a new technique

 Serdar Kula,  Osman Tunç¹,  Akif Kavgacı,  Fatma İncedere

Department of Pediatric Cardiology, Faculty of Medicine, Gazi University; Ankara-Turkey

¹BTech Innovation; Ankara-Turkey

Introduction

The persistent left superior vena cava (PLSVC) is the most common congenital anomaly variant of thoracic venous drainage. The right-sided superior vena cava is found in the majority of PLSVC cases. However, an isolated PLSVC with no right superior vena cava is an exceedingly rare venous anomaly since it is present only in 0.09%–0.13% of the patients with congenital heart defects. Contrarily, PLSVC with right-sided superior vena cava affects 0.3%–0.5% of the general population (1, 2).

This manuscript's objective is to show a rare congenital anatomical variation of the cardiovascular system with the use of a less popular but simple and efficacious technique (Appendix 1).

An 11-year-old male patient was referred to our hospital with a preliminary diagnosis of left-sided superior vena cava. A prior echocardiography examination of the patient only detected a wide coronary sinus. A detailed echocardiography examination demonstrated the absence of right vena cava superior. Magnetic resonance (MR) angiography validated the absence of right vena cava superior and showed that hemiazygos vein drained into the PLSVC, which opened to the right atrium via a large coronary sinus.

The Portable Document Format (PDF) is the best-known and most widely utilized data format for the exchange of electronic documents. Even though a lot of people commonly use this document format, the PDF offers more features than many people know of. Our aim was to adopt the already well-known technique

of three-dimensional (3D) PDF for depicting a rare congenital anatomical variation of the cardiovascular system. The adoption of this technique to describe congenital cardiovascular anomalies can be a great merit for medical students, researchers, and clinicians.

The 3D PDF technique can be identified as a PDF document with embedded 3D objects. This technique has great potential for almost every scenario wherein 3D objects should be visualized and exchanged between computers with various operating systems. This format widely utilizes biomedical data for the reconstruction of human anatomy to the advantage of medical students or utilizes clinical characteristics for planning surgery (3, 4). Besides providing educational information for patients and medical students, 3D PDF offers a very efficient and convenient way to distribute 3D structures by embedding 3D objects into scientific publications especially in digital publications.

Since 3D MR imaging has been previously claimed to be sufficient for clinical use, it can be questioned whether 3D PDF has any superiority over 3D MR imaging. The 3D PDF technique provides some additional advantages for medical education and surgical/invasive procedures since it allows near realistic viewing of internal structures and free interaction with anatomical characteristics. The utilization of 3D PDF requires no additional specific hardware or software, only the free and generally embedded ones. Also, 3D PDF documents are smaller than other 3D objects. Therefore, every medical student or clinician can easily benefit from 3D PDF models.

Address for correspondence: Dr. Serdar Kula, Gazi Üniversitesi Tıp Fakültesi,
Çocuk Kardiyoloji Bilim Dalı, Beşevler, Ankara-Türkiye
Phone: +90 312 202 56 26 E-mail: serdarkula@gmail.com

Accepted Date: 25.06.2020 **Available Online Date:** 15.09.2020

©Copyright 2020 by Turkish Society of Cardiology - Available online at www.anatoljcardiol.com
DOI:10.14744/AnatolJCardiol.2020.28742



Within the scope of this study, 3D planning and modeling was conducted by means of Mimics Innovation Suite 22.0 (Materialize, Leuven, Belgium) software. Following the importation of MR angiography dicom file data into Mimics, radiological sections were opened in axial, coronal, and sagittal view plans. Hounsfield Unit values of two-dimensional radiological images were assigned in MR as they were determined with the use of masking. Using the related module of Mimics, the structures were segmented by following the anatomical boundaries of the neighboring tissues. To maintain a detailed modeling phase of the 3D models acquired by Mimics, the design module in Mimics has been imported into 3-Matic 14.0 (Materialise, Leuven, Belgium). Anatomical structures are totally modeled with the use of the design commands supplied by 3-Matic 14.0 software (Fig. 1). The modeling of involved anatomical regions was completed and transferred as 3D PDF, which is among the file transfer features of the abovementioned software (Appendix 1).

Even though it has not been widely adopted yet, routine utilization of 3D PDF in medical disciplines should be assessed, and its use in clinical practice should be further promoted. Newe and Becker (5) searched for articles that cited 3D PDF technique and discovered that 3D PDF figures were actually available in 156 out of 200 articles (78.0%) that were published in the last 10 years. According to Newe and Becker (5), the 3D

content was embedded directly into the PDF version of the articles in only 34 publications. The relatively lower rate of 3D publications might be ascribed to the unawareness and lack of knowledge as regards this technique in the field of medical sciences.

Conclusion

The reason why this manuscript was made is to highlight that the physicians should be encouraged to utilize 3D PDF technique more widely because of its immensely great potential for medical education, scientific research, and clinical communication. Since it would be prudent to expect the enrichment of scientific articles by interactive visualization of 3D images, the journals can encourage their authors to utilize 3D PDF technology.

Acknowledgments: The 3D PDF file mentioned in this study is provided as an attachment (Appendix 1). This document requires Adobe Reader to view it. If no Adobe Reader is available, please click here to download to your desktop. Then, right click on the 3D PDF file and open using an Adobe Reader. Watching the information video regarding its use is suggested prior to the opening of the 3D PDF file (Video 1).

Video 1. Information video regarding the usage of 3D PDF file.

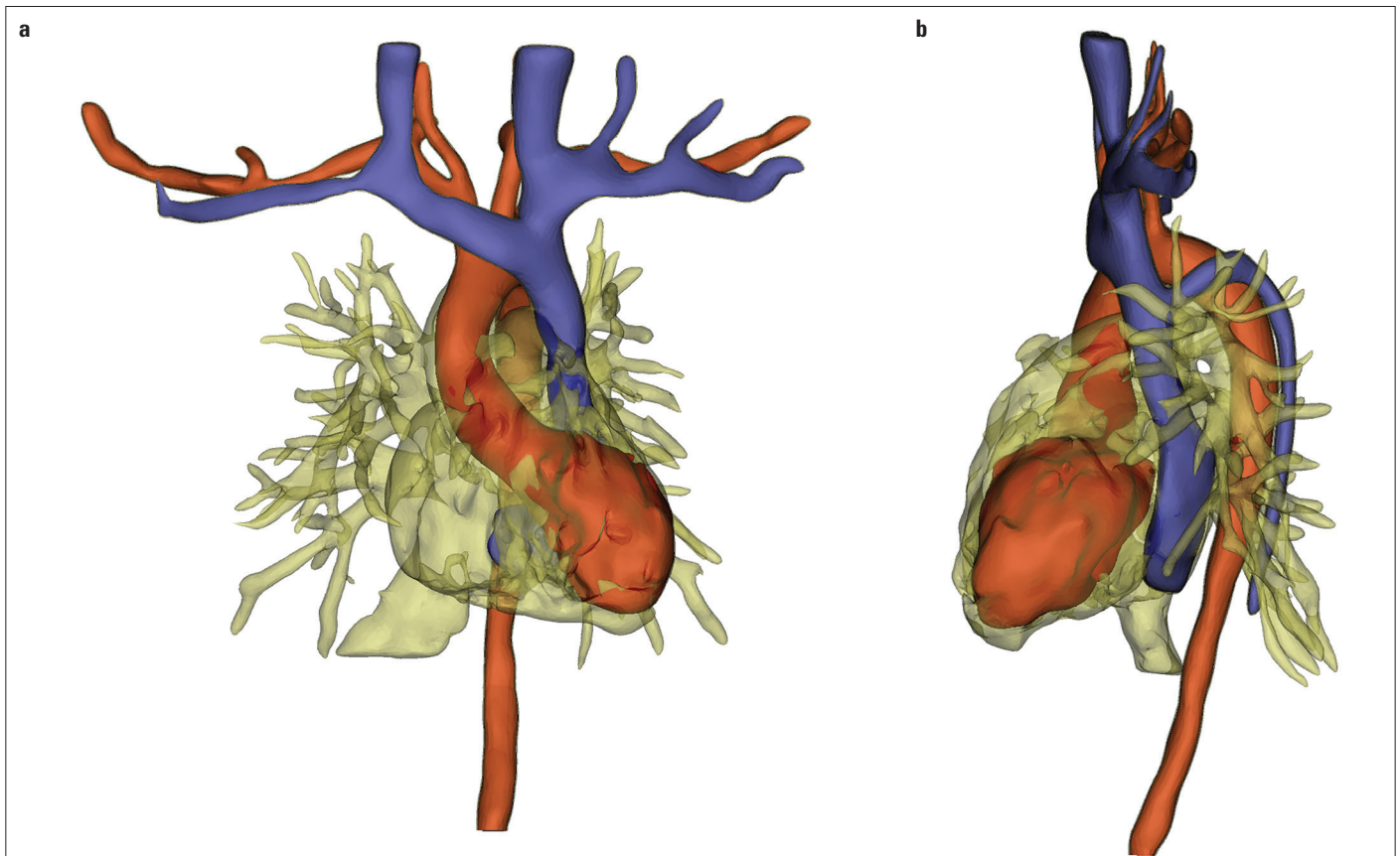


Figure 1. (a) Frontal and (b) lateral reconstructive views of cardiac anatomy with the use of the 3-Matic 14.0 software

Conflict of interest: None declared.

Peer-review: Internally peer-reviewed.

Authorship contributions: Concept – S.K.; Design – S.K.; Supervision – S.K.; Fundings – None; Materials – None; Data collection &/or processing – O.T.; Analysis &/or interpretation – None; Literature search – A.K., F.İ.; Writing – A.K., F.İ.; Critical review – S.K.

References

1. Coblenz MG, Criscito MA, Cohn JD. Persistent left superior vena cava complicating hemodynamic monitoring catheterization. *Crit Care Med* 1978; 6: 32-5.
2. Leibowitz AB, Halpern NA, Lee MH, Iberti TJ. Left-sided superior vena cava: A not-so-unusual vascular anomaly discovered during central venous and pulmonary artery catheterization. *Crit Care Med* 1992; 20: 1119-22.
3. Mavar-Haramija M, Prats-Galino A, Méndez JA, Puigdelívoll-Sánchez A, de Notaris M. Interactive 3D-PDF Presentations for the Simulation and Quantification of Extended Endoscopic Endonasal Surgical Approaches. *J Med Syst* 2015; 39: 127.
4. Neue A, Becker L, Schenk A. Application and evaluation of interactive 3D PDF for presenting and sharing planning results for liver surgery in clinical routine. *PLoS One* 2014; 9: e115697.
5. Neue A, Becker L. Three-Dimensional Portable Document Format (3D PDF) in Clinical Communication and Biomedical Sciences: Systematic Review of Applications, Tools, and Protocols. *JMIR Med Inform* 2018; 6: e10295.