

Use of AccuVein AV400 for identification of probable RICH



Fatmah AlZahrani, MD,^a Megan Crosby, BSc,^b and Loretta Fiorillo, MD, FRCPC^{a,c,d}
Edmonton, Alberta

Key words: diagnostic technique; pediatrics; rapidly involuting infantile hemangioma; vascular malformation; vein finder.

INTRODUCTION

Visual diagnostic tools are commonly used in dermatology such as the Wood's lamp, the Tzanck smear, or the potassium hydroxide preparation. One thing the tools mentioned above have in common is that they are readily available in a dermatologist's office and give almost immediate results.

In pediatric dermatology, there is a greater need to accurately diagnose skin lesions using the least invasive methods to minimize the amount of distress both to the child and to the families.

Congenital hemangiomas (CH) are common benign vascular neoplasms that begin to proliferate in utero and complete development at birth. Rapidly involuting congenital hemangioma (RICH) is a subtype of CH that begins involution in the first few weeks of life, reaching completion around 12 to 24 months. We report a case of an infant with a RICH occurring on the supraclavicular area that was diagnosed using an AccuVein AV400 vein finder.

CASE REPORT

A 5-month-old, dark-skinned boy presented to clinic for follow-up for possible punch biopsy of a single, nonpulsatile, well-demarcated, dark brown, atrophic plaque measuring 10 cm × 2.5 cm with a linear, midline depression in the center and an elevated, compressible, soft border that was more pale than the central portion. The atrophic plaque was first observed at birth when it measured

Abbreviations used:

CH:	congenital hemangioma
NICH:	noninvoluting congenital hemangioma
PICH:	partially involuting congenital hemangiomas
RICH:	rapidly involuting congenital hemangioma

11 cm × 3.5 cm on the left supraclavicular area (Fig 1).

Birth history was unremarkable, and the patient was healthy with no allergies, medications, or other medical conditions. The differential diagnosis at the first visit was smooth muscle hamartoma, semianular lipoatrophy, and, less likely, RICH.

Before selecting the punch biopsy site, one vein approximately 0.3 mm in size was visible to the naked eye within the plaque. To minimize the bleeding and avoid puncturing a large vein, an infrared AccuVein AV400 vein finder was obtained and used to ensure we would be able to avoid the large visible vein.

When applying the vein finder to the lesion, one large vein with an extensive network of small superficial branching vessels was seen specifically localized to the area of the atrophic plaque. A working diagnosis of probable RICH was made (Fig 2).

Follow-up 1 year later showed an 11 cm × 3 cm atrophic plaque with a red/brown linear depression in the center and an elevated, compressible, soft border. The child was discharged from the

From the Divisions of Dermatology^a and Pediatric Dermatology^c and Faculty of Medicine and Dentistry,^b University of Alberta and the Dermatology Residency Program, University of Alberta, Walter C Mackenzie Health Science Centre.^d

Funding sources: None.

Conflicts of interest: None disclosed.

Correspondence to: Fatmah AlZahrani, MD, Department of Medicine, Division of Dermatology, 8-112T CSB, 11350 – 83 Avenue, Edmonton, Alberta, T6G 2G3, Canada. E-mail: fsa.zahrani@gmail.com.

JAAD Case Reports 2019;5:213-5.

2352-5126

© 2018 by the American Academy of Dermatology, Inc. Published by Elsevier, Inc. This is an open access article under the CC BY-NC-ND license (<http://creativecommons.org/licenses/by-nc-nd/4.0/>).

<https://doi.org/10.1016/j.jcdr.2018.11.022>

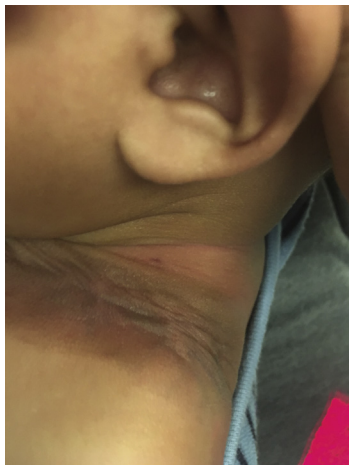

Fig 1. Atrophic plaque on the left supraclavicular area of a 5-month-old boy.

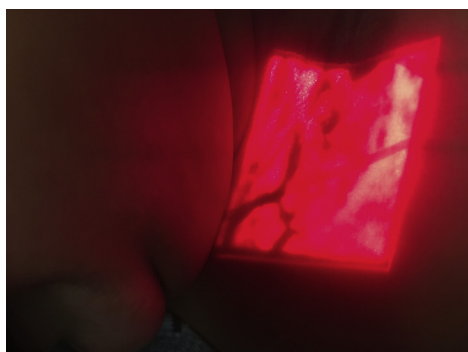


Fig 2. Atrophic plaque as seen under the vein finder.

dermatology clinic with the diagnosis of a resolved RICH with residual skin atrophy.

DISCUSSION

There are 3 types of congenital hemangiomas: RICH, the noninvoluting congenital hemangioma (NICH), and partially involuting congenital hemangiomas (PICH). In the first few weeks of life, it is expected for RICH subtypes to involute, the NICH subtype persists, whereas there is partial involution of PICH. RICH lesions are rare compared with other types of hemangiomas and tend to be located on the head, trunk, and arms.^{1,2} Diagnosis is typically done based on history of involution since birth and clinical examination; however, if the diagnosis is unclear, magnetic resonance imaging shows areas of heterogeneity, angiography displays arterial aneurysms and large dilated draining veins, and histopathology from biopsy shows that RICH lesions do not express glucose transporter-1 protein.^{3,4} Pathologic specimens show that the dilated veins of RICH tend to be thick walled, and sometimes they can be seen clinically even at the first visit.^{2,3} The projected

prognosis for RICH is that it involutes within a year to a well-defined pale atrophic plaque with dilated veins, and case reports have noted an occasional RICH that may flatten but persists in a partially involuted state.⁴⁻⁶

The presence of a large central vein indicated a vasculature network within the atrophic plaque, making the diagnosis of smooth muscle hamartoma and semiannular lipoatrophy less likely. The post-natal behavior of involution in the presence of a dilated vein further strengthens the argument for a diagnosis of RICH. Further workup could confirm the diagnosis of RICH; however, RICH has many overlapping morphologic, histopathologic, and radiographic similarities to other CHs. Small retrospective studies have diagnosed RICH without radiographic or histopathology; however, the absence of tissue biopsy to confirm the diagnosis is a limitation of this case.²

Management involves serial observation with an option for pulsed dye laser to diminish discoloration or surgical excision depending on the postinvolution changes. The infrared vein finder is a minimally invasive tool commonly used in the emergency department and on pediatric wards mainly to help visualize veins to assist with intravenous line insertions.⁷⁻⁹

In pediatric dermatology, it is important to have accurate, yet minimally invasive techniques of diagnosing cutaneous lesions both for improving management of patients and minimizing distress to patients and their families. In this case, the use of an infrared AccuVein AV400 vein finder allowed us to both provide diagnosis to the family using an immediate visual aid and prevent a complication of obtaining a biopsy of a highly vascular lesion. Although a biopsy would be ideal to confirm this clinical diagnosis, the young age of the child prompted us to delay biopsy until the child was older or if the parents noticed a change. It would be beneficial to see future studies on the use and precision of infrared vein finders on vascular lesions, especially for pediatric populations.

REFERENCES

1. Boon LM, Enjolras O, Mulliken JB. Congenital hemangioma: evidence of accelerated involution. *J Pediatr.* 1996;128:329-335.
2. Deveza E, Puzenat E, Manzoni P, Humbert P, Aubin F. Congenital hemangiomas: Report on ten patients. *Arch Pediatr.* 2015;22(7):685-692.
3. Berenguer B, Mulliken JB, Enjolras O, et al. Rapidly involuting congenital hemangioma: clinical and histopathologic features. *Pediatr Dev Pathol.* 2003;6:495-510.
4. Nasser E, Piram M, McCuaig CC, Kokta V, Dubois J, Powell J. Partially involuting congenital hemangiomas: a report of 8 cases and review of the literature. *J Am Acad Dermatol.* 2014;70:75-79.

5. Liang MG, Frieden IJ. Infantile and congenital hemangiomas. *Sem Pediatr Surg.* 2014;23(4):162-167.
6. Maguiness S, Uihlein LC, Liang MG, Kozakewich H, Mulliken JB. Rapidly involuting congenital hemangioma with fetal involution. *Pediatr Dermatol.* 2015;32(3):321-326.
7. Kaddoum RN, Angheliescu DL, Parish ME, et al. A randomized controlled trial comparing the AccuVein AV300 to standard insertion technique for intravenous cannulation of anesthetized children. *Pediatr Anesth.* 2012;22(9):884-889.
8. Hess HA. A biomedical device to improve pediatric vascular access success. *Pediatr Nurs.* 2010;36(5):259-263.
9. Cuper NJ, de Graaff JC, Hartman BJ, Verdaasdonk RM, Kalkman CJ. Difficult arterial cannulation in children: is a near-infrared vascular imaging system the answer? *Br J Anaesth.* 2012;109(3):420-426.