

A novel stop mutation (p.(Gln22*)) of DAX1 (NR0B1) results in late-onset X-linked adrenal hypoplasia congenita

Judith Gerards¹, Michael M Ritter², Elke Kaminsky³, Andreas Gal⁴,
Wolfgang Hoepfner⁴ and Marcus Quinkler¹

¹Endocrinology in Charlottenburg and ²Diabetology and Endocrinology, HELIOS Klinikum Berlin-Buch, Berlin, Germany, ³Praxis für Humangenetik, and ⁴Bioglobe GmbH, Hamburg, Germany

Correspondence
should be addressed
to M Quinkler

Email
marcusquinkler@t-online.de

Summary

DAX1 (NR0B1) is an orphan nuclear receptor, which plays an important role in development and function of the adrenal glands and gonads. Mutations in DAX1 cause X-linked adrenal hypoplasia congenita (X-linked AHC), which is characterized by adrenal insufficiency (AI) and hypogonadotropic hypogonadism (HHG). Affected boys present with adrenal failure usually in childhood and, later in life, with delayed puberty. However, patients with a late-onset form of X-linked AHC have also been described in the past years. We report a male patient who presented with symptoms of an adrenal crisis at the age of 38 years and was later diagnosed with HHG. Family history was positive with several male relatives diagnosed with AI and compatible with the assumed X-chromosomal inheritance of the trait. Direct sequencing of DAX1 of the patient revealed a hemizygous cytosine-to-thymine substitution at nucleotide 64 in exon 1, which creates a novel nonsense mutation (p.(Gln22*)). In order to compare the clinical presentation of the patient to that of other patients with X-linked AHC, we searched the electronic database MEDLINE (PubMed) and found reports of nine other cases with delayed onset of X-linked AHC. In certain cases, genotype–phenotype correlation could be assumed.

Learning points:

- X-linked AHC is a rare disease characterized by primary AI and hypogonadotropic hypogonadism (HHG). The full-blown clinical picture is seen usually only in males with a typical onset in childhood.
- Patients with a late-onset form of X-linked AHC have also been described recently. Being aware of this late-onset form might help to reach an early diagnosis and prevent life-threatening adrenal crises.
- Adult men with primary AI of unknown etiology should be investigated for HHG. Detecting a DAX1 mutation may confirm the clinical diagnosis of late-onset X-linked AHC.
- In relatives of patients with genetically confirmed X-linked AHC, targeted mutation analysis may help to identify family members at risk and asymptomatic carriers, and discuss conscious family planning.

Background

X-linked adrenal hypoplasia congenita (X-linked AHC) is caused by a mutation of the DAX1 gene (1). Patients with this disease, mainly males whereas also a few females have been described, usually present themselves with signs and symptoms of primary AI in early infancy or anytime

throughout childhood. The adequate therapy consists of a lifelong glucocorticoid and mineralocorticoid replacement therapy. At the expected time of puberty, patients present with hypogonadotropic hypogonadism (HHG) and delay or lack of sexual maturation (2). Next to the typical form

of presentation in early infancy or childhood, there have been some X-linked AHC patients described that show an onset of symptoms in late adolescence or even adulthood (3, 4, 5, 6, 7, 8, 9). These late-onset cases suggest a milder form of X-linked AHC; however, they are also susceptible to adrenal crisis often triggered by an unrelated severe illness or other environmental stress (8).

Case presentation

The patient was born with a length of 53 cm and a weight of 4200 g. As a child, the patient grew fast until the age of 14 years – his growth continued until the age of 16 years (final height 186 cm). In this period, vertigo attacks started and the patient needed more rest. Pubic hair growth started at the age of 15 years, but otherwise his puberty was delayed. The growth of a beard started with 17 years. The patient reported that muscle composition had ever been slight, and muscle buildup had been hard to achieve. The patient did not report any olfactory problems in terms of a Kallmann's syndrome. He affirmed a question regarding salt craving.

At the age of 38 years, he complained about fatigue, vertigo, an inclination of collapses. It worsened with nausea and vomiting during a feverish episode (38.3°C) due to acute tonsillitis. Upon clinical examination, low blood pressure (105/65 mmHG), increased heart rate (104 bpm) and a higher respiratory rate (22 breaths/min) were measured. Darker skin pigmentation was noticed. Testicular volume was reported with 12 mL bilaterally (Tanner stage IV). Except for dehydration and painful, swollen tonsils, clinical examination did not show any other pathologic findings. Upon admission, serum sodium was low (122 mmol/L); potassium was in normal range (3.8 mmol/L).

Due to a positive familial history regarding primary AI and the current clinic, an adrenal crisis due to tonsillitis was assumed and a therapy with hydrocortisone, fludrocortisone and rehydration was initiated. Upon treatment, the patient showed clinical recovery within a day. Hormonal analysis confirmed primary AI with an increased ACTH (>2000 ng/L; normal range (NR): 7.2–63 ng/L), low basal serum cortisol (52 µg/L; (NR): 62–194 µg/L), decreased aldosterone (11 ng/L; (NR): 20–150 ng/L) and an increased renin concentration (1697 ng/L, (NR): 1.5–18 ng/L). Adrenal gland antibodies (21-hydroxylase antibodies) could not be detected; hepatitis serology and HIV antibodies were negative. Thyroid function and blood glucose values were normal. A normal calcium level excluded a hypoparathyroidism.

Sonography of the kidneys and adrenal glands was performed but did not show any abnormalities. Chest X-ray was normal.

Two years later, the patient reported of impaired libido, which had been decreasing since one year. At that time point, luteinizing hormone (LH) and prolactin were tested normal. Follicle-stimulating hormone (FSH), sex hormone-binding globulin (SHBG) and testosterone have been increased. Inhibin B was lowered, but testis-sonography was without pathological findings, despite a testicular volume of 6 mL bilaterally (Tanner stage II). Semen analysis revealed azoospermia (semen volume: 3.4 mL; sperm count: 0×10^6 per mL; motility: 0%; abnormal forms: not done). On physical examination, bilateral gynecomastia (2 cm), sparse beard growth,

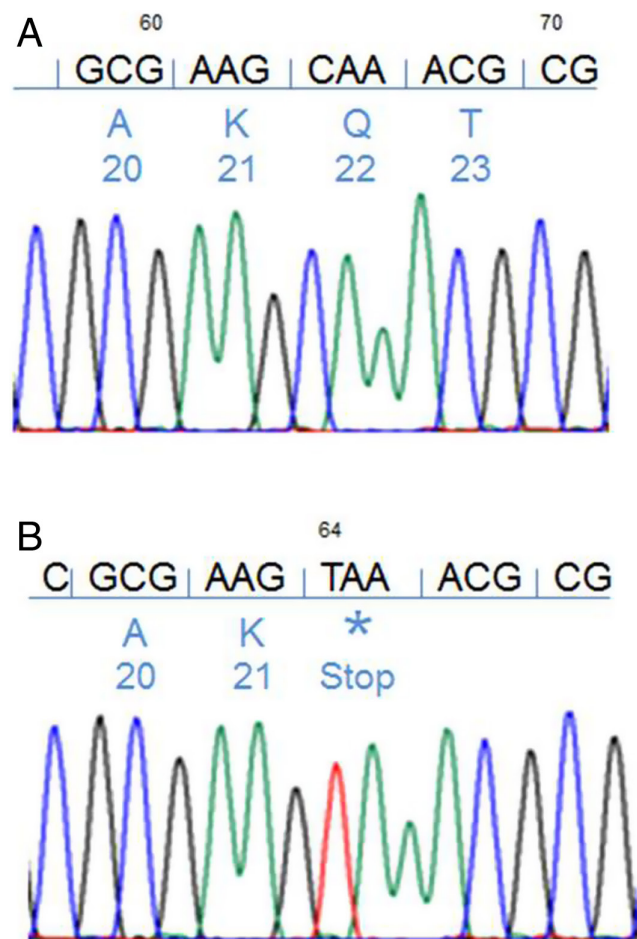


Figure 1
Partial DNA sequence chromatogram of DAX1, exon 1. Top line shows the sequence of DNA with nucleotide (above) and codon (below) numbers as well as the amino acids (one letter code). (A) Reference sequence. (B) Sequences of a male patient presenting with primary adrenal insufficiency and hypogonadotropic hypogonadism due to a c.64C>T variant of DAX1.



reduced pubic hair and enhanced skin pigmentation were found. Testosterone replacement was started with dermal testosterone (testogel) and was switched to testosterone-undecanoat injections every 12 weeks during follow-up.

The combined presentation of primary AI and progressive HHG, together with a positive family history (four male cousins on mother's side of the family with primary AI) raised suspicion of DAX1-related X-linked AHC and mutation analysis was initiated.

Investigation

Direct sequencing of the DAX1 gene revealed a hemizygous cytosine-to-thymine substitution at nucleotide 64 in codon 22, exon 1 (Fig. 1), which creates a nonsense mutation (TAA) at position 22, instead of glutamine (p.(Gln22*)). The mutation lies within the first repetitive motif of the amino terminus. This finding suggests a mutant NROB1, resulting in X-linked AHC.

Treatment

The patient's treatment is shown in Table 1.

Outcome and follow-up

Follow-up (2009–2016) was performed regularly every six months with laboratory tests and physical examinations (Table 1).

Discussion

X-linked AHC characterized by AI and hypogonadotropic hypogonadism (HHG) and is due to mutations in DAX1, the gene encoding an orphan nuclear receptor. Affected boys present with adrenal failure usually in childhood and, later in life, with delayed puberty (2). However, patients with a late-onset form of X-linked AHC have also been described in the past years. DAX1 protein acts as transcriptional repressor.

The electronic database MEDLINE (PubMed) was searched and we identified nine other cases of late-onset X-linked AHC with six different mutations (Table 2) (3, 4, 5, 6, 7, 8, 9): Two nonsense mutations (p.(Gln37*), p.(Trp39*) (3, 4, 8)), three missense mutations (p.(Tyr380Asp), p.(Iso439Ser) and p.(Ser259Pro) (5, 6, 9)), and a deletion of three nucleotides resulting in the loss of an amino acid (p.305delGly) (7). Locations of the different patients' mutations are shown in Fig. 2.

Investigation of clinical presentation revealed that seven patients with late-onset X-linked AHC presented with primary AI (Table 2), but only four of the patients have complete HHG. One subject has partial HHG (case 3) and two did not develop HHG up to now (case 9 and 10). Azoospermia was found in four patients, oligospermia was described in two. In the other patients, semen analysis was not performed; however, normal fertility was stated in two patients (case 9 and 10). An interesting aspect of the clinical history of the patient (reported by us) is the progressive course of HHG with shrinkage of

Table 1 Laboratory values upon re-evaluation and medication of the patient with X-chromosomal adrenal hypoplasia congenita (X-linked AHC).

Parameter	Unit	Reference value	Reference value					
			Nov. 08	Sep. 09	Sep. 10	Nov. 12	Jul. 14	Jul. 16
ACTH	pg/mL	1.6–46	>1250 (+)	n.d.	n.d.	n.d.	1250 (+)	612.8 (+)
17-OH-progesterone	ng/mL	0.2–1.3	0.59	0.32	0.46	n.d.	n.d.	0.4 (–)
DHEA	ng/mL	550–4100	83 (–)	<50 (–)	53 (–)	110 (–)	n.d.	41.4 (–)
Androstenedione	ng/mL	0.29–2.67	0.20 (–)	0.10 (–)	0.10 (–)	0.27 (–)	n.d.	0.01 (–)
Testosterone	ng/mL	2.5–9.0	2.6	1.7 (–)	2.0 (–)	7.4	3.23	1.67
LH	U/mL	2.0–6.2	3.7	2.8	2.5	n.d.	2.29	2.74
SHBG	nmol/L	13–62	35.3	30	n.d.	n.d.	34.4	31.1
Renin	ng/L	2.0–24.6	66.50 (+)	n.d.	n.d.	34.4 (+)	366.6 (+)	14.5
Serum potassium	mmol/L	3.4–5.2	3.5	3.8	3.8	4	4.1	4.4
Medication	Hydrocortisone (mg/day)		25	25	25	25	20	20
	Fludrocortisone (mg/day)		0.1	0.1	0.1	0.1	0.1	0.1
	Testosterone					Testosterone gel 25 mg/day	Testosterone- undecanoat every 12 weeks	

(+) indicating an increased value, (–) indicating a decreased value. Hormone measurements were performed by chemiluminescence immunoassays using Immulite by Siemens and Liaison by Diasorin.

ACTH, adrenocorticotropic hormone; DHEA, dehydroepiandrosterone; LH, luteinizing hormone; n.d., not done; SHBG, sex hormone-binding globulin.



Table 2 Clinical and genetic features of patients with late-onset X-chromosomal adrenal hypoplasia congenita (X-linked AHC).

Case No.	First clinical signs	Age at diagnosis		Sperm analysis	Testicular volume (mL)	DAX1 mutation	Mother heterozygous	Reference
		PAI (years)	HHG (years)					
1	Fatigue, dizziness, adrenal crisis	38	40	Azoospermia	6 mL (b)	<u>p.(Gln22*)</u>	+	This case
2	Fatigue, nausea, hyperpigmentation	20	20	Azoospermia	4 mL (b)	<u>p.(Gln37*)</u>	+	4
3	Fatigue, sore throat, dizziness	19	24	Oligospermia	20 mL (b)	<u>p.(Trp39*)</u>	+	3
4	Present 5 years before diagnosis: fatigue, weight loss, orthostatic dizziness, eunuchoidal habitus	28	28	Azoospermia	5 mL (b)	<u>p.(Tyr380Asp)</u>	+	6
5	Present 5 years before diagnosis: fatigue, nausea, dizziness	28	28	Severe oligospermia	6 mL (b)	<u>p.(Iso439Ser)</u>	+	5
6	Skin pigmentation (small testes in examination)	18	18	Azoospermia	n.a. ('small testes')	305delGly	+	7
7	Delayed puberty, low weight, episodes of weakness (during illnesses)	22	22	n.d.	2 mL/3 mL	<u>p.(Trp39*)</u>	n.a.	8
8	Hypogonadism, later impaired co-syntropin stimulation, sudden death during intensive physical activity	23	18	n.d.	n.a.	<u>p.(Trp39*)</u>	n.a. (brother of case 7)	8
9	Not mentioned (PAI)	28	'Normal fertility'	n.d.	n.a.	<u>p.(Ser259Pro)</u>	+	9
10	Not mentioned (PAI)	36	'Normal fertility'	n.d.	n.a.	<u>p.(Ser259Pro)</u>	+(brother of case 9)	9

b, bilaterally; HHG, hypogonadotropic hypogonadism; n.a., not available; n.d., not done; PAI, primary adrenal insufficiency; (+), yes; (-), no.

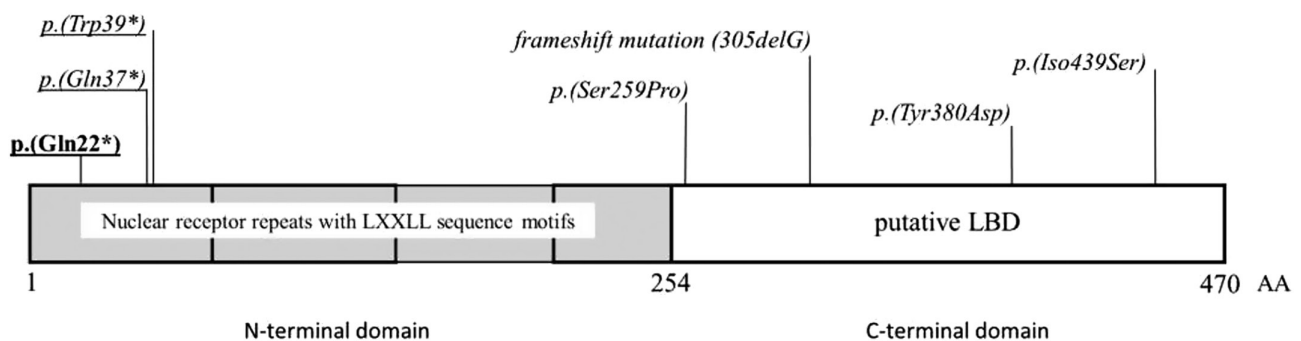


Figure 2

Putative domain structure of DAX1 and location of the variants associated with late-onset X-chromosomal adrenal hypoplasia congenita (X-linked AHC) listed in Table 2. The mutation described in this report is underlined and written in bold. Variants leading to immediate or premature termination of protein translation are underlined, whereas missense mutations are written in italics. LBD, ligand-binding domain.



testicular volume, decreasing libido and appearance of gynecomastia after the diagnosis of AI.

Only three patients had a positive family history for primary AI with a segregation pattern compatible with maternal inheritance. Cases 7 and 8 are important to highlight because these two brothers presented first with hypogonadism and later on with an impaired cortisol response to co-syntropin stimulation. Case 8 passed away suddenly during intensive physical activity and before hydrocortisone medication was started (8).

The cases with missense mutations seem similar in phenotype, because all cases (cases 4, 5, 9 and 10) initially reported signs of adrenal insufficiency (Table 2). Case 5 had a missense mutation in the putative LBD (5), thus alternating the structure within the carboxy-terminal region of the protein. Missense mutations tend to cluster in this region and account for approx. 25% of all DAX1 mutations. Also the other known mutations causing late-onset X-linked AHC are also found in the putative LBD region. These mutations seem to alter protein folding, thereby impairing nuclear localization and cofactor recruitment.

The cases with nonsense mutations, which are located in the part of the gene encoding the first amino-terminal nuclear receptor repeat, do not share a similar clinical pattern, because two patients presented first with signs of hypogonadism (cases 7 and 8), whereas the other two (cases 2 and 3) with signs of AI. This suggests some other additional DAX1-unrelated genetic, epigenetic and/or nongenetic factors involved in the phenotype.

The DAX1 gene consists of an internal in-frame translation start site at the methionine codon 83 with a partially conserved Kozak consensus sequence (4). The data of Ozisik *et al.* strongly suggest that in patients with nonsense mutations in the gene encoding the extreme amino terminus of DAX1, the internal in-frame translation generates a shorter DAX1 protein that partially rescues the clinical phenotype of the patients (4). In addition, low levels of truncated proteins were found in comparison to the wildtype thus indicating lower translation efficiency from the alternate start site (4). However, some of the naturally occurring nonsense or frameshift mutations that cause a premature termination codon 5' to the putative alternative start site (codon 83) are associated with the classical AHC phenotype (4).

Based on these findings, we hypothesize a similar mechanism with an alternate initiation codon in our patient with the p.(Gln22*) mutation, otherwise the

largely truncated protein would be nonfunctional with total loss of repression activity of DAX1 and a classical X-linked AHC with clinical manifestation in early childhood could be expected.

Up to date, there is no clear genotype–phenotype correlation of the DAX1 mutations, and especially, no explanation for the difference between a late-onset and a classical X-linked AHC, as well as X-linked AHC with only primary AI or in combination with HHG are poorly understood. This phenotypic variability might be due to other factors, such as modifier genes, compensation from other genes, epigenetic or nongenetic factors. Therefore, it seems crucial to further investigate families harboring DAX1 mutations, thus identifying those modulators.

The history of the presented patient shows that the detection of a rare disease often takes a long time even though there are affected family members in former generations. As can be seen in this case study, it is important to identify DAX1 mutations for genetic counseling regarding conscious family planning, pregnancies and especially for the early identification of patients at risk for primary AI. Immediate steroid hormone replacement in family members that reveal impaired adrenal function can prevent those patients from adrenal crises as first manifestation of the disease.

Declaration of interest

The authors declare that there is no conflict of interest that could be perceived as prejudicing the impartiality of the research reported.

Funding

This research did not receive any specific grant from any funding agency in the public, commercial or not-for-profit-sector.

Patient consent

Written informed consent has been obtained from the patient for publication of the submitted article and any accompanying images.

Author contribution statement

Judith Gerards is a medical student. She did the research for this article, assembled patient's medical data, compared late-onset forms of X-linked AHC and wrote the manuscript. Michael M Ritter identified further family members with this DAX1 mutation, and helped writing the manuscript. Elke Kaminsky did the mutational analysis, and helped writing the manuscript. Andreas Gal and Wolfgang Hoepfner were our counselor in genetic issues and helped writing the manuscript. Marcus Quinkler treated the patient, coordinated the research, analyzed the literature and wrote the manuscript.



References

- 1 Muscatelli F, Strom TM, Walker AP, Zanaria E, Récan D, Meindl A, Bardoni B, Guioli S, Zehetner G, Rabl W *et al.* 1994 Mutations in the DAX-1 gene give rise to both X-linked adrenal hypoplasia congenita and hypogonadotropic hypogonadism. *Nature* **1994** 672–676. (doi:10.1038/372672a0)
- 2 Achermann JC, Meeks JJ & Larry Jameson J 2001 Phenotypic spectrum of mutations in DAX-1 and SF-1. *Molecular and Cellular Endocrinology* **185** 17–25. (doi:10.1016/S0303-7207(01)00619-0)
- 3 Raffin-Sanson M-L, Oudet B, Salenave S, Brailly-Tabard S, Pehuet M, Christin-Maitre S, Morel Y, Young J *et al.* 2013 A man with a DAX1/NROB1 mutation, normal puberty, and an intact hypothalamic-pituitary-gonadal axis but deteriorating oligospermia during long-term follow-up. *European Journal of Endocrinology* **168** K45–K50. (doi:10.1530/EJE-12-1055)
- 4 Ozisik G, Mantovani G, Achermann JC, Persani L, Spada A, Weiss J, Beck-Peccoz P, Jameson JL *et al.* 2003 An alternate translation initiation site circumvents an amino-terminal DAX1 nonsense mutation leading to a mild form of X-linked adrenal hypoplasia congenita. *Journal of Clinical Endocrinology and Metabolism* **88** 417–423. (doi:10.1210/jc.2002-021034)
- 5 Tabarin A, Achermann JC, Recan D, Bex V, Bertagna X, Christin-Maitre S, Ito M, Jameson JL, Bouchard P *et al.* 2000 A novel mutation in DAX1 causes delayed-onset adrenal insufficiency and incomplete hypogonadotropic hypogonadism. *Journal of Clinical Investigation* **105** 321–328. (doi:10.1172/JCI17212)
- 6 Mantovani G, Ozisik G, Achermann JC, Romoli R, Borretta G, Persani L, Spada A, Jameson JL, Beck-Peccoz P *et al.* 2002 Hypogonadotropic hypogonadism as a presenting feature of late-onset X-linked adrenal hypoplasia congenita. *Journal of Clinical Endocrinology and Metabolism* **87** 44–48. (doi:10.1210/jcem.87.1.8163)
- 7 Sekiguchi Y, Hara Y, Matsuoka H, Hayashi Y, Katsumata N & Hirata Y 2007 Sibling cases of Addison's disease caused by DAX-1 gene mutations. *Internal Medicine* **46** 35–39. (doi:10.2169/internalmedicine.46.6082)
- 8 Guclu M, Lin L, Erturk E, Achermann JC & Cangul H 2010 Puberty, stress, and sudden death. *Lancet* **376** 1512. (doi:10.1016/S0140-6736(10)61153-1)
- 9 Oh CM, Chun S, Lee JE, Lee JS, Park S, Gee HY, Kim SW *et al.* 2017 A novel missense mutation in NROB1 causes delayed-onset primary adrenal insufficiency in adults. *Clinical Genetics*. (doi:10.1111/cge.12966)

Received in final form 23 June 2017

Accepted 27 July 2017